

HEPATOPROTECTIVE EFFECTS OF PIPERINE ON THIOACETAMIDE-INDUCED HEPATOTOXICITY IN RATS: A LIPID PROFILE ANALYSIS

Abstract. Piperine is an alkaloid with possesses bio-enhancing properties, has a long history of traditional use in revitalizing the liver and treating various hepatic ailments. Therefore, the current investigation aimed to determine the hepatoprotective potential of Piperine following oral administration in albino rats with liver damage induced by thioacetamide. In this study, thirty rats were divided into five equal groups, each groups containing 6 rats and experimented for eighth weeks. **Group I** (control): received normal saline @ 0.9 % p.o daily. **Group II** (diseased): received a single dose of Thioacetamide (TAA@ 150 mg/kg), twice per week. **Group III:** received Piperine (PIP @ 50 mg/kg b.d wt p.o daily) orally. **Group IV:** received TAA (@ 150 mg/kg i.p. twice/week) + PIP (@ 50 mg/kg b.d wt p.o daily). **Group V** (standard group): TAA (@ 150 mg/kg i.p. twice/week) +standard drug (Silymarin @ 50 mg/kg p.o daily). At the end of the experiment (57th day) all rats were sacrificed. The thioacetamide-treated group (Group II) exhibited severe changes in the lipid profile parameters (total cholesterol, triglyceride, high-density lipoprotein (HDL) and low-density lipoprotein (LDL) cholesterol and glucose level. Based on the observed results in piperine-treated groups (IV) compared to the thioacetamide group (II), the study suggests piperine's potential for hepatoprotection against thioacetamide-induced hepatotoxicity.

Keywords: Piperine, Thioacetamide, lipid profile, hepatoprotection, hypocholesterolemic and hypoglycemic effect.

Introduction. Liver fibrosis is a major health concern with no standard treatment due to its complex causes with significant morbidity and mortality (Altamirano-Barrera et al., 2017). This chronic condition is characterized by the excessive deposition of extracellular matrix (ECM) by activated hepatic stellate cells (HSCs), leading to a progressive distortion of the normal liver architecture and impaired function (Reeves & Friedman, 2002). Inflammation, often triggered by oxidative stress, is a key driver of HSC activation (Greenwel et al., 2000). Pro-inflammatory cytokines, chemokines, and adhesion molecules further contribute to this process, creating a complex web of signaling pathways that promote fibrosis (Pinzani & Macias-Barragan, 2010). The absence of effective treatment options underscores the urgent need for novel therapeutic strategies to target liver fibrosis. Medicinal plants have been used for centuries as a source of food, spices, and remedies for many diseases. Black pepper (*Piper nigrum*), a member of the *Piperaceae* family, is one of the most commonly used spices in the world. It has a distinct sharp flavor due to the presence of Piperine, a phytochemical. Piperine (1-piperoyl piperidine) is a major alkaloid of *Piper nigrum* Linn. (Piperaceae) and *Piper longum* Linn. (*Piperaceae*) and has been reported to possess bioavailability enhancing activity by increasing absorption various drug molecule (Lee et al., 2005) (Khatri et al., 2015, 2016). This might be achieved due to alteration in membrane lipid dynamics and change in the conformation of enzymes in the intestine. Piperine was also reported to possess numerous benefits including antioxidant (Vijayakumar et al., 2004), antimicrobial (Mirza et al., 2011), neuroprotective (Chonpathompikunlert et al., 2010), antiparasitic (Freire-de-Lima et al., 2008) anticancer (Bezerra et al., 2008), analgesic (Yasir et al., 2018), anti-inflammatory (Bang et al., 2009) anti-apoptotic (Shrivastava et al., 2013), hepatoprotective (Koul and Kapil, 1993), antitumor (Sunila et al., 2004), immunomodulatory (Sunila et al., 2004), antimutagenic (Abo-Zeid et al., 2009) and antimetastatic (Smilkov et al., 2019).

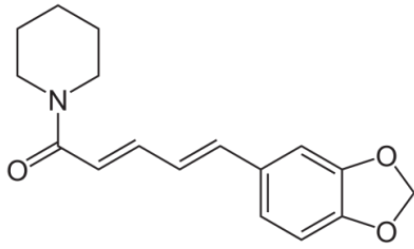


Fig. 1. Structure of Piperine

(Haq et al., 2021)

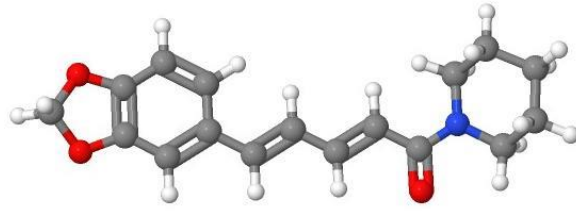


Fig. 2. Interactive Chemical Structure 3D

Model (Ball and Stick)

Source:<https://pubchem.ncbi.nlm.nih.gov/compound/Piperine#section=3D-Conformer&fullscreen=true>

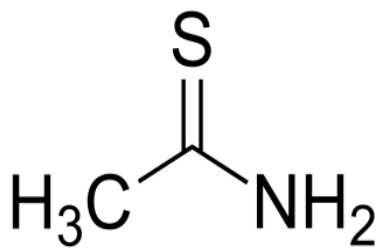


Fig. 3. Chemical Structure of Thioacetamide

(Source:https://en.wikipedia.org/wiki/File:Ethanethioamide_200.svg)

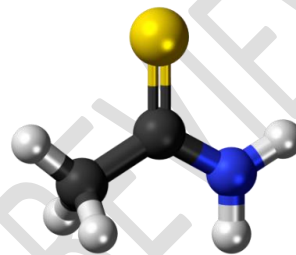


Fig. 4. Interactive Chemical Structure 3D

Model (Ball and Stick)

(Source:<https://pubchem.ncbi.nlm.nih.gov/compound/Thioacetamide#section=3D-Conformer>)

METHODOLOGY

Materials and Methods. This study was conducted at the Department of Veterinary Pharmacology and Toxicology, College of Veterinary Science, P.V. Narsimha Rao Telangana Veterinary University, Hyderabad, Telangana, Republic of India (Bharat).

Animals. Adult, inbred albino rats of either sex, weighing 150–200 g, were used in this study. The rats were housed in clean polycarbonate cages at the College of Veterinary Science, Hyderabad, Telangana, with ad libitum access to water and a regular pellet diet. Following a two-week acclimation period under close veterinary supervision to ensure good health, the animals were subjected to the experiment. All procedures were conducted in accordance with ethical guidelines to

minimize stress. The study was approved by the Institutional Animal Ethics Committee (IAEC) with reference number **IAEC No. 02/26/C.V.Sc, Hyd. IAEC**. All procedures adhered to the Committee for the Purpose of Control and Supervision of Experiments on Animals (CPCSEA) guidelines for animal care and use. **Tab. 1** demonstrates the experimental design of the research work.

Experimental Design. Thirty healthy, inbred albino rats (150-200 g) were randomly divided into five groups (n=6/group). The chemicals used were **Piperine** (PIP, 50 mg/kg body weight/day, oral), thioacetamide (TAA, 150 mg/kg body weight, intraperitoneal injection twice/week), and normal saline (0.9 %, oral). The groups were as follows:

Table 1. Different experimental groups and their treatment

Groups	Treatments	No. of animals
I	Control (Normal Saline @ 0.9 % p.o daily)	6
II	Disease control Thioacetamide (TAA @ 150 mg/kg i.p. twice/week)	6
III	Piperine (PIP @ 50 mg/kg b.d wt p.o daily)	6
IV	TAA (@ 150 mg/kg i.p. twice/week) + PIP (@ 50 mg/kg b.d wt p.o daily)	6
V	TAA (@ 150 mg/kg i.p. twice/week) + Standard drug (Silymarin @ 50 mg/kg p.o daily)	6

Body weight. The body weight changes were recorded weekly for 8 weeks. Individual body weights of all rats were recorded on 0th, 7th day, 14th day, 21st day, 28th day, 35th day, 42nd day, 49th day and 56th day of the total 8 weeks of experiment.

Organ weight. On the 56th day of the study, rats were euthanized with a CO₂ chamber, and liver and kidney weights were measured. The relative organ weight was calculated as organ weight (mg) per body weight (g).

Lipid profile parameters. This study investigated the potential of Piperine, a nutraceutical from black pepper (*Piper nigrum*), against thioacetamide (TAA)-induced liver fibrosis in mice. Silymarin served as a reference antifibrotic drug. Piperine @ 50 mg/kg significantly improved liver function by reducing total cholesterol, triglyceride, HDL and LDL cholesterol and glucose. These improvements were confirmed by body weight and liver index (%) changes in rats.

Statistical Analysis. Data analysis followed the statistical methods recommended by Snedecor and Cochran (Snedecor and Cochran, 1989).

~~RESULT~~

Results and Discussion.

UNDER PEER REVIEW

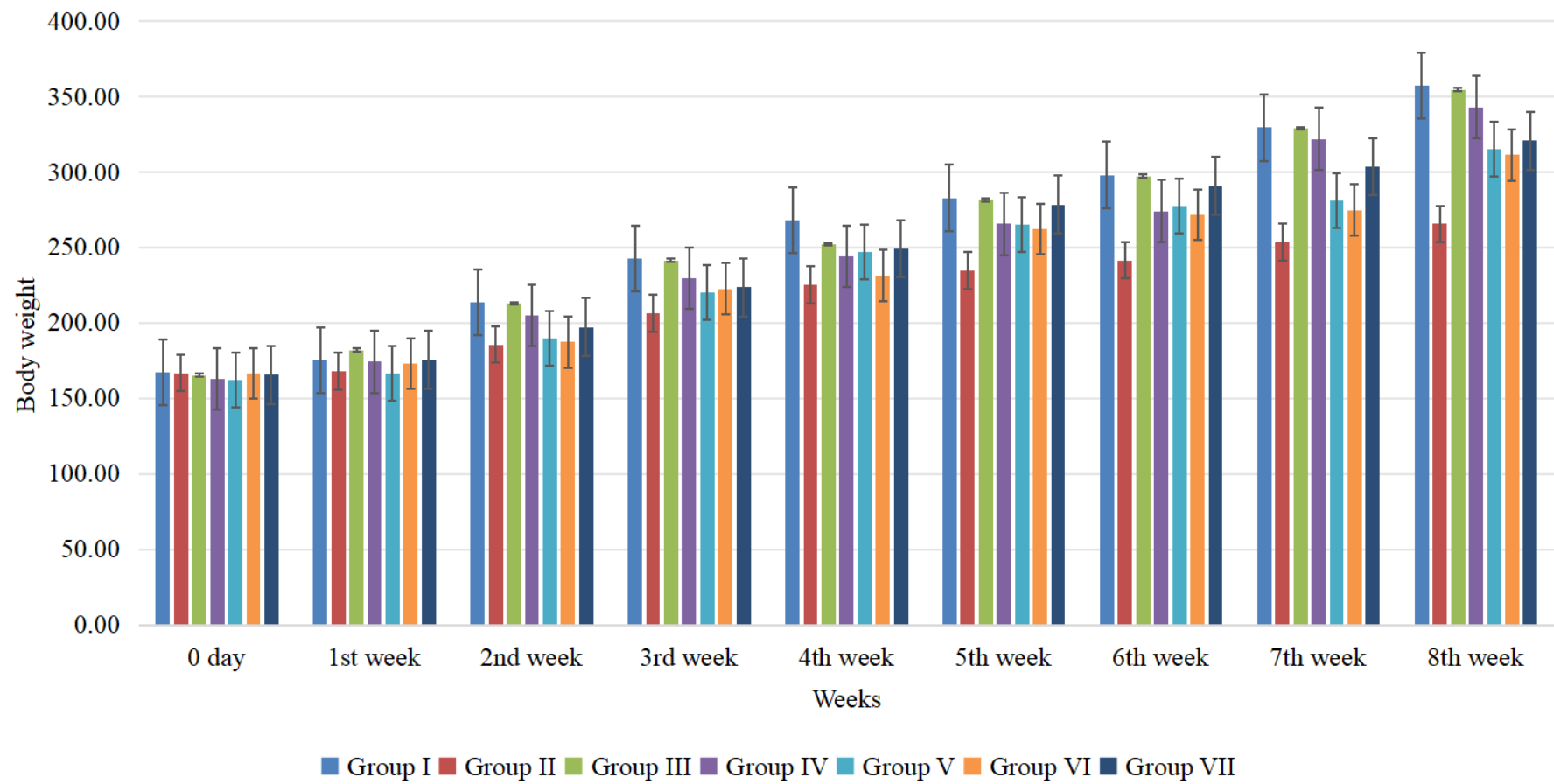


Fig. 5. Mean \pm body weight (g) in different groups of rats in different weeks

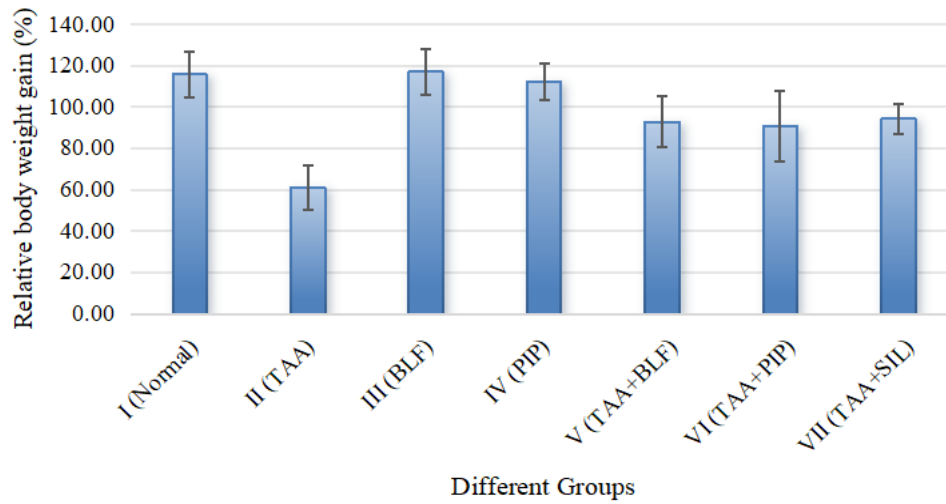


Fig. 6. Relative body weight gain (%)

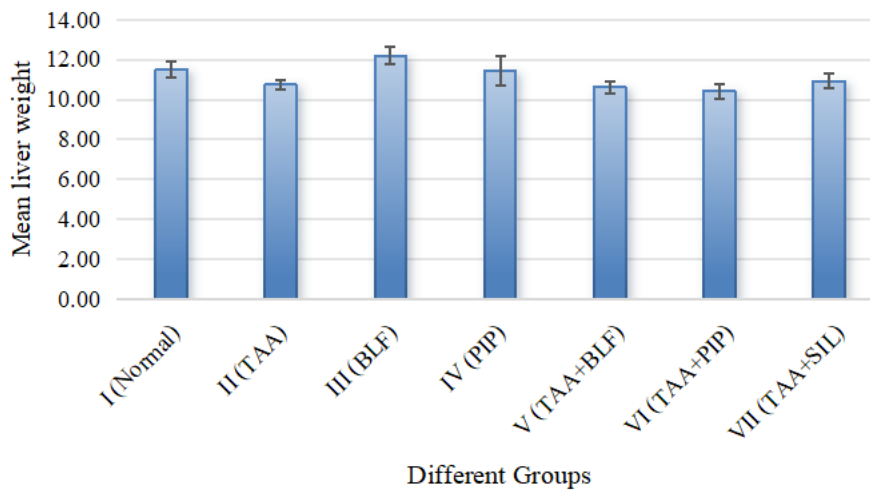


Fig. 7. Mean liver weight

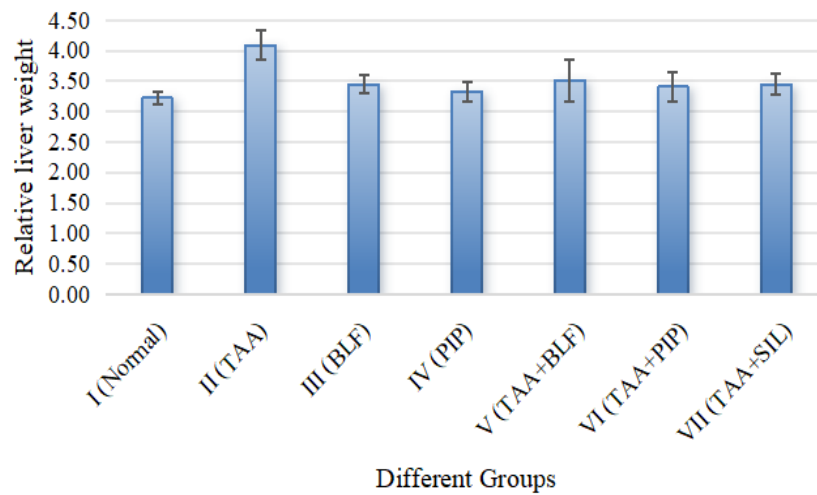


Fig. 8. Relative liver weight or liver index (%)

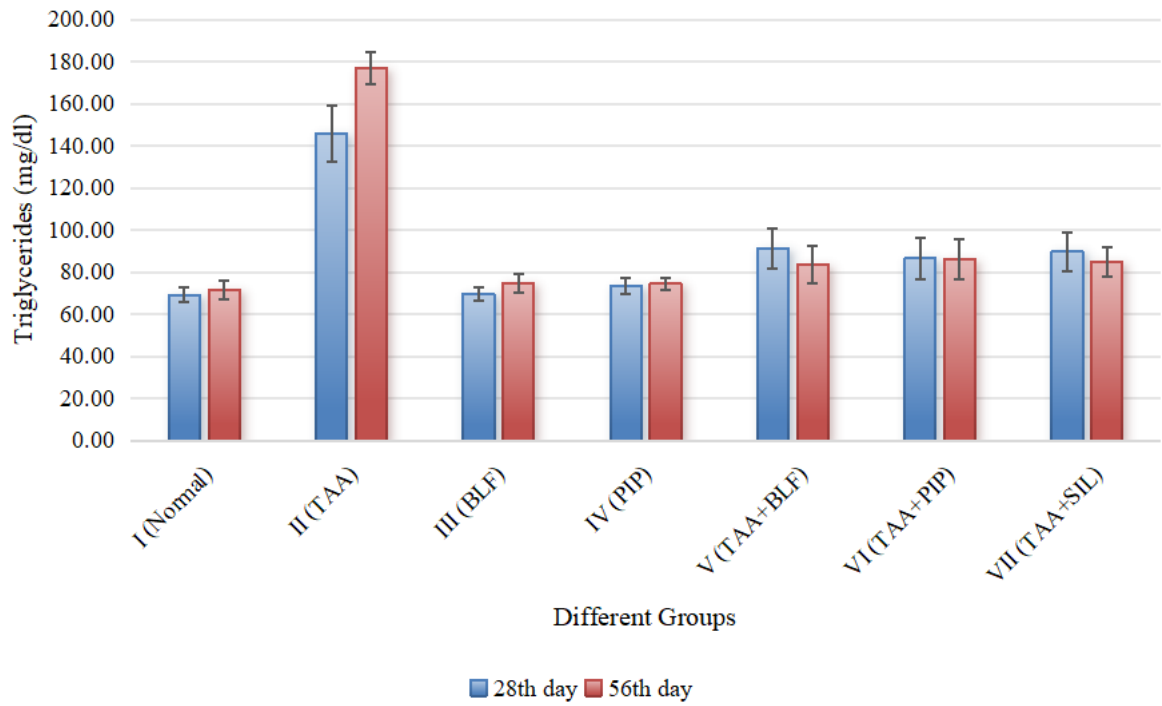


Fig. 9. Triglycerides concentration (mg/dl) in different groups of rats

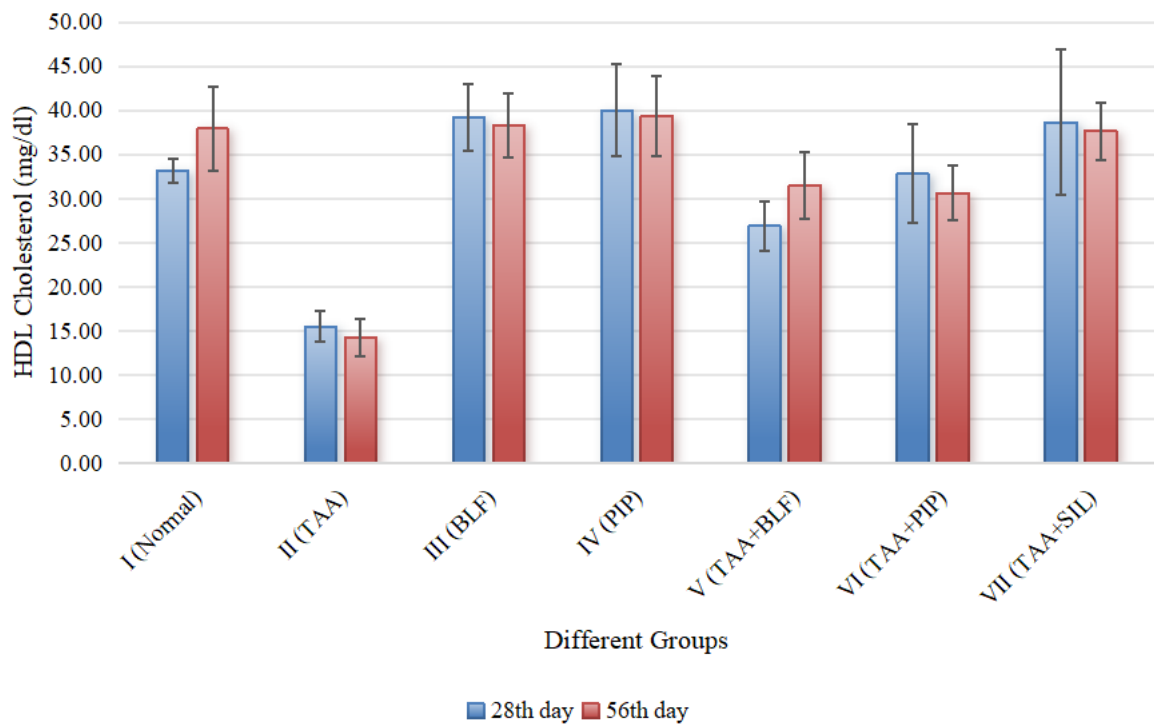


Fig. 10. HDL Cholesterol concentration (mg/dl) in different groups of rats

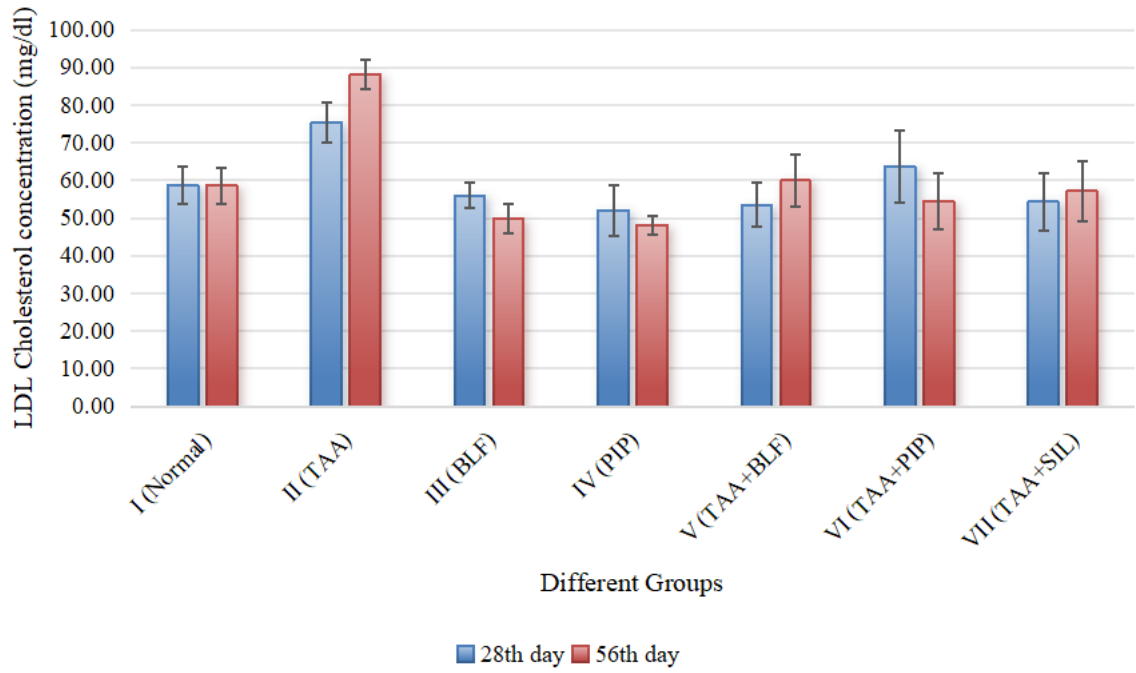


Fig. 11. LDL Cholesterol concentration (mg/dl) in different groups of rats

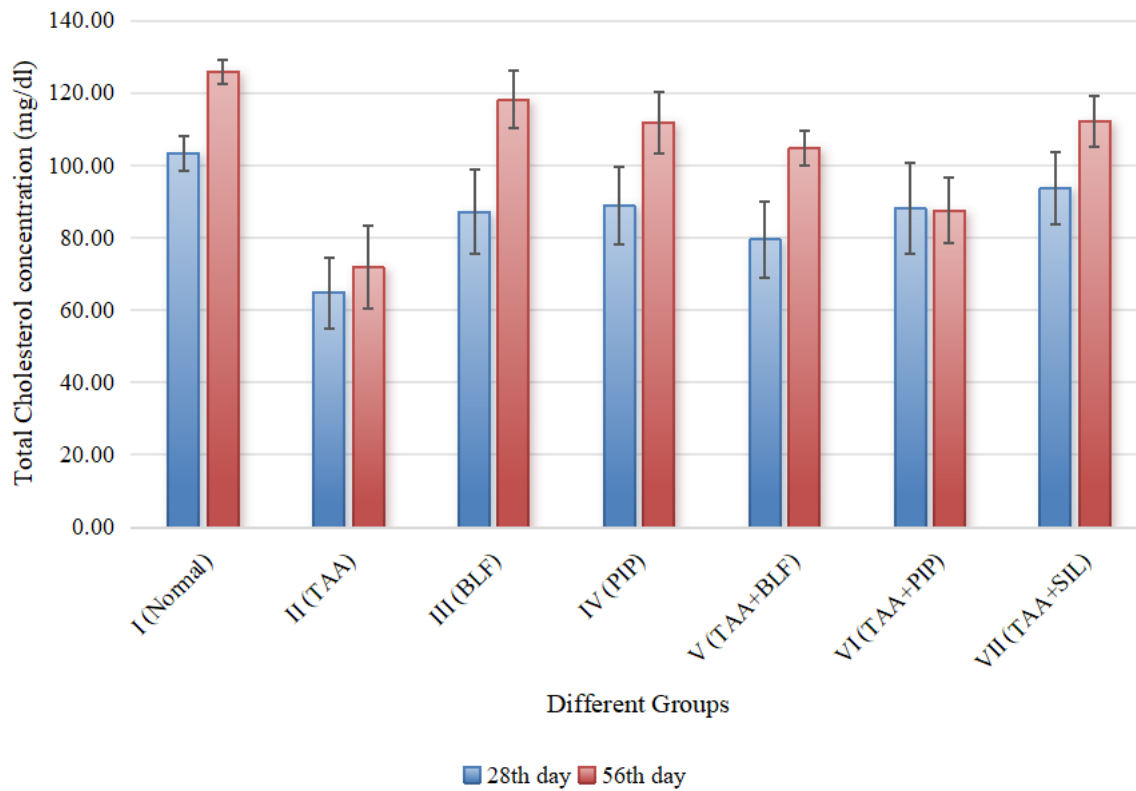


Fig. 12. Total Cholesterol concentration (mg/dl) in different groups of rats

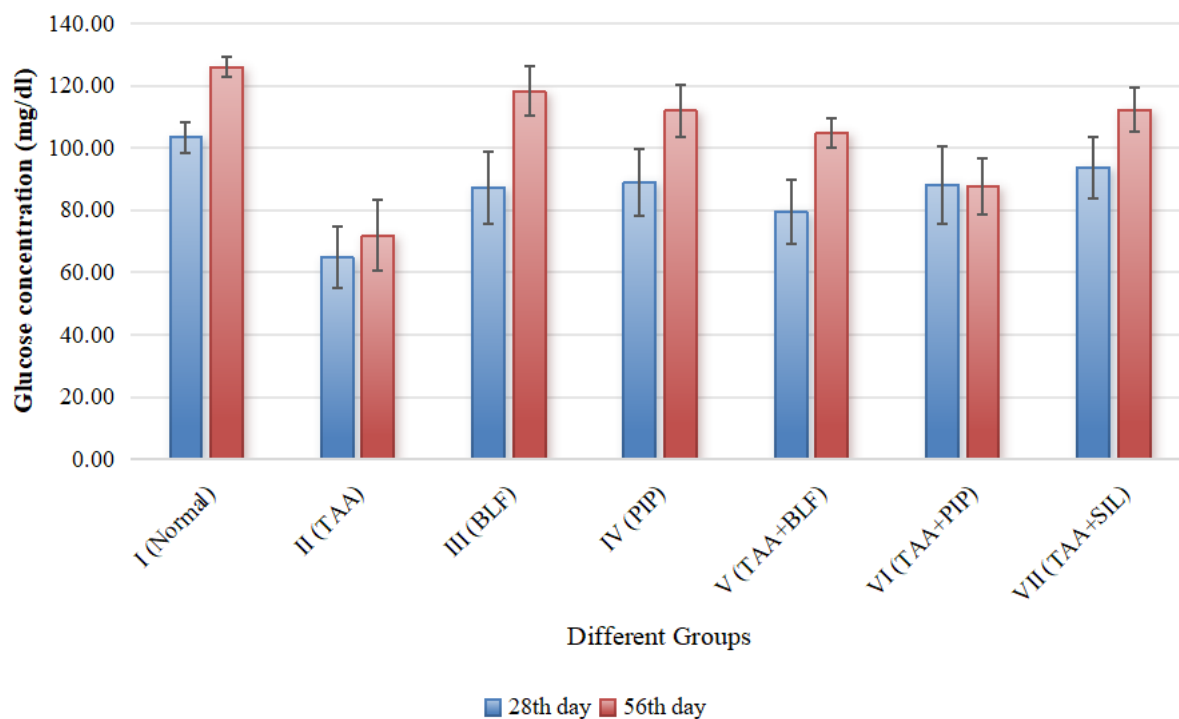


Fig. 13. Glucose concentration (mg/dl) in different groups of rats

DISCUSSION

The results of body weights of the present study demonstrated that BLF and PIP orally administered against thioacetamide induced hepatic toxicity severely affected the body weight and performance of Wistar rats. Body weight in all the groups animals was observed to be increased as the experiment advanced except Group II (TAA). Thioacetamide (TAA) administration induced marked toxicity in rats, as evidenced by their impaired body weight gain. The body weight in Group II (TAA) animals was observed to be significantly lower than in all other groups on 56th day of experiment, this finding aligns with previous studies suggesting that TAA exposure reduces nutrient absorption and metabolic efficiency, thereby hindering growth rate (Kadir et al., 2013, Li et al., 2002, Hessin et al., 2015). Interestingly, the Group V (TAA+BLF) exhibited body weight increase as compare to the Group II (TAA). This suggests a potential mitigating effect of BLF on TAA-induced growth impairment, possibly by improving nutrient uptake or metabolism (Togawa et al., 2002a). Body weight measurements in Group VI (TAA+PIP) demonstrated a significant recovery compared to Group II (TAA) exposed only to thioacetamide (TAA). This finding suggests that piperine treatment (PIP) may mitigate the body weight loss associated with TAA-induced hepatic toxicity. The combine affect of curcuming and piperine

against thioacetamide induced hepatotoxicity found to have increase body weight in rats demonstrated by Shivhare et al. (2023).

Our study employed prolonged (Eight weeks) TAA administration in rats, resulting in observable visual and quantifiable changes in body weight and body weight gain, TAA administration in the toxic group resulted in a significantly reduced body weight gain compared to the normal control group. Conversely, treatment groups receiving TAA combined with BLF (Group V) and PIP (Group VI) exhibited a statistically significant increase in body weight gain relative to the TAA group alone, corroborating findings by Zaidi and Masood (2020) and (Togawa et al. (2002b)). The observed decrease in body weight suggests a state of sustained catabolism. However, it remains to be elucidated whether this reduction is a direct consequence of TAA-induced hepatotoxicity or an indirect effect mediated by liver injury.

Eight weeks of thioacetamide administration significantly increased in liver-to-body weight (relative liver weight) ratio in the toxic group compared to controls. Conversely, the treatment groups (TAA + BLF or Group V and TAA + PIP or Group VI) exhibited a significant decrease in both parameters compared to the toxic group. Interestingly -?. Of particular interest are the works of.... As previously demonstrated by Rizzo et al. (1997), they observed hepatomegaly in TAA-treated rats is a well-established indicator of hepatic lesions and associated liver damage resulting from the well-documented toxicological effects of TAA. Hsieh et al. (2008) reported a significant increase in liver weight in rats following Thioacetamide administration, a well-established model of hepatotoxicity. Furthermore, the formation of ECM in fibrotic livers offers the higher liver-to-body weight ratio (liver index). This explains the elevated liver index observed in the TAA group (Chen et al., 2012).

Our results of lipid profile test demonstrated a significant decrease in HDL cholesterol levels within the TAA-exposed group compared to the control group. Conversely, groups V (TAA + BLF) and VI (TAA + PIP) exhibited a significant increase in HDL (high-density lipoprotein cholesterol) cholesterol and total cholesterol levels compared to the TAA-exposed group. These observations suggest that TAA toxicity induces significant alterations in plasma and hepatic metabolism. Plasma analysis reveals hypoglycemia (decreased blood glucose), decreased HDL cholesterol (the “good” cholesterol), and a reduction in total protein. Conversely, plasma levels of triglycerides, total cholesterol, and LDL (low-density lipoprotein cholesterol) cholesterol (the “bad” cholesterol) and total cholesterol are elevated.

Hepatic analysis demonstrates disrupted metabolic protein profiles alongside dysregulation of both carbohydrate and lipid metabolism (Trennery and Waring, 1983; Galisteo et al., 2006; Jain and Singhai, 2011).

The liver serves as a central metabolic hub, act as the regulator of carbohydrate, protein, and lipid metabolism. A critical function of the liver is the storage and metabolism of glycogen as a readily available energy source. This process ensures glucose homeostasis during fasting periods, particularly for tissues with a preferential or obligate reliance on glucose, such as neurons and erythrocytes (Nelson and Cox, 2022). In our findings the glucose level was reduced (on both 28th and 56th day of experiment) as compare to the TAA induced rats as compare to the normal control group, but the treatment groups TAA+BLF (group V) and TAA+PIP (group VI) showed significantly higher in glucose level as compare to the TAA toxic group. TAA toxicity likely induces a biphasic response in blood glucose regulation. Initially, TAA may promote glycogenolysis (anaerobic breakdown of liver glycogen), leading to a temporary increase in blood glucose. This could potentially stimulate pancreatic β -cells and subsequent insulin secretion. However, with prolonged exposure (e.g., by the 8th week observed by Ebrahim et al., 2004), TAA-induced hepatotoxicity may deplete hepatic glycogen stores, resulting in hypoglycemia despite elevated serum insulin levels.

Conclusion. Piperine may effect (influence) the production of TC, TG, LDL and HDL, glucose level and may improve the function of hepatocytes liver cells, which are responsible for many important tasks, such as detoxification and waste excretion. Experimentally proven pharmacological effects are aimed at stabilising the functional state of the liver. and waste removal. This can help to improve overall liver health. The analysis of the obtained experimental data may be the basis for further in-depth studies of the functioning of the liver and the hepatobiliary system as a whole, to identify biomarkers of enzymatic nature to prove the presence of membrane-stabilising, antioxidant, anti-inflammatory activity of Piperine and its probable mechanisms of pharmacological action.

REFERENCES

- Hessin A, Hegazy R, Hassan A, Yassin N and Kenawy S. 2015. Lactoferrin enhanced apoptosis and protected against thioacetamide-induced liver fibrosis in rats. Open access Macedonian journal of medical sciences 3 (2): 195.
- Kadir F A, Kassim N M, Abdulla M A and Yehye W A. 2013. Hepatoprotective role of ethanolic extract of Vitex negundo in thioacetamide-induced liver fibrosis in

- male rats. *Evidence-based Complementary and Alternative Medicine* 2013 (1): 739850.
- Hsieh C C, Fang H L and Lina W C. 2008. Inhibitory effect of *Solanum nigrum* on thioacetamide-induced liver fibrosis in mice. *Journal of ethnopharmacology* 119 (1):117-21.
- Shivhare S, Shrman K, Gautam V and Dubey S. 2023. Histopathological examination of the hepatoprotective effect of curcumin with piperine on thioacetamide induced hepatotoxicity in rats. *Emer Life Sci Res* 9 (2): 51-60
- Li X, Benjamin I S and Alexander B. 2002 Reproducible production of thioacetamide-induced macronodular cirrhosis in the rat with no mortality. *Journal of hepatology* 36 (4): 488-93.
- Zaidi S N and Masood J. 2020. The protective effect of fenugreek seeds extract supplementation on glucose and lipid profile in thioacetamide induced liver damage in rats. *Pakistan Journal of Pharmaceutical Sciences* 33 (5).
- Rizzo C C, de Castro O, Junior S, Sankarankutty A K, Menegazzo L A and Granato R G. 1997. Repercussões sistêmicas da icterícia obstrutiva. *Medicina (Ribeirão Preto)* 30 (2): 173-82.
- Togawa J I, Nagase H, Tanaka K, Inamori M, Umezawa T, Nakajima A, Naito M, Sato S, Saito T and Sekihara H. 2002b. Lactoferrin reduces colitis in rats via modulation of the immune system and correction of cytokine imbalance. *American Journal of Physiology-Gastrointestinal and Liver Physiology* 283 (1): G187-95.
- Togawa J I, Nagase H, Tanaka K, Inamori M, Nakajima A, Ueno N, Saito T and Sekihara H. 2002a. Oral administration of lactoferrin reduces colitis in rats via modulation of the immune system and correction of cytokine imbalance. *Journal of gastroenterology and hepatology* 17 (12): 1291-8.
- Galisteo M, Suárez A, Montilla M P, Fernandez M I, Gil A and Navarro M C. 2006. Protective effects of *Rosmarinus tomentosus* ethanol extract on thioacetamide-induced liver cirrhosis in rats. *Phytomedicine* 13 (1-2): 101-8.
- Trennery P N and Waring R H. 1983. Early changes in thioacetamide-induced liver damage. *Toxicology letters* 19 (3): 299-307.
- Lee SA, Hong SS, Han XH, Hwang JS, Oh GJ, Lee KS, Lee MK, Hwang BY, Ro JS. Piperine from the fruits of *Piper longum* with inhibitory effect on monoamine oxidase and antidepressant-like activity. *Chemical and pharmaceutical bulletin*. 2005;53(7):832-5.
- Jain N K and Singhai A K. 2011. Protective effects of *Phyllanthus acidus* (L.) Skeels leaf extracts on acetaminophen and thioacetamide induced hepatic injuries in Wistar rats. *Asian Pacific Journal of Tropical Medicine* 4 (6): 470-4.
- Khatri S, Awasthi R. Piperine containing floating microspheres: an approach for drug targeting to the upper gastrointestinal tract. *Drug delivery and translational research*. 2016 Jun;6:299-307.
- Armed Forces Institute of Pathology (US), 1960. Manual of histologic and special staining technics. McGraw-Hill, Blakiston Division.
- Snedecor, G.W. and Cochran, W.G., 1989. Statistical methods, 8thEdn. Ames: Iowa State Univ. Press Iowa, 54, pp.71-82.
- Vijayakumar R, Surya D, Nalini N. Antioxidant efficacy of black pepper (*Piper nigrum* L.) and piperine in rats with high fat diet induced oxidative stress. *Redox Report*. 2004 Apr 1;9(2):105-10.

- Mirza ZM, Kumar A, Kalia NP, Zargar A, Khan IA. Piperine as an inhibitor of the MdeA efflux pump of *Staphylococcus aureus*. *Journal of medical microbiology*. 2011 Oct;60(10):1472-8.
- Chonpathompikunlert P, Wattanathorn J, Muchimapura S. Piperine, the main alkaloid of Thai black pepper, protects against neurodegeneration and cognitive impairment in animal model of cognitive deficit like condition of Alzheimer's disease. *Food and Chemical Toxicology*. 2010 Mar 1;48(3):798-802.
- Freire-de-Lima L, Ribeiro TS, Rocha GM, Brandão BA, Romeiro A, Mendonça-Previato L, Previato JO, de Lima ME, de Carvalho TM, Heise N. The toxic effects of piperine against *Trypanosoma cruzi*: ultrastructural alterations and reversible blockage of cytokinesis in epimastigote forms. *Parasitology research*. 2008 Apr;102:1059-67.
- Bezerra DP, Castro FO, Alves AP, Pessoa C, Moraes MO, Silveira ER, Lima MA, Elmiro FJ, Alencar NM, Mesquita RO, Lima MW. In vitro and in vivo antitumor effect of 5-FU combined with piplartine and piperine. *Journal of Applied Toxicology: An International Journal*. 2008 Mar;28(2):156-63.
- Yasir A, Ishtiaq S, Jahangir M, Ajaib M, Salar U, Khan KM. Biology-oriented synthesis (BIOS) of piperine derivatives and their comparative analgesic and anti-inflammatory activities. *Medicinal Chemistry*. 2018 May 1;14(3):269-80.
- Bang JS, Oh DH, Choi HM, Sur BJ, Lim SJ, Kim JY, Yang HI, Yoo MC, Hahm DH, Kim KS. Anti-inflammatory and antiarthritic effects of piperine in human interleukin 1 β -stimulated fibroblast-like synoviocytes and in rat arthritis models. *Arthritis research & therapy*. 2009 Apr;11:1-9.
- Shrivastava P, Vaibhav K, Tabassum R, Khan A, Ishrat T, Khan MM, Ahmad A, Islam F, Safhi MM, Islam F. Anti-apoptotic and anti-inflammatory effect of Piperine on 6-OHDA induced Parkinson's rat model. *The Journal of Nutritional Biochemistry*. 2013 Apr 1;24(4):680-7.
- Koul IB, Kapil A. Evaluation of the liver protective potential of piperine, an active principle of black and long peppers. *Planta medica*. 1993 Oct;59(05):413-7.
- Sunila ES, Kuttan G. Immunomodulatory and antitumor activity of *Piper longum* Linn. and piperine. *Journal of ethnopharmacology*. 2004 Feb 1;90(2-3):339-46.
- Abo-Zeid MA, Farghaly AA. The anti-mutagenic activity of piperine against mitomycin C induced sister chromatid exchanges and chromosomal aberrations in mice. *Nat. Sci*. 2009;7:72-8.
- Hsieh, C.C., Fang, H.L. and Lina, W.C., 2008. Inhibitory effect of *Solanum nigrum* on thioacetamide-induced liver fibrosis in mice. *Journal of ethnopharmacology*, 119(1), pp.117-121.
- Haq I U, Imran M, Nadeem M, Tufail T, Gondal T A and Mubarak M S. 2021. Piperine: A review of its biological effects. *Phytotherapy research* 35 (2): 680-700.
- Reeves HL, Friedman SL. Activation of hepatic stellate cells—a key issue in liver fibrosis. *Front Biosci*. 2002 Apr 1;7(4):808-26.
- Greenwel P, Domínguez-Rosales JA, Mavi G, Rivas-Estilla AM, Rojkind M. Hydrogen peroxide: A link between acetaldehyde-elicited $\alpha 1$ (i) collagen gene up-regulation and oxidative stress in mouse hepatic stellate cells. *Hepatology*. 2000 Jan;31(1):109-16.
- Pinzani M, Macias-Barragan J. Update on the pathophysiology of liver fibrosis. *Expert review of gastroenterology & hepatology*. 2010 Aug 1;4(4):459-72.
- Altamirano-Barrera A, Barranco-Fragoso B, Méndez-Sánchez N. Management strategies for liver fibrosis. *Annals of hepatology*. 2017 Jan 15;16(1):48-56.