

# Mantle Cell Lymphoma of Gastrointestinal Tract as a Lead Point for Intussusception: A Case Report

## Abstract:

Intussusception is a rare event seen in adults; we hereby present a case of 60 years old male who presented with features of acute intestinal obstruction. On exploratory laparotomy, the patient was found to have an ileocolic intussusception along with a large mesenteric lymph node, resection of the ileocolic segment was done, and the histopathology and immunohistochemistry were suggestive of Mantle Cell Lymphoma which is a subtype of B-Cell Non-Hodgkins Lymphoma. Patient has been managed with 6 cycles of R-CHOP chemotherapy.

Key words: Chemotherapy, Hodgkins Lymphoma, immunohistochemistry, lymphoid cells

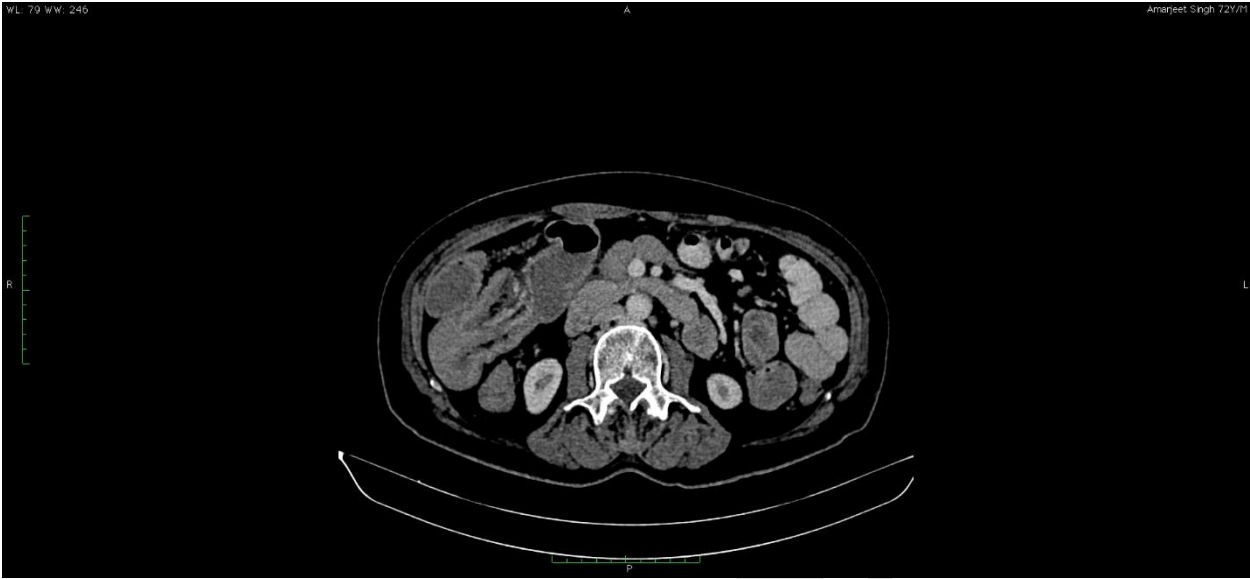## Introduction:

Intussusception is the telescoping of a proximal segment of the bowel into the lumen of the distal segment. This pathology has an incidence of 1.5-4 cases per 1000 live births, with Male: Female ratio being 3:2. (1) The usual age of presentation is in infancy, where it is considered primary with no specific lead point whereas in adults it is often secondary to some lead points like lipomas, hamartomas, adenocarcinomas, etc. Malignant lymphoma is an infrequent cause of intussusception, being a lead point in less than 1% of cases (2,8-10). Diffuse large B cell lymphoma is the most common type of lymphoma incriminated in intussusception. Although Mantle cell lymphoma usually has extensive GIT involvement, there are very few cases where MCL was a lead point of intussusception (2).

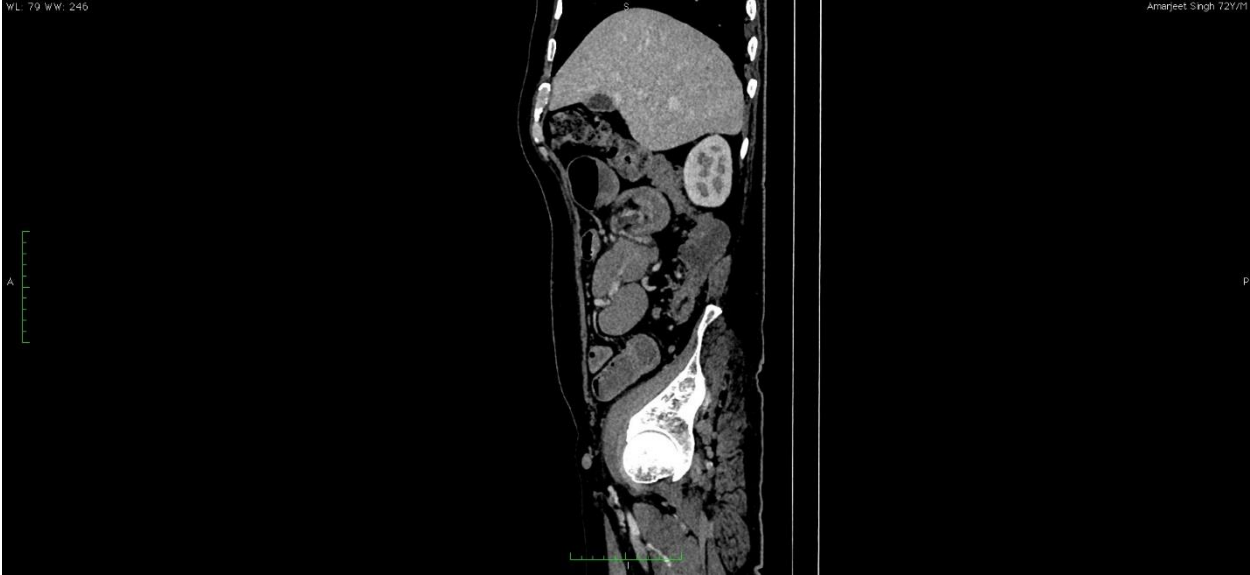## Case Presentation:

We hereby present a 60 years old male patient who presented to the emergency department with recurrent episodes of intermittent diffuse abdominal pain, anorexia, and altered blood in stools for 2 months, abdominal distension and bilious non-projectile vomiting since 2 days. A working diagnosis of acute intestinal obstruction was made and the patient was subjected to Contrast-enhanced computed tomography of the abdomen which demonstrated ileocolic intussusception with invagination of the distal segment of ileum into the proximal ascending colon with associated mild proximal dilation of the bowel loops (Figure 1A, Figure 1B and Figure 1C). The patient was taken up for exploratory laparotomy, initial attempts were made to reduce the intussusception, but upon failure to do so, we proceeded to do a right hemicolectomy with primary ileocolic anastomosis with a proximal covering ileostomy. Histopathology of the resected specimen showed diffuse subepithelial infiltrate of the monotonous population of small to medium-sized lymphoid cells admixed with few small lymphocytes and histiocytes; Lymphoid cells had oval to slightly indented nuclei, dark clumped chromatin, inconspicuous nucleoli and scanty cytoplasm which was suggestive of lymphoma (Figure 2). Immunohistochemical (IHC) staining identified the abnormal lymphoid cells as CD20+, CD5+, CD43+, Cyclin D1+, SOX11+, and LCA+ with Ki 67 proliferative index being 30%, hence making a diagnosis of Mantle Cell Lymphoma. After

satisfactory post-operative recovery, the patient was referred to the department of oncology where he was administered 6 cycles of Rituximab, Cyclophosphamide, Hydroxydaunorubicin, Oncovin, Prednisolone (R-CHOP regimen). The patient underwent ileostomy closure at the end of 6 months.



Figure



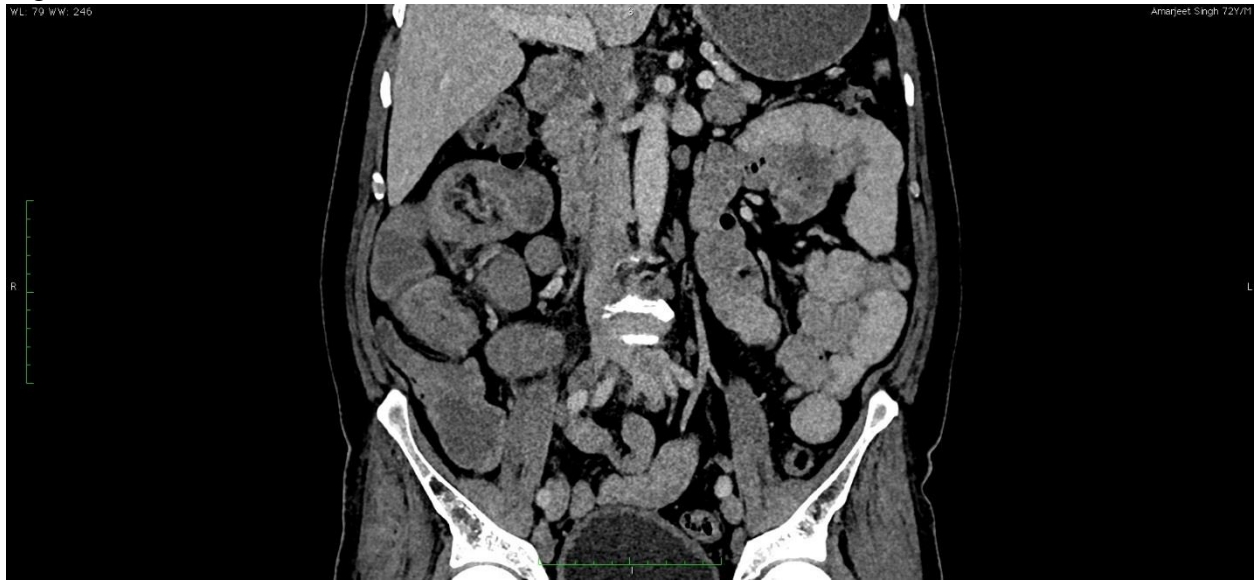


Figure 1C

Figures 1(A-C) mild proximal dilation of the bowel loops

UNDER PEER REVIEW

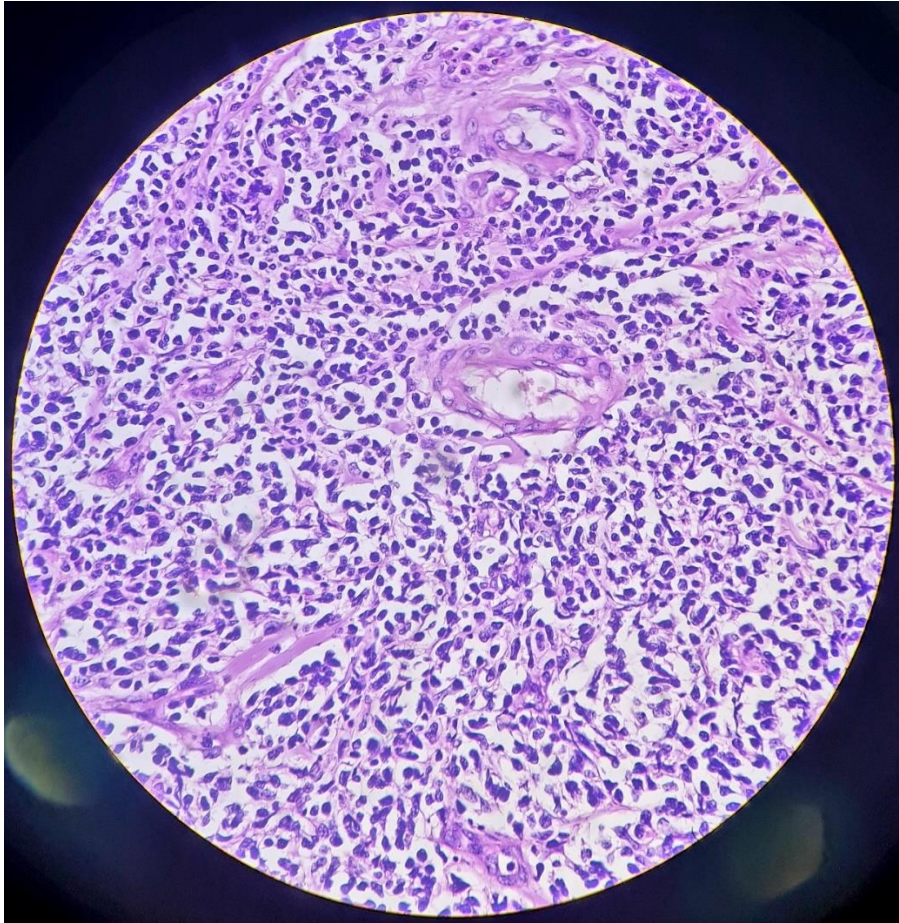


Figure 2: Histopathology of specimen suggestive of Mantle Cell Lymphoma

### Discussion:

Mantle Cell Lymphoma is a subtype of Non-Hodgkins Lymphoma comprising ~7% of adult cases of NHL. The typical age of presentation is 60 years with lymphadenopathy and advanced-stage disease (III or IV).

Mantle cell lymphoma is a derivative of the naïve B cell population of the lymphoid mantle zone. These cells are negative for CD23 and positive for CD5 by immunohistochemistry (4). Cytogenetically, in Mantle cell lymphoma, there is overexpression of Cyclin D1 associated with a rearrangement of Bcl-1 locus on chromosome 11 due to t (11:14) (q13;q32).

Xie CG, Kella et al, and Matsuda K et al presented similar reports of ileocaecal intussusception with mantle cell lymphoma as a lead point. In all these cases patients were managed surgically with resection of the involved segment except for in the case report by Matsuda et al where reduction of intussusception was done by endoscopic manipulation and right hemicolectomy was done at a later date as a precaution to prevent a recurrence (5,6,7). In case reports by Xie CG, Matsuda K et al postoperative chemotherapy was refused by the patient, Kella V et al administered 6 cycles of R-CHOP regimen post operatively. However, 2 year follow up in all these patients was

uneventful and patient was found in remission. At 2 year follow up of our patient, PET-CT did not show any metabolically active lesion and patient is currently in remission.

## **Conclusion**

Intussusception in adults is very rare and, whenever present, signifies a malignant pathology and warrants surgical intervention. In conclusion, if an adult is diagnosed with intussusception, Mantle cell lymphoma must be considered as a differential.

## **Consent**

As per international standards or university standards, patient(s) written consent has been collected and preserved by the author(s).

## **Disclaimer (Artificial intelligence)**

### **Option 1:**

Author(s) hereby declare that NO generative AI technologies such as Large Language Models (ChatGPT, COPILOT, etc) and text-to-image generators have been used during writing or editing of manuscripts.

### **Option 2:**

Author(s) hereby declare that generative AI technologies such as Large Language Models, etc have been used during writing or editing of manuscripts. This explanation will include list the name, version, model, and source of the generative AI technology and as well as the all input prompts provided to a generative AI technology

Details of the AI usage are given below:

- 1.
- 2.
- 3.

## **References:**

- 1) Shakya VC, Agrawal CS, Koirala R, et al. Intussusception due to non-Hodgkin's lymphoma; different experiences in two children: two case reports. *Cases J.* 2009;2:6304.

- 2) Grin A, Chetty R, Bailey D. Mantle cell lymphoma as a rare cause of intussusception: a report of 2 cases. *Ann Diagn Pathol.* 2009;13(6):398-401.
- 3) Weisenberg DD, Armitage JO. Mantle cell lymphoma- an entity comes of age. *Blood.* 1996;87(11):4483-4494
- 4) Li JY, Gaillard F, Moreau A, et al. Detection of translocation t(11;14)(q13;q32) in mantle cell lymphoma by fluorescence in situ hybridization. *Am J Pathol.* 1999;154(5):1449-1452.
- 5) Xie CG, Xu XM, Wei SM. Multiple Lymphomatous Polyposis of the Intestine with Ileocecal Intussusception Due to Mantle Cell Lymphoma: A Case Report of a 34-Year-Old Man. *Am J Case Rep.* 2018;19:262-266.
- 6) Kella VK, Constantine R, Parikh NS, et al. Mantle cell lymphoma of the gastrointestinal tract presenting with multiple intussusceptions- case report and review of literature. *World J Surg Oncol.* 2009;7:60.
- 7) Matsueda K, Toyokawa T, Sakata M, Fujita I, Horii J. Mantle Cell Lymphoma with a Single Protruding Lesion as a cause of Intussusception. *Intern Med.* 2018;57(12):1751-1755.
- 8) Aljarad Z, Nasser M, Ghazal A, Alkhaled M, Obeed B, Shaghaleh MM, Alhussein MWH. A Rare Case Report of Duodenal Marginal Zone B-cell Lymphoma Related to Immunoproliferative Small Intestinal Disease and Associated Lymphoma (IPSID). *J. Adv. Med. Med. Res.* [Internet]. 2017 Mar. 30 [cited 2024 May 28];20(8):1-4. Available from: <https://www.journaljammr.com/index.php/JAMMR/article/view/3183>
- 9) Khatti S, Memon RA, Memon AS, Hashmi F, Kumar S, Khatoon S, Memon FH, Pathan AH. Frequency and Clinical Presentation of Colorectal Carcinoma among Patients with Lower Gastrointestinal Symptoms. *J. Pharm. Res. Int.* [Internet]. 2021 Jun. 14 [cited 2024 May 28];33(31B):136-42. Available from: <https://journaljpri.com/index.php/JPRI/article/view/2532>
- 10) Sanguedolce F, Zanelli M, Zizzo M, Martino G, Rossi C, Parente P, Ascani S. Clinical, pathological and molecular features of plasmablastic lymphoma arising in the gastrointestinal tract: A review and reappraisal. *Pathology-Research and Practice.* 2020 Jun 1;216(6):152973.