

SURGICAL MANAGEMENT OF ILEOCAECOCOLIC INTUSSUSCEPTION AND INTESTINAL PERFORATION IN A KITTEN

Abstract :

OBJECTIVES

Intussusception is defined as a prolapse or invagination of one portion of the intestinal tract into the lumen of an adjoining segment. Most common sites of intussusception are enterocolic, and ileocolic. Intussusception is more common in kittens less than one year of age, while rare in adults. Vomition, melena, dyschezia, dehydration, abdominal pain and emaciation are common clinical signs. Intussusception along with intestinal perforations is rare planned to be repaired surgically. Our aim is to describe a surgical procedure designed specifically to surgically correct ileocaecocolic intussusception and intestinal perforation in a kitten.

Keywords: Colonopexy, Intussusception, Intestinal perforation, Kitten, Laparotomy.

INTRODUCTION

Intussusception is defined as a prolapse or invagination of one portion of the intestinal tract into the lumen of an adjoining segment. The components of an intussusception include the invaginated intussusceptum, and the enveloping segment intussusceptien (Allenspach, 2010). Most common sites of intussusception are enterocolic, and ileocolic. Intussusception is more common in puppies less than one year of age, while rare in adults. Vomition, melena, dyschezia, dehydration, abdominal pain and emaciation are common clinical signs. Diagnosis is usually based on history, physical examination and use of imaging techniques like plain and contrast radiography and ultrasonography (Paryani, 2013). The present case report describes the successful surgical management of intussusception in a kitten.

METHODS

A two months old kitten was brought to department with history of anorexia, dyschezia and prolapsed mass through rectum since last 3-4 days. Clinical examination revealed dehydration and tachycardia. Rectal temperature and respiratory rate were within the normal range. The mucous membrane was pale. Palpation of abdomen revealed pain. In order to rule out possibility of rectal prolapse blunt end of thermometer was passed between the rectal wall and protruding mass which progressed upto the cranial of pubis suggesting possibility of prolapse of intussusceptum. Complete blood count and serum biochemistry profile was performed. CBC showed anaemia (5.1 g%), PCV (30%) moderate leukocytosis ($20.2 \times 10^3/\mu\text{l}$) and neutrophilia (88.0%). On serum biochemical analysis hypoproteinemia (46 g/L) and hypoalbuminemia (20 g/L) was observed. Ultrasonography revealed multiple hyperechoic and hypoechoic concentric lines in sagittal plane were found which were suggestive of intussusception (Fig. 1). On the basis of above findings, it was confirmed to be a case of intestinal intussusceptions and it was decided to manage surgically.

RESULTS

The ventral midline was prepared aseptically for surgery. Animal was premedicated with atropine sulphate @ 0.04 mg/kg body weight subcutaneously and butorphanol @ 0.2 mg/kg was given intramuscularly as preemptive analgesia. Anaesthesia was achieved by administration of mixture of Xylazine @ 0.5 mg/kg and Ketamine @ 20 mg/kg intramuscularly and maintained with isoflurane (Fig. 2). On laparotomy, perforations were found on dorsal wall of ileum at three places (Fig. 3). The perforated sites were washed with NSS 0.9% solution and sutured with inverted pattern with 3-0 polydioxanone. The intussuscepted mass was washed with NSS 0.9% and retracted back into the abdominal cavity which confirmed intussusception at ileo-colic junction (Fig. 4). Manual reduction of the intussusceptions was attempted by gentle milking of intussusceptum from intussusciens. Efforts were made to reduce the intussusceptum by pushing it out rather than using traction only on the intussusceptum (push and pull method). After reduction patency of tract and vascularisation was confirmed near to normal. To prevent reoccurrence, colon was fixed to right

abdominal wall (colonopexy). Linea alba was closed in simple continuous suture pattern using vicryl no.1-0 suture material. Subcutaneous tissue was closed in routine manner and skin was sutured in simple interrupted pattern using nylon. Post-operatively, Cefpodoxime @ 5 mg/kg b.wt. orally every 12 hours and Meloxicam @0.3 mg/kg b.wt. was given orally every 24 hours for 1 week. Animal was given only intravenous fluids for three days followed by liquid diet. Skin sutures were removed on 12th post-operative day. Animal made an uneventful recovery.

DISCUSSION

Intussusception is the invagination of one portion of the intestine into the other portion. Retrospective studies have indicated that puppies and kittens have a much higher incidence of intussusception than adult animals (Lewis and Ellison, 1987; Han *et al.*, 2008). Intussusceptions occurs in any age or species but more than 80 percent of this occurs in less than one year old animals (Dixon *et al.*, 2004; Jawre *et al.*, 2009). Wilson and Burt (1974) reported 37 out of 45 animals were of less than one year of age whereas Weaver (1977) reported 19 of 26 dogs in were less than six months old. The age of the kitten in the present study was two months. The most common clinical signs in present study included vomiting, dehydration, depression, anorexia and melana and sausage shaped mass prolapsed through anus (Chaudhary *et al.*, 2016). Intussusception have been reported at numerous locations (Applewhite *et al.*, 2001) but most commonly reported at ileocaecocolic junction (Applewhite *et al.*, 2002). Prolapse of ileocolic intussusceptions through anus has been reported in cats (Demetriou and Welsh, 1999). Similar findings were also noticed in the present case. Ultrasonography was used to confirm intussusception and rectal prolapse was easily diagnosed by inserting a blunt probe between mass and anal sphincter (Chaudhary *et al.*, 2016). The surgical management of intestinal intussusceptions involves simple reduction, manual reduction with plication, intestinal resection and anastomosis, and intestinal resection and anastomosis with plication depending upon the condition of the intussuscepted part (Ellison,1986; Purohit *et al.*, 2016; Sodhi *et al.*, 2019). Surgical correction is the primary treatment and colopexy is highly

recommended due to the low recurrence rate (Marderstein and Delaney, 2007). In present case, the surgical correction with entropexy was performed immediately after the diagnosis of intussusceptions. Thus, on the basis of above findings, it is concluded that the manual reduction along with entropexy is as reliable method to correct intussusceptions and prevent its further reoccurrence.

CONCLUSION

Surgical correction with entropexy was performed immediately after the diagnosis of intussusceptions. Thus, on the basis of above findings, it is concluded that the manual reduction along with entropexy is as reliable method to correct intussusceptions and prevent its further reoccurrence.

REFERENCES

- Allenspach, K. (2010). Diseases of the large intestine. In: Ettinger S.J. and Feldman E.C. (eds.), Textbook of Veterinary Internal Medicine. 7th Edn. Saunders Elsevier. St. Louis, Missouri. pp. 1573–1608.
- Applewhite, A.A., Cornell, K.K. and Selcer, B.A. (2001). Pylorogastric intussusceptions in the dog: A case report and literature review. *J Am Anim Hosp Assoc.*, 37. 238-43.
- Applewhite, A.A., Cornell, K.K., Selcer, B.A. (2002). Diagnosis and treatment of intussusceptions in dogs. *Compendium on continuing education for the practising Veterinarian - North American.* 24(2): 110-27.
- Chaudhary, R.N., Sharma, S., Tiwari, D.K., Pandey, A.K. and Ram Mehar (2015). Intussusception in puppies mimicking rectal prolapse: A review of six cases. *Intas Polivet*, 17 (1): 177-179.
- Demetriou J.L. and Welsh E.M. (1999). Rectal prolapse of an ileocaecal neoplasm associated with intussusception in a cat. *J Feline Med Surg*, 1: 253-56.
- Dixon, B. C. (2004). In: Tilley, L.P. and Smith Jr., F.W.K (ed.) The 5-minute Veterinary Consult Canine and Feline, 3rd Edn, Lippincott Williams and Wilkins. pp 721-722.

- Ellison, G.W. (1986). Nontraumatic surgical emergencies of the abdomen. In: Bright, R., ed. *Contemporary Issues in Small Animal Practice*. Vol. 2. New York: Churchill Livingstone. pp 127-173.
- Han, T.S., Kim, J.H., Cho, K., Park, J., Kim, G. and Choi, S.H. (2008). Double intussusceptions in a Shih-Tzu puppy. *J Biomed Res*, 9: 55-58.
- Jawre, S., Shahi, A., Chandrapuria, V.P. and Tiwari, D.K. (2008). Laparoscopic diagnosis and surgical management of ileo-caecal intussusception in Bull Mastiff bitch. *Intas Polivet*, 9(2): 153-155.
- Lewis, D.D. and Ellison, G.W. (1987). Intussusception in dogs and cats: A Review of 36 cases. *Can Vet J*, 33: 660-64.
- Marderstein, E.L. and Delaney, C.P. (2007). Surgical management of rectal prolapse. *Nat Clin Pract Gastroenterol Hepatol.*, 4: 552-561.
- Paryani, M.R. (2013) Duodenogastric intussusceptions in a mixed breed dog. *Annals of Bio. Res.*, 4(6):286-289.
- Purohit, S., Chaudhary, S.R., Mistry, J.N., Patel, P.B., Siddiquee, G.M. and Patel, J.S. (2016). Surgical management of intussusceptions in cattle: A clinical study of five cases. *Ruminant Sci.* 5: 107-12.
- Sodhi, H.S., Mohindroo, J., Sharma, A.K., Mahajan, S.K. and Verma, P. (2019). Clinical manifestations of gastrointestinal tract disorders in bovine. *Ruminant Sci.* 8: 257-62.
- Weaver, A.D. (1977). Canine intestinal intussusception. *Vet. Rec.* 100: 524-27.
- Wilson, G.P. and Burt, J.K. (1974). Intussusception in the dog and cat: A review of 45 cases. *J. Am. Vet. Med. Assoc.* 164: 515-18.

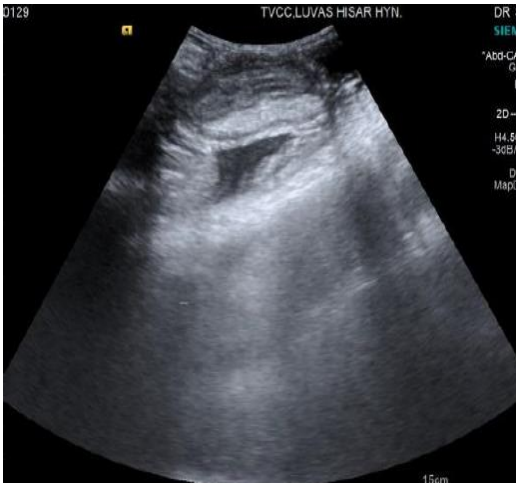


Fig. 1: Ultrasonogram showing multiple hyperechoic and hypoechoic concentric lines in longitudinal section

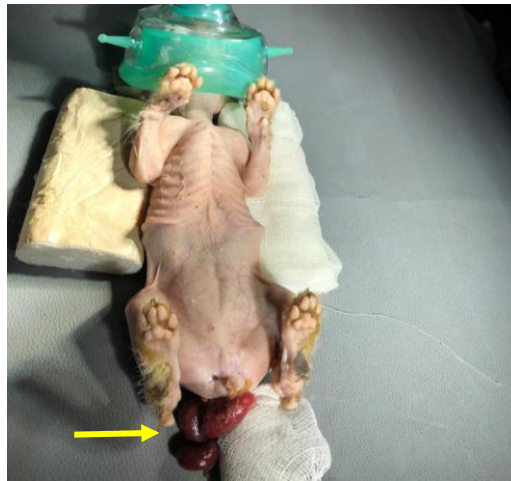

Fig. 2: Positioning of the kitten with prolapsed mass (arrow) in dorsal recumbancy.

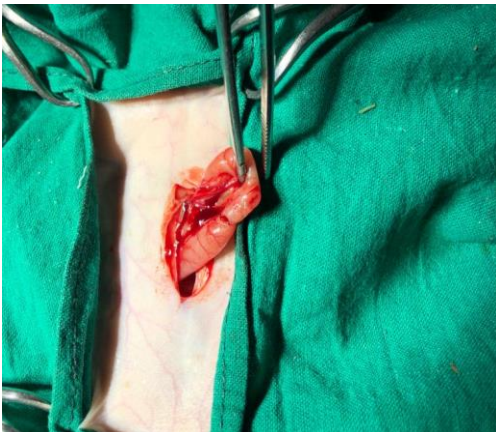

Fig. 3: Perforation on dorsal wall of ileum

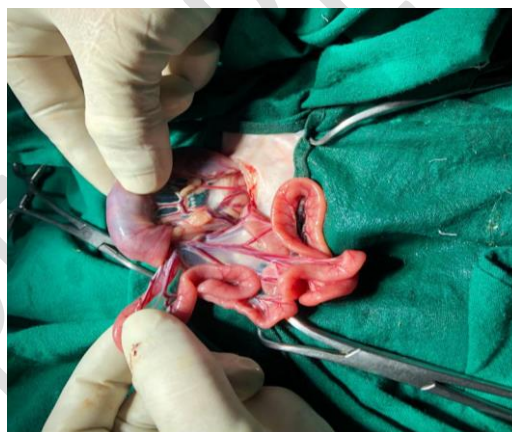


Fig. 4: Intussusception at ileocaecocolic junction.