

Original Research Article

Usefulness of Colonoscopy in Paediatric Lower Gastrointestinal Disorders

ABSTRACT:

Aim: To observe the indications, findings and effectiveness of colonoscopy in paediatric patients having gastrointestinal symptoms.

Study design: Retrospective study

Place and duration of study: Department of Paediatric Gastroenterology, Bangabandhu Sheikh Mujib Medical University, Dhaka, Bangladesh, between January, 2022 and December, 2022.

Methodology: We included 105 patients, aged ≤ 16 years, who had their first colonoscopy and their demographic data, indications and extent of colonoscopy, abnormal colonoscopy findings, definite diagnosis and complications following the procedure were recorded.

Results: Out of 105 patients, common indication for colonoscopy was lower GI bleeding (64.76%) followed by chronic diarrhea (15.23%) and chronic abdominal pain (10.48%). Colo-rectal polyp was most frequently diagnosed (34.28%) followed by IBD (17.14%) and intestinal tuberculosis (12.38%). The diagnostic yield of colonoscopy for chronic diarrhoea was 87.5 %, hematochezia 82.36 %, and chronic abdominal pain 72.72 %. Ileal intubation was done in 26.67% cases. Only one patient developed procedure related complication.

Conclusion: Paediatric colonoscopy is useful diagnostic tool for evaluating hematochezia, chronic diarrhoea or chronic abdominal pain in children.

Keywords: colonoscopy, children, diagnostic yield.

1. INTRODUCTION:

Paediatric colonoscopy is used as a routine diagnostic and therapeutic tool for various lower gastrointestinal disorders in children.¹ Most paediatric gastroenterologists are now skilled to perform total colonoscopy in all paediatric age group. Major challenges for colonoscopy in children are hazards of sedation, difficult bowel preparation, technical difficulties and poor compliance of patients.² As there is slightly higher risk of complications than adult patients, it is performed less frequently in paediatric patients. So careful selection of patient for colonoscopy is utmost important to improve diagnostic yield and minimize the complications. The most prevalent indications of colonoscopy in children are lower gastrointestinal bleeding, abdominal pain and chronic diarrhoea.³ Therapeutic colonoscopy is most frequently done for polypectomy and bleeding management.^{4,5} Colorectal polyp and inflammatory bowel disease are frequently diagnosed in children among lower gastrointestinal disorders. Recent studies have suggested that the incidence of inflammatory bowel disease (IBD) is increasing over last few years in Asian population.⁵ About 20-30% of IBD patients are diagnosed in childhood.⁵ Colonoscopy can serve as a major tool for early detection and treatment of colorectal polyp and IBD. The European Society for Paediatric Gastroenterology Hepatology and Nutrition (ESPGHAN) and the British Society of Paediatric Gastroenterology, Hepatology and Nutrition (BSPGHAN) have published their guidelines about the indications for endoscopy to improve the selectivity of patients.^{4,6}

In our country, paediatric gastroenterology is an emerging subject, so colonoscopy is done in a limited number of centres by paediatric gastroenterologists.

We have conducted the present study to observe the indications, findings and effectiveness of colonoscopy in paediatric patients having gastrointestinal symptoms.

2. MATERIALS AND METHODS:

This retrospective study was done in Department of Pediatric Gastroenterology and Nutrition, Bangabandhu Sheikh Mujib Medical University, Dhaka, Bangladesh, from January 2022 to December 2022.

All patients aged ≤ 16 years, who had undergone their first colonoscopy for different indications during this one-year period were enrolled in this study. Colonoscopy were performed by experienced pediatric gastroenterologist with a Pentax EC 3490 LK 3.8 pediatric colonoscope.

Before the procedure, complete blood count, coagulation profile and HBsAg status were checked in every patient. At the same time, bowel preparation was given and informed written consent was taken from the guardians after briefing about the detail procedure and possible complications.

Bowel preparation was started for each patient from the day before the procedure with low residual diet and polyethylene glycol (PEG) and phosphate enema for children ≥ 6 year of age and with sodium picosulfate if child is < 6 year. Patients were sedated by intravenous pethidine and oral midazolam.

Colonoscopy was done in left lateral position and position was changed to right lateral and supine position when the gastroenterologist faced difficulty in advancing the colonoscope. Whenever a polyp was found in rectum or colon, it was removed by using polypectomy snare and sent for histopathological examination. All vital signs and oxygen saturation were monitored during colonoscopy.

For each patient, demographic data, indications of colonoscopy, extent of colonoscopy, abnormal colonoscopy findings, definite diagnosis and complications following the procedure were recorded and analyzed. Data was collected from hospital record book.

Statistical analysis was done using SPSS (version 25). Data was expressed as mean \pm standard deviation, frequency and percentages.

3. RESULTS AND DISCUSSION:

PATIENT CHARACTERISTICS:

A total of 130 children had undergone colonoscopy in 2022, among them 25 patients were excluded due to incomplete data and 105 patients were enrolled in this study. The most common age group was found 5-10 years and the mean age was $8.2(\pm 3.5)$ years with 64 (61%) male and 41 (39%) female. Some other studies also found that this age group had the highest rate of colonoscopy.^{7,8,9} Wu et al found mean age was 7.7 ± 5.4 years in their study which is similar to our study.⁵

Of 105 colonoscopies, cecum was reached in 45.71% cases, ileoscopy was performed in 26.67% cases, which is lower than some other studies. This may be due to lack of proper anesthetic facilities, inadequate bowel preparation, technical difficulties, severe colitis and also in some cases pathological lesions were identified in other parts of colon. Recent study reported that now a days terminal ileum can be approached in 65-83% cases.¹⁰ Morita et al reported that in their facility ileoscopy was possible in 98.2% cases.¹ As IBD cases are increasing over last few years and terminal ileum is involved in 85% cases in Crohn's disease, so in any suspected case of IBD, ileal intubation should be done.² Different institutions follow different protocols for anesthesia during colonoscopy. As the anesthetic facilities are limited in our study place, so patients were sedated by combination of midazolam and pethidine. This protocol is also practiced in China.² The demographics are detailed in Table 1.

Table 1: Demographics of patients who had colonoscopy (n = 105):

Age group	
< 5 year	15 (14.3%)
5-10 year	60 (57.1%)
>10 year	30 (28.6%)
Sex	
Male	64 (61%)
Female	41 (39%)
Extent of colonoscopy	
-ileum	28 (26.67%)
-cecum	48 (45.71%)
- colon	22 (20.95%)
-rectum	07 (6.67%)

INDICATIONS:

The most common indication of colonoscopy was lower GI bleeding (64.76%), followed by chronic diarrhoea (15.23%). Other indications were chronic abdominal pain (10.48%), occult GI bleeding (5.1%) and unexplained weight loss (3.80%). (Table 2) This study finding is similar to some other studies which also reported that per rectal bleeding is the main cause of colonoscopy in children.^{3, 11,12,13,14} European Society for Paediatric Gastroenterology Hepatology and Nutrition (ESPGHAN) and European Society of Gastrointestinal Endoscopy (ESGE) also mentioned in clinical guidelines about paediatric gastrointestinal endoscopy that hematochezia is the main indication of colonoscopy in children.⁴

FINDINGS OF COLONOSCOPY:

Colonic polyp (33.3%) was the most frequent finding observed during colonoscopy. Linear ulcer with erythematous mucosa was found in 21.9% of cases, diffuse nonspecific ulcer in 9.5% cases. Deformed IC valve with or without distorted cecum was found in 10.5% cases who later diagnosed as intestinal TB. The less common finding was anal fissure (1.9%). Normal colonic mucosa was found in 22.9% of cases.(Fig 1) In another study conducted among 332 Bangladeshi children, colorectal polyp was found in 41.3% of cases followed by non-specific colitis (13.55%), IBD (6%), SRUS (1.2%), ileocecal tuberculosis (1.5%).⁷ According to some study reports, colonic polyp occurs more frequently in asian population than in western population. ^{5,8}

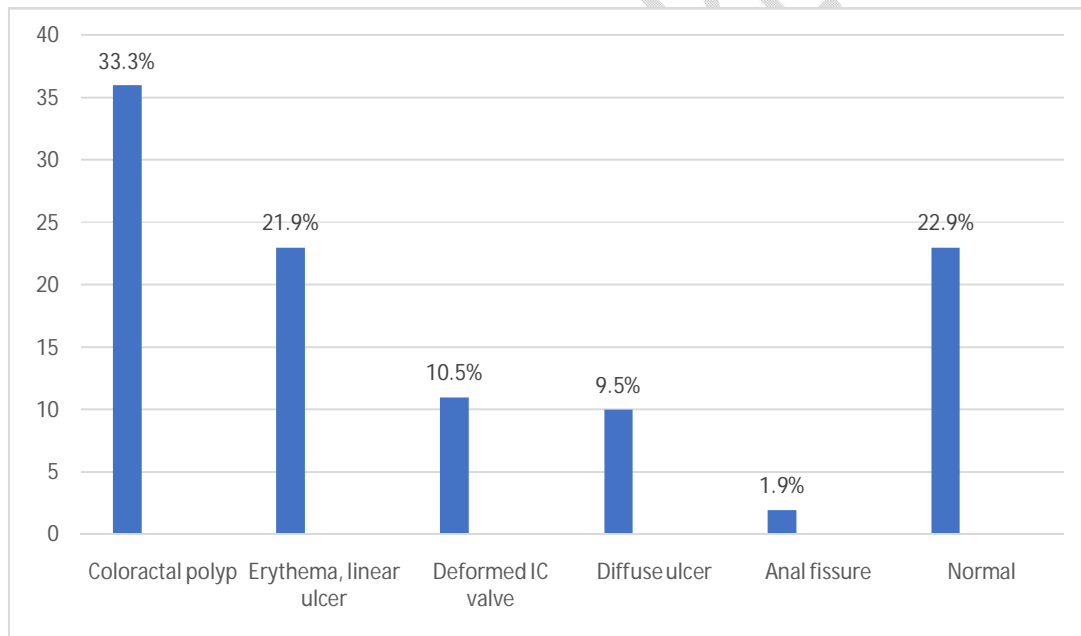


Figure 1: Frequency of colonoscopy findings

Table 2: Indications and diagnostic yield of colonoscopy (n =105):

Indications	Patient no (%)	Diagnostic yield	Patient no (%)
Lowergastrointestinal bleeding	68 (64.76%)	Colorectal polyp	36 (52.94%)
		SRUS	07 (10.3%)
		IBD	07 (10.3%)
		Anal fissure	02 (2.94%)
		Obscure GI bleeding	04 (5.88%)
		Negative	12 (17.64%)
Chronic diarrhoea	16 (15.23%)	Intestinal TB	07(43.75%)
		IBD	05 (31.25%)
		Pseudomembranous colitis	02 (12.5%)
		Negative	02 (12.5%)
Chronic abdominal pain	11 (10.48%)	Intestinal TB	05(45.45 %)
		IBD	03(27.27%)
		Negative	03(27.27 %)
Occult bleeding	06 (5.71%)	IBD	02(33.33%)
		Negative	04(66.66%)
Weight loss	04 (3.80%)	Intestinal TB	01 (25%)
		IBD	01 (25%)
		Negative	02 (25%)

FINAL DIAGNOSIS AND DIAGNOSTIC YIELD:

The most common diagnosis was colorectal polyp (34.28%) followed by IBD (17.14%), intestinal TB (12.38%), SRUS (6.7%), obscure GI bleeding (3.8%), anal fissure (1.9%). Conclusive diagnosis could not be reached in 23 patients (21.90%). (Table 3)

The diagnostic yield of lower GI bleeding was 82.36%, chronic diarrhoea 87.5 %, chronic abdominal pain 72.72 %, weight loss 50% and occult bleeding 33.33 %.

Among patients with LGIB, colorectal polyp (52.94%) was the common aetiology. Juvenile polyp was most commonly identified polyp and most of them (98.3%) were located in rectum or sigmoid colon. SRUS is an unrecognized cause of lower GI bleeding which was found in 10.3% of children which was later confirmed by histopathological examination. No source of bleeding was identified during upper and lower GI endoscopy in 5.88% of children and diagnosed as mid GI bleeding.

Intestinal TB was the common cause found in children presented with chronic diarrhoea and abdominal pain. In this current study, seven patients with chronic diarrhoea had blood mixed stool, among them 5 patients were diagnosed as ulcerative colitis and 2 patients as pseudomembranous colitis who responded completely to oral Vancomycin.

The incidence of IBD is increasing day by day in South Asian paediatric population.^{15,16} This may be due the impact of western culture on dietary habit and life style of Asian people. In our study, IBD was diagnosed in 17.1 % of patients whose main clinical presentation was either hematochezia, chronic diarrhoea, chronic abdominal pain or weight loss. In this study, 12 cases were ulcerative colitis (UC) and 6 cases were diagnosed as crohn's disease (CD).

In our study, 77.1 % of the patients had positive macroscopic features which is comparable to another study conducted in China which revealed that 70.5% of their patients had positive finding during colonoscopy.² In another study conducted by Mike et al. in UK, the diagnostic yield of colonoscopy was found 40%.¹⁷

Table 3:Disease distribution of diagnostic colonoscopies (n = 105):

Diagnosis	Patient no. (%)
Colo-rectal polyp	36 (34.28%)
IBD	18 (17.14%)
Intestinal TB	13 (12.38%)
SRUS	07 (6.66%)
Mid GI bleeding	04 (3.8%)
Pseudomembranous colitis	02 (1.9%)
Anal fissure	02 (1.9%)
Normal	23 (21.9%)

IBD: Inflammatory bowel disease, SRUS: Solitary rectal ulcer syndrome

COMPLICATION:

In this study period, one of our patients experienced intestinal perforation during colonoscopy who later required surgical intervention. The immediate complication of paediatric colonoscopy is 1.1%.⁹ Colonic perforation is one of the serious complications of colonoscopy which occurs in 0.01% to 0.3% of cases.¹⁸ However, the rate of complication was found higher in another study conducted in Japan.¹⁹

Our study had some limitations. As the data were collected from hospital record book, some data were incomplete. This one was a single centre retrospective study, final conclusion cannot be drawn from this study.

4. CONCLUSION:

Colonoscopy is an useful diagnostic tool for evaluating lower gastrointestinal disorders in paediatric age group. It is a safe procedure which can be used both as diagnostic and therapeutic purposes.

CONSENT:

As per international standards, parental written consent has been collected and preserved by the author(s).

ETHICAL APPROVAL:

As per international standards or university standards written ethical approval has been collected and preserved by the author(s).

References:

1. Morita M, Takedatsu H, Yoshioka S, Mitsuyama K, Tsuruta K, Kuwaki K, et al. Utility of Diagnostic Colonoscopy in Pediatric Intestinal Disease. *J. Clin.Med.* 2022;11(19):5747. <https://doi.org/10.3390/jcm11195747>.
2. Lei P, Gu F, Hong L, Sun Y, Li M, Wang H, et al. Pediatric Colonoscopy in South China: A 12-Year Experience in a Tertiary Center. *PLOS ONE.* 2014; 9(4): e95933. doi:10.1371/journal.pone.0095933
3. Nambu R, Hagiwara SI, Kakuta F, Hara T, Shimizu H, Abukawa D, et al. Current role of colonoscopy in infants and young children: a multicenter study. *BMC Gastroenterology.* 2019;19(1):149. <https://doi.org/10.1186/s12876-019-1060-7>.
4. Thomson M, Tringali A, Dumonceau JM, Tavares M, TabbersMM, Furlano R, et al. Paediatric Gastrointestinal Endoscopy: European Society for Paediatric Gastroenterology Hepatology and Nutrition and European Society of Gastrointestinal Endoscopy Guidelines. *JPediatr GastroenterolNutr.* 2017;64: 133–153. <https://doi.org/10.1097/MPG.0000000000001408>.
5. Wu CT, Chen CA, Yang YJ. Characteristics and Diagnostic Yield of Pediatric Colonoscopy in Taiwan. *PediatrNeonatal.* 2015;56:334-38. <http://dx.doi.org/10.1016/j.pedneo.2015.01.005>.
6. Tringali A, Thomson M, Dumonceau JM, Tavares M, Tabbers MM, Furlano R, et al. Pediatric gastrointestinal endoscopy: European Society of Gastrointestinal Endoscopy (ESGE) and European Society for Paediatric Gastroenterology Hepatology and Nutrition (ESPGHAN) guideline executive summary. *Endoscopy.* 2017; 49(01):83–91. doi: 10.1055/s-0042-111002.
7. Begum F, Nahid KL, Islam F, Majumder W, Rukunuzzaman MD, Karim ASMB. Paediatric Colonoscopy: Experience from Pediatric Gastroenterology and Nutrition Department, BSMMU. *Banglad. J.Child Health.* 2021;45:25-28. <https://doi.org/10.3329/bjch.v45i1.55470>.
8. Sharma B, Sharma R, Bodh V, Sharma S, Sood A, Sharma R . Chronic lower gastrointestinal bleeding: Etiological profile and role of colonoscopy among children from sub-Himalayan ranges of North India. *J.Dig.Endosc.* 2018; 9:109-13. DOI:10.4103/jde.JDE_33_18.
9. Kawada PS, O'Loughlin EV, Stormon MO, Dutt S, Lee CH, Gaskin KJ. Are we overdoing pediatric lower gastrointestinal endoscopy? *JPediatr GastroenterolNutr.*2017;64:898-902. doi: 10.1097/MPG.0000000000001192.
- 10.1097/MPG.0000000000001192.

10. Batres LA, Maller ES, Ruchelli E, Mahboubi S, Baldassano RN. Terminal ileum intubation in pediatric colonoscopy and diagnostic value of conventional small bowel contrast radiography in pediatric inflammatory bowel disease. *J Pediatr Gastroenterol Nutr.* 2002;35:320-3.doi: 10.1097/00005176-200209000-00015
11. Altamimi E, Odeh Y, A-quraan T, Mohamed E, Rawabdeh N. Diagnostic and therapeutic outcomes of pediatric colonoscopies in Jordanian children. *J PediatrNeonat IndividualMed.* 2022; 11:e110211. <https://doi.org/10.7363/110211>.
12. Yoshioka S, Takedatsu H, Fukunaga S, Kuwaki K, Yamasaki H, Yamauchi R. Study to determine guidelines for pediatric colonoscopy. *World JGastroenterol.* 2017; 23:5773-79.doi: 10.3748/wjg.v23.i31.5773.
13. Mahmud S, Parvez M, Baidya M, Rashid R, Tasneem F, Hasan AR. Spectrum of Colonoscopy in Children: A Tertiary Centre Experience from Bangladesh. *DS (Child) HJ.*2022;38(1):8-16. <https://doi.org/10.3329/dshj.v38i1.66996>.
14. Park JH. Role of colonoscopy in the diagnosis and treatment of pediatric lower gastrointestinal disorders. *KoreanJPediatr.* 2010;53(9):824-9. DOI: 10.3345/kjp.2010.53.9.824.
15. Zeng Z, Zhu Z, Yang Y, Ruan W, Peng X. Incidence and clinical characteristics of inflammatory bowel disease in a developed region of Guangdong Province, China: a prospective population-based study. *JGastroenHepatol.*2013; 28: 1148–1153. <https://doi.org/10.1111/jgh.12164>.
16. Ng SC, Tang W, Ching JY, Wong M, Chow CM. Incidence and Phenotype of Inflammatory Bowel Disease Based on Results From the Asia- Pacific Crohn's and Colitis Epidemiology Study. *Gastroenterology.*2013;145: 158–165.doi: 10.1053/j.gastro.2013.04.007.
17. Thomson M, Sharma S. Diagnostic yield of upper and lower gastrointestinal endoscopies in children in a tertiary centre. *J Pediatr GastroenterolNutr.*2017; 64(6):903–906.DOI: 10.1097/MPG.0000000000001582.
18. Park JH. Pediatric Colonoscopy: The Changing Patterns and Single Institutional Experience Over a Decade. *Clin Endosc.* 2018 ;51(2):137-141. doi: 10.5946/ce.2018.051.
19. Kudo T, Abukawa D, Nakayama Y, Segawa O, Uchida K, Jimbo K, et al. Nationwide survey of pediatric gastrointestinal endoscopy in Japan. *J Gastroen Hepatol.* 2021; 36(6):1545–1549. DOI: 10.1111/jgh.15297.

UNDER PEER REVIEW