

Case report

Bilateral Adrenal Hemorrhage in a Patient Anticoagulated with Apixaban for Antiphospholipid syndrome (APS): a rare case report

ABSTRACT

Context:

Adrenal hemorrhage is a recognized yet rare complication associated with antiphospholipid syndrome (APS), an autoimmune disorder characterized by the presence of antiphospholipid antibodies that increase the risk of thrombosis. The incidence of adrenal hemorrhage in patients with APS has a diagnostic yield of approximately one-third, indicating that it may often go unrecognized in clinical practice. Traditionally, the management of APS has relied on anti-vitamin K therapy, such as warfarin. However, the advent of direct oral anticoagulants (DOACs) has prompted discussions about their use as an alternative. Recent clinical guidelines, however, strongly advise against the use of DOACs in patients with APS due to concerns over their safety and efficacy in preventing thromboembolic events.

Case Presentation:

This case study describes a 53-year-old woman with a history of venous thromboembolism who was treated with apixaban, a direct oral anticoagulant. She presented with acute abdominal pain and symptoms suggestive of adrenal insufficiency. Initial evaluations revealed significant changes in her clinical condition, leading to further diagnostic imaging. A CT scan demonstrated bilateral adrenal hemorrhage, which was a surprising finding given her anticoagulation therapy.

Subsequent laboratory tests indicated a positive triple antibody profile, confirming a diagnosis of primary antiphospholipid syndrome. This case is particularly noteworthy as there have been limited documented instances of adrenal hemorrhage in patients receiving chronic anticoagulation with apixaban. The presentation of bilateral adrenal hemorrhage in the context of APS adds a crucial dimension to the understanding of the disease and its management.

Conclusion:

This case highlights the potential for serious complications, such as adrenal hemorrhage, in patients with antiphospholipid syndrome, particularly those treated with direct oral anticoagulants. It underscores the necessity for clinicians to remain vigilant for such rare yet significant events in the management of APS. Additionally, this case raises important questions regarding the appropriateness of DOACs in this patient population, especially given the latest recommendations against their use. Increased awareness and further investigation into the implications of anticoagulation strategies in APS patients are warranted to improve patient outcomes and safety.

Keywords: Apixaban, Antiphospholipid syndrome (APS), Bilateral Adrenal Hemorrhage, case report.

1. INTRODUCTION

Antiphospholipid syndrome (APS) is a rare but serious condition.

The treatment of APS is based on the administration of anticoagulant medication, specifically anti-vitamin K (AVK), which has the ability to prevent the formation of blood clots.

The advent of direct oral anticoagulants (DOACs) in the fields of cardiology and vascular medicine has prompted questions regarding their efficacy in preventing thrombotic events in APS.

In light of the available literature, the latest French recommendations and the NASM advise against the use of DOACs in patients with APS.

Comment [AM1]: Add references, and needs more explanation about APS disease and how adrenal hemorrhages take place

2. CASE PRESENTATION

The patient is a 53-year-old woman who is presenting with deep vein thrombosis of the left popliteal vein in relation to apixaban AOD (5 mg, administered in the morning and evening). Following a one-month course of apixaban, the patient was admitted to the emergency department of Casablanca with respiratory distress and vomiting.

Upon admission, the patient was observed to be in a confused state. Her vital signs were notable for hypotension (99/70 mmHg), tachycardia (100 bpm), tachypnoea (24 bpm), and 90% free air saturation. Her Glasgow Coma Scale score was 14/15, and she exhibited no neurological deficits. Her temperature was 37.6°C, and her capillary blood glucose level was 0.29 g/L.

Following the administration of oxygen therapy via a high-concentration mask, correction of the hypoglycaemia and conditioning, the clinical examination revealed no additional heart murmurs and pleuropulmonary auscultation was normal.

A cardiac evaluation was conducted, which revealed no abnormalities in the electrocardiogram (Figure 1).

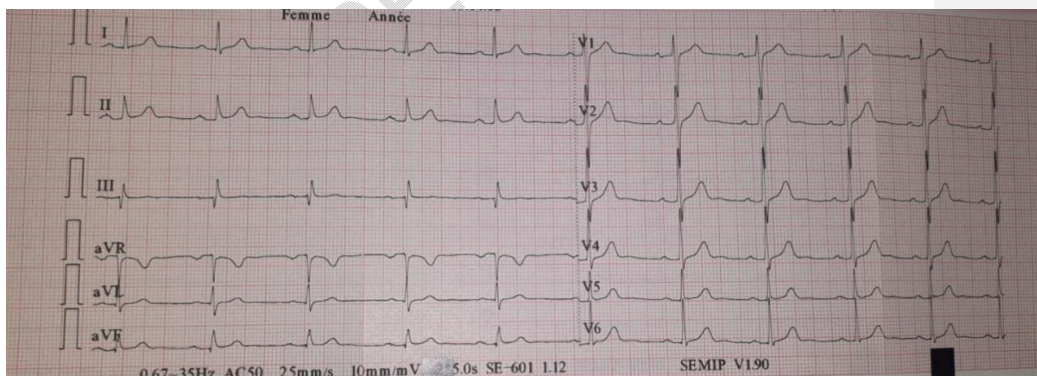


Figure 1: The electrocardiogram (ECG) displayed sinus rhythm at a heart rate of 68 beats per minute (bpm), with no evidence of repolarisation abnormalities.

The trans-thoracic echocardiogram (TTE) yielded borderline normal results, with a left ventricular ejection fraction (LVEF) of 60% (Figure 2).

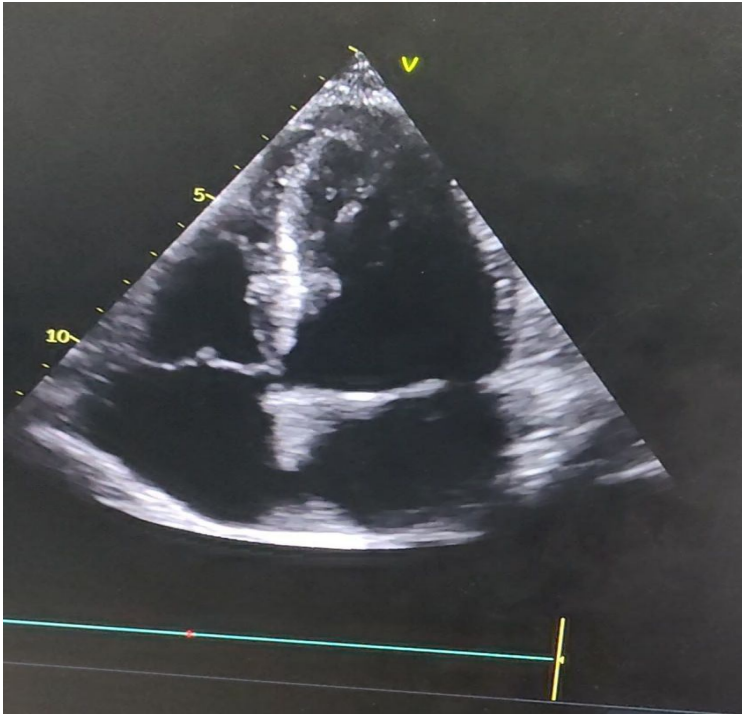


Figure 2: TTE revealed good biventricular function with an LVEF of 60%.

Biological assessment revealed the presence of hyponatremia at 129 mmol/L, hyperkalaemia at 5.9 mmol/L, and hypoglycaemia.

In light of the clinical context, an abdominal CT scan was performed, which revealed bilateral haemorrhagic necrosis of both adrenal glands.

Management measures were initiated, comprising the administration of 100 mg of hydrocortisone hemisuccinate in conjunction with HDR.

The patient's clinical signs fully resolved, and her level of consciousness improved.

Comment [AM2]: Mention its value

Comment [AM3]: Explain this synonym

Comment [AM4]: More details about the timelines between admission, diagnosis and treatment are needed

3. DISCUSSION

Adrenal haemorrhage represents a rare and potentially fatal complication of antiphospholipid syndrome (APS).

The underlying mechanism of adrenal haemorrhage is thought to be thrombosis resulting from the presence of underlying coagulopathy [1].

The destruction of the adrenal cortex resulting from thrombosis and/or haemorrhage can occur rapidly; however, the extent to which it can affect adrenal function can vary.

The utilisation of a novel generation of direct-acting oral anticoagulants (DAAs) has largely superseded the use of warfarin in the management of hypercoagulability. DAAs possess predictable anticoagulant effects and do not necessitate dose monitoring, in contrast to warfarin. The convenience of DAAs has resulted in an increase in their utilisation. However, to date, there are no sufficiently robust randomised controlled trials that have established the safety of DAAs [1-8].

The following factors have been identified as potential risk factors for HA: anticoagulant therapy, recent surgery, tumour metastases, corticotropin stimulation, adrenal tumour, physiological stress (trauma and burns), severe sepsis and APLS [2].

The selection of an anticoagulant for the treatment of antiphospholipid antibody syndrome (APS) may be pertinent to the risk of developing adrenal haemorrhage. However, the number of clinical cases available for analysis is limited, and therefore, it can only be hypothesised that warfarin may confer a lower risk of adrenal haemorrhage in comparison to other anticoagulant drugs (AODs).

Furthermore, it has been documented that patients with antiphospholipid antibody syndrome have experienced severe complications following a transition from warfarin to AOD therapy [3].

Adrenal haemorrhage has also been observed in patients without antiphospholipid antibody syndrome who were undergoing AOD therapy [4 - 5].

Currently, the evidence for secondary prevention of thrombotic events in patients with APLS using AODs is limited [6].

The European League Against Rheumatism (EULAR) has issued a recommendation against the use of AODs in APLS [7].

Until further evidence on the safety of AODs in APLS is available, warfarin should remain the reference anticoagulant [8].

4. CONCLUSION

APAS is a rare disease for which treatment is based on a consensus of experts.

The growing utilisation of AODs in a multitude of ailments gives rise to the question of their role in APS treatment. The available evidence suggests an increased risk of thrombosis in patients with high-risk APS, particularly in cases of triple positivity for antiphospholipid antibodies.

This has been demonstrated for rivaroxaban and a study is underway for apixaban (excluding arterial APS). Our case suggests that apixaban is ineffective in the treatment of high-risk APS, confirming the validity of recent recommendations.

Finally, this observation serves as a reminder that bilateral haemorrhagic necrosis of the adrenal glands is a serious complication of APS, which should always be investigated in the presence of abdominal pain with hypotension, in order to initiate specific treatment.

Comment [AM5]: Move to discussion

REFERENCES

1. Espinosa G., Santos E., Cervera R., Piette J. C., de la Red G., Gil V., Font J., Couch R., Ingelmo M., and Asherson R. A., Adrenal involvement in the antiphospholipid syndrome: clinical and immunologic characteristics of 86 patients, *Medicine (Baltimore)*. (2003) 82, no. 2, 106–118, <https://doi.org/10.1097/00005792-200303000-00005>, 2-s2.0-0037340571.
2. Di Serafino M., Severino R., Coppola V., Gioioso M., Rocca R., Lisanti F., and Scarano E., Nontraumatic adrenal hemorrhage: the adrenal stress, *Radiology Case Reports*. (2017) 12, no. 3, 483–487, <https://doi.org/10.1016/j.radcr.2017.03.020>, 2-s2.0-85017438487.
3. Crowley M. P., Cuadrado M. J., and Hunt B. J., Catastrophic antiphospholipid syndrome on switching from warfarin to rivaroxaban, *Thrombosis Research*. (2017) 153, 37–39, <https://doi.org/10.1016/j.thromres.2017.03.006>, 2-s2.0-85015707473.
4. Alidoost M., Soomro R., Gubeladze A., Morabia A., Holland S., Asif A., and Hossain M. A., Rivaroxaban related bilateral adrenal hemorrhage: a rare complications of direct oral

anticoagulants—a case reports, *Am J Case Rep.* (2019) 20, 1607–1611, <https://doi.org/10.12659/ajcr.917780>.

5. Ly B. A. and Quintero L., Adrenal insufficiency from unilateral adrenal hemorrhage in a patient on rivaroxaban thromboprophylaxis, *AACE Clinical Case Reports.* (2019) 5, no. 1, e70–e72, <https://doi.org/10.4158/accr-2018-0340>.

6. Kakadia B., Suero-Abreu G. A., Daci R., and Then R. K., Would you use novel oral anticoagulants (NOACs) for thromboprophylaxis in patients with an underlying hypercoagulable state? A literature review through a case report, *BMJ Case Reports.* (2020) 13, no. 10, <https://doi.org/10.1136/bcr-2020-237238>, e237238.

7. Tektonidou M. G., Andreoli L., Limper M., Amoura Z., Cervera R., Costedoat-Chalumeau N., Cuadrado M. J., Dorner T., Ferrer-Oliveras R., Hambly K., Khamashta M. A., King J., Marchiori F., Meroni P. L., Mosca M., Pengo V., Raio L., Ruiz-Irastorza G., Shoenfeld Y., Stojanovich L., Svenungsson E., Wahl D., Tincani A., and Ward M. M., EULAR recommendations for the management of antiphospholipid syndrome in adults, *Annals of the Rheumatic Diseases.* (2019) 78, no. 10, 1296–1304, <https://doi.org/10.1136/annrheumdis-2019-215213>, 2-s2.0-85065986415.

8. Jiun-Ruey Hu, Jiawei Tan, PSAT045 Spontaneous Adrenal Hemorrhage with Partial Adrenal Insufficiency in a Patient Anticoagulated with Apixaban for Antiphospholipid Syndrome, *Journal of the Endocrine Society*, Volume 6, Issue Supplement_1, November-December 2022, Pages A107–A108, <https://doi.org/10.1210/jendso/bvac150.219>