

Gossypiboma: A Hidden Complication of Emergency Caesarean Section – A Rare Case Report and Literature Review

Abstract

Gossypiboma is caused by accidental retention of surgical sponges or swab in the body after the surgery. The abdominal cavity is the most common site of retained surgical sponges, which is usually rarely reported because of the fear of medico legal problems. Factors contributing to sponge retention include disorganized emergency surgeries, prolonged operations, unstable patient conditions, inexperienced personnel, and obesity. Typical symptoms include abdominal pain (42%), palpable masses (27%), and fever (12%). Common complications are fistula formation, abscesses, and intestinal obstruction, predominantly affecting the abdomen (56%), pelvis (18%), and thorax (11%). Surgical removal is the sole treatment option. We present a case of a 30-year-old woman who underwent an emergency caesarean section four months prior and subsequently developed a fistula and pus discharge at the incision site. Diagnosis was confirmed via CT scan, revealing a retained surgical sponge in the Douglas pouch, which was surgically removed.

Keywords: Emergency caesarean section, Gossypiboma, Textiloma, Retained Foreign body (RFB)

Introduction

Surgical sponges are the most frequently retained foreign bodies (RFB). The term "Gossypiboma" is derived from Latin, with "gossypium" meaning cotton and "boma" referring to concealment. The incidence rate of this condition ranges from 1 in 1000 to 15,000 surgical procedures, accounting for 0.3% to 1% of abdominal operations. Gossypiboma is particularly common in gynecological and upper abdominal emergency surgeries, but it may also occur in thoracic, orthopaedic, urological, and neurosurgical procedures. [1,2,4]

Clinical presentations of Gossypiboma vary based on sponge location and type of reaction. Symptoms can be asymptomatic or manifest as a pseudotumor syndrome, with common signs including abdominal distension, pain, palpable masses, abscesses, fistula formations, nausea, vomiting, and weight loss due to obstruction and malabsorption. Intra-abdominal sponges may migrate into the ileum, stomach, colon, vagina, or urinary bladder. [3,4,5]

Imaging modalities for diagnosis include ultrasound, CT, and MRI, each providing distinct features for retained sponges.

1. Ultrasound is useful in the diagnosis of abdominal retained sponges. The ultrasound features are usually a well-defined mass containing wavy internal echogenic focus with hypoechoic rim and a strong posterior acoustic shadow or air pockets.
2. On CT abdomen and pelvis—A gossypiboma may manifest as a cystic lesion with internal spongiform appearance with mottled shadow as air bubbles, hyperdense capsule, concentric layering, mottled shadows and mural calcification
3. MRI—Imaging features of gossypiboma in the abdomen and pelvis, which includes well defined mass with peripheral wall.[2,3,8]

Case Report

A 30-year-old female presented to our centre on 20th October 2020 with complaints of lower abdominal pain and a purulent discharge from a sinus at the incision site, persisting for three months following a lower segment caesarean section (LSCS), performed four months earlier at a rural hospital. Her general examination and laboratory parameters were within normal limits. Upon abdominal examination, a vertical midline scar with a sinus tract was observed in the lower part of the incision, along with a palpable lump in the infraumbilical region.

A pelvic ultrasound (USG) revealed a complex, heterogeneous mass in the pouch of Douglas. A subsequent CT scan of the abdomen showed a relatively well-defined, thick-walled lesion with trapped air located posterior to the uterus in the pouch of Douglas, measuring 10x8cm. The lesion appeared to be a gossypiboma, communicating anteriorly with a fistula tract.

An emergency exploratory laparotomy was performed under general anesthesia. Intraoperatively, a surgical sponge measuring 25x12 cm with an attached tail was discovered and removed. The sponge was located posterior to the uterus and urinary bladder, adhering to the rectal wall, and surrounded by foul-smelling thick pus. Pus samples were collected in a sterile container for culture and sensitivity testing. Following the removal of the sponge, a thorough peritoneal lavage with normal saline was conducted. The vertical midline incision was closed with all necessary precautions, ensuring accurate counts of sponges and instruments. The culture and sensitivity results showed the presence of Gram-positive bacteria, specifically *Staphylococcus aureus*.

The postoperative course was uneventful, and the patient was discharged on the 10th postoperative day, having recovered well. She was advised to follow up regularly. The removal of the surgical sponge was not disclosed to the patient's relatives or the media to maintain confidentiality and avoid potential medicolegal issues. (Fig 1-6)

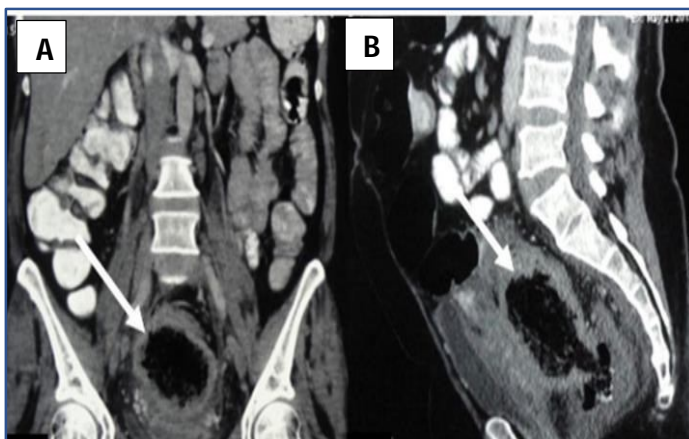


Fig-1 CT Abdomen and pelvis showed, well defined, heterogenous, air trapped pelvic mass

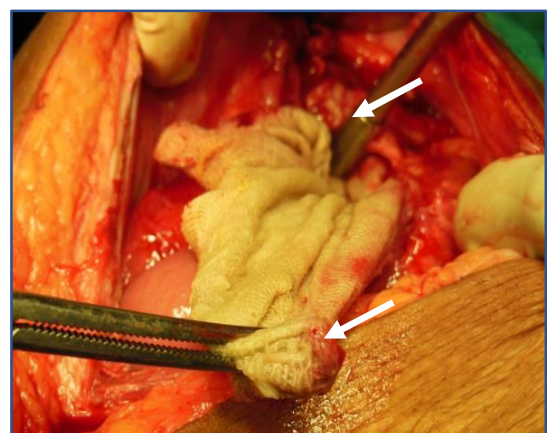


Fig-2 Exploratory laparotomy showing surgical sponge

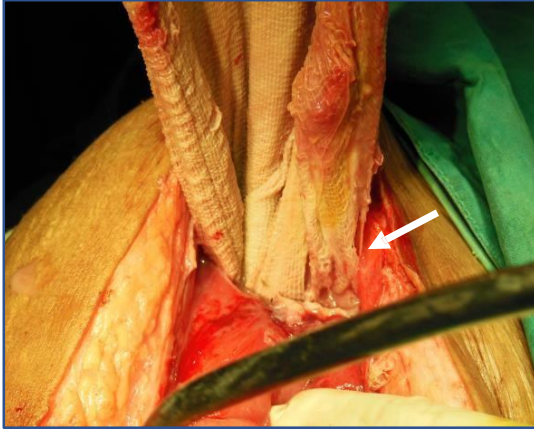


Fig-3 Explorative laparotomy showing surgical sponge in the pelvis

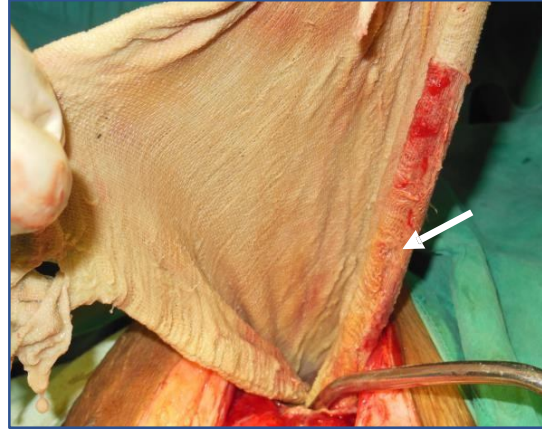


Fig-4 Intraoperative photograph showing complete removal of surgical sponge

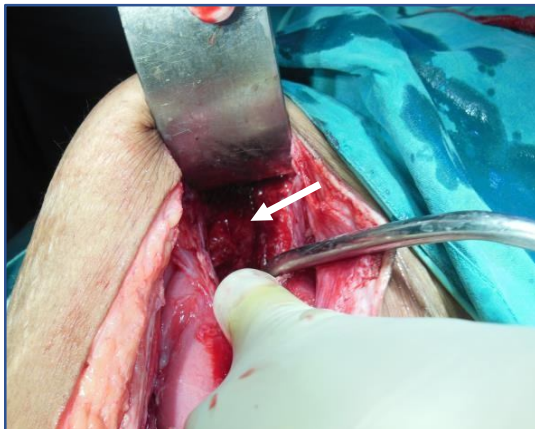


Fig-5 Intraoperative photograph showing pelvic cavity

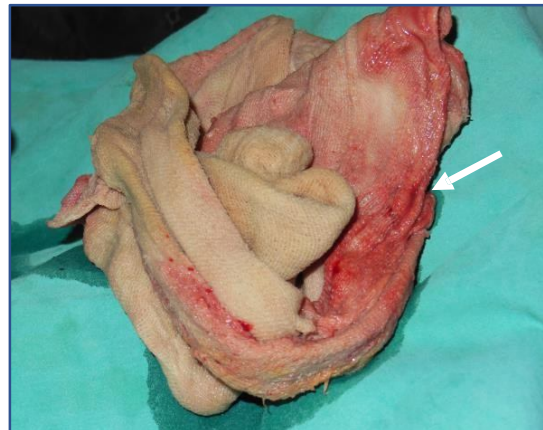


Fig-6 Photograph showing surgical sponge measuring 25x12

Discussion and Review

Gossypiboma, first reported in 1884 by Wilson, is derived from the Latin word "Gossypium" (meaning cotton) and "Boma" (meaning concealment). Retained foreign bodies (RFB) occur in 0.001%-0.01% of surgical procedures, with approximately 80% of cases caused by gossypiboma most often a retained surgical sponge. These incidents are more commonly observed in gynecological surgeries (41.2%) compared to abdominal surgeries (35.7%). [1,2,5]

A comprehensive electronic search was conducted in the PubMed database, covering the period from inception to May 31, 2023. Using search terms like "Gossypiboma," "Textiloma," "Gauze," "Sponge," and "Caesarean section," we identified 57 published cases related to gossypiboma. [1,4,5]

Prevention is critical to minimizing the incidence of gossypiboma. In India, surgeons can be prosecuted under Section 304A of the Indian Penal Code, which carries a penalty of up to 2 years in prison. The following strategies can help prevent gossypiboma: [2,4,9]

Risk factors contributing to gossypiboma include:

1. Emergency procedures involving significant blood loss.
2. Changes in scrub nurses during surgery.

3. Complex or intricate surgical procedures.
4. Surgeries involving multiple body cavities.
5. Unexpected change in the course of surgery
6. Long-duration surgeries
7. obese patients. [1,5]

Pathophysiology:

The pathogenesis of gossypiboma involves two types of responses:

1. **Exudative Inflammatory Response:** In patients with a hyper-antigenic reaction to the retained foreign body (RFB), an abscess forms around the object. As pressure increases, the abscess may rupture toward the intestinal wall, potentially forming an internal or external fistula. This can result in partial or complete migration of the sponge into the intestinal or colonic lumen. Once inside, it may either pass through unnoticed or cause obstruction in a narrowed section of the bowel, with possible discharge through the anus.
2. **Fibrinous Response:** In this response, the retained foreign body becomes encapsulated and forms a calcified mass. These cases often remain asymptomatic for years, with about one-third of patients being diagnosed incidentally. [2,3,8,9]

Surgical Management:

The only treatment for gossypiboma is surgical removal, which should be done urgently to prevent complications and legal consequences. Exploratory laparotomy is the standard approach, but minimally invasive techniques like endoscopy or laparoscopy may be effective depending on the foreign body's location, size, and the surgeon's expertise. However, endoscopic treatment is generally unsuccessful in cases involving transmural migration. [1,4,7]

Gossypiboma is a hidden danger that can arise after emergency, prolonged, or gynecological surgeries, making it a true nightmare for both surgeons and gynaecologists. [3,]

Gossypiboma can be prevented by incorporating a multidisciplinary approach which includes.

1. **Standard Sponge Counting:** Following protocols set by the American College of Surgeons and U.S. nursing guidelines, sponges should be counted at various stages of the procedure before starting, when adding new items, before closing the abdominal cavity, and before final skin closure. Any discrepancy should prompt an immediate search for missing items.
2. **WHO Surgical Safety Checklist:** This simple, effective checklist should be implemented to enhance surgical safety.
3. **Improved Communication:** Raising awareness and promoting clear communication among surgeons, nurses, and technicians in the operating room are essential for tracking the number and location of surgical sponges.
4. **Technological Innovations:** Implementing advanced technologies such as radiofrequency identification (RFID) tags and barcode scanning for surgical sponges can reduce the risk of retained foreign bodies.

5. **Surgical Training:** Surgical residency programs should include comprehensive training on proper counting methods for surgical sponges, gauze, and instruments to ensure operating room guidelines are followed.

Conclusion

Gossypiboma, the retention of foreign bodies within the abdominal cavity, is a rare but serious condition that can lead to significant complications and legal repercussions. Ensuring patient safety in the operating room is the shared responsibility of the entire surgical team, including surgeons, anaesthesiologists, and nurses.

A CT scan is the diagnostic tool of choice for detecting retained foreign bodies. To prevent such incidents, strict measures such as barcoding and radiofrequency identification (RFID) tagging of sponges should be implemented.

Failure to do so may result in both medical and legal consequences, as retained surgical sponges can lead to disputes between the patient and the medical team. Surgeons may face emotional distress, reputational damage, and charges of negligence. Hence, prevention always remains better than cure.

References

1. Kumar P, Shukla P, Tiwary SK, Verma A, Khanna AK. Gossypiboma: An avoidable but not a rare complication. *Proceedings of Singapore Healthcare*. 2021;30(4):330-333. doi:10.1177/2010105821991168
2. Alemu BN, Tirneh AG. Gossypiboma: A Case Series and Literature Review. *Ethiopian J Health Sci*. 2020 Jan;30(1):147-149. doi: 10.4314/ejhs.v30i1.19. PMID: 32116444; PMCID: PMC7036463.
3. Adonis Manzella, Paulo Borba Filho, Eolo Albuquerque, Fabiana Farias, and João Kaercher, Imaging of Gossypibomas: Pictorial Review, *American Journal of Roentgenology*, <https://doi.org/10.2214/AJR.07.7132>
4. Varlas, V. N.; Bors, R. G.; Mastalier, B.; Balescu, I.; Bacalbasa, N.; Cirstoiu, M.-M. Gossypiboma, the Hidden Enemy of an Emergency Cesarean Hysterectomy—Case Report and Review of the Literature. *J. Clin. Med*. 2023, 12, 5353. <https://doi.org/10.3390/jcm12165353>
5. Srivastava, K. N., Agarwal, Amit, Gossypiboma Posing as a Diagnostic Dilemma: A Case Report and Review of the Literature, *Case Reports in Surgery*, 2014, 713428, 3 pages, 2014. <https://doi.org/10.1155/2014/713428>
6. Rajput A, Loud PA, Gibbs JF, Kraybill WG. Diagnostic challenges in patients with tumors: Gossypiboma (foreign body) manifesting 30 years after laparotomy. *J Clin Oncol*. 2003;21:3700-1.
7. Ram, Tulasi & Dahiya, Divya & Naik, Anil. (2019). Gossypiboma: case report and review of literature. *International Surgery Journal*. 6. 4148. 10.18203/2349-2902.isj20195142.
8. Odion C, Okomayin AA, Tagar E, Odigie VI, Okpara ojiego CS, Aisabokhale O. Gossypiboma—“string of pearls” sign may be diagnostic: A case report. *Ann Med Res Pract* 2023;4:3.
9. de Sousa JB, Alves Martins BA, Rocha Ferreira IA, e Silva SM, de Oliveira PG (2020) Transmural migration of Gossypiboma with Intraluminal small-bowel obstruction: A case report. *Am J Case Rep* 21:e924506

10. TaameGebretsion M, Alemu TS, Mergiyaw YA. Gossypiboma – A Rare Cause of Palpable Intra-Abdominal Mass: A Case Report. *Open Access Surgery*. 2023;16:25-31 <https://doi.org/10.2147/OAS.S407868>