

Case report

Nondysraphic Intramedullary Spinal Cord Lipoma : A rare Cause of Paraparesis In A Child

ABSTRACT

Spinal cord lipomas constitute a very small percentage of all CNS tumors. The incidence of nondysraphic intramedullary lipoma of spinal cord is below 1% of all spinal cord tumors. Due to their mass effect, they can significantly cause progressive neurological deficits. We present a case of one and half year old girl with paraparesis. MRI whole spine was done which suggested C5-T1 intramedullary spinal cord lipoma. Laminectomy of C5, C6 and L1 with laminoplastic laminotomy from C7 to T12 for subtotal resection of lipoma was done. Early detection and timely treatment of intramedullary is recommended to prevent disease progression and better surgical outcome.

Keywords: [intramedullary, lipoma, spine]

1. INTRODUCTION

The incidence of spinal cord tumors, which are extremely rare tumors of the central nervous system, rises with advancing age.[1] Primary Spinal Cord tumors originate from the spinal cord or its surrounding tissues while Secondary Spinal Cord tumors originate from different parts of the body which metastases through blood or lymph. Depending upon the location with duramater, they can be extradural or intradural. Intradural may be extramedullary which is more common or intramedullary which is less common[2]

Spinal cord lipomas are made up of adipocytes and are benign in nature. They can be classified into 3 main groups:- lipomas of the conus medullaris, lipomas of the terminal filum, and subpial lipomas. Subpial lipomas are entirely intramedullary lesions and they are very rare[3] Intradural intramedullary spinal cord lipomas remain most commonly associated with dysraphism [2,4] and the incidence of nondysraphic intramedullary spinal cord lipomas is less than 1% of all spinal cord tumors[5] Nondysraphic intramedullary lipoma is even rarer in pediatric age group. [6]The posterior part of the cervical or thoracic spine are the most common locations of intradural lipomas[4]

2. PRESENTATION OF CASE

A one and a half years old girl presented with inability to sit or stand without support since birth. On neurological examination, paraparesis was present, knee jerk reflex was exaggerated and ankle clonus was found positive on both sides. GCS was 15/15, there was no abnormality on cranial nerve examination and no positive family history was present. Other than motor weakness, the patient had no other signs of developmental delay in terms of cognitive, social, emotional behavior. There was no signs of skin stigmata like hair, dimple or mass. Routine blood test were within normal limits. MRI spine revealed intramedullary lipoma expanding from C5 to L1 vertebrae. (Fig. 1 & 2) Patient was diagnosed with spastic paraparesis due to intradural intramedullary lipoma as was planned for maximum safe resection of the tumor. Under

general anesthesia, patient was positioned supine and posterior midline incision followed by subperiosteal dissection was done to retract and detach paraspinous muscles. Laminectomy of C5, C6 and L1 with laminoplastic laminotomy from C7 to T12 was done. Ligamentum flavum was resected and dura was open for accessing the intradural intramedullary lipoma.(Fig. 3)

There was no spinal dysraphism. The intramedullary lipoma was compressing both sides of the nerve roots. Subtotal removal of the lipoma was done as it was intermingled with the spinal cord. (Fig. 4) Excised tissue was sent to Pathology lab for biopsy and it was consistent with fibro-lipoma. Immediate post operative neurological status of the patient was same as preoperative status and the postoperative course was uneventful and patient was discharged after one week of surgery..

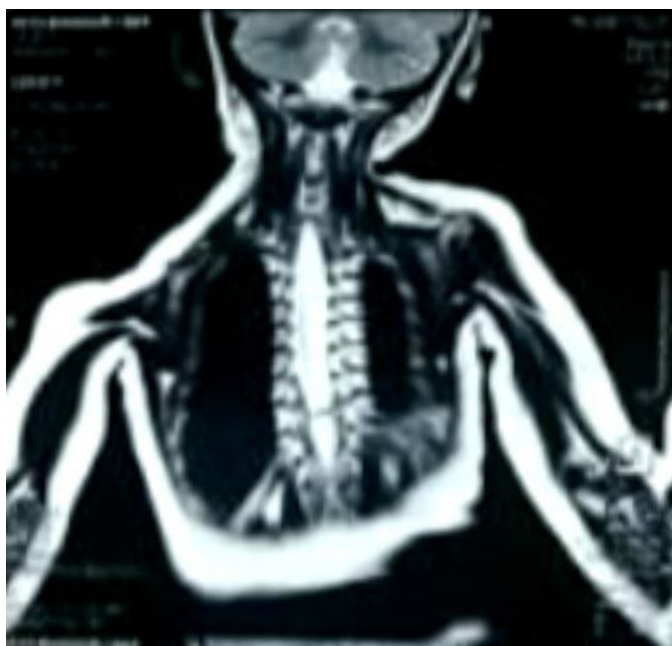


Figure 1.MRI whole spine, coronal section shows a large well defined fat contained predominantly extramedullary intradural lesion extending from C5 to L1 vertebral level s/o lipoma.

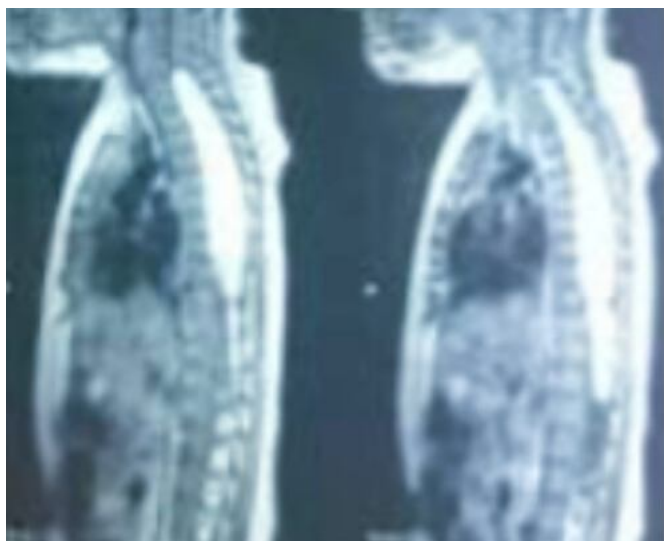

Figure 2: MRI whole spine, sagittal view shows a large well defined fat contained predominantly extramedullary intradural lesion extending from C5 to L1 vertebral level s/o lipoma

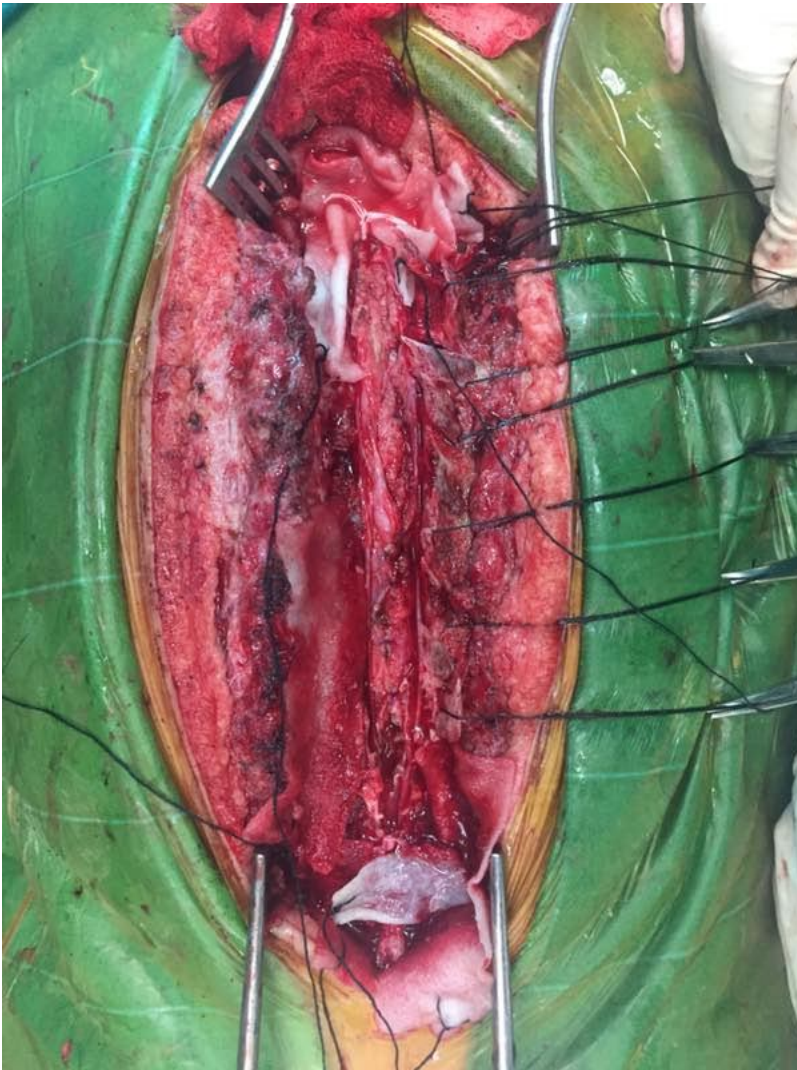

Figure 3 : Posterior midline incision and subperiosteal dissection done to retract and detach paraspinous muscles. Laminectomy of C5, C6 and L1 with laminoplastic laminotomy from C7 to T12 was done. Ligamentum flavum was resected and dura was open for accessing the intradural intramedullary lipoma.

UNDER

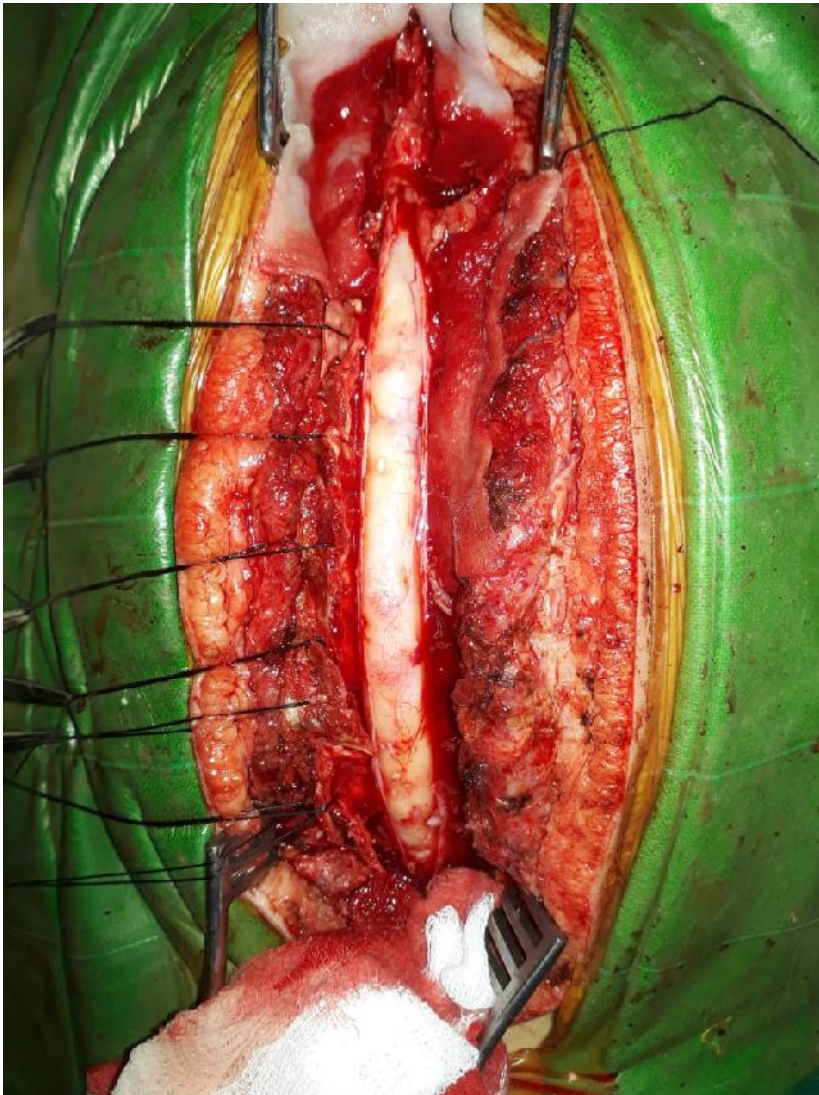

Figure 4 : The intramedullary lipoma was compressing both sides of the nerve roots. Subtotal removal of the lipoma was done as the mass was intermingled with the spinal cord.

3. DISCUSSION

A number of hypotheses have been put forward as the cause of intramedullary lipomas but none of them completely clarify the exact origins of the spinal lipoma. However, "Developmental Error Theory" is the most commonly accepted hypotheses which states that the growth of lipoma in the spinal cord is due to inclusion of misplaced adipocytes during the formation of the neural tube. [7,8,9]. Spinal lipoma is a hamartoma or a malformation and not a true neoplasm.[9] This theory too explains the dorsal location of lipoma and may also describe the existence of the nondysraphic spinal lipoma [7,8,9]

Early clinical presentation of spinal cord lipoma includes a slow ascending spastic monoparesis or paraparesis [10,11] The characteristic clinical presentation of intramedullary spinal cord lipomas is that the evolution of initial symptom is gradual but late deterioration is sudden [8,10,11] When there is physiological reserve for accommodation of the slow enlargement of lipoma, there is or no functional change, but when there is no more physiological reserve, neurological features progresses rapidly [8] Nondysraphic spinal cord lipomas have only small space for enlargement and therefore they have early appearance of symptoms [11]

Spinal Cord lipomas are a mixture of fatty tissues and connective tissues intervened by neural tissues so they are more a congenital lesion rather than a neoplasm [7,8,11] They can be managed conservatively if there is no symptoms. [7] However, surgical debulking should be done in symptomatic patients but aggressive debulking is not recommended. Decompression alone is sufficient even in symptomatic patients. Additionally, the impinging nature of the lipoma hampers gross total removal.[7,10] Early surgical treatment also avoids irreversible spinal cord dysfunction, therefore, early surgical intervention before symptoms progression is justifiable [8]

4. CONCLUSION

Intramedullary lipoma may be benign and very rarely found in children, but since its mass effect can cause symptoms which can deteriorates rapidly, early diagnosis with appropriate management like laminoplastic laminotomy for decompression of the lesion is crucial for preventing the progression of the symptoms,spinal stability and better cosmetic result.

CONSENT (WHEREEVER APPLICABLE)

All authors declare that 'written informed consent was obtained from the patient (or other approved parties) for publication of this case report and accompanying images. A copy of the written consent is available for review by the Editorial office/Chief Editor/Editorial Board members of this journal.

ETHICAL APPROVAL (WHEREEVER APPLICABLE)

All authors hereby declare that all experiments have been examined and approved by the appropriate ethics committee and have therefore been performed in accordance with the ethical standards laid down in the 1964 Declaration of Helsinki.

Disclaimer (Artificial intelligence)

Option 1:

Author(s) hereby declare that NO generative AI technologies such as Large Language Models (ChatGPT, COPILOT, etc.) and text-to-image generators have been used during the writing or editing of this manuscript.

Option 2:

Author(s) hereby declare that generative AI technologies such as Large Language Models, etc. have been used during the writing or editing of manuscripts. This explanation will include the name, version, model, and source of the generative AI technology and as well as all input prompts provided to the generative AI technology

Details of the AI usage are given below:

- 1.
- 2.
- 3.

REFERENCES

1. Schellinger KA, Propp JM, Villano JL, McCarthy BJ. Descriptive epidemiology of primary spinal cord tumors. *J Neurooncol*. 2008;87:173–9.
2. Samartzis D, Gillis CC, Shih P, O'Toole JE, Fessler RG. Intramedullary spinal cord tumors: Part I-epidemiology, pathophysiology, and diagnosis. *Global Spine J*. 2015;5:425–35.
3. Finn MA, Walker ML. Spinal lipomas: Clinical spectrum, embryology, and treatment. *Neurosurg Focus*. 2007;23:E10.
4. Wilson PE, Oleszek JL, Clayton GH. Pediatric spinal cord tumors and masses. *J Spinal Cord Med*. 2007;30(Suppl 1):S15–20.
5. de Araújo LP, Dezena RA, da Silva MN, Etchebehere RM, Dornelas AG. Thoraco-lumbar nondysraphic intramedullary spinal cord lipoma with an unusual aspect on MRI: Case report and review. *J Bras Neurocirurgia*. 2012;23:251–5.
6. Abuzayed B, Alawneh K, Al Qawasmeh M, Raffee L. Nondysraphic spinal intramedullary lipoma: a rare case and management. *Turk Arch Pediatr*. 2021;56:85–87.
7. Dyck P . Intramedullary lipoma. Diagnosis and treatment. *Spine* 1992; **17**: 979–981.
8. Lee M *et al*. Intramedullary spinal cord lipomas. *J Neurosurg* 1995; **82**: 394–400.
9. Ammerman BJ, Henry JM, De Girolami U, Earle KM . Intradural lipomas of the spinal cord. A clinicopathological correlation. *J Neurosurg* 1976; **44**: 331–336.
10. Kodama T, Numaguchi Y, Gellad FE, Sadato N . Magnetic resonance imaging of a high cervical intradural lipoma. *Comput Med Imag Graph* 1991; **15**: 93–95.

11. Timmer FA, van Rooij WJ, Beute GN, Teepe JL . Intramedullary lipoma. *Neuroradiology* 1996; **38**: 159–160.

UNDER PEER REVIEW