

Case report

A rare cases of endogenous endophthalmitis: diagnostic and therapeutic challenges

ABSTRACT

Aims: This report aims to highlight the importance of prompt diagnosis and intervention in cases of endogenous endophthalmitis, with particular focus on its nephrological etiology and associated systemic infections.

Presentation of Case: Two cases of endogenous endophthalmitis were observed in patients with nephrological complications. Case 1 involved a 50-year-old man with end-stage renal disease on hemodialysis, who presented with severe visual impairment in the right eye due to *Staphylococcus aureus* sepsis from a hemodialysis catheter infection. Despite aggressive treatment with intravitreal and systemic antibiotics, the patient's visual prognosis was poor. Case 2 involved a 65-year-old woman with acute pyelonephritis and undiagnosed diabetes, presenting with unilateral visual loss and ocular inflammation. Systemic and intravitreal antibiotics, alongside corticosteroids, led to a favorable outcome with a final visual acuity of 7/10.

Discussion: Both cases underscore the link between systemic infections, particularly in patients with renal or diabetic conditions, and endogenous endophthalmitis. Prompt recognition of ocular symptoms in patients with systemic infections is critical, as early intervention can preserve visual function. The role of broad-spectrum antibiotics, timely intravitreal injections, and systemic infection control is emphasized.

Conclusion: These cases illustrate the importance of early multidisciplinary intervention in managing endogenous endophthalmitis secondary to nephrological infections. While outcomes vary depending on disease severity and patient health, rapid diagnosis and treatment are vital to improving prognosis and preserving vision.

KEYWORDS: *Endogenous endophthalmitis, nephrological complications, systemic infection, hemodialysis, Staphylococcus aureus, intravitreal antibiotics, diabetes, ocular infection*

1. INTRODUCTION

Endogenous endophthalmitis is a serious, vision-threatening intraocular infection caused by hematogenous spread of the pathogens, usually due to distant systemic infections [1]. Patients with renal complications, such as those on hemodialysis or with urinary tract infections, are at heightened risk due to their compromised immune systems and frequent exposure to invasive procedures. Given that only early intervention can help preserve visual acuity, prompt recognition and management of this condition is important [2]. This article describes two interesting and rare cases that outline the nephrological etiology for endogenous endophthalmitis and the need for rapid diagnosis and treatment.

2. PRESENTATION OF CASE

CASE 1:

A 50-year-old man with end-stage renal disease and type 2 diabetes was recently placed on hemodialysis via a temporary dual lumen catheter. The patient presented to the emergency

department with pain, swelling, and blurry vision in his right eye, accompanied with chills and fever for the past 3 days.

On ophthalmological examination, the patient's had only a perception of hand motion in the affected eye. Slit-lamp examination revealed swollen lids, conjunctival injection, corneal edema, anterior chamber hypopyon, and vitreous infiltration. Urgent ophthalmological consultation was obtained, and the diagnosis of acute endophthalmitis was confirmed. Further examination revealed erythema at the subcutaneous tunnel with mild drainage at the exit site of the catheter (**Figure 1**).

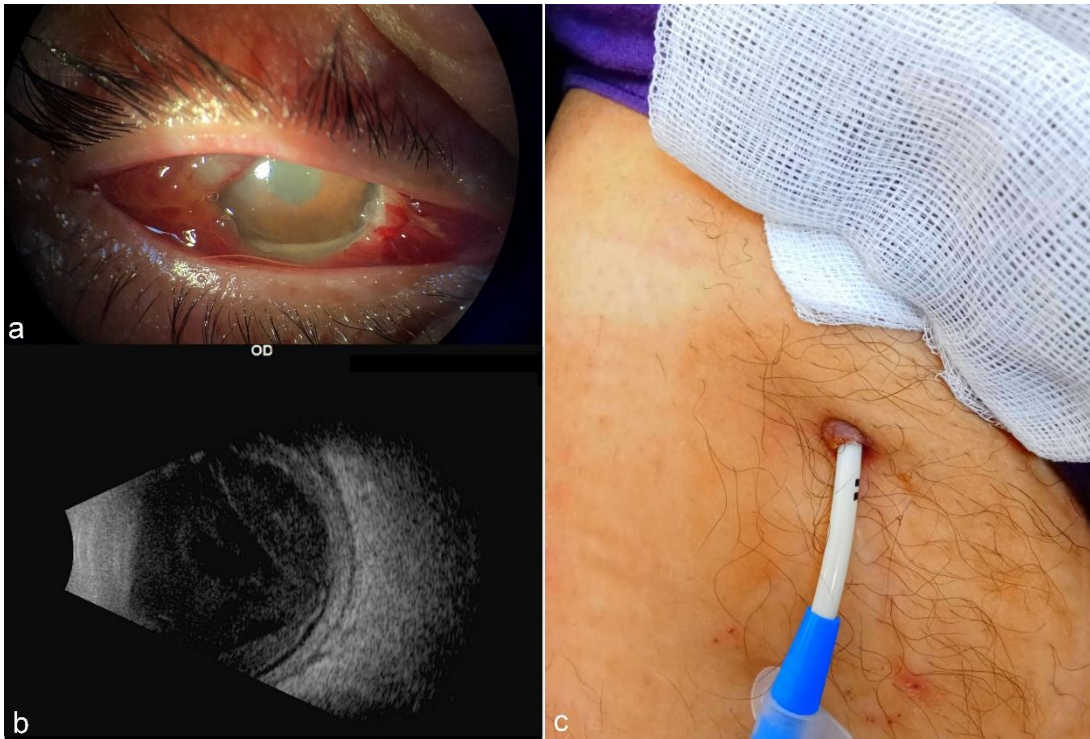


Figure 1:

- Anterior segment photo of the patient showing conjunctival injection, corneal edema, and anterior chamber hypopyon.
- B-scan of the patient revealed vitreous opacity.
- Cutaneous examination revealed erythema at the subcutaneous tunnel, with mild drainage at the catheter exit site.

Ocular ultrasound findings confirmed increased echogenicity within the vitreous cavity and thus supported the diagnosis of endophthalmitis. Based on a history of hemodialysis, the causative organism was suspected to be related to the hemodialysis catheter. Blood cultures at the time of admission were positive for *Staphylococcus aureus*, indeed indicating that the source was his hemodialysis catheter.

The initial management included immediate intravitreal injection of antibiotics. Broad-spectrum intravenous antibiotics were also initiated immediately along with removal of the hemodialysis catheter. Cultures of the vitreous sample and the hemodialysis catheter confirmed the presence of *Staphylococcus aureus*, which correlated with the blood culture.

Despite timely intervention, the visual acuity in the affected eye continued to deteriorate. Repeat intravitreal antibiotic injections were given (**Figure 2**). Treatment was maintained for 1 month, but the ophthalmological outcome was poor, with the formation of fibrin in front of the pupillary axis and phthisis bulbi.

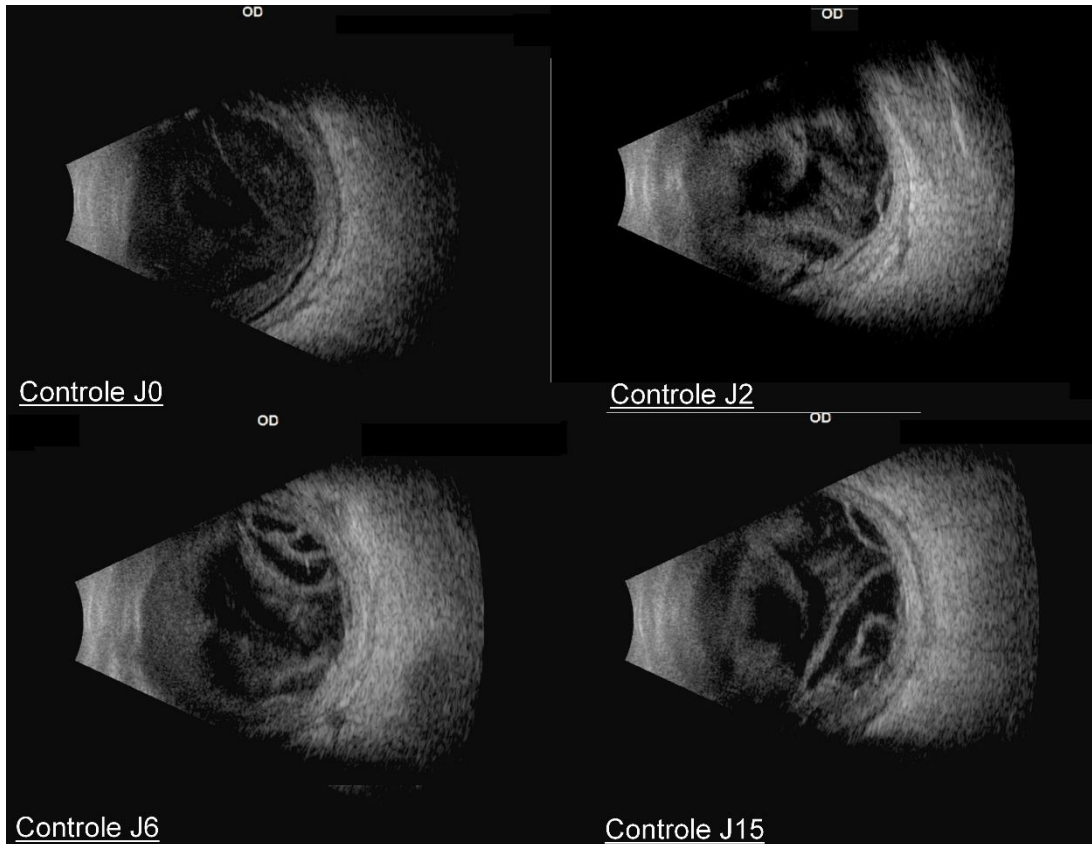


Figure 2: The progression was marked by an increase in vitreous opacity, with a localized retinal detachment developing over time.

CASE 2:

A 65-year-old woman was referred to our emergency department for unilateral painful red eye and sudden decrease in visual acuity in her right eye. These complaints began four days after she was diagnosed with acute pyelonephritis by the urology department after she reported left lumbar pain and fever.

Ophthalmological examination revealed a visual acuity limited to counting fingers at one-meter, conjunctival hyperemia with a perikeratic circle, corneal edema, and an important inflammatory reaction in the anterior chamber (**Figure 3a**). The vitreous was dense with pre-macular organization that prevented detailed fundus evaluation. Ocular ultrasound showed increased echogenicity within the vitreous cavity.

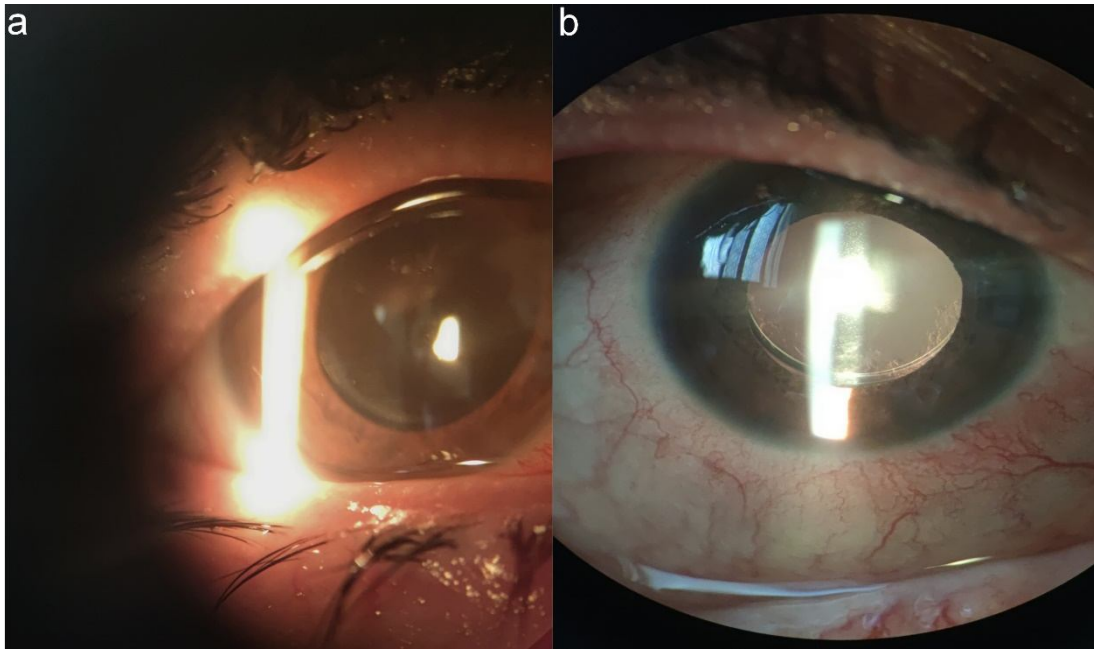


Figure 3

- a) Patient's clinical image upon emergency room admission
- b) Clinical image post-recovery.

In view of this clinical presentation, endogenous endophthalmitis was suspected. Urine culture revealed sensitive *Staphylococcus aureus*. Uroscan findings included the presence of ureterohydronephrosis due to a pelvic pre-meatal ureteral microlithiasis (630 HU) and two bilateral caliceal lithiases with significant functional impact (**Figure 4**).

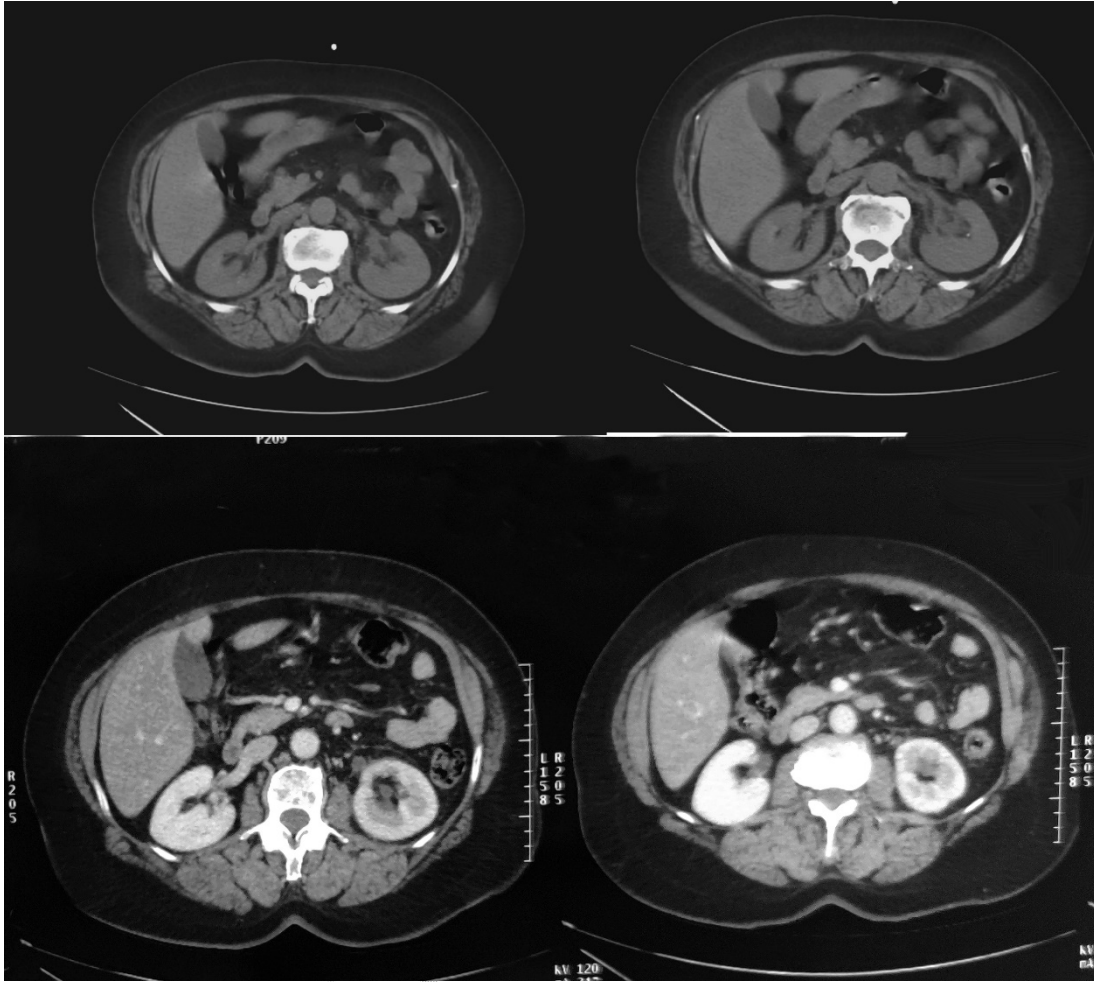


Figure 4: Image depicting the uroscan findings of ureterohydronephrosis located upstream of a pelvic pre-meatal ureteral microlithiasis

The patient was treated with systemic antibiotics, specifically third-generation cephalosporins and gentamicin, resulting in a favorable clinical response. Ophthalmologically, she received intravitreal injections of Ceftazidime and Vancomycin and was administered fortified eye drops containing the same antibiotics, leading to notable improvement. Once infection control was achieved, both topical and systemic corticosteroid therapies were initiated, which significantly reduced the inflammatory signs (**Figure 3b**).

Subsequent uroscan control revealed no dilation of the excretory cavities bilaterally and spontaneous expulsion of the lithiases, with resolution of renal suppuration due to systemic antibiotic therapy. Risk factor assessment identified previously undiagnosed diabetes, with a glycated hemoglobin level of 9%. Biological inflammation markers, including white blood cell count and C-reactive protein, normalized. Upon discharge, the patient's best visual acuity was recorded at 7/10. She was referred for follow-up care in nephrology and endocrinology.

3. DISCUSSION

The current study reports two unusual cases of unilateral endogenous endophthalmitis due to nephrological causes. Incidentally, the patients in both cases were diabetic, an underlying condition represented in the vast majority of patients with endogenous endophthalmitis [3].

Endogenous bacterial endophthalmitis, also referred to as metastatic bacterial endophthalmitis, represents a rare but severe ocular complication following a wide range of systemic infections, including those with hemodialysis catheters. The development of endophthalmitis in this setting represents a severe condition that needs to be identified early and treated promptly in order to preserve visual function.

The most common mechanism is hematogenous dissemination, where the bacteria ingress into the bloodstream and travel until they reach the eye [1]. Most instances of endogenous endophthalmitis are unilateral, with the right eye predominantly affected; this can be attributed to the more direct arterial supply from the right carotid artery [4].

Endogenous or metastatic bacterial endophthalmitis is a rare complication but often devastating from systemic bloodstream infection, accounting for 2-8% of all cases of endophthalmitis [5]. It is often associated with chronic medical conditions such as diabetes mellitus, chronic kidney diseases, several other chronic invasive procedures, non-ocular surgeries, the use of intravenous drugs, or even the prolonged use of central venous catheters [5].

The diagnosis of metastatic staphylococcal endophthalmitis in our case is supported by the following observations: the endophthalmitis following a well-documented episode of staphylococcal sepsis, the exclusion of evidence for any other infecting organism, and the response to systemic and local antibiotic therapy. In cases of suspected endogenous endophthalmitis, cultures of blood, urine, aqueous humor, vitreous humor, and other clinically relevant fluids must be done [9]. Blood cultures may be positive in up to 71% of patients with endogenous endophthalmitis, while vitreous and other aqueous humor cultures may be positive in 61% to 70% of cases [10]. Such cultures are critical to establishing the diagnosis but must be obtained from all possible additional sites of infection, including catheters and draining lesions. Negative eye cultures are not uncommon. [10]

Endogenous endophthalmitis will require intravitreal antibiotic therapy in its acute management [4]. Systemic antibiotics are also used to control distant foci of infection and prevent a persistent state of bacteremia, thus minimizing the risk of involvement of the other eye. The use of an initial broad-spectrum antibiotic therapy with vancomycin and an aminoglycoside or a third-generation cephalosporin is indicated [11].

In severe cases presenting with marked vitreous cloudiness, retinal detachment, low initial visual acuity, and the presence of virulent organisms, vitrectomy proved to be beneficial [12]. Vitrectomy was also useful for the isolation of the responsible pathogen with a detection rate of 62.5%, comparable to the 57.1% positivity of blood cultures [13]. Corticosteroids are very controversial [10]; however, it appears to be effective in reducing the chances of enucleation/evisceration, particularly in conjunction with vitrectomy [14].

This disease is generally associated with a poor prognosis and resulting in blindness for the majority of patients, as seen in our first case. In the early stages, the prognosis is generally favorable, but in the presence of other risk factors can lead to a poor prognosis [8]. Our second case had a good outcome with very satisfactory final visual acuity no doubt as a result of early systemic and local antibiotics.

4. CONCLUSION

Both cases indicate the importance of early suspicion and intervention in case of potential ocular complications during nephrological infections. Although they represent absolutely different patients' attitude and final results, both are united in the demonstration of the importance of timely and multidisciplinary intervention to save the vision.

CONSENT

All authors declare that 'written informed consent was obtained from the patient for publication of this case report and accompanying images. A copy of the written consent is available for review by the Editorial office/Chief Editor/Editorial Board members of this journal.

ETHICAL APPROVAL

All authors hereby declare that all experiments have been examined and approved by the appropriate ethics committee and have therefore been performed in accordance with the ethical standards laid down in the 1964 Declaration of Helsinki."

REFERENCES

- 1.Lin X, Huang R, Su J, Li H, Liu Z, Zhang P, et al. Optic nerve gliomas in adults: a SEER-based study. *Life*. 2022;15(1):262–9.
- 2.Hill CS, Khan M, Phipps K, Green K, Hargrave D, Aquilina K. Neurosurgical experience of managing optic pathway gliomas. *Childs Nerv Syst ChNS Off J Int Soc PediatrNeurosurg*. 2021;37(6):1917–29.
- 3.Farazdaghi MK, Katowitz WR, Avery RA. Current treatment of optic nerve gliomas. *Curr Opin Ophthalmol*. 2019;30(5):356–63.
- 4.Liu Y, Zhang-Nunes S, Zhu X, Xu X, Sun X, Wu Y. Late adult onset optic pathway astrocytoma. *J Clin Neurosci*. 2013;20(11):1610–2.
- 5.Cao Y, Tang X, Zan X, Li S. Benign optic nerve gliomas in an adult: A case report. *Medicine (Baltimore)*. 2022;101(34): e30132.
- 6.Hoyt WF, Meshel LG, Lessell S, Schatz NJ, Suckling RD. Malignant optic glioma of adulthood1. *Brain*. 1973;96(1):121–32.
- 7.Ben-Ishai M, Stiebel-Kalish H, Bialer OY. Malignant optic glioma of adulthood. *Harefuah*. 2019;158(11):708–10.
- 8.Bilgin G, Al-Obailan M, Bonelli L, Glasgow BJ, Vinters HV, Arnold AC. Aggressive low-grade optic nerve glioma in adults. *Neuro-Ophthalmol*. 2014;38(6):297–309.

APPENDIX



CARE Checklist of information to include when writing a case report



| Topic | Item | Checklist item description | Reported on Line |
|-----------------------------|------|--|---|
| Title | 1 | The diagnosis or intervention of primary focus followed by the words "case report" | L1-2 |
| Key Words | 2 | 2 to 5 key words that identify diagnoses or interventions in this case report, including "case report" | L-14-16 |
| Abstract (no references) | 3a | Introduction: What is unique about this case and what does it add to the scientific literature? | L12-13 |
| | 3b | Main symptoms and/or important clinical findings | L12-13 |
| | 3c | The main diagnoses, therapeutic interventions, and outcomes | L12-13 |
| | 3d | Conclusion—What is the main "take-away" lesson(s) from this case? | L12-13 |
| Introduction | 4 | One or two paragraphs summarizing why this case is unique (may include references) | L20-27 |
| Patient Information | 5a | De-identified patient specific information | L32-33 / L67-68 |
| | 5b | Primary concerns and symptoms of the patient | L33-35 / L68-70 |
| | 5c | Medical, family, and psycho-social history including relevant genetic information | L32 / L68-70 |
| | 5d | Relevant past interventions with outcomes | L36-41/LL71-75 |
| Clinical Findings | 6 | Describe significant physical examination (PE) and important clinical findings | L49-53/L80-83 |
| Timeline | 7 | Historical and current information from this episode of care organized as a timeline | L49-53/L80-83 |
| Diagnostic Assessment | 8a | Diagnostic testing (such as PE, laboratory testing, imaging, surveys) | L49-53/L80-83 |
| | 8b | Diagnostic challenges (such as access to testing, financial, or cultural) | L49-50/LL80 |
| | 8c | Diagnosis (including other diagnoses considered) | L49-50/LL80 |
| | 8d | Prognosis (such as staging in oncology) where applicable | L54-57/L87-92 |
| Therapeutic Intervention | 9a | Types of therapeutic intervention (such as pharmacologic, surgical, preventive, self-care) | L54-57/L87-92 |
| | 9b | Administration of therapeutic intervention (such as dosage, strength, duration) | L54-57/L87-92 |
| | 9c | Changes in therapeutic intervention (with rationale) | LL58-61/L93-98 |
| Follow-up and Outcomes | 10a | Clinician and patient-assessed outcomes (if available) | LL58-61/L93-98 |
| | 10b | Important follow-up diagnostic and other test results | LL58-61/L93-98 |
| | 10c | Intervention adherence and tolerability (How was this assessed?) | |
| | 10d | Adverse and unanticipated events | |
| Discussion | 11a | A scientific discussion of the strengths AND limitations associated with this case report | L102-104 |
| | 11b | Discussion of the relevant medical literature with references | LL105-145 |
| | 11c | The scientific rationale for any conclusions (including assessment of possible causes) | LL105-145 |
| | 11d | The primary "take-away" lessons of this case report (without references) in a one paragraph conclusion | L149-152 |
| Patient Perspective | 12 | The patient should share their perspective in one to two paragraphs on the treatment(s) they received | |
| Informed Consent | 13 | Did the patient give informed consent? Please provide if requested | Yes <input checked="" type="checkbox"/> No <input type="checkbox"/> |

UNDER REVIEW