

Updated Approaches to the Management of Complicated Peptic Ulcer Disease: A focus on bleeding, perforation and obstruction: Narrative review article

Abstract

Complicated peptic ulcer disease are complications that occur from peptic ulcer disease and can be divided into bleeding peptic ulcer, perforated peptic ulcer and gastric outlet obstruction. The diagnosis and management of this condition is important, as bleeding peptic ulcer disease is managed by endoscopy and medical therapy. Perforated gastric ulcer is primarily treated by surgical closure of the ulcer which can be performed by an open or laparoscopic method. Gastric outlet obstruction is managed by endoscopic ballon dilatation with surgical bypass being reserved for failure of medical therapy. As complicated peptic ulcer is associated with a significant morbidity and mortality, we have conducted this review article to look at the management of complicated peptic ulcer disease.

Keywords- “Bleeding peptic ulcer”, “Perforated peptic ulcer”, “Gastric outlet obstruction”, “endoscopic therapy” and “open surgery”

Introduction

Complicated peptic ulcer disease is a clinical spectrum that includes hemorrhage, perforation and obstruction. Medical therapy of peptic ulcer disease with proton pump inhibitors and helicobacter pylori eradication has seen a reduction of uncomplicated peptic ulcer disease but the incidence of complicated peptic ulcer disease has remained static. The incidence of bleeding peptic ulcer ranges from 19.4 to 57 patients per 100,000 population. The incidence of perforation accounts for 3.77 patients per 100,000 population. The risk factors for complicated peptic ulcer disease include the use of non-steroidal anti-inflammatory drugs (NSAID) and Aspirin(1).

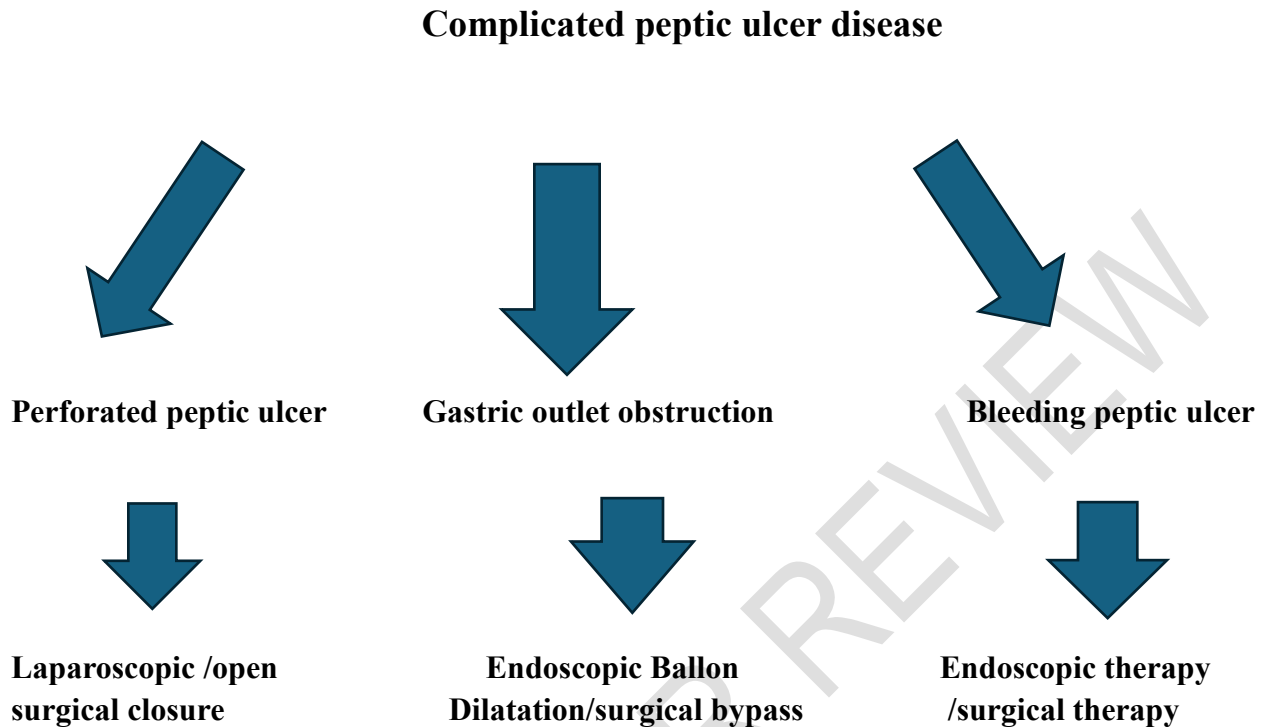
The complications of peptic ulcer disease are now the most common acute admissions to the surgical ward despite improved management of peptic ulcer disease with anti-secretory therapy and helicobacter pylori eradication. Bleeding peptic ulcer is the most common complication and is seen in 10% to 20% of cases. The management of bleeding peptic ulcer is by resuscitation and endoscopic therapy with surgery being performed if there is failure of endoscopic therapy.

Perforated peptic ulcer is the second most common complication and it is in 2% to 10% of cases. Helicobacter pylori infection is an important factor in the etiology of perforated peptic ulcer and the primary management is surgical closure with helicobacter pylori eradication. Gastric outlet obstruction is the third most common complication that is seen in 5% to 8% of cases. The management can be divided into non-operative therapy that includes anti-secretory therapy and endoscopic ballon dilatation. Operative therapy can be divided into resection like a subtotal gastrectomy or bypass surgery like a gastroenterostomy(2,3).

The World Society of Emergency Surgeons (WSES) in their guidelines on the management of perforated and bleeding peptic ulcer has recommended resuscitation and surgical treatment of perforated peptic ulcer, with laparoscopic surgery being the procedure of choice. Antimicrobial therapy is also essential for management of perforated peptic ulcer. For Bleeding peptic ulcer prompt resuscitation and endoscopic treatment is the first line of therapy, with surgery being reserved for failure of endoscopic therapy. The use of proton pump inhibitors and eradication of helicobacter pylori is essential for the management of both conditions(4).

The management of complicated peptic ulcer disease has seen a change in the trend of management. The management of bleeding peptic ulcer is primarily by endoscopic therapy with surgery being reserved for failure of this form of therapy. For perforated peptic ulcer the primary management is closure of the perforation surgically with laparoscopic closure of perforated gastric ulcer being the preferred treatment option and open surgical closure of the perforated gastric ulcer being reserved for patients who present with sepsis and signs of shock. For gastric outlet obstruction, endoscopic ballon dilatation is the primary treatment of choice with surgical bypass being reserved for failure of this form of therapy. We have conducted this review article to investigate the various management options. We conducted a literature review using PUBMED, Cochrane database of clinical reviews and Google scholar looking for clinical trial, observational studies, cohort studies systemic reviews, and meta-analysis from 1985 to 2024. We used the following keywords, “perforated peptic ulcer”, “Bleeding peptic ulcer”, “Gastric outlet obstruction”, “endoscopic therapy “and “open surgery”. All articles were in English language only. Further articles were obtained by manual cross referencing of the literature. Case reports and studies with less than 10 patients and editorials were excluded. Adult male and female patients were included in this study and pediatric patients were excluded.

Image I. Flowchart showing the treatment options for complicated peptic ulcer disease



Discussion

Bleeding Peptic ulcer

The incidence of bleeding peptic ulcer has seen a marked decrease over the past decade. It is seen in older patients with underlying co-morbidities, the use of aspirin and non-steroidal anti-inflammatory drugs(NSAID).The mortality from bleeding peptic ulcer has been constant over the past few years in spite of improved endoscopic therapy, and reduced surgical therapy(5,6).The risk stratification of patients with bleeding peptic ulcer can be done to categorize patients into low risk and high risk patients. The Glasgow Blatchford (GB) scoring system is ideal to identify low risk patients that can be managed as an outpatient. A score of less than 1 is associated with a need for intervention and death of 1%. The Rockall and Glasgow Blatchford (GB) score are used to identify patients at risk of treatment failure, with patients with a Rockall score of more than 6 are associated with a high risk of rebleeding and death(7,8).The endoscopic appearance of a peptic ulcer can be used to assess the risk of rebleeding, The Forrest classification divides the appearance of the ulcer as active bleeding or non-bleeding visible vessel(Forrest 1A,1B,IIA) for high risk patients and low risk patients with a flat, clean base ulcer(Forrest IIC and III)(9).

In High-risk patients who have been presented with bleeding peptic ulcer, after the patients has been resuscitated, endoscopy should be performed within 24 hours from the onset of bleeding.

Endoscopic therapy often establishes the diagnosis, achieves hemostasis and reduces the risk of rebleeding (10–12). Immediate endoscopy is not recommended as the high-risk patient who has not been adequately resuscitated may deteriorate further when endoscopic intervention is done (13). A randomized study by Lau et al looking at the mortality from bleeding in high risk bleeding peptic ulcer patients who underwent endoscopy with 6 hours against those that underwent endoscopy with 24 hours. This study concluded that there was no difference in the mortality between both the groups (14).

Endoscopic therapy for bleeding peptic ulcer can be divided into epinephrine injection of 1:10,000 or 1:20,000 in saline which is injected around the bleeding vessel, which then provides local vessel compression and tamponade effect. Electrocoagulation provides heat and coagulates the bleeding vessel, heater probe which allows transfer of heat over the surrounding tissues. Endo clips which are deployed over the bleeding vessels, over the proximal and distal end of the bleeding vessel. Combination therapy which utilizes injection of epinephrine with endo clip application is associated with better outcomes than monotherapy (15–22).

Surgical therapy is indicated when there is failure of endoscopic therapy for bleeding gastric ulcer. The type of surgical response can be divided into a minimal surgical approach which involves underrunning of the bleeding peptic ulcer (ulcer plication) and a definitive surgical procedure like a vagotomy or gastrectomy which will stop the bleeding and prevent recurrence. The clinical state of the patient is important in deciding which surgical procedure that need to be performed (23). Vagotomy and a drainage procedure is effective to stop the bleeding, but it is associated with an ulcer recurrence rate of 10% to 15%. Gastrectomy is associated with an ulcer recurrence rate of less than 1% but it has a higher morbidity and mortality (24–26). The location of the ulcer will determine which surgical procedure that need to be performed, a bleeding ulcer in the duodenum can be treated with underrunning of the bleeding vessel followed by a truncal vagotomy and a pyloroplasty. For ulcers over the duodenal bulb with scarring, then a subtotal gastrectomy or an antrectomy may need to be performed. Performing a gastrectomy is associated with a higher risk of duodenal dehiscence (27). The current trend in the surgical management of bleeding peptic ulcer is by performing decreasing acid reduction procedures like gastrectomy and this has seen a reduction in mortality and complication rates (28,29).

Table I Forrest classification of non-variceal bleed and prevalence

Forrest Classification	Prevalence (%)	Risk of Rebleeding (%)
Ia	7%	55%
Ib	27%	50%
IIa	26%	43%
IIb	11%	22%
IIc	4%	10%
III	25%	5%

Source: Laine et al.

Perforated peptic ulcer

Perforated peptic ulcer is the second most common complication of peptic ulcer disease. The use of drugs like aspirin, non-steroidal anti-inflammatory drugs (NSAID) and *Helicobacter pylori* have all been implicated in the etiology of perforated peptic ulcer disease. The most common site of perforation is the first part of the duodenum, followed by the antrum of the stomach. The clinical presentation is with upper abdominal pain followed by acute peritonitis and up to 35% of cases present with sepsis. The mortality rate from perforated peptic ulcer is up to 30%(30,31).The diagnosis of perforated peptic ulcer is confirmed by an erect chest x-ray or by a computerized tomography (CT). The management of perforated peptic ulcer is by surgical therapy which includes simple closure of the ulcer with an omental patch and a vagotomy or performing a partial gastrectomy for a large ulcer. The choice of which surgical procedure will depend on the clinical presentation of the patient. Conservative treatment for a sealed perforated peptic ulcer can be done for patients who present early and who are hemodynamically stable, but it is not routinely recommended (32–34).

The closure of the perforated peptic ulcer can be performed as an open or laparoscopic procedure. The closure is achieved by closing the perforated ulcer over an omental patch and this may be combined with a truncal vagotomy. Open closure of the perforated peptic ulcer is still the gold standard in the management of perforated peptic ulcer(35,36). There have been several studies that looked at the feasibility of laparoscopic closure of the perforated peptic ulcer and these studies concluded that laparoscopic closure of a perforated peptic ulcer was safe, effective and associated with reduced morbidity and mortality(37–41).

The mortality from perforated peptic ulcer is due to patients' factors like increased age, the presence of co-morbidities like diabetes mellitus and hypertension. The onset of presentation is important as the delay in presentation and the presence of sepsis increases the morbidity and mortality(42–44)

Gastric outlet obstruction

This is the third most common complication of peptic ulcer disease, and it is seen in 5% to 10% of cases. The clinical presentation is with upper abdominal pain and non-bilious vomiting, and they develop fluid and acid base balance abnormalities. On examination of the abdomen a succussion splash may be demonstrated. An upper gastrointestinal contrast series or computerized tomography may be used to establish the diagnosis. The diagnosis is confirmed by the inability to pass an endoscope through the pylorus. The management of gastric outlet obstruction can be divided into medical management which involves endoscopic balloon dilatation and helicobacter pylori eradication therapy. Surgical management involves performing a bypass like a gastrojejunostomy or a pyloroplasty(45–48).

The medical management of gastric outlet obstruction is by endoscopic balloon dilatation, where a balloon catheter is passed through the pylorus and dilated for 5 to 10 minutes. The procedure is repeated over a period of 3 to 4 months to maintain patency of the pylorus. The success rate for balloon dilatation is up to 70% after 1 year and 50% after 3 years of therapy. Endoscopic dilatation is a safe procedure with the main complications being bleeding and perforation. Recurrence of symptoms after two years of therapy will indicate failure of therapy(49–53)

Surgical therapy for gastric outlet obstruction involves performing a bypass by either a pyloroplasty or a gastrojejunostomy. The two most common pyloroplasty surgeries are the Finney pyloroplasty and the Heineke – Mikulicz pyloroplasty. Both procedures involve opening the pylorus and first part of the duodenum, and the closure is performed in a transverse manner to maintain patency of the duodenum and stomach. In patients where there is extensive scarring of the duodenum, a gastrojejunostomy can be performed to bypass the obstruction. An ante-colic gastrojejunostomy is the most common bypass procedure that is performed. Gastrectomies are seldom performed for gastric outlet obstruction (54–57)

Conclusion

The management of complicated peptic ulcer disease has seen a trend toward endoscopic and medical therapy. For bleeding peptic ulcer disease endoscopic therapy is the current first line therapy with surgery being reserved for failure of medical therapy. The mortality rate has remained static over the past few years. For perforated peptic ulcer, surgical closure of the perforation is the treatment of choice with laparoscopic repair being the preferred option if the service is available. The mortality from perforated peptic ulcer is high due to the risk of sepsis secondary from acute peritonitis. Gastric outlet obstruction is the least common complication from complicated peptic ulcer disease, and it is management with endoscopic balloon dilatation with surgery being reserved for failure of endoscopic therapy.

Conflict of interest-There is no conflict of interest

Disclaimer (Artificial intelligence)

Option 1:

Author(s) hereby declare that NO generative AI technologies such as Large Language Models (ChatGPT, COPILOT, etc.) and text-to-image generators have been used during the writing or editing of this manuscript.

References

1. Lau JY, Sung J, Hill C, Henderson C, Howden CW, Metz DC. Systematic review of the epidemiology of complicated peptic ulcer disease: incidence, recurrence, risk factors and mortality. *Digestion*. 2011;84(2):102-13. doi: 10.1159/000323958. Epub 2011 Apr 14. PMID: 21494041.
2. Behrman SW. Management of complicated peptic ulcer disease. *Arch Surg*. 2005 Feb;140(2):201-8. doi: 10.1001/archsurg.140.2.201. PMID: 15724004.
3. Milosavljevic T, Kostić-Milosavljević M, Jovanović I, Krstić M. Complications of peptic ulcer disease. *Dig Dis*. 2011;29(5):491-3. doi: 10.1159/000331517. Epub 2011 Nov 16. PMID: 22095016.
4. Tarasconi A, Coccolini F, Biffi WL, Tomasoni M, Ansaloni L, Picetti E, Molfino S, Shelat V, Cimbanassi S, Weber DG, Abu-Zidan FM, Campanile FC, Di Saverio S, Baiocchi GL, Casella C, Kelly MD, Kirkpatrick AW, Leppaniemi A, Moore EE, Peitzman A, Fraga GP, Ceresoli M, Maier RV, Wani I, Pattonieri V, Perrone G, Velmahos G, Sugrue M, Sartelli M, Kluger Y, Catena F. Perforated and bleeding peptic ulcer: WSES guidelines. *World J Emerg Surg*. 2020 Jan 7;15:3. doi: 10.1186/s13017-019-0283-9. PMID: 31921329; PMCID: PMC6947898.
5. Sadic J, Borgström A, Manjer J, Toth E, Lindell G. Bleeding peptic ulcer - time trends in incidence, treatment and mortality in Sweden. *Aliment Pharmacol Ther*. 2009 Aug 15;30(4):392-8. doi: 10.1111/j.1365-2036.2009.04058.x. Epub 2009 Jun 6. PMID: 19508403.

6. Feinman M, Haut ER. Upper gastrointestinal bleeding. *Surg Clin North Am*. 2014 Feb;94(1):43-53. doi: 10.1016/j.suc.2013.10.004. PMID: 24267496.
7. Laursen SB, Jørgensen HS, Schaffalitzky de Muckadell OB; Danish Society of Gastroenterology and Hepatology. National consensus on management of peptic ulcer bleeding in Denmark 2014. *Dan Med J*. 2014 Nov;61(11):C4969. PMID: 25370969.
8. Chiu PW, Sung JJ. Acute nonvariceal upper gastrointestinal bleeding. *Curr Opin Gastroenterol*. 2010 Sep;26(5):425-8. doi: 10.1097/MOG.0b013e32833d1746. PMID: 20703110.
9. Gralnek IM, Barkun AN, Bardou M. Management of acute bleeding from a peptic ulcer. *N Engl J Med*. 2008 Aug 28;359(9):928-37. doi: 10.1056/NEJMra0706113. PMID: 18753649.
10. Sung JJ, Chiu PW, Chan FKL, Lau JY, Goh KL, Ho LH, Jung HY, Sollano JD, Gotoda T, Reddy N, Singh R, Sugano K, Wu KC, Wu CY, Bjorkman DJ, Jensen DM, Kuipers EJ, Lanas A. Asia-Pacific working group consensus on non-variceal upper gastrointestinal bleeding: an update 2018. *Gut*. 2018 Oct;67(10):1757-1768. doi: 10.1136/gutjnl-2018-316276. Epub 2018 Apr 24. Erratum in: *Gut*. 2019 Feb;68(2):380. doi: 10.1136/gutjnl-2018-316276corr1. PMID: 29691276; PMCID: PMC6145289.
11. Hegade VS, Sood R, Mohammed N, Moreea S. Modern management of acute non-variceal upper gastrointestinal bleeding. *Postgrad Med J*. 2013 Oct;89(1056):591-8. doi: 10.1136/postgradmedj-2013-131842. Epub 2013 Aug 7. PMID: 23924686.
12. Orpen-Palmer J, Stanley AJ. Update on the management of upper gastrointestinal bleeding. *BMJ Med*. 2022 Sep 28;1(1):e000202. doi: 10.1136/bmjmed-2022-000202. PMID: 36936565; PMCID: PMC9951461.
13. Laine L, Jensen DM. Management of patients with ulcer bleeding. *Am J Gastroenterol*. 2012 Mar;107(3):345-60; quiz 361. doi: 10.1038/ajg.2011.480. Epub 2012 Feb 7. PMID: 22310222.
14. Lau JYW, Yu Y, Tang RSY, Chan HCH, Yip HC, Chan SM, Luk SWY, Wong SH, Lau LHS, Lui RN, Chan TT, Mak JWY, Chan FKL, Sung JJY. Timing of Endoscopy for Acute Upper Gastrointestinal Bleeding. *N Engl J Med*. 2020 Apr 2;382(14):1299-1308. doi: 10.1056/NEJMoa1912484. PMID: 32242355.
15. Kovacs TO, Jensen DM. Endoscopic therapy for severe ulcer bleeding. *Gastrointest Endosc Clin N Am*. 2011 Oct;21(4):681-96. doi: 10.1016/j.giec.2011.07.012. PMID: 21944418; PMCID: PMC3878947.

16. Barkun AN, Almadi M, Kuipers EJ, Laine L, Sung J, Tse F, Leontiadis GI, Abraham NS, Calvet X, Chan FKL, Douketis J, Enns R, Gralnek IM, Jairath V, Jensen D, Lau J, Lip GYH, Loffroy R, Maluf-Filho F, Meltzer AC, Reddy N, Saltzman JR, Marshall JK, Bardou M. Management of Nonvariceal Upper Gastrointestinal Bleeding: Guideline Recommendations From the International Consensus Group. *Ann Intern Med.* 2019 Dec 3;171(11):805-822. doi: 10.7326/M19-1795. Epub 2019 Oct 22. PMID: 31634917; PMCID: PMC7233308.
17. Gralnek IM, Dumonceau JM, Kuipers EJ, Lanas A, Sanders DS, Kurien M, Rotondano G, Hucl T, Dinis-Ribeiro M, Marmo R, Racz I, Arezzo A, Hoffmann RT, Lesur G, de Franchis R, Aabakken L, Veitch A, Radaelli F, Salgueiro P, Cardoso R, Maia L, Zullo A, Cipolletta L, Hassan C. Diagnosis and management of nonvariceal upper gastrointestinal hemorrhage: European Society of Gastrointestinal Endoscopy (ESGE) Guideline. *Endoscopy.* 2015 Oct;47(10):a1-46. doi: 10.1055/s-0034-1393172. Epub 2015 Sep 29. PMID: 26417980.
18. Samuel R, Bilal M, Tayyem O, Guturu P. Evaluation and management of Non-variceal upper gastrointestinal bleeding. *Dis Mon.* 2018 Jul;64(7):333-343. doi: 10.1016/j.disamonth.2018.02.003. Epub 2018 Mar 7. PMID: 29525375.
19. Wong SH, Sung JJ. Management of GI emergencies: peptic ulcer acute bleeding. *Best Pract Res Clin Gastroenterol.* 2013 Oct;27(5):639-47. doi: 10.1016/j.bpg.2013.08.003. Epub 2013 Sep 5. PMID: 24160924.
20. Alzoubaidi D, Lovat LB, Haidry R. Management of non-variceal upper gastrointestinal bleeding: where are we in 2018? *Frontline Gastroenterol.* 2019 Jan;10(1):35-42. doi: 10.1136/flgastro-2017-100901. Epub 2018 Feb 9. PMID: 30651955; PMCID: PMC6319149.
21. Alali AA, Barkun AN. An update on the management of non-variceal upper gastrointestinal bleeding. *Gastroenterol Rep (Oxf).* 2023 Mar 20;11:goad011. doi: 10.1093/gastro/goad011. PMID: 36949934; PMCID: PMC10027415.
22. Wasserman RD, Abel W, Monkemuller K, Yeaton P, Kesar V, Kesar V. Non-variceal Upper Gastrointestinal Bleeding and Its Endoscopic Management. *Turk J Gastroenterol.* 2024 May 20;35(8):599-608. doi: 10.5152/tjg.2024.23507. PMID: 39150279; PMCID: PMC11363156.
23. Chiu PW, Lau JY. What if endoscopic hemostasis fails?: Alternative treatment strategies: surgery. *Gastroenterol Clin North Am.* 2014 Dec;43(4):753-63. doi: 10.1016/j.gtc.2014.08.006. Epub 2014 Sep 12. PMID: 25440923.
24. de la Fuente SG, Khuri SF, Schiffner T, Henderson WG, Mantyh CR, Pappas TN. Comparative analysis of vagotomy and drainage versus vagotomy and resection

- procedures for bleeding peptic ulcer disease: results of 907 patients from the Department of Veterans Affairs National Surgical Quality Improvement Program database. *J Am Coll Surg.* 2006 Jan;202(1):78-86. doi: 10.1016/j.jamcollsurg.2005.09.001. Epub 2005 Nov 10. PMID: 16377500.
25. Lee CW, Sarosi GA Jr. Emergency ulcer surgery. *Surg Clin North Am.* 2011 Oct;91(5):1001-13. doi: 10.1016/j.suc.2011.06.008. PMID: 21889026; PMCID: PMC3811928.
 26. Hudnall A, Bardes JM, Coleman K, Stout C, Regier D, Balise S, Borgstrom D, Grabo D. The surgical management of complicated peptic ulcer disease: An EAST video presentation. *J Trauma Acute Care Surg.* 2022 Jul 1;93(1):e12-e16. doi: 10.1097/TA.0000000000003636. Epub 2022 Apr 1. PMID: 35358158; PMCID: PMC9233136.
 27. Lau JY, Chung SC. Surgery in the acute management of bleeding peptic ulcer. *Baillieres Best Pract Res Clin Gastroenterol.* 2000 Jun;14(3):505-18. doi: 10.1053/bega.2000.0094. PMID: 10952812.
 28. Olufajo OA, Wilson A, Yehayes B, Zeineddin A, Cornwell EE, Williams M. Trends in the Surgical Management and Outcomes of Complicated Peptic Ulcer Disease. *Am Surg.* 2020 Jul;86(7):856-864. doi: 10.1177/0003134820939929. PMID: 32916073.
 29. Sarosi GA Jr, Jaiswal KR, Nwariaku FE, Asolati M, Fleming JB, Anthony T. Surgical therapy of peptic ulcers in the 21st century: more common than you think. *Am J Surg.* 2005 Nov;190(5):775-9. doi: 10.1016/j.amjsurg.2005.07.019. PMID: 16226957.
 30. Søreide K, Thorsen K, Harrison EM, Bingener J, Møller MH, Ohene-Yeboah M, Søreide JA. Perforated peptic ulcer. *Lancet.* 2015 Sep 26;386(10000):1288-1298. doi: 10.1016/S0140-6736(15)00276-7. PMID: 26460663; PMCID: PMC4618390.
 31. Svanes C. Trends in perforated peptic ulcer: incidence, etiology, treatment, and prognosis. *World J Surg.* 2000 Mar;24(3):277-83. doi: 10.1007/s002689910045. PMID: 10658061.
 32. Chung KT, Shelat VG. Perforated peptic ulcer - an update. *World J Gastrointest Surg.* 2017 Jan 27;9(1):1-12. doi: 10.4240/wjgs.v9.i1.1. PMID: 28138363; PMCID: PMC5237817.
 33. Weledji EP. An Overview of Gastroduodenal Perforation. *Front Surg.* 2020 Nov 9;7:573901. doi: 10.3389/fsurg.2020.573901. PMID: 33240923; PMCID: PMC7680839.
 34. Bertleff MJ, Lange JF. Perforated peptic ulcer disease: a review of history and treatment. *Dig Surg.* 2010 Aug;27(3):161-9. doi: 10.1159/000264653. Epub 2010 Jun 22. PMID: 20571260.

35. Mouly C, Chati R, Scotté M, Regimbeau JM. Therapeutic management of perforated gastro-duodenal ulcer: literature review. *J Visc Surg.* 2013 Nov;150(5):333-40. doi: 10.1016/j.jviscsurg.2013.07.001. Epub 2013 Sep 4. PMID: 24011662.
36. Leeman MF, Skouras C, Paterson-Brown S. The management of perforated gastric ulcers. *Int J Surg.* 2013;11(4):322-4. doi: 10.1016/j.ijisu.2013.02.010. Epub 2013 Feb 27. PMID: 23454244.
37. Siu WT, Leong HT, Law BK, Chau CH, Li AC, Fung KH, Tai YP, Li MK. Laparoscopic repair for perforated peptic ulcer: a randomized controlled trial. *Ann Surg.* 2002 Mar;235(3):313-9. doi: 10.1097/00000658-200203000-00001. PMID: 11882751; PMCID: PMC1422436.
38. Kim CW, Kim JW, Yoon SN, Oh BY, Kang BM. Laparoscopic repair of perforated peptic ulcer: a multicenter, propensity score matching analysis. *BMC Surg.* 2022 Jun 16;22(1):230. doi: 10.1186/s12893-022-01681-1. PMID: 35710415; PMCID: PMC9205025.
39. Tartaglia D, Strambi S, Coccolini F, Mazzone A, Miccoli M, Cremonini C, Cicuttin E, Chiarugi M. Laparoscopic versus open repair of perforated peptic ulcers: analysis of outcomes and identification of predictive factors of conversion. *Updates Surg.* 2023 Apr;75(3):649-657. doi: 10.1007/s13304-022-01391-6. Epub 2022 Oct 3. PMID: 36192594; PMCID: PMC10042947.
40. Siow SL, Mahendran HA, Wong CM, Hardin M, Luk TL. Laparoscopic versus open repair of perforated peptic ulcer: Improving outcomes utilizing a standardized technique. *Asian J Surg.* 2018 Mar;41(2):136-142. doi: 10.1016/j.asjsur.2016.11.004. Epub 2016 Dec 7. PMID: 27955872.
41. Pereira A, Santos Sousa H, Gonçalves D, Lima da Costa E, Costa Pinho A, Barbosa E, Barbosa J. Surgery for Perforated Peptic Ulcer: Is Laparoscopy a New Paradigm? *Minim Invasive Surg.* 2021 May 12;2021:8828091. doi: 10.1155/2021/8828091. PMID: 34055409; PMCID: PMC8133844.
42. Thorsen K, Søreide JA, Søreide K. What is the best predictor of mortality in perforated peptic ulcer disease? A population-based, multivariable regression analysis including three clinical scoring systems. *J Gastrointest Surg.* 2014 Jul;18(7):1261-8. doi: 10.1007/s11605-014-2485-5. Epub 2014 Mar 8. PMID: 24610235; PMCID: PMC4057623.
43. Thorsen K, Glomsaker TB, von Meer A, Søreide K, Søreide JA. Trends in diagnosis and surgical management of patients with perforated peptic ulcer. *J Gastrointest Surg.* 2011 Aug;15(8):1329-35. doi: 10.1007/s11605-011-1482-1. Epub 2011 May 13. PMID: 21567292; PMCID: PMC3145078.

44. Hut A, Tatar C, Yıldırım D, Dönmez T, Ünal A, Kocakuşak A, Akıncı M. Is it possible to reduce the surgical mortality and morbidity of peptic ulcer perforations? *Turk J Surg.* 2017 Dec 1;33(4):267-273. doi: 10.5152/turkjsurg.2017.3670. PMID: 29260131; PMCID: PMC5731562.
45. Jawa RS, Mercer DW. Gastric outlet obstruction. In: *Common Problems in Acute Care Surgery.* Springer New York; 2013. p. 227–48. DOI: [10.1016/B978-1-4160-0317-5.50028-5](https://doi.org/10.1016/B978-1-4160-0317-5.50028-5)
46. Koop AH, Palmer WC, Stancampiano FF. Gastric outlet obstruction: A red flag, potentially manageable. *Cleve Clin J Med.* 2019 May;86(5):345-353. doi: 10.3949/ccjm.86a.18035. PMID: 31066665.
47. Gisbert JP, Pajares JM. Review article: Helicobacter pylori infection and gastric outlet obstruction - prevalence of the infection and role of antimicrobial treatment. *Aliment Pharmacol Ther.* 2002 Jul;16(7):1203-8. doi: 10.1046/j.1365-2036.2002.01275.x. PMID: 12144568.
48. Papanikolaou IS, Siersema PD. Gastric Outlet Obstruction: Current Status and Future Directions. *Gut Liver.* 2022 Sep 15;16(5):667-675. doi: 10.5009/gnl210327. Epub 2022 Mar 22. PMID: 35314520; PMCID: PMC9474481.
49. Kochhar R, Sethy PK, Nagi B, Wig JD. Endoscopic balloon dilatation of benign gastric outlet obstruction. *J Gastroenterol Hepatol.* 2004 Apr;19(4):418-22. doi: 10.1111/j.1440-1746.2003.03283.x. PMID: 15012779.
50. Kochhar R, Kochhar S. Endoscopic balloon dilation for benign gastric outlet obstruction in adults. *World J Gastrointest Endosc.* 2010 Jan 16;2(1):29-35. doi: 10.4253/wjge.v2.i1.29. PMID: 21160676; PMCID: PMC2998862.
51. Cherian PT, Cherian S, Singh P. Long-term follow-up of patients with gastric outlet obstruction related to peptic ulcer disease treated with endoscopic balloon dilatation and drug therapy. *Gastrointest Endosc.* 2007 Sep;66(3):491-7. doi: 10.1016/j.gie.2006.11.016. Epub 2007 Jul 20. PMID: 17640640.
52. Hamzaoui L, Bouassida M, Ben Mansour I, Medhioub M, Ezzine H, Touinsi H, Azouz MM. Balloon dilatation in patients with gastric outlet obstruction related to peptic ulcer disease. *Arab J Gastroenterol.* 2015 Sep-Dec;16(3-4):121-4. doi: 10.1016/j.ajg.2015.07.004. Epub 2015 Oct 3. PMID: 26440958.
53. Zare E, Raeisi H, Honarvar B, Lankarani KB. Long-term Results of Endoscopic Balloon Dilatation for Gastric Outlet Obstruction Caused by Peptic Ulcer Disease. *Middle East J Dig Dis.* 2019 Oct;11(4):218-224. doi: 10.15171/mejdd.2019.152. Epub 2019 Nov 5. PMID: 31824625; PMCID: PMC6895853.

54. Søreide K, Sarr MG, Søreide JA. Pyloroplasty for benign gastric outlet obstruction-- indications and techniques. *Scand J Surg.* 2006;95(1):11-6. doi: 10.1177/145749690609500103. PMID: 16579249.
55. Søreide K, Thorsen K, Søreide JA. Strategies to improve the outcome of emergency surgery for perforated peptic ulcer. *Br J Surg.* 2014 Jan;101(1):e51-64. doi: 10.1002/bjs.9368. Epub 2013 Nov 29. PMID: 24338777.
56. Ellis H. Pyloric stenosis complicating duodenal ulceration. *World J Surg.* 1987 Jun;11(3):315-8. doi: 10.1007/BF01658108. PMID: 3604238.
57. Iliklerden ÜH, Kalayci T, Kotan MÇ. Benign gastric outlet obstruction surgery: A tertiary center experience. *Eastern Journal of Medicine.* 2021;26(3):450–6. DOI: [10.5505/ejm.2021.47354](https://doi.org/10.5505/ejm.2021.47354)

UNDER PEER REVIEW