

**CYSTIC DUCT VARIATIONS IN ADULT POPULATION; A MAGNETIC
RESONANCE BASED CHOLANGIOPANCREATICOGRAPHY AT A TERTIARY
CARE REFERRAL HOSPITAL**

ABSTRACT

Objective: To demonstrate the imaging and anatomical features of cystic duct variants on Magnetic resonance cholangiopancreatography and document prevalence in urban population.

Study Design: Retrospective observational study.

Place and Duration of Study: Department of Radiology, Liaquat National Hospital Karachi, from *January 2021 to December 2022*.

Methodology: Magnetic resonance cholangiopancreatography(MRCP) was performed in a total of 152 cases for various indications for example cholelithiasis, choledocholithiasis, biliary tract obstruction, acute cholecystitis, chronic pancreatitis and pancreatic divisum, A phased array body coil and departmental protocols were used for the examinations, which produced heavily T2 weighted sequences including FRFSE (fast recovery fast spin echo) coronal oblique 3D images. Through multiplanar reconstruction, reformatting and maximum intensity projections were done for acquired images to optimize ductal visualization. PACS (picture archiving and communication system) was used for the evaluation of MRCP images. The ductal course, length, and insertion of the cystic duct were recorded. Descriptive statistics were calculated using SPSS. Chi-Square test was applied considering p-value ≤ 0.05 as significant.

Results: The mean age was 34.49 ± 7.78 years. For the insertion of the cystic on bile duct, Right Lateral Insertion was 70.4%, Spiral Course with Medial Insertion was 3.3%, Low lateral insertion was 6.6%, Low Medial insertion was 5.3%, High Insertion was 3.3%, Anterior Insertion was 1.3%, Posterior Insertion was 7.9%. For the course and length of cystic duct, parallel Course was 7.2%, Short length of cystic duct was 17.1%. In others variants, Cystic duct joining right hepatic duct was 0.7%, and no Right Posterior sectorial hepatic duct draining into cystic duct was observed. On the other hand, there is no significant difference between age or sex and a specific anatomical variation in the cystic duct, $p > 0.05$.

Conclusion: Among the existing anatomical variants in the cystic duct in this adult population, where the lateral insertion is the most common form, up to 70% of the cases, it should not be overlooked that approximately one of every five patients may have a short cyst which can predispose to bile duct injury at the time of a cholecystectomy if adequate care is not taken.

Keywords: Magnetic resonance cholangiopancreatography (MRCP), cystic duct variants

INTRODUCTION

The variations and anatomy of the biliary system have been extensively researched and established.¹ However, the anatomy and variations of the ductal cyst must be known in detail due to the major organs' close proximity and the intricate processes involved in embryogenesis. Otherwise, fatal complications may result due to iatrogenic injuries to biliary tract.^{1, 2} Consequently, iatrogenic injuries may cause adhesions, fibrotic bands, inflammation or bleeding. A noninvasive imaging technology that can outline the structure of the cystic ducts before any intervention operation could be very important clinically. Ultrasound makes it challenging to see non-dilated cystic ducts.

Studies have demonstrated that the most effective method of noninvasive imaging for determining the anatomy of the cystic duct and common bile duct is magnetic resonance cholangiopancreatography, which significantly enhances the laparoscopic cholecystectomy's safety level. Numerous variations in length, direction, and junction of the cystic duct have been documented in the literature.^{2,3}

Clinically more significant variations in the cystic duct include low insertion, anterior or posterior spiral course with medial insertion, low drainage of the cystic duct to the right or left hepatic duct, double cystic duct, and parallel course of the cystic duct with the common hepatic duct.¹⁻³

The common hepatic duct, most commonly enters from the right lateral aspect that joins the common hepatic duct approximately midway between the ampulla of Vater and hepatic confluence.³

High insertion is the term used to describe the point where the main hepatic duct and the cystic duct converge. Low insertion occurs when the common hepatic duct meets at the organ's lowest point. Anterior, posterior and medial insertion is documented when cystic duct joins common hepatic duct as anterior, posterior, and medial (to the left of Common hepatic duct). The term "short cystic duct" refers to a cystic duct that is shorter than 5.0 millimeters. A cystic duct's parallel path with the common hepatic duct for at least 2 centimeters is referred to as a long parallel insertion. Literature also reported that the right hepatic duct had abnormal cystic duct drainage.¹⁻³ Additionally, it has been noted that individuals with the abnormalities in their cystic duct are more likely to have gallbladder stones than those without changes.⁴ It was discovered that low insertion of the common duct was the most prevalent variant⁴⁻⁶.

It is important to know the anatomical variations of the cystic duct as considering these variants during surgical, laparoscopic or percutaneous procedures, there is reduction in the complications.¹⁻⁴

METHODOLOGY

We carried out the retrospective study. All patients who were hospitalized or visited outpatient department and referred for MRCP in our hospital for different indications, were included in the study. However those patients were excluded from the study who have undergone any biliary

tract surgery, had cholangiocarcinoma, having history of liver transplant, had choledochal cyst or had neoplastic masses of pancreatic head or liver. After taking approval from Research and Ethical Review Committee, this study was conducted from January 2021 to December 2022, over a period of 2 years. All data kept anonymous and confidential. Informed Consent would not be taken as this is a retrospective study.

There was variability in the cystic duct's entry point into the common hepatic duct. Normal insertion was considered when it connects to the CHD about midway between the ampulla of Vater and the hepatic confluence. When the cystic duct joins the CHD in the upper third, the insertion point is thought to be high. When cystic duct joins CHD in its bottom third, low insertion was taken into consideration. The posterior, anterior, and medial points where the ductal cyst joins CHD were recorded as the insertion point. The cystic duct was considered short when the length of the cystic duct was <5 mm. The insertion was considered long-parallel when the course of the parallel cystic duct with CHD was at least 2 cm. The right hepatic duct insertion into the cystic duct was regarded as drainage of the aberrant cystic duct into the hepatic duct of the right.

By following departmental protocols, utilizing a 1.5-tesla Toshiba and GE, employing a phased array body coil, the examinations were carried out to produce heavily T2 weighted sequences that included fast recovery fast spin echo coronal oblique 3D images.

Before the study, patients were instructed to fast for four hours to decrease gastric and duodenal fluid discharges, lower intestinal peristalsis, and encourage gall bladder distension. Multiplanar reconstruction and maximum intensity projections are used to reformat obtained pictures in several planes for the best possible visibility of the ducts. A radiology expert evaluated the MRCP pictures using PACS. Documentation was done on the cystic duct's length, course, and insertion.

The predesigned proforma was used for data entry. SPSS v.25 was utilized for the descriptive and inferential statistical analyses. Quantitative and qualitative variables were presented as mean \pm sd and frequency along with percentages respectively. The Chi-square or Fisher exact test was used for the association of categorical variables as appropriate. P-value ≤ 0.05 was considered statistically significant.

RESULTS:

Out of total of 152 patients, the overall mean age was 34.49 ± 7.78 years. We found 54.6% of patients had age ≤ 35 years and 45.4% had >35 years (Figure-1). Their gender was noted as 49.3% males and 50.7% females (Figure 2).

The anatomical variants were noted as Normal right lateral Insertion was 70.4%, Spiral Course with Medial Insertion was 3.3%, Low insertion was 6.6%, Low Medial insertion was 5.3%, High Insertion was 3.3%, Anterior Insertion was 1.3%, Posterior Insertion was 7.9%, Parallel Course was 7.2%, Short length of cystic duct was 17.1%, Cystic duct joining right hepatic duct was 0.7%, and there was no Rt. Post-sectorial hepatic duct draining into the cystic duct was observed. The detailed frequency distribution of demographics and anatomical variants is presented in Table 1

The anatomical variants concerning age group and gender were also analyzed and their associations were evaluated. It was observed that the anatomical variants were not significantly associated with age groups and gender ($p>0.05$). The detailed findings of the association of age group and gender with anatomical variants are presented in Table 2.

DISCUSSION

The cystic duct's position and level of insertion are, where the most prevalent anatomical differences occur.⁷ Under the confluence of the left hepatic duct and right hepatic duct, the ductal cyst normally connects to the common hepatic duct by a right-lateral position. It might have a spiral insertion in the front or the back, prevalent in 58% of people, making it deemed typical.⁸⁻¹⁰ Between the porta hepatis and the ampulla of Vater, the cystic duct often connects to the CBD from a right lateral location. Alternative insertion patterns for the cystic duct include (a) anterior spiral insertion, (b) posterior spiral insertion, (c) low lateral insertion, (d) proximal insertion, and (e) low medial insertion. The cystic duct may connect to the right, left or common hepatic duct in place of the common bile duct. Alternatively, the cystic duct may join at the ampulla of Vater, intrapancreatic CBD and intraduodenal CBD. The cystic duct insertion into the duodenum is a rare occurrence.^{7,11}

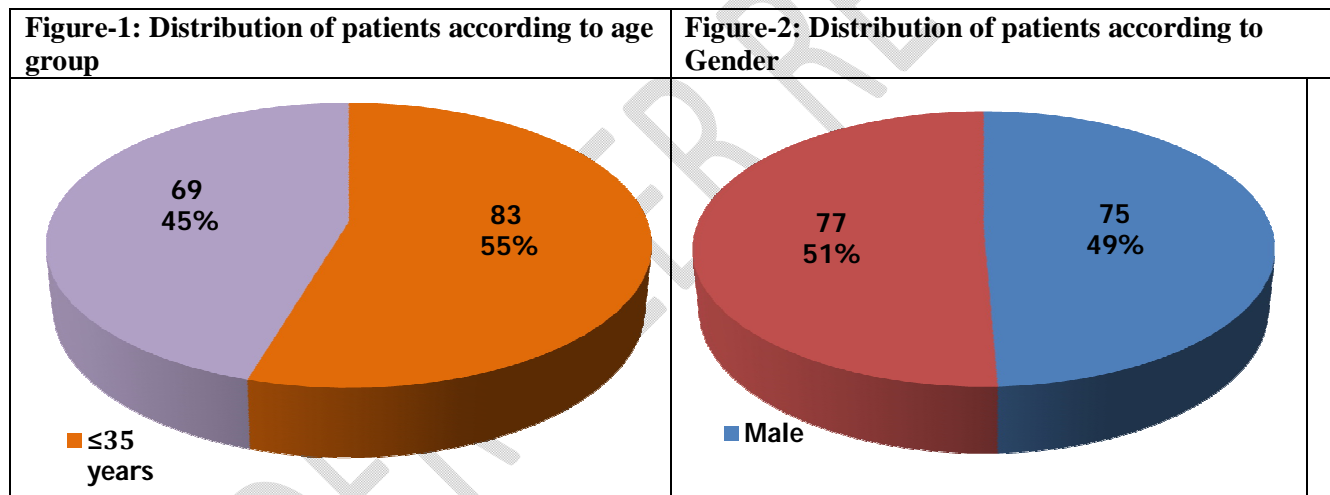


Table-1 Frequency distribution of Patient's Anatomical variants

	YES	NO
	n(%)	n(%)
Normal RT Lat Insertion	107(70.4)	45(29.6)
Spiral Course with Medical Insertion	5(3.3)	147(96.7)
Low insertion	10(6.6)	142(93.4)
Low Medical insertion	8(5.3)	144(94.7)
High Insertion	5(3.3)	147(96.7)
Anterior Insertion	2(1.3)	150(98.7)
Posterior Insertion	12(7.9)	140(92.1)
Parallel Course	11(7.2)	141(92.8)
Short length of cystic duct	26(17.1)	126(82.9)
Cystic duct joining right hepatic duct	1(0.7)	151(99.3)
Rt. Post sectorial hepatic duct draining into cystic duct	0(0)	152(100)

Table 2: Association of age and gender with Anatomical variants

	Age Group		P-value*	Gender		P-value*
	≤35 years	>35 years		Male	Female	
Normal RT Lat Insertion						
Yes	59(55.1)	48(44.9)	0.838	56(52.3)	51(47.7)	0.255
No	24(53.3)	21(46.7)		19(42.2)	26(57.8)	
Spiral Course with Medial Insertion						
Yes	2(40)	3(60)	0.659	1(20)	4(80)	0.367
No	81(55.1)	66(44.9)		74(50.3)	73(49.7)	
Low insertion						
Yes	5(50)	5(50)	1.000	4(40)	6(60)	0.746
No	78(54.9)	64(45.1)		71(50)	71(50)	
Low Medial insertion						
Yes	5(62.5)	3(37.5)	0.729	6(75)	2(25)	0.164
No	78(54.2)	66(45.8)		69(47.9)	75(52.1)	
High Insertion						
Yes	2(40)	3(60)	0.659	3(60)	2(40)	0.679
No	81(55.1)	66(44.9)		72(49)	75(51)	
Anterior Insertion						
Yes	2(100)	0(0)	0.501	0(0)	2(100)	0.497
No	81(54)	69(46)		75(50)	75(50)	
Posterior Insertion						
Yes	7(58.3)	5(41.7)	0.787	4(33.3)	8(66.7)	0.248
No	76(54.3)	64(45.7)		71(50.7)	69(49.3)	
Parallel Course						
Yes	5(45.5)	6(54.5)	0.548	3(27.3)	8(72.7)	0.128
No	78(55.3)	63(44.7)		72(51.1)	69(48.9)	
Short length of cystic duct						
Yes	15(57.7)	11(42.3)	0.728	10(38.5)	16(61.5)	0.223
No	68(54)	58(46)		65(51.6)	61(48.4)	
Cystic duct joining right hepatic duct						
Yes	1(100)	0(0)	1.000	1(100)	0(0)	0.493
No	82(54.3)	69(54.7)		74(49)	77(51)	

*Insignificant at p-value>0.05

The extrahepatic biliary tree's anatomy can be visualized by means of a range of imaging techniques, including ultrasound, computed tomography (CT), infusion CT cholangiography, direct cholangiography (percutaneous transhepatic cholangiography, endoscopic retrograde

cholangiopancreatography, transhepatic cholangiopancreatography, transperitoneal cholangiopancreatography, T-tube cholangiography^{12,13,15,17} The last ten years have observed a rise in the use of high resolution MR imaging and MRCP as exceptionally accurate and noninvasive techniques for evaluating the extrahepatic biliary system.^{11,12}

Accurate preoperative biliary architecture assessment and delineation are crucial for ensuring a safe and successful outcome.^{12,13} MRCP is a continuously improving imaging method that is utilised to provide the best possible images of the biliary and pancreatic ductal architecture. It is non-invasive, ionising radiation-free, and doesn't call for anaesthetic. The identification of preoperative hepatobiliary tract and cystic duct anatomy, along with its associated variations and abnormalities, plays a critical role in the prevention of iatrogenic complications.^{12,13}

In a research, 1.3-2.6% of patients were found to have a short cystic duct. In a prior study, 51.5% of patients had a correct lateral insertion of the cystic duct in the middle third of the common hepatic duct. In 16% of the instances, there was medial insertion. In 9% of instances, low insertion was detected. 7.5% of patients had a cystic duct route that ran parallel to common hepatic duct. In 6% of cases, high insertion in the cystic duct, and in 1% of cases, the cystic duct was short.^{12,13,17} In one instance, drainage in the right hepatic duct from the cystic duct was noted.⁸

Griffin et al. reported that in 50% of cases, the lateral common hepatic duct connected to the cystic duct while in 30% of cases, it was put in the front and rear; and in 20% of cases, it was implanted medially.¹⁸ It should be noted that medial insertion was observed in 10–18% cases in other studies. Around 8–11% of instances have been documented to have low medial insertion.^{18,19}

Evidence from studies indicates that the common and cystic hepatic ducts are parallel for at least 2 cm in 1.2-25% of patients. It is necessary to diagnose abnormal cystic duct, high point of union with the CBD, abnormal intrahepatic bile ducts uniting with the cystic duct and abnormal cystic duct draining into the right hepatic duct because all variations may create unintended transactions and ligations during surgery if they are undiagnosed^{3,17}

The risk of the cystic duct being longer than normal is increased by the low junction of the CHD and the potential for partial fusion before anastomosis.¹⁶

Sometimes the cystic duct will enter the right hepatic duct. If this happens, there is a risk that the right hepatic duct will be mistaken for a cystic duct and split where it connects to left hepatic duct, or if latter duct accidentally damaged during surgery, bile leakage will contaminate the field.¹⁶

In a research with 122 patients, 31 (25.2%) had anatomical abnormalities at various pancreatobiliary tract levels.¹² In our study, the findings was 21(5.6%). A thorough examination of the literature revealed studies that reported these variances in 13% to 19% of their groups. According to an Italian research study, 43% of patients had anatomical variations, while the remaining 57% of patients showed the normal layout of the pancreatobiliary tract anatomy.³ Total 39.5% of the sample in one research with 590 participants had comparable changes.¹⁹ Our findings are well below these numbers.

High diagnostic accuracy is achieved in the delineation of anatomic variations of cystic ducts and bile ducts as a result of the recent improvement in spatial resolution attained by MRCP in combination with ultra-fast pattern.^{19,20}

Owing to budgetary restrictions, the current study was unable to include the general population and could only include patients who required MRCP owing to a pancreatobiliary tract condition. This resulted in a small sample size. Additionally, only 1.5 Tesla was employed in the

study because of the non-availability of 3 Tesla facilities. The study will still be helpful to clinical health practitioners despite its limitations. It will aid in the assessment of cystic duct variations and, eventually, aid in reducing the occurrence of surgical problems during the operations.

CONCLUSION

The easy to understand non-invasive MRCP technique might be used to detect variations in the pancreatic duct, reducing the likelihood of problems during surgical treatments.

Disclaimer (Artificial intelligence)

Option 1:

Author(s) hereby declare that NO generative AI technologies such as Large Language Models (ChatGPT, COPILOT, etc.) and text-to-image generators have been used during the writing or editing of this manuscript.

Option 2:

Author(s) hereby declare that generative AI technologies such as Large Language Models, etc. have been used during the writing or editing of manuscripts. This explanation will include the name, version, model, and source of the generative AI technology and as well as all input prompts provided to the generative AI technology

Details of the AI usage are given below:

- 1.
- 2.
- 3.

Consent

As per international standards or university standards, patient(s) written consent has been collected and preserved by the author(s).

REFERENCES

1. Taştumur Y. Anatomical Variations of the Cystic Duct in Turkish Population and their Association with Biliary Track Stone. *J Col Physician Surgeon Pak.* 2020 Oct;1;30(10):1005-8.
2. Sarawagi R, Sundar S, Gupta SK, Raghuwanshi S. Anatomical variations of cystic ducts in magnetic resonance cholangiopancreatography and clinical implications. *Radiol Res Pract.* 2016 Jan 1;2016.
3. Sherifi F, Bajraktari I, Bexheti S, Lahu A, Gashi Z, Shatri J. Anatomic variations of the cystic duct assessed by magnetic resonance cholangiopancreatography. *Italian J AnatomEmbryol.* 2018 Nov 23;123(2):158-64.
4. Zhang L, Yang YY, Zhang L, Gao LC, Wang ZD, Jiang GJ, Gao M. The Value and Discussion of Cystic Duct Variation Diagnosed by MRCP. *J Kunm Med Uni.* 2018 Jan 1;39(6):109-12.

5. Gupta A, Rai P, Singh V, Gupta RK, Saraswat VA. Intrahepatic biliary duct branching patterns, cystic duct anomalies, and pancreas divisum in a tertiary referral center: A magnetic resonance cholangiopancreatographic study. *Ind J Gastroenterol*. 2016 Sep 1;35(5):379-84.
6. Yu J, Turner MA, Fulcher AS, Halvorsen RA. Congenital anomalies and normal variants of the pancreaticobiliary tract and the pancreas in adults: part 1, biliary tract. *Am J Roentgenol*. 2006 Dec;187(6):1536-43
7. George RA, Debnath J, Singh K, Satija L, Bhargava S, Vaidya A. Low insertion of a cystic duct into the common bile duct as a cause for a malpositioned biliary stent:demonstration with multidetector computed tomography. *Singapore Med J*. 2009;50(7):e243-46.
8. D'Angelo T, Racchiusa S, Mazziotti S, Cicero G. Magnetic Resonance (MR) Cholangiopancreatography Demonstration of the Cystic Duct Entering the Right Hepatic Duct. *Am J Case Rep*. 2017;18:242-45.
9. Mortele KJ, Rocha TC, Streeter JL, Taylor AJ: Multimodality imaging of pancreatic and biliary congenital anomalies. *Radiographics*, 2006; 26: 715–31
10. Turner MA, Fulcher AS: The cystic duct: Normal anatomy and disease processes. *Radiographics*, 2001; 21: 3–22
11. Benson EA, Page RE: A practical reappraisal of the anatomy of the extra-hepatic bile ducts and arteries. *Br J Surg*, 1976; 63: 853–60
12. Sherifi F, Bajraktari I, Bexheti S, Lahu A, Gashi Z, Shatri J. Anatomic variations of the cystic duct assessed by magnetic resonance cholangiopancreatography. *Ital J Anat Embryol*. 2018;1232):158-64
13. Taourel P, Bret PM, Reinhold C, Barkun AN, Atri M. Anatomic variants of the biliary tree: diagnosis with MR cholangiopancreatography. *Radiology* 1996;199:521-7.
14. Ochiai T, Yamazaki S, Ohta K. Is drip infusion cholecystocholangiography (DIC) an acceptable modality at cholecystectomy for cholecystolithiasis, considering the frequency of bile duct maljunction and intraoperative bile duct injury? *J Hepatobiliary Pancreat Surg* 2004; 11:135-9.
15. Hirao K, Miyazaki A, Fujimoto T, Isomoto I, Hayashi K. Evaluation of aberrant bile ducts before laparoscopic cholecystectomy: helical CT cholangiography versus MR cholangiography. *Am J Roentgenol* 2000; 175:713-20.

16. Tsitouridis I, Lazaraki G, Papastergiou C, Pagalos E, Germanidis G. Low conjunction of the cystic duct with the common bile duct: does it correlate with the formation of common bile duct stones? *Surg Endosc* 2007; 21:48-52.
17. Ishaque I, Ilyas A, Khan O, Kazmi QH, Ladak AH, Rafay A. Role of magnetic resonance cholangiopancreatography (MRCP) in learning anatomical variations in pancreatic duct. *Pak Med Assoc.* 2020;70:472-76
18. Griffin N, Charles-Edwards G, Grant AL. Magnetic resonance cholangiopancreatography: the ABC of MRCP. *Insights Imag.* 2012;3:11-21.
19. Önder H, Özdemir MS, Tekbaş G, Ekici F, Bilici A. 3-T MRI of the biliary tract variations. *Surg Radiol Anat.* 2013;35:161-167.
20. Mortelé KJ, Ros PR. Anatomic variants of the biliary tree: MR cholangiographic findings and clinical applications. *Am J Roentgenol.* 2001;177:389-94.