

## **Disseminated lupus erythematosus: neurological manifestations in childhood: a case series of two patients**

### **Abstract :**

Neuropsychiatric lupus encompasses the neurological and psychiatric manifestations of systemic lupus erythematosus and presents a significant diagnostic challenge due to its broad clinical variability. Affecting between 14% and 75% of lupus patients, it can occur at any stage of the disease. We present two illustrative pediatric cases compiled in a pediatric nephrology unit:

Case 1: A young girl with pericarditis, cognitive impairment, and persistent headaches at the time of diagnosis.

Case 2: A boy with prolonged fever, whose disease evolution revealed neuropsychiatric lupus through the onset of visual disturbances, upper limb muscle weakness, and headaches.

These cases highlight the necessity for heightened clinical vigilance in children with lupus to allow for early detection of neurological complications.

### **Introduction:**

Systemic lupus erythematosus (SLE) is an autoimmune disease of varying severity, depending on the organ involved and disease activity, resulting in clinical polymorphism and characterized by the production of antinuclear antibodies, particularly anti-native DNA antibodies.

The neuropsychiatric manifestations of systemic lupus erythematosus (SLE) are clinically and therapeutically heterogeneous, grouped under the term neuropsychiatric lupus (NPL).

The objective of our work is to determine when neurological and neuropsychological manifestations can be attributed to lupus and how best to manage them.

### **Case 1:**

This is a 15-year-old girl with no family history of autoimmune diseases, born to first-degree consanguineous parents who are in good health. The illness began 1 month before her admission to the hospital with memory problems, headaches, polyarthralgia, alopecia, and malar rash. The condition progressed with abdominal distension, dyspnea, chest pain, fever, and general malaise. Clinical examination revealed a dyspneic, pale, febrile child with a heart rate of 120 bpm, muffled heart sounds, moderate ascites, pleural effusion, and lower extremity edema.

Laboratory tests showed anemia, lymphopenia, thrombocytopenia, elevated C-reactive protein, increased erythrocyte sedimentation rate, a positive direct Coombs test, hypoalbuminemia, hypocomplementemia, normal renal function with proteinuria. Chest X-ray revealed cardiomegaly and pleural effusion. Echocardiography showed a large pericardial effusion, dilated inferior vena cava, and moderate to severe mitral regurgitation, confirming the diagnosis of cardiac tamponade. Urgent pericardial drainage was performed. Cultures of the pericardial fluid were negative for bacteria and acid-fast bacilli. Cytological examination of the fluid did not show any neoplastic cells.

Immunological tests revealed the presence of anti-DNA, anti-nucleosome, and anti-histone antibodies. Anti-Sm antibodies were negative. A renal biopsy revealed class IV lupus nephritis with an activity index of 6 and a chronicity index of 2. Ophthalmological examination was normal. A diagnosis of systemic lupus erythematosus was made.

The patient was treated with methylprednisolone boluses followed by oral prednisone with good clinical response and complete resolution of the pericardial effusion. Three months later, the patient presented with memory problems and slowed thinking. Brain MRI showed diffuse moderate widening of the cortical sulci and demyelinating lesions of the deep white matter, consistent with lupus. A repeat renal biopsy confirmed class IV lupus nephritis, leading to the initiation of immunosuppressive therapy with monthly cyclophosphamide boluses for 6 months, followed by oral azathioprine and hydroxychloroquine.

The patient has been under regular follow-up care with a one-year retrospective.

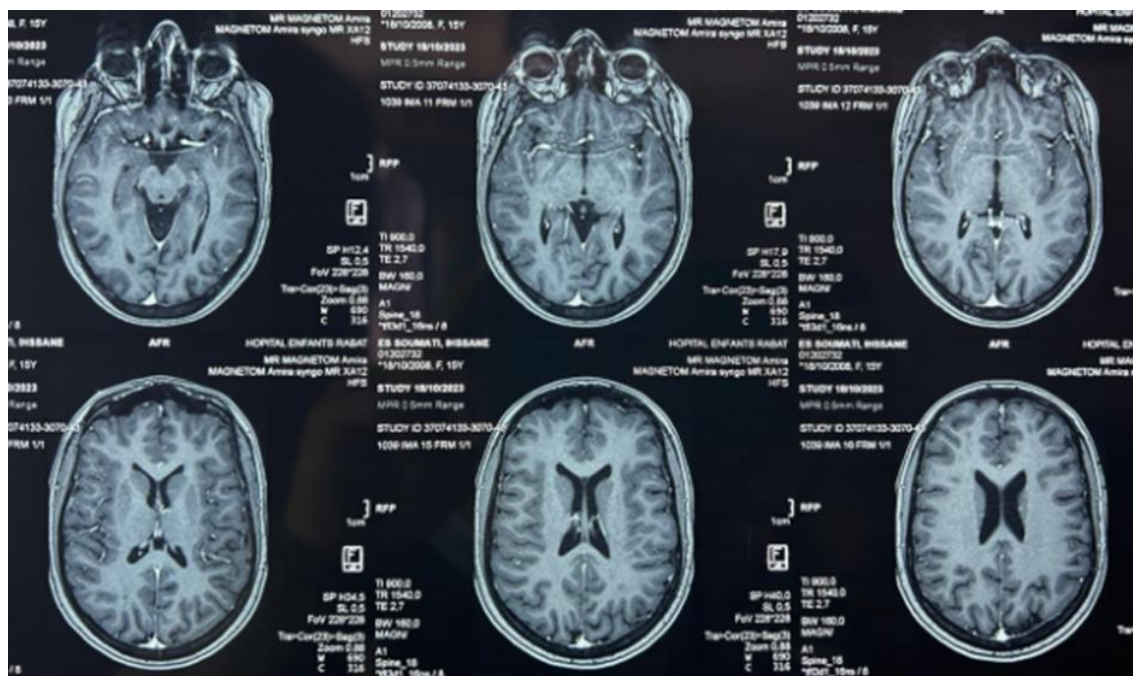


Figure 1: A transverse MRI scan of the brain, post-gadolinium injection, reveals diffuse moderate widening of the cortical sulci and demyelinating lesions in the deep white matter

## Case 2:

This is a 14-year-old child with no family history of autoimmune diseases, born to non-consanguineous healthy parents. The illness began 1 month ago with asthenia, polyarthralgia, and abdominal pain in the context of a fever of 38.5°C, persistent, band-like headache, and general malaise. Clinical examination revealed an asthenic, pale, febrile child with a heart murmur at the mitral area, a pink nail bed, and unremarkable skin, mucous membrane, and neurological examinations. A CT scan showed left pleural effusion, peritoneal fluid in the right paracolic gutter, and bilateral axillary and inguinal lymphadenopathy.



In 1999, the American College of Rheumatology (ACR) established a comprehensive classification of the neurological manifestations of systemic lupus erythematosus (SLE), grouped under the term "neurolupus" or "neuropsychiatric systemic lupus erythematosus" (NPSLE). Table 1 includes 12 central nervous system (CNS) and 7 peripheral nervous system (PNS) manifestations, providing a standardized framework for describing and recognizing the various neurological and psychiatric complications associated with SLE (3,4, 5).

Central Nervous System Manifestations	Peripheral Nervous System Manifestations
<ol style="list-style-type: none"> <li>1. Headaches</li> <li>2. Mood disorders (depression)</li> <li>3. Anxiety disorders</li> <li>4. Psychosis</li> <li>5. Cognitive dysfunction</li> <li>6. Epilepsy</li> <li>7. Cerebrovascular manifestations</li> <li>8. Myelopathy</li> <li>9. Demyelinating syndrome</li> <li>10. Acute confusional state</li> <li>11. Abnormal movements</li> <li>12. Aseptic meningitis</li> </ol>	<ol style="list-style-type: none"> <li>1. Cranial nerve involvement</li> <li>2. Polyneuropathy</li> <li>3. Dysautonomia</li> <li>4. Mononeuropathy</li> <li>5. Myasthenia gravis</li> <li>6. Guillain-Barré syndrome</li> <li>7. Plexopathy</li> </ol>

**Table 1 :** ACR classification of neuropsychiatric manifestations in systemic lupus erythematosus (3).

Unterman et al. reported a 56% prevalence of neuropsychiatric manifestations in their meta-analysis. Headaches were the most common (28%), followed by mood disorders (21%), cognitive impairments (20%), seizures (10%), stroke (8%), and anxiety (6%) (4).

Parihk et al.'s study of 108 children with lupus found that 25% experienced neurological manifestations. These occurred before diagnosis in 4%, at diagnosis in 15%, and after diagnosis in 26%. All patients had headaches, 56% had behavioral changes (depression, confusion), 25% had chorea, and 19% reported visual loss (6).

Both patients experienced persistent headaches. The girl had cognitive impairments and depression at diagnosis, whereas the boy developed decreased visual acuity over time.

### **Paraclinical tests :**

In the management of neuropsychiatric manifestations of lupus, the recommended examinations include, blood test, conventional brain MRI, Cerebro-spinal fluid analysis, MRS spectroscopy, and brain PET.

#### **✓ Blood tests :**

here is no specific blood test to diagnose neuro-lupus. However, alongside relevant clinical signs of the disease itself, various blood tests may be useful. A complete blood count can help detect hematologic involvement; tests for C3 and C4 consumption, TPHA-VDRL serology, anti-native DNA antibodies, anti-Sm antibodies, and antiphospholipid antibodies can confirm the disease. However, three types of antibodies seem particularly involved in central nervous system involvement in NPSLE: antiphospholipid, anti-N-methyl-D-aspartate receptor, and anti-ribosomal antibodies (7).

✓ **Brain MRI :**

is the gold standard for evaluating central nervous system involvement in lupus, including cerebral, spinal cord, vascular, and inflammatory lesions. T2 hyperintensities are commonly found in the periventricular and subcortical white matter, particularly in the frontal and parietal lobes (8,9). FLAIR sequences enhance the detection of these T2 hyperintensities, especially in periventricular and subcortical regions.

Although white matter hyperintensities are frequently observed in patients with neuropsychiatric manifestations, the cause-and-effect relationship is not always established. Studies have shown that certain morphological and signal characteristics of hyperintensities (number, size, association with other lesions, intensity, contours) could be risk factors for the development of neuropsychiatric symptoms, but these results remain to be confirmed by larger studies (10).

Hyperintensities in the gray matter (cortex and basal ganglia) suggest a direct neuronal damage by antineuronal autoantibodies (4).

Lacunar infarcts are found in 21% to 60% of patients with neurolupus (11).

Our patients' MRI findings are consistent with previous studies.

✓ **Cerebrospinal fluid analysis :**

is crucial to exclude viral or bacterial meningitis or meningoencephalitis in immunosuppressed children with lupus (12), although aseptic lupus meningitis should be considered.

✓ **EEG (electroencephalogram):**

**It is considered a very sensitive but non-specific examination for cerebral lupus, showing abnormalities even in the most subtle neuropsychiatric manifestations. Some researchers have noted more focal abnormalities with selective involvement of the left temporal or temporolimbic regions (13).**

✓ **Magnetic Resonance Spectroscopy (MRS) :**

By identifying and quantifying the amounts of different molecules in the brain, this technique reveals abnormalities invisible to conventional MRI exams. The analysis focuses on biomarkers such as N-acetylaspartate (NAA), total choline (including its different components), myo-inositol, and creatine. Creatine, present at a relatively constant level in glial and neuronal cells, serves as an internal reference to normalize the concentrations of other metabolites and allow for inter-individual comparisons (8).

Brooks et al. demonstrated that the reduction of NAA was associated with neuronal loss, thus confirming its role as a marker of neuronal integrity in the context of neurolupus (12).

The decrease in NAA is reversible in some cases, indicating a possible recovery of neurons. Nevertheless, it can also be the sign of future neuronal degradation, detectable by MRI (10,14).

While the release of choline, resulting from demyelination processes, is an indirect marker of membrane alteration. Although not specific to the severity of the lesion, the elevation of choline levels is correlated with an increase in gliosis, vasculitis, and tissue edema, suggesting ongoing pathological activity (12).

However, these abnormalities can be found in other neurodegenerative diseases such as Alzheimer's and multiple sclerosis (12,14).

✓ **Brain single-photon emission computed tomography (SPECT) :**

"Brain SPECT, by assessing cerebral perfusion, demonstrates increased sensitivity in detecting brain lesions related to lupus, particularly in deep brain regions. Focal hypoperfusions are frequently observed, even in the absence of lesions visible on MRI, and are often associated with disease activity. The clinical resolution of these abnormalities suggests a close link with pathological activity (14,15).

**Neurolyupus treatment:**

The therapeutic management of neurolyupus is complex and based on an individualized approach. Mild or nonspecific manifestations benefit from standard symptomatic treatment. Severe inflammatory and autoimmune manifestations require immunosuppression, the choice and duration of which are determined by the severity of the disease and the therapeutic response. Corticosteroids and immunosuppressants are first-line treatments, although scientific literature data is limited.

✓ **Corticosteroid therapy :**

is the first-line treatment for inflammatory neurological manifestations of lupus. The EULAR recommendations specify the administration modalities and dosages according to the different clinical manifestations. Bolus corticosteroids (at a dose of 7.5 to 15 mg/kg for 3 consecutive days followed by oral administration at a dose of 1 mg/kg) are particularly indicated in severe forms and spinal cord involvement. The combination of corticosteroids and immunosuppressants may be considered in refractory cases or in cases of significant systemic activity (16,17).

✓ **Cyclophosphamide :**

In a 2005 study by Barile-Fabris et al., two treatments for neurolyupus were compared: monthly then trimonthly cyclophosphamide for a year, and monthly methylprednisolone boluses for four months, followed by every two and then three months. All patients initially received methylprednisolone. While both treatments improved symptoms initially, cyclophosphamide was more effective in maintaining this improvement long-term. Patients on methylprednisolone had more frequent relapses as bolus frequency decreased (18).

Dosing is not standardized. By analogy with renal involvement, a dose of 500 to 700 mg/m<sup>2</sup> (with a maximum of 1200 mg) every four weeks for six months can be considered, adjusting the dose according to the patient. Maintenance therapy is then essential to prevent relapses with alternating steroids (10-20 mg of prednisolone every other day) and substituting azathioprine (2 mg/kg/day) for methotrexate (initial dose of 7.5 mg/week, increased or decreased by 2.5 mg/week depending on response or side effects; maximum 20 mg/week) can be instituted for an additional minimum of 10 months, depending on the response, followed by a gradual withdrawal (17).

Mycophenolate and cyclosporine can be as effective as methotrexate and azathioprine. Case reports and small studies suggest intravenous immunoglobulins and thalidomide may be beneficial for some patients (19).

✓ **Rituximab:**

EULAR experts consider rituximab as a second-line therapeutic option for patients suffering from confusional states, psychoses, or myelites who do not respond to conventional treatments (18.20).

Our patients were started on methylprednisolone boluses followed by oral administration, then placed on monthly intravenous cyclophosphamide boluses for six months, followed by azathioprine according to the EULAR protocol, with good clinical and biological outcome

**Conclusion:**

Systemic lupus erythematosus (SLE) is an autoimmune disease that is more common in adults than in children. Neuro-lupus is characterized by significant clinical heterogeneity, making its diagnosis challenging. Indeed, the diversity of pathophysiological mechanisms underlying neuro-lupus results in a variety of neurological and psychiatric symptoms. Diagnosis relies on a multidisciplinary approach, combining medical history, clinical examination, additional tests (brain/spinal MRI), and lupus-specific biological data. Treatment is determined based on the severity of each symptom and the assessment of their causal link with lupus.

**Consent**

As per international standards, parental written consent has been collected and preserved by the author(s).

**Disclaimer (Artificial intelligence)**

Option 1:

Author(s) hereby declare that NO generative AI technologies such as Large Language Models (ChatGPT, COPILOT, etc.) and text-to-image generators have been used during the writing or editing of this manuscript.

Option 2:

Author(s) hereby declare that generative AI technologies such as Large Language Models, etc. have been used during the writing or editing of manuscripts. This explanation will include the name, version, model, and source of the generative AI technology and as well as all input prompts provided to the generative AI technology

Details of the AI usage are given below:

- 1.
- 2.
- 3.

**References :**

1. PLATT JL, BURKE BA, FISH AJ, KIM Y, and al. Systemic lupus erythematosus in the first two decades of life(1982).. *Am J Kidney Dis*, 11: S212-S222.
2. KORNREICH H. . Systemic lupus erythematosus in childhood.*Clin Rheum Dis*, 2: 429-443.
3. The American College of Rheumatology nomenclature and case definitions for neuropsychiatric lupus syndromes. *Arthritis Rheum* 1999;42:599–608
4. Unterman A, Nolte JE, Boaz M, Abady M, and al. Neuropsychiatric syndromes in systemic lupus erythematosus: a metaanalysis.*Semin Arthritis Rheum* 2010.
5. Olfat MO, Al-Mayouf SM, Muzaffer MA. Pattern of neuropsychiatric manifestations and outcome in juvenile systemic lupus erythematosus. *Clin Rheumatol* 2004;23:395–9.
6. Parikh, S., Swaiman, K. F., & Kim, and al . Neurologic characteristics of childhood lupus erythematosus. *Pediatric Neurology*, 13(3), 198–201. doi:10.1016/0887-8994(95)00186-j
7. S. Madrane , C. Ribl, Service d'immunologie clinique et d'allergologie HUG, 1211. *Rev Med Suisse* 2012 ; 8 : 848-53
  
8. Jennings JE, Sundgren PC, Attwood J, McCune J, Maly P. Value of MRI of the brain in patients with systemic lupus erythematosus and neurologic disturbance.*Neuroradiology* 2004;46:15–21.
9. Sibbitt Jr WL, Sibbitt RR, Brooks WM. Neuroimaging in neuropsychiatric systemic lupus erythematosus. *Arthritis Rheum* 1999;42:2026–38.
10. Ainiala H, Dastidar P, Loukkola J, Lehtimaki T, Korpela M, Peltola J, et al. Cerebral MRI abnormalities and their association with neuropsychiatric manifestations in SLE: a population-based study. *Scand J Rheumatol* 2005;34:376–82.
11. Jung RE, Segall JM, Grazioplene RG, Qualls C, and al. Cortical thickness and subcortical gray matter reductions in neuropsychiatric systemic lupus erythematosus. *PLoS One* 2010;5:e9302.
12. Calabrese LH, Molloy ES, Huang D, Ransohoff RM. Progressive multifocal leukoencephalopathy in rheumatic diseases: evolving clinical and pathologic patterns of disease. *Arthritis Rheum* 2007;56:2116–28.
13. Joseph, F. G., Scolding, N. J. and al (2010). Neurolupus. *Practical Neurology*, 10(1), 4–15. doi:10.1136/jnnp.2009.200071 10.1136/jnnp.2009.200071
14. Brooks WM, Sibbitt Jr WL, Kornfeld M, Jung RE, Bankhurst AD, Roldan CA. The histopathologic associates of neurometabolite abnormalities in fatal neuropsychiatric systemic lupus erythematosus. *Arthritis Rheum* 2010;62:2055–63.
15. Appenzeller S, Li LM, Costallat LT, Cendes F. Evidence of reversible axonal dysfunction in systemic lupus erythematosus: a proton MRS study. *Brain* ,2005;128:2933–40.
16. Zhang X, Zhu Z, Zhang F, Shu H, Li F, and al. Diagnostic value of singlephoton-emission computed tomography in severe central nervous system involvement of systemic lupus erythematosus: a case-control study. *Arthritis Rheum* 2005;53:845–9.
17. Lopez-Longo FJ, Carol N, Almoguera MI, Olazaran J, and al. Cerebral hypoperfusion detected by SPECT in patients with systemic lupus erythematosus is related to clinical activity and cumulative tissue damage.*Lupus* 2003;12:813–9.

18. Baca V, Lavalle C, Garcia R, Catalan T, and al. Favorable response to intravenous methylprednisolone and cyclophosphamide in children with severe neuropsychiatric lupus. *J Rheumatol* 1999;26:432–9.
19. Bertsias GK, Ioannidis JP, Aringer M, Bollen E, and al. EULAR recommendations for the management of systemic lupus erythematosus with neuropsychiatric manifestations: report of a task force of the EULAR standing committee for clinical affairs. *Ann Rheum Dis* 2010;69:2074–82
20. Barile-Fabris L, Ariza-Andraca R, Olguin-Ortega L, Jara LJ, and al. Controlled clinical trial of IV cyclophosphamide versus IV methylprednisolone in severe neurological manifestations in systemic lupus erythematosus. *Ann Rheum Dis* 2005;64:620–5.