

Original Research Article

Pathogenesis of pyometra: Treatment and diagnosis



Abstract

Pyometra refers to an acute or persistent suppurative inflammation of the uterine wall. A six-year-old Persian cat was admitted to Pet Hospital, with history of anorexia and chronic emaciation. During abdominal examination, the uterus felt larger and firmer than usual. Then ultrasonography examination was done and it revealed anechoic multiple pus pockets. Blood analysis showed that the level of AST, ALT, urea, creatinine increased, and PCV and Hb% decreased. All the findings confirmed that cat had suffering from pyometra. After confirmation, it was decided to do ovariohysterectomy under general anaesthesia. The suture was removed after fourteen days. The cat had a complete recovery without any complication.

Key words: Queen, Pyometra, Ultrasonography, Ovariohysterectomy

1. Introduction

Pyometra is a uterine inflammatory disease that is characterized by ascending vaginal bacterial infection and cystic endometrial hyperplasia (CEH), which is the result of progesterone stimulating the endometrium. It has been reported that cats older than five years old are more likely to contract the disease than kittens. Cats who have had one or more litters have also reported experiencing it[6].

Depression, anorexia or inappetence, vomiting, diarrhea, listlessness, abdominal distention, polyuria, and polydipsia are typical clinical symptoms. A sanguineous to mucopurulent discharge from the vulva is recorded in cases of cervical dilatation[9].

Repeated exposure to progesterone during the luteal phase of the estrus cycle results in the development of pyometra. Progesterone reduces muscle activity, inhibits leukocyte function, and encourages gland growth and mucus secretion in the uterus to create an environment that is favorable for fetal development. Due to the fact that most cats with pyometra have CL in their ovaries[1].

In a case of pyometra, abdominal ultrasonography is the most crucial diagnostic tool. Usually, there is a distention of the uterine horns with hypo- to hyperechoic fluid that may or may not

be flocculating. The uterine wall frequently has irregular edges, a thicker appearance, and small hypoechoic areas that are indicative of endometrial gland cystic changes. Phagocytized bacteria and diffuse or segmental neutrophils can make up the pyometra. Leukopenia may be evident in approximately 5% of cases[13].

The complex pathogenesis of pyometra is not yet completely understood but involves both hormonal and bacterial factors. Although most studies have been done in dogs, the development is believed similar in cats. The uterine environment during the luteal phase is suitable for pregnancy but also for microbial growth. Progesterone stimulates growth and proliferation of endometrial glands, increased secretion, cervical closure, and suppression of myometrial contractions[3].

Vaginal discharge may be observed along with mild, nonspecific clinical signs in cases of open pyometras. Nonetheless, sepsis, peritonitis, and even animal death can happen in closed pyometra[4].

2. Materials and Methods

In the present study, the cat was diagnosed clinically with pyometra. On physical examination, body temperature found 103°F, heart rate 164 beats per minute and respiratory rate 38 breaths per minute. On abdominal ballottement the uterus felt harder and enlarged than normal. Diagnosis of pyometra was confirmed based on the presence of clinical signs (anorexia, lethargy, vomiting, abdominal distention, and vulvar discharge) and ultrasonographical findings. Trans-abdominal ultrasonography was performed using a B-mode real-time ultrasound scanner. A 7.5 MHz linear array transducer were used to confirm the diagnosis. Haematology and serum AST, ALT, ALP, BUN and Creatinine levels were evaluated.

2.1. Anaesthesia

As muscle relaxant xylazine hydrochloride (Injection xylazine 1mg/ kg BW intramuscularly) administered and as a general anaesthesia ketamine hydrochloride 20mg/Kg body weight intravenously) was administered. The maintenance anaesthetic dose was given half of the initial dose during the surgery. Preparation of surgical area was carried out after shaving and removing hairs. 70% alcohol scrubbed onto the skin around the surgery area, the area is then covered until surgery, since nothing must touch it once.

2.2. Surgical Procedure

Close monitoring of temperature, heart rate, gum colour, pulse strength and depth of anaesthesia was done. An incision was made in the middle of the underside along the length of the abdomen. After exposing the abdomen by laparotomy, the uterine and ovarian blood vessels were properly secured and the ovaries, uterine horns and uterus were completely removed. The abdominal wall was closed with catgut (size: 1-0) and skin was closed by simple continuous pattern using silk.

3. Results and Discussion

Depression, dehydration, fatigue, pyrexia, anorexia, or inappetence, vomiting, diarrhoea, listlessness, distention of the abdomen, polyuria, polydipsia, and weight loss were noted as typical clinical signs. The only cats that have a viscous, watery, or thick vulvar discharge are those who have open pyometra. Usually, the discharge has a creamy, light tan-pink to dark brown[4]. Any age can be used to diagnose pyometra. According to descriptions, the disorder is more common in cats who have had one or more litters and is more common in cats over the age of five who have never given birth to kittens[3, 4].

According to the current study, the cat's haemoglobin level was lower before treatment, indicating anaemia, which is consistent with earlier reports of [12, 5]. This may be caused by red blood cell loss through diapedesis into the uterine lumen in addition to decreased feed intake and impaired erythropoiesis in cases with severe toxemia[11].

Before treatment, the total erythrocyte count in the pyometra-affected bitches was lower, suggesting anaemia similar to what was found in this study. While severe non-regenerative, microcytic, hypochromic anaemia with very high white blood cell counts may indicate concurrent blood loss from diapedesis into luminal pus and from shortened life span of circulating erythrocytes associated with iron deficiency, it may also be linked to the toxic depression of the bone marrow[7].

Among the bitches affected with pyometra the absolute neutrophilia, lymphopenia, and monocytosis with normal eosinophil count was the most consistent finding. The regenerative shift to the left in neutrophilia may be caused by the retention of purulent exudates in the uterus, which chemotactically affects neutrophils and accelerates granulopoiesis. Severe stress may also be the cause of lymphopenia, and a chronic suppurative process may be the cause of elevated monocyte counts[8].

Septicaemia caused hepatocellular damage, which in the dehydrated cats led to reduced hepatic circulation and cellular hypoxia. In this investigation, a process of inhibition of liver enzyme synthesis or potential damage to the hepatic membrane can account for the decreased ALT result. Secondary renal dysfunction linked to bacterial endotoxin to pyometra may occur. Dehydration may be the cause of the elevated blood urea nitrogen and creatinine concentrations in this instance[2, 9].

Although the cause of cats' higher death rate is unknown, one theory is that they are less susceptible to endotoxins or are less likely to exhibit clinical symptoms until they have sepsis[10]. This study, which is nearly identical to the [5] study, used xylazine hydrochloride and ketamine hydrochloride to perform an ovariohysterectomy while the patient was under general anaesthesia.

Table 1: Haematological findings of cat pyometra

Haematological parameters	Results	Reference value
Total RBC	5.1	05-10
Total WBC	3.9	5.5-19.5
HB (%)	4.9	9.8-15.4
PCV (%)	17	29-45
MCV (fl)	56	41-54
MCHC (pg)	20	31-36
Neutrophil (%)	82	35-75
Lymphocyte (%)	22	27-36
Monocyte (%)	01	00-05
Basophil (%)	00	00-01
Eosinophil (%)	01	00-04

Biochemical Parameters	Results	Reference value
AST	34	7-38
ALT	96	25-97
Urea	38	19-34
Creatinine	3.4	0.9-2.2

Table 2: Biochemical findings of cat pyometra

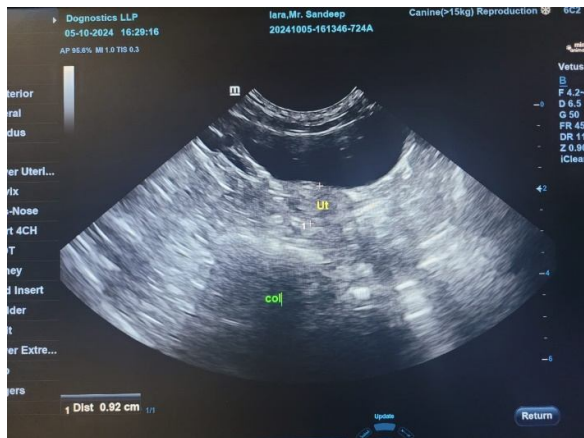

Fig 1: Upon USG of Queen pyometra, Anechoicfluid filled pocket in uterus found

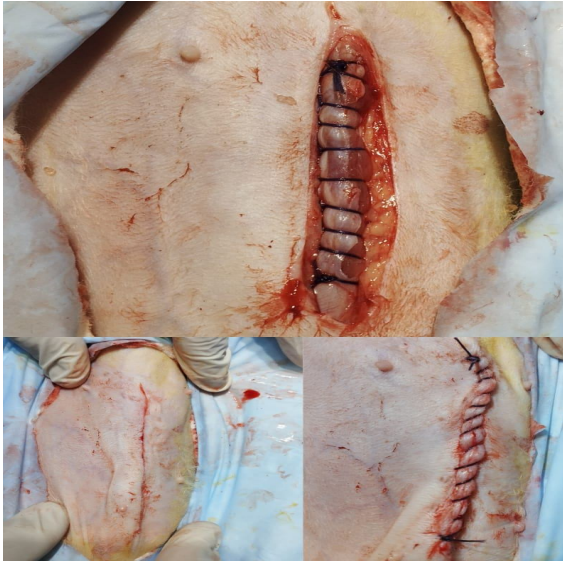


Fig 2: Suturing of abdomen after ovariohysterectomy

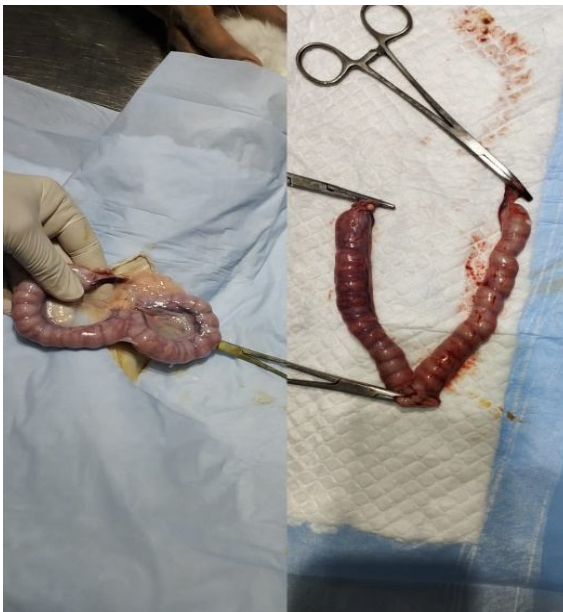

Fig 3: Queen pyometra uterus

4.Conclusion: By the outcomes of the present study, we can conclude that Ovariohysterectomy is the best method for treating chronic pyometra in queens.

References:

1. Dow C. The cystic hyperplasia-pyometra complex in the cat. *Veterinary Research*. 1962;74, pp.141-147.

2. Egenvall A, Hagman R, Bonnett BN, Hedhammar A, Olson P, Lagerstedt AS. Breed risk of pyometra in insured dogs in Sweden. *Journal of veterinary internal medicine.* 2001;15(6), pp.530-538.
3. Hagman R, Holst BS, Möller L, Egenvall A. Incidence of pyometra in Swedish insured cats. *Theriogenology.* 2014;82(1), pp.114-120.
4. Hagman R. Pyometra in small animals. *Veterinary Clinics: Small Animal Practice,* 2018;48(4), pp.639-661.
5. Hasan T, Hossain MM, Tahsin N, Hossain MA, Uddin AM. Pyometra in a Cat: A Clinical Case Report. *Biomedical Journal of Scientific & Technical Research.* 2021;37(5), pp.29851-29856.
6. Johnston SD, Kustritz MV, Olson PS. *Canine and feline theriogenology.* 2001.
7. Kashi N, Tiwari SK, Kalim MO. Physiological and haematological changes in bitches with pyometra. *Indian Veterinary Journal.* 2009;86(7), pp.734-736.
8. Miller MA, Ramos-Vara JA, Dickerson MF, Johnson GC, Pace LW, Kreeger JM, Turnquist SE, Turk JR. Uterine neoplasia in 13 cats. *Journal of veterinary diagnostic investigation.* 2003;15(6), pp.515-522.
9. Nak D, Misirlioglu D, Nak Y, Keskin A. Clinical laboratory findings, vaginal cytology and pathology in a controlled study of pyometra in cats. *Australian Veterinary Practitioner,* 2005;35(1), pp.10-14.
10. Pande N, Prabhakar S, Gandotra VK, Honparkhe M, Nanda AS. Efficacy of different techniques for diagnosis of pyometra in female dogs. *The Indian Journal of Animal Reproduction.* 2006;27(1), pp.31-33.
11. Payan Carreira R, Saraiva AL, Santos T, Vilhena H, Sousa A, Santos C, Pires MA. Feline endometrial adenocarcinoma in females < 1 year old: a description of four cases. *Reproduction in Domestic Animals.* 2013;48(5), pp.e70-e77.
12. Sontas BH, Erdogan Ö, Apaydin Enginler SÖ, Yilmaz ÖT, Şennazli G, Ekici H. Endometrial adenocarcinoma in two young queens. *Journal of small animal practice.* 2013;54(3), pp.156-159.
13. Verstegen J, Onclin K. The mucometra-pyometra complex in the queen. In *Proceedings of the North American Veterinary Conference.* 2006; pp. 7-11.