

Short communication

The spectrum of kidney biopsy findings in HIV-infected patients

Abstract

Renal impairment during human immunodeficiency virus (HIV) infection is a frequent occurrence, attributed to the infection itself or sometimes to antiretroviral therapy. It is a major factor in morbidity and mortality. The impact of renal histology on treatment choices highlights the importance of histological diagnosis in HIV-positive patients with renal impairment. This was a retrospective descriptive study carried out in the nephrology department of the Ibn Rochd University Hospital in Casablanca between January 2019 and December 2022 on renal biopsy punctures performed in HIV-infected patients. Our study included 19 patients who met the above criteria. Histological findings were dominated by focal segmental glomerulosclerosis (FSGS) (42.1%) and extramembranous glomerulonephritis (36.8%). Tubulointerstitial nephritis was observed in three patients and one patient had IgA nephropathy. The incidence of renal impairment in HIV infection is increasing. These patients should be systematically screened for potentially reversible nephropathy if treatment is initiated in time. This highlights the importance of close collaboration between nephrologists and infectious diseases specialists in the management and follow-up of these patients.

Keywords : HIV infection, renal biopsy puncture, histological diagnosis, focal segmental glomerulosclerosis (FSGS)

Introduction

HIV infection is a major cause of morbidity and mortality worldwide. Once fatal, it is now classified as a chronic disease, thanks to easier access to antiretroviral treatment. It affects several organs, including the kidney. More recent epidemiological studies confirm the high incidence of kidney damage: from 15.5 to 38% of cases. (1 ; 2) There are many clinical and pathological aspects to kidney disease. They range from the usual causes to nephropathy directly induced by HIV. The risk factors for kidney disease identified in the literature include age, high viral load, low CD4 count, co-infection with hepatitis C virus (HCV), sub-Saharan origin, diabetes and hypertension (3). The main aim of our work was to shed light on renal damage in HIV-infected patients based on histological data from their renal biopsy punctures.

Patients and methods

Study design

This was a single-centre retrospective study conducted in the nephrology, dialysis and transplantation department of the Ibn Rochd University Hospital of Casablanca, from January 2019 to December 2022.

Demographic, Clinical, biological and histological data were collected from patient's medical records and from registers of renal biopsy punctures.

Inclusion criteria

All HIV-infected patients who underwent renal biopsy at our facility during the above-mentioned period.

Exclusion criteria

Patients with missing data were excluded.

Data collection

Demographic data including age, ethnicity, sex and duration of HIV infection were collected from medical records. Biological results were also collected, in particular plasma creatinine, 24-hour proteinuria, albuminemia and protidemia.

Statistical analysis was carried out using STATA 15.1 software.

Results

19 patients were included in our study. Anthropometric and biological data are summarized in Tables 1 and 2.

Age (years)	37±12
Male (%)	47.3
Length of time of the HIV infection (months)	45.9 ± 47.5
Past Medical History	
Hypertension	2
Diabetes mellitus	2
Cardiovascular disease	1
History of tobacco use	5
Substance abuse	2
Hepatitis C–virus coinfection	1
On antiretroviral therapy	15

Table 1 : Patient characteristics

The mean age was 37 ± 12 years, and 47.3% were male. The mean age of infection before the kidney disease was 45.9 months. Comorbidities were dominated by smoking in five patients.

The mean proteinuria was 3.41g/24h. The mean plasma creatinine 32mg/l.

Serum creatinine (mg/l)	32 ± 12,8
eGFR (ml/min/1,73 m ²)	20.9 ± 16,4
Proteinuria (g/d)	3.41
Dipstick proteinuria	
0 or trace	1

1+	2
2+	4
3+	9
4+	3
Serum albumin (g/l)	31

Table 2 : Biological data

The indication for renal biopsy was mainly impure nephrotic syndrome in 55% of cases.

Histological findings were as follows:

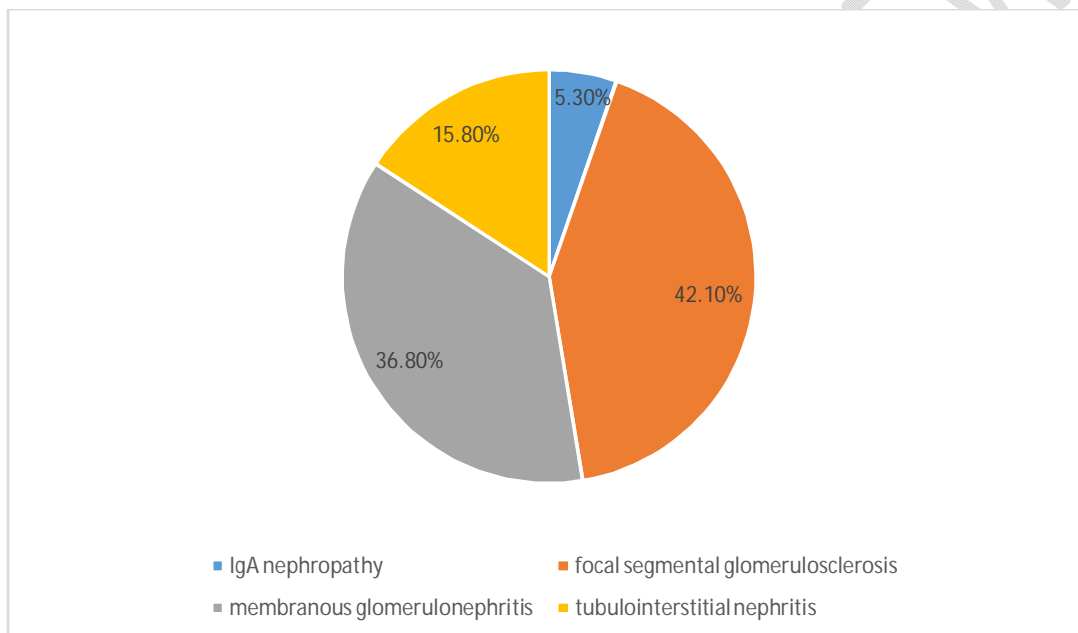


Figure 1 : Histological results

Histological findings were dominated by focal segmental glomerulosclerosis (FSGS) in 8 patients (42.1%) and extramembranous glomerulonephritis in 7 patients (36.8%). Tubulointerstitial nephritis was observed in three patients (15.8%) and one patient had IgA nephropathy (5.3%).

Discussion

Based on the 2018 estimates from the Joint United Nations Programme on HIV/AIDS (UNAIDS), approximately 37.9 million individuals globally, including both adults and children, are living with HIV infection. In the United States, around 1.1 million people are currently living with HIV, with approximately 39,000 new infections reported annually, according to the latest 2016 data. The extended lifespan and aging of this population, thanks to effective antiretroviral therapies, are contributing to a rise in the incidence of HIV-related kidney disorders and various other comorbid conditions. (4)

This study held twofold significance: First and foremost, it enabled us to determine the histological aspect of renal damage in HIV infection. Secondly, it supported the need for close collaboration between nephrologists and infectiologists in the overall management of patients living with HIV, by proposing regular monitoring of renal function with a view to detecting potentially reversible abnormalities if treated early and correctly.

Our study showed that the focal segmental glomerulosclerosis is the most common histological finding in the population of the HIV infected patients. The results in the literature were more diversified.

A biopsy cohort of 437 HIV positive patients at Columbia University Medical Center between January 1, 2010, and November 30, 2018 showed a surprising diversity. Immune complex glomerulonephritis (ICGN) and diabetic nephropathy each were more prevalent than HIV-associated nephropathy, with tenofovir nephrotoxicity, FSGS not otherwise specified (NOS), and global sclerosis (NOS) following in frequency. HIV-associated nephropathy was the most prevalent condition among patients not receiving antiretroviral therapy, with 94% of these patients being Black. The presence of FSGS (NOS) was notably associated with both Black race (68%) and antiretroviral therapy use (77%), suggesting that some cases may represent a milder form of HIV-associated nephropathy. The most frequently observed ICGNs were IgA nephropathy and membranous glomerulopathy, both of which were associated with antiretroviral therapy in over 90% of cases, followed by hepatitis C-associated proliferative ICGN. Among the 16 cases of uncharacterized ICGN with no identifiable etiology, 69% were not on antiretroviral therapy, potentially representing genuine HIV-associated immune complex kidney disease. Additionally, dual diagnoses were present in 17% of patients, highlighting the complexity of the lesions. (4).

A systematic review and meta-analysis (PROSPERO registration number CRD42016036246) was designed to assess the global and regional prevalence of chronic kidney disease (CKD) in HIV patients. Sixty-one eligible articles (n = 209,078 HIV patients) from 60 countries were selected, covering research published between January 1982 and May 2016. The overall CKD prevalence was found to be 6.4% (95% CI 5.2–7.7%) using the MDRD method, 4.8% (95% CI 2.9–7.1%) with CKD-EPI, and 12.3% (95% CI 8.4–16.7%) with the Cockcroft–Gault formula; p = 0.003 indicated a significant difference among estimators. Subgroup analysis revealed variations in prevalence by WHO region, with Africa showing the highest MDRD-based prevalence at 7.9%. The observed heterogeneity could be attributed to WHO region, the presence of comorbid hypertension and diabetes mellitus, but not to gender, hepatitis B or C coinfection, CD4 count, or antiretroviral status. (5)

This manuscript appears to be scientifically robust and technically sound for several reasons. First, it is likely based on the thorough analysis of kidney biopsy samples, providing direct and reliable histopathological data to support its findings. The use of well-established biopsy techniques ensures that the conclusions drawn are based on objective, reproducible observations. Additionally, the study likely employs a comprehensive cohort of HIV-infected patients, which increases the

statistical power and relevance of the findings. By controlling for potential confounding variables and using appropriate clinical data, the manuscript likely offers a clear understanding of the renal pathologies associated with HIV, further enhancing its credibility and scientific accuracy.

Conclusion

The incidence of renal impairment in HIV infection is increasing. These patients should be systematically screened for potentially reversible nephropathy if treatment is initiated in time. This underscores the importance of regular monitoring of patients living with HIV, and of referring them to a nephrologist if renal damage is detected. This manuscript on the spectrum of kidney biopsy findings in HIV-infected patients is highly significant for the scientific community as it provides detailed insights into the renal complications associated with HIV. Understanding these biopsy findings is critical for diagnosing and managing HIV-associated nephropathy (HIVAN) and other kidney-related conditions in HIV-infected individuals. As antiretroviral therapy (ART) has extended the lifespan of HIV patients, the prevalence of chronic kidney disease in this population has increased, making this research crucial for improving patient outcomes through early detection and targeted treatment strategies. It also contributes to the growing body of knowledge on HIV's systemic effects.

References

- [1]. Emem CP, Arogundade F, Sanusi A, Adelusola K, Wokoma F, Akinsola A. Renal disease in HIV-seropositive patients in Nigeria: an assessment of prevalence, clinical features and risk factors. *Nephrol Dial Transplant* 2008;23:741—6.
- [2]. Wyatt CM, Winston JA, Malvestutto CD, Fishbein DA, Barash I, Cohen AJ, et al. Chronic kidney disease in HIV infection: an urban epidemic. *AIDS* 2007;21:2101—3.
- [3]. N.J. Weiner *et al.* The HIV-associated renal diseases: current insight into pathogenesis and treatment *Kidney Int* (2003)
- [4]. *Kidney International* (2020) 97, 1006–1016; <https://doi.org/10.1016/j.kint.2020.01.018>
- [5]. Ekrikpo UE, Kengne AP, Bello AK, Effa EE, Noubiap JJ, Salako BL, Rayner BL, Remuzzi G, Okpechi IG. Chronic kidney disease in the global adult HIV-infected population: A systematic review and meta-analysis. *PLoS One*. 2018 Apr 16;13(4):e0195443. doi: 10.1371/journal.pone.0195443. PMID: 29659605; PMCID: PMC5901989.

The author states that he used ChatGPT in the grammatical correction of certain paragraphs.