

Case report

Chronic cutaneous injury of a hemodialysis patient in a tertiary hospital in Burkina Faso

Commented [1]: It's not injury.... Title can be cutaneous TB in hemodialysis patient....

Abstract

Mycobacterium tuberculosis is a bacterium with polymorphic infections. Pulmonary lesions remain a major public health problem. Cutaneous localization is uncommon and favored by immunosuppression such as chronic hemodialysis. Chronic wounds of immunocompromised patients are very often neglected. In developing countries, diagnosis is often difficult and delayed due to scarcity of resources. New diagnostic tests inaccessible in Burkina Faso contrast with the availability of treatment. We report a case of cutaneous tuberculosis in a chronic hemodialysis patient.

Commented [2]: What type of bacterium,? Polymorphic infection or multi organs system involvement?

Commented [3]: Chronic non healing

Keywords: Tuberculosis, cutaneous, chronic hemodialysis, Burkina Faso

UNDER PEER REVIEW

Introduction

Tuberculosis is a public health problem, with pulmonary localization accounting for over 80% of cases [1]. Cutaneous tuberculosis is characterized by a clinical polymorphism that often leads to misdiagnosis. Lesions mimic other more common conditions. Infection with the human immunodeficiency virus, diabetes and chronic renal failure are considered to be the main contributing factors. The pathology is rare, diagnosis is often difficult and microbiological confirmation is not always possible [2]. With this in mind, we report a case of cutaneous tuberculosis in a chronic hemodialysis patient in the Nephrology Department of the Yalgado Ouédraogo University Hospital.

Case presentation

Clinical observation

Mr. G A K is a male patient, aged 21, butcher by profession, resident in a peripheral district of Ouagadougou, hypertensive, treated with perindopril eight milligrams and amlodipine ten milligrams, with no other drug treatment. He has been on hemodialysis for six months (two sessions per week) via a femoral central venous catheter. His baseline nephropathy is undetermined. Physical examination revealed an initially nodular ulcerated lesion that had been evolving for over six months, prior to the start of hemodialysis, in an afebrile context with no pruritus, cough or signs of tuberculosis impregnation. The lesion was located in the proximal third of the anterior aspect of the left arm. It was ulcerating-budding, roughly rounded, measuring four centimeters long, well limited to the crusty edges, raised with a soft base, budding and painless (Figure 1). The patient had no generalized or locoregional adenopathy. The physical examination was normal.

Sputum examination by GeneXpert was negative. However, there was a highly reactive tuberculin skin test measuring 25 millimeters. Human immunodeficiency virus retroviral serology was negative. Front-view chest radiograph was normal. A cutaneous biopsy was performed. Pathological findings of the cutaneous lesion revealed inflammatory granulomatous, epithelioid and giant cell lesions. Epithelioid cells, lymphocytes, numerous multinucleated giant cells of the Langhans and Müller type and numerous altered polynucleated cells were noted. Small foci of anastomosing, eosinophilic caseous necrosis were also associated with fibrosis (Figure 2).

Within the limits of the specimen, there was no tumor proliferation. The histological appearance was suggestive of cutaneous mycobacteriosis. Neither culture nor polymerase chain reaction (PCR) testing could be performed. Mycobacterium tuberculosis was incriminated as a priority.

Commented [4]: How long patient has been CKD, how long the wound was there, was there any trauma?

Commented [5]: Mention treatment history for the wound, antibiotics, steroids etc.

After a pre-therapeutic workup, anti-tuberculosis treatment was started, adapted to the patient's renal function according to the Information Conseil Adaptation Renal (ICAR) letter, with three rifampicin/ isoniazid tablets daily and four pyrazinamide/ethambutol tablets every forty-eight hours [3]. The lesion healed one month after the start of anti-tuberculosis treatment.

Commented [6]: Mention total months of TB treatment WHO guidelines/ your country guidelines for cutaneous TB

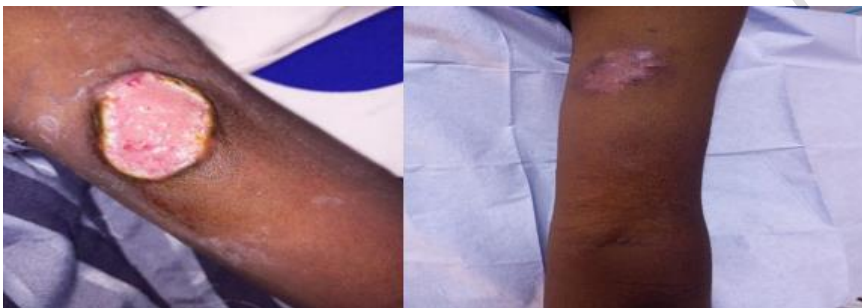

Figure 1: Ulcerated lesion on the anterior aspect of the left thoracic limb at diagnosis and after 02 months of anti-tuberculosis treatment (Images taken by Alassane Dianda)

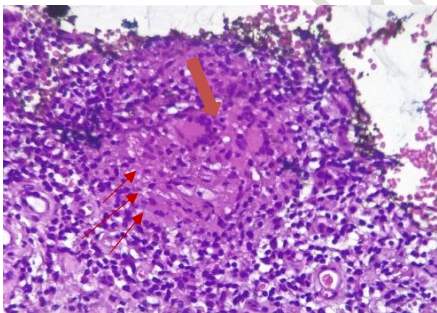


Figure 2: Histological lesion; hemateins-eosin staining at intermediate magnification; Langhans-type giant cells (orange arrow); lymphocytic infiltration in red arrows (Image taken by Aida Sandrine Ouédraogo).

Discussion

Cutaneous tuberculosis is a rare extra-pulmonary localization [1,4]. The rarity of this condition highlights the importance of investigating all chronic wounds in hemodialysis patients. The lingering nature of the condition, combined with the absence of life-threatening organ involvement in our patients, may explain the long evolution of lesions before positive diagnosis [5]. Stage V chronic kidney disease constitutes a state of immunosuppression for a variety of reasons. Uremia causes inflammation and reduces immune system function, with increased susceptibility to infection [4]. Risk factors for the development of this condition included end-stage renal failure, residence in an endemic area and occupation as a butcher. In addition, the clinical presentation is polymorphic, mimicking several conditions.

Lesions may be discrete erythematous papules, an infiltrated plaque or nodule evolving into an ulcerated lesion, pustules or vesicles [6,7]. In a context of limited human and material resources, the diagnosis of extra pulmonary tuberculosis is often tedious. Means of diagnostic confirmation are not always accessible, leading to delays in the management of this pathology. The current reference methods for diagnosis are microscopy and culture. However, the low sensitivity of microscopy and the laborious, time-consuming procedures involved in culture mean that these methods are less effective than the others [8]. The etiological agent is confirmed in the laboratory by direct screening and culture, histopathological analysis, interferon-gamma release assay (IGRA) and polymerase chain reaction (PCR). Hemodialysis patients are a target group for the IGRA test, which is unavailable in Burkina Faso.

Interferon-gamma release testing in this high-risk group has the advantage of not being subject to cross-reactivity with individuals vaccinated with Bacille Calmette et Guérin. QuantiFeronTB-Gold positivity can also be a predictor of tuberculosis [9]. Moreover, atypical mycobacteriosis should not be overlooked in this immunocompromised population [10], hence the importance of histopathology and culture.

The skin test is a relatively inexpensive examination, but its interpretation is limited, since a positive result does not necessarily indicate active tuberculosis [11]. *Mycobacterium tuberculosis* var *tuberculosis* was strongly suspected, although the bovids variant could also be implicated, given the patient's occupation. One limitation was the lack of precise identification of the germ variant.

. The diversification of diagnostic methods in a developing country can be a lifesaver. In addition, the treatment regimen is based on antibacillary drugs, in line with Burkina Faso's national

tuberculosis control program, with dosage adapted to the patient's renal function in accordance with the ICAR letter [12]. The antibiotics used are accessible and free of charge, making management of the disease relatively straightforward.

Conclusion

Cutaneous tuberculosis remains a rare and probably under-diagnosed pathology in developing countries. Although it is rare in the general population, it should always be considered in the presence of a chronic wound, especially in immunocompromised patients.

Consent:

we have obtained the patient's verbal and written consent for the use of the data collected

Competing interests:

we declare that we have no conflict of interest in of any kind

Disclaimer (Artificial intelligence)

Option 1:

Author(s) hereby declare that NO generative AI technologies such as Large Language Models (ChatGPT, COPILOT, etc) and text-to-image generators have been used during writing or editing of manuscripts.

References

1. Dicko A, Faye O, Fofana Y, Soumoutera M, Berthé S, Touré S, et al. Cutaneous tuberculosis in Bamako, Mali. *Pan Afr Med J*. June 8, 2017;27:102.
2. Kaul S, Kaur I, Mehta S, Singal A. Cutaneous tuberculosis. Part I: Pathogenesis, classification, and clinical features. *J Am Acad Dermatol* [Internet]. Feb 7, 2022 [cited Oct 4, 2022];0(0). Available from: [https://www.jaad.org/article/S0190-9622\(22\)00202-X/abstract](https://www.jaad.org/article/S0190-9622(22)00202-X/abstract)
3. Yves Berland, Gilbert Deray, Maurice Laville. Maniement des antituberculeux chez le patient insuffisant rénal, lettre d'Icar.
4. Frankel A, Penrose C, Emer J. Cutaneous Tuberculosis. *J Clin Aesthetic Dermatol*. Oct 2009;2(10):19-27.
5. Andonaba JB, Barro-Traoré F, Yaméogo T, Diallo B, Korsaga-Somé N, Traoré A. Cutaneous tuberculosis: observation of six confirmed cases at the CHU Souro SANOU (CHUSS) of Bobo-Dioulasso (Burkina Faso). *Pan Afr Med J*. 11 Oct 2013; 16:50.
6. Suraprasit P, Silpa-archa N, Triwongwanat D. Cutaneous Miliary Tuberculosis in a Chronic Kidney Disease Patient. *Case Rep Dermatol*. 31 oct 2014;6(3):253-7.
7. Van Zyl L, du Plessis J, Viljoen J. Cutaneous tuberculosis overview and current treatment regimens. *Tuberc Edinb Scotl*. déc 2015;95(6):629-38.
8. Kawano S, Maeda T, Watanabe J, Fujikura Y, Mikita K, Hara Y, et al. Successful diagnosis of tuberculous lymphadenitis by loop-mediated isothermal amplification of cutaneous samples from an ulcerated surface lesion: a case report. *J Med Case Reports*. déc 2014;8(1):254.
9. Lee SSJ, Chou KJ, Su IJ, Chen YS, Fang HC, Huang TS, et al. High Prevalence of Latent Tuberculosis Infection in Patients in End-Stage Renal Disease on Hemodialysis: Comparison of QuantiFERON-TB GOLD, ELISPOT, and Tuberculin Skin Test. *Infection*. avr 2009;37(2):96-102.
10. Sabeti S, Pourabdollah Tootkaboni M, Abdolahi M, Pourabdollah M. *Mycobacterium haemophilum*: A report of cutaneous Infection in a Patient with end-stage renal disease. *Int J Mycobacteriology*. déc 2016;5 Suppl 1:S236.
11. Dogan E, Erkoc R, Sayarlioglu H, Uzun K. Tuberculin skin test results and the booster phenomenon in two-step tuberculin skin testing in hemodialysis patients. *Ren Fail*. 2005;27(4):425-8.
12. Ministry of Health. Technical guide to tuberculosis control. 12th. 2022. 134 p