

## Case report

# inspiratory chest pain and fever after acute myocardial infarction: Dressler's syndrome demonstrated on cardiac MRI

## ABSTRACT

**Introduction:** Dressler's syndrome develops in some cases several days to weeks or even months after the myocardial infarction; the incidence also seems to have declined in recent years. This syndrome is caused by an autoimmune reaction to material extracted from necrotic myocytes.

**Case Report:** In this report, we present a case of a 72-year-old woman who was diagnosed with Dressler's syndrome after 1 month from acute coronary syndrome. A cardiac MRI was performed, which showed features of pericarditis. The patient responded well to treatment with NSAID and colchicine and was discharged home in good general condition.

**Discussion:** Cardiac MRI is particularly effective in identifying pericardial effusion, pericardial thickening, and inflammation-hallmarks of Dressler's syndrome. With its ability to perform tissue characterization through T1 and T2 mapping and late gadolinium enhancement, Cardiac MRI can distinguish between active inflammation and fibrotic changes. This feature is essential in determining the stage of Dressler's syndrome and guiding appropriate treatment.

**Conclusion:** Due to the significant number of patients living in the community who suffered MI, underwent cardiac surgery or received cardiac implantable device placement, clinical suspicion of PCIS warrants further diagnostic evaluation using imaging modalities especially cardiac MRI for timely diagnosis and treatment

*Keywords: Dressler's syndrome, Inspiratory chest pain, Fever, Cardiac MRI, Case report*

## 1. INTRODUCTION

"Dressler's syndrome also known as post myocardial infarction (MI) syndrome, is a form of secondary pericarditis with or without a pericardial effusion, that occurs because of injury to heart or pericardium" [1]. "It develops weeks to months after the initial infarction, and rarely within the first week post-MI. It is characterized by the development of inflammation of the pericardium as well as another serosa" [2]. "If left untreated, inflammation of the pericardium can lead to scarring, thickening, and muscle tightening of the heart, which can be life-threatening" [3]. "Dressler's syndrome is associated with an immune system response to heart damage" [4,5].

## 2. CASE PRESENTATION

A 72-year-old female with, arterial hypertension, diabetes mellitus and dyslipidemia. She had past history of coronary artery disease - inferolateral myocardial infarction, moderate left ventricular (LV) dysfunction diagnosed 1 month back and Percutaneous transluminal coronary angioplasty (PTCA) with stent to the circumflex artery done 1 month back.

The patient presented to the emergency department, reporting pain of a different pattern: severe constrictive chest pain lasting one hour that worsened with deep inspiration and while in a supine position associated with fever. The physical examination demonstrated a blood pressure of 140/85 mmHg, tachycardia (105 bpm), temperature of 38.6°C, and no jugular venous distension. A pericardial friction sound was easily audible at the lower left sternal border. Moreover, the

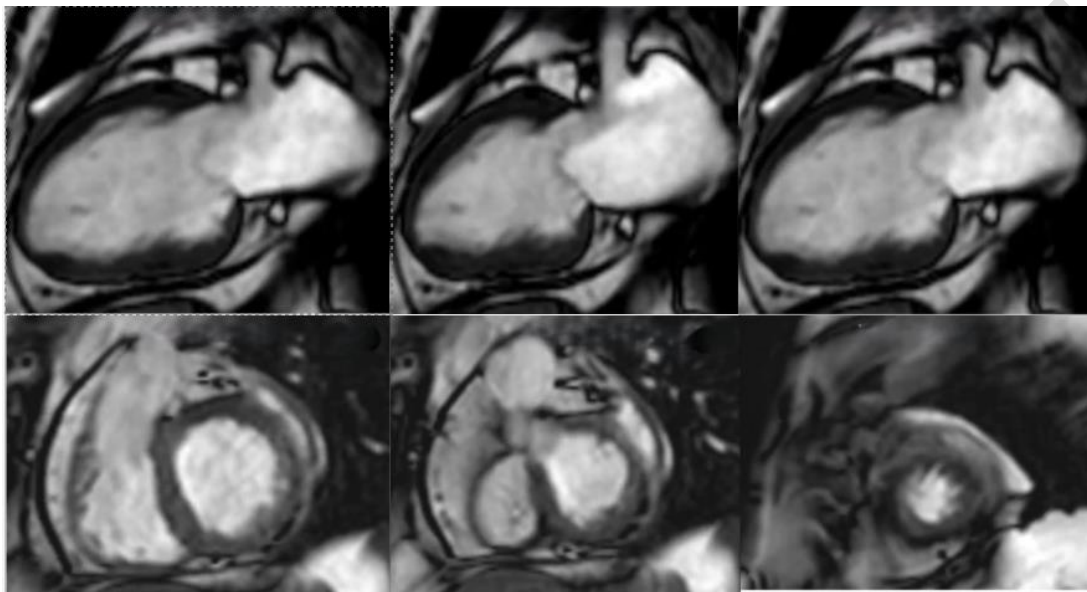
electrocardiogram showed diffuse ST-segment elevation with a depression of the PR segment, highly suggestive of pericarditis.

Laboratory tests revealed elevated acute-phase reactants (moderate leukocytosis, high erythrocyte sedimentation rate and C reactive protein of 158 mg/L). Sterile blood cultures and myocardial necrosis markers were negative.

Transthoracic echocardiogram revealed a small circumferential anechoic pericardial effusion (diastolic diameter of 5 mm), without collapse of the cardiac chamber.

Dressler's syndrome was suspected due to the history of STEMI, constantly elevated inflammatory parameters, negative blood and urine cultures, and no other clear diagnosis.

Cardiac MRI (CMRI) was performed and demonstrated an inferior akinesia and medial and basal inferolateral akinesia, leading to a mild deterioration of left ventricular systolic function (ejection fraction 41%, Figure 1).



Volumen VI		
Masa DF	60.28 g	(74-146)
VDF	88.56 ml	(76-160)
VSF	51.91 ml	(17-55)
SV	36.65 ml	(53-109)
EF	41.38 %	(59-79)
CO	3.34 l/min	
ED Mass/BSA	36.03 g/m <sup>2</sup>	(48-78)
VDF/Sup. Corp.	52.94 ml/m <sup>2</sup>	(49-85)
VSF/Sup. Corp.	31.03 ml/m <sup>2</sup>	(11-31)
SV/Sup. Corp.	21.91 ml/m <sup>2</sup>	(34-60)
CO/Sup. Corp.	1.99 l/(min*m <sup>2</sup> )	

Volumetria VD		
VDF	63.82 ml	(67-155)
VSF	21.43 ml	(5-59)
SV	42.39 ml	(52-106)
EF	66.42 %	(59-83)
EB	3.86 l/min	
VDF/Sup. Corp.	38.15 ml/m <sup>2</sup>	(45-83)
VSF/Sup. Corp.	12.81 ml/m <sup>2</sup>	(5-33)
SV/Sup. Corp.	25.34 ml/m <sup>2</sup>	(32-58)
CO/Sup. Corp.	2.31 l/(min*m <sup>2</sup> )	

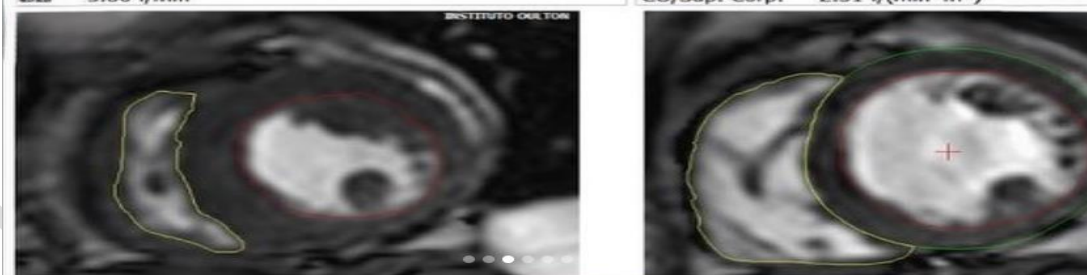
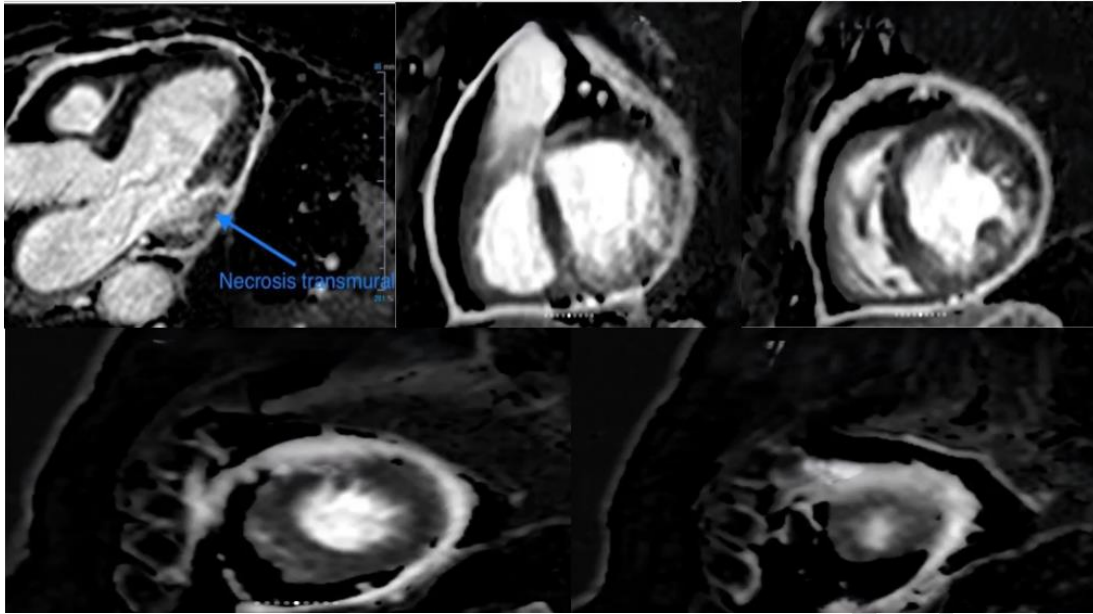
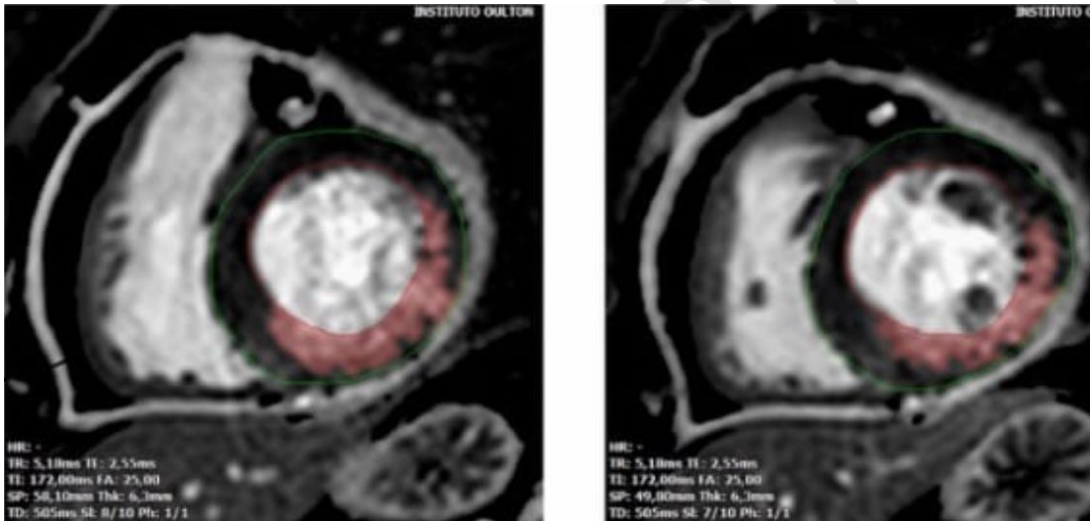


Figure 1: MRI demonstrated an inferior akinesia and medial and basal inferolateral akinesia with LV ejection fraction 41%)

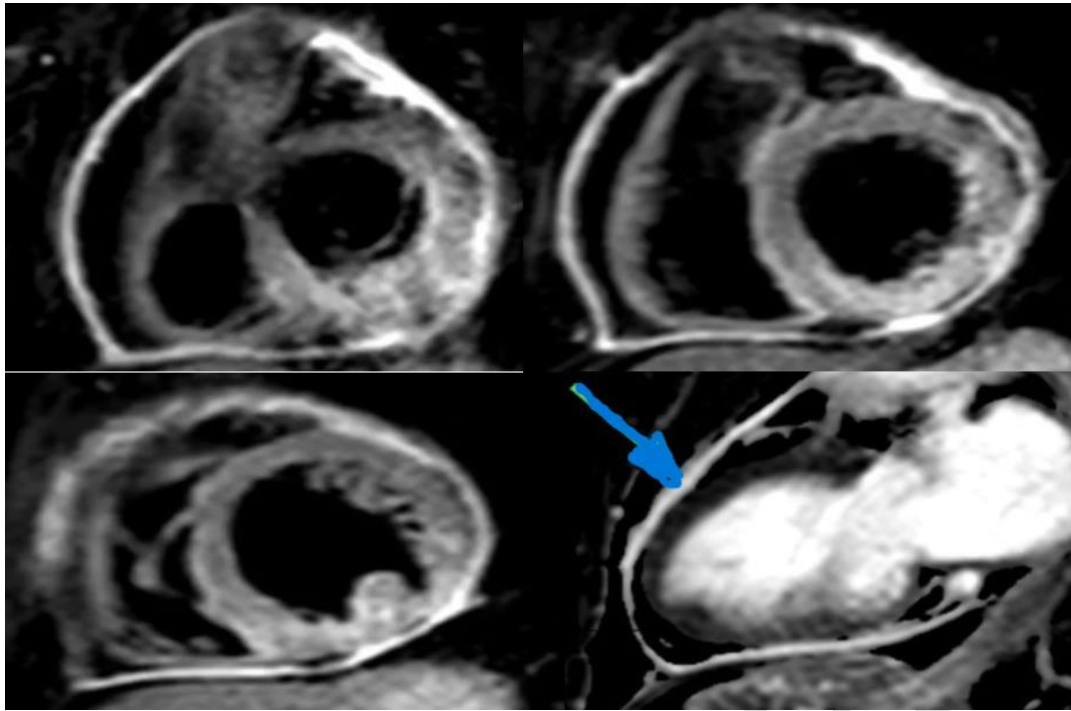


**Figure 2:** The late gadolinium enhancement sequence shows: medial infero-lateral transmural necrosis, and infero-medial, inferior and basal infero-lateral subendocardial necrosis



**Figure 3:** corresponding to a necrotic mass of 23 grams, equivalent to 28% of the total LV mass

It is important to note that the pericardium is thickened (4 mm), and also shows hypersignal in the T2 STIR sequence and homogeneous gadolinium uptake, which makes the diagnosis of acute pericarditis.



**Figure 4:** showed thickening of the pericardium, hypersignal in the T2 STIR sequence and homogeneous gadolinium uptake (blue arrow)

The CMRI also showed a mild left pleural effusion (Figure 5) and considering the clinical context of the patient, corresponds to the so-called Dressler's syndrome.

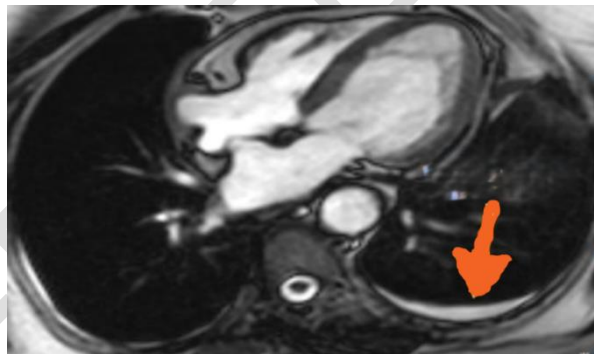


Figure 5 demonstrated a mild left pleural effusion (orange arrow).

The patient was treated with aspirin 500 mg 3 times daily and colchicine 1 mg once daily. His physical signs and laboratory data improved within several days. Three months later, his pericardial effusion had improved. Colchicine 1 mg/day was continued without any side effects for 6 months, with no recurrence in symptoms noted or examinations repeated.

### 3. DISCUSSION

Dressler syndrome is part of the post-cardiac injury syndrome (PCIS) an aetiologic heterogeneous group of autoimmune-mediated conditions of pericardial, epicardial, and myocardial inflammation. It is important to realize that inflammation is not confined to the pericardium and epicardium but also affects the myocardium to some extent.

The pathophysiology of PCIS is not completely understood. In 1956, Dressler suggested a role of an auto-antigens-mediated hypersensitivity reaction after MI, leading to myocardial necrosis, and subsequent pericarditis and pleuropericardial effusions in predisposed patients (14). The current hypothesis of PCIS stands with autoimmune pathogenesis, inciting the

cascade with damage to the pericardial and pleural mesothelial cells, caused by either necrosis of the myocardium, surgical trauma, blunt thoracic trauma, or iatrogenic damage to the pericardium (15).

Following myocardial infarction or cardiac surgery, myocardial tissue damage leads to the release of cardiac antigens into the bloodstream. These antigens, which are normally confined to the intracellular environment, become exposed to the immune system, triggering the formation of autoantibodies against myocardial cells. The presence of anti-myocardial antibodies is indicative of an autoimmune response, where the body mistakenly targets its own cardiac tissues, leading to inflammation of the pericardium, pleura, and even the myocardium (15). Identifying these antibodies can help distinguish Dressler's syndrome from other causes of pericarditis, offering diagnostic and therapeutic value by guiding anti-inflammatory and immunosuppressive treatments.

"The PCIS is diagnosed through a combination of clinical symptoms and imaging modalities that assess pericardial inflammation and effusion. Nevertheless, symptoms of epicardial and pericardial inflammation, such as pain, effusions, and fever, dominate the clinical picture. Signs of ventricular dysfunction such as heart failure, ventricular arrhythmias or severe conduction abnormalities are very rare" (6).

"Clinical evaluation usually reveals mild to moderate effusions both in the pericardium (>80%) and in the pleural space (>60%), and sometimes pericardial friction rubs (30-60%) on auscultation. Laboratory analysis shows systemic inflammation with elevation of C-reactive protein (CRP) (74%), and elevated blood leucocytes" (9,10).

"A diagnosis of PCIS may be considered in patients with chest pain, fever, pericardial or pleural effusions, and a re-emerging systemic inflammatory response syndrome after an appropriate latency period following prior Myo pericardial or pleural injury. Importantly, alternative causes for inflammation and effusion need to be ruled out before a diagnosis of PCIS can be established" (6-7).

"Transthoracic echocardiography (TTE) is the first-line imaging tool due to its wide availability and ability to quickly identify pericardial effusion and assess the heart's function. It provides real-time information about the thickness of the pericardium and the presence of fluid in the pericardial space. However, it has limited sensitivity for detecting subtle inflammation. Chest X-ray is not a direct imaging modality for diagnosing pericarditis, chest X-rays can reveal secondary signs of Dressler's syndrome, such as an enlarged cardiac silhouette due to pericardial effusion. It's a useful initial assessment tool but lacks specificity" (10,11). "Computed Tomography (CT) scan provides detailed anatomic views of the pericardium and can detect pericardial thickening, calcifications, and fluid accumulation. It is particularly useful in cases where other causes of chest pain or complications, such as pulmonary embolism, need to be excluded" (10,11).

In PCIS the cardiac MRI (CMRI) has good diagnostic value for pericardial inflammation in patients with post-MI. Presence of pericardial inflammation and effusion on CMRI has been reported as marker of myocardial infarction (MI) severity (11). CMRI findings of pericarditis have been reported in up to 40% of patient's post-myocardial infarction when imaged early, typically adjacent to the site of infarction (13). CMRI can provide evidence of pericardial inflammation and is clinically useful when trying to establish a cause for atypical post-myocardial infarction chest pain with atypical ECG and/or laboratory data (13).

"The role of the perfusion technique in Cardiac MRI (CMR) for diagnosing Dressler's syndrome is an important consideration in refining the diagnostic process. Perfusion imaging in CMRI is primarily used to assess myocardial blood flow and to identify areas of ischemia or infarction by evaluating how well blood perfuses the heart muscle. This technique is critical in diagnosing ischemic heart disease or assessing myocardial viability but plays a more limited role in evaluating pericardial conditions, such as Dressler's syndrome" (2,12).

"Dressler's syndrome is characterized by inflammation of the pericardium, often presenting with pericardial effusion, without direct involvement of myocardial perfusion abnormalities. As a result, the perfusion technique itself is not typically a primary tool in diagnosing this syndrome. The primary CMR sequences used in diagnosing Dressler's syndrome focus on detecting pericardial inflammation (via late gadolinium enhancement) and edema (via T2-weighted sequences)" (12,13).

"Given that myocardial ischemia can cause chest pain and similar clinical symptoms, the perfusion technique could have helped confirm that the patient's symptoms were solely related to pericarditis rather than ongoing ischemic issues. This differentiation would ensure the treatment focused appropriately on the inflammatory process associated with Dressler's syndrome" (13,16).

The diagnosis of Dressler syndrome is not easy and can be confused with many other cardiac disorders. Hence, it is best managed with an interprofessional team that includes a cardiac nurse, emergency department physician, cardiologist, radiologist, and intensivist (17).

Mainstays of treatment are non-steroidal anti-inflammatory drugs (NSAIDs) and the adjunct use of colchicine, albeit that there are no randomized controlled trials addressing specific treatment approaches for PCIS. Treatment decisions must be taken with care given the potential side effects and risks associated with NSAID and colchicine in cardiac and post-surgery patients (8). Patients who do not respond to NSAIDs therapy may be given a course of corticosteroids (e.g., prednisone) tapered over a 4-week period. In cases where patients do not respond adequately to prednisone or have contraindications to its use, alternative treatments such as immunosuppressive agents may be considered (17).

The outlook for most patients with Dressler syndrome is excellent. However, the recovery may take 2 to 4 weeks (17).

#### **4. CONCLUSION**

After development of primary percutaneous coronary intervention treatment for acute coronary syndrome, complications decrease. Nevertheless, occasionally doctors can encounter rare complications. This case report shows that, although very rare, Dressler syndrome should be considered as a possible cause in every post-MI patient presenting with chest pain, fatigue, and signs of inflammation.

#### **DISCLAIMER (ARTIFICIAL INTELLIGENCE)**

AUTHOR(S) HEREBY DECLARE THAT NO GENERATIVE AI TECHNOLOGIES SUCH AS LARGE LANGUAGE MODELS (CHATGPT, COPILOT, ETC) AND TEXT-TO-IMAGE GENERATORS HAVE BEEN USED DURING WRITING OR EDITING OF MANUSCRIPTS.

#### **CONSENT**

WRITTEN INFORMED CONSENT WAS OBTAINED FROM THE PATIENTS FOR PUBLICATION OF THIS CASE REPORT AND ANY ACCOMPANYING IMAGES.

#### **ETHICAL APPROVAL**

AS PER INTERNATIONAL STANDARDS OR UNIVERSITY STANDARDS WRITTEN ETHICAL APPROVAL HAS BEEN COLLECTED AND PRESERVED BY THE AUTHOR(S).

#### **COMPETING INTEREST**

THE AUTHORS DECLARE THAT THEY HAVE NO COMPETING INTERESTS

#### **REFERENCES**

- 1-Foris LA, Bhimji SS (2017) Publishing Dressler's syndrome. In: Stat Pearls. Treasure Island: Stat Pearls.
2. Lawley C, Mazhar J, Grieve SM, Figtree GA (2013) Visualizing pericardial inflammation in Dressler's syndrome with cardiac magnetic resonance imaging. Int J Cardiol 168: 32-33.
3. Bonow RO (2015) Pericardial diseases. In: Braunwald's Heart Disease: A Textbook of Cardiovascular Medicine. (10th edn).

4. Adams JG (2013) Pericarditis, pericardial tamponade, and myocarditis. In: Emergency Medicine: Clinical Essentials. (2nd edn).
5. Sendon JL, Gurfinkel EP, Lopez de Sa E (2010) Factors related to heart rupture in acute coronary syndromes in the Global Registry of Acute Coronary Events. *Eur Heart J* 31: 1449-1456.
6. Imazio M, Hoit BD. post-cardiac injury syndromes. An emerging cause of pericardial diseases. *Int J Cardiol.* 2013 Sep 30;168(2):648-52.
7. Gouriet F, Levy PY, Casalta JP, Zandotti C, Collart F, Lepidi H, Cautela J, Bonnet JL, Thuny F, Habib G, Raoult D. Etiology of Pericarditis in a Prospective Cohort of 1162 Cases. *Am J Med.* 2015 Jul;128(7):784.e1-8.
8. Meurin P, Lelay-Kubas S, Pierre B, Pereira H, Pavy B, Iliou MC, Bussi re JL, Weber H, Beugin JP, Farrokhi T, Bellemain-Appaix A, Briota L, Tabet JY; French Society of Cardiology. Colchicine for postoperative pericardial effusion: a multicentre, double-blind, randomised controlled trial. *Heart.* 2015 Nov;101(21):1711-6.
9. Imazio M, Negro A, Belli R, Beqaraj F, Forno D, Giammaria M, Trincherio R, Adler Y, Spodick D. Frequency and prognostic significance of pericarditis following acute myocardial infarction treated by primary percutaneous coronary intervention. *Am J Cardiol.* 2009 Jun 1 ;103(11):1525–9.
10. Adler Y, Charron P, Imazio M, et al. 2015 ESC guidelines for the diagnosis and management of pericardial diseases. *Eur Heart J* 2015;36:2921–64.
11. Klein AL, Abbara S, Agler DA, et al. American Society of echocardiography clinical recommendations for multimodality cardiovascular imaging of patients with pericardial disease. *J Am Soc Echocardiogr* 2013;26:965–1012.
12. Patel RKC. Pericardial Disease. In: Christopher M, Hundley G, eds. Atlas of cardiovascular magnetic resonance imaging. first. Philadelphia: Saunders, 2010: 110–20
13. Alexios S, Apostolos V, Emmanouil A, Christina K " Cardiac magnetic resonance imaging of pericardial diseases: a comprehensive guide " *European Heart Journal - Cardiovascular Imaging*, Volume 24, Issue 8, August 2023, Pages 983–998
14. W. Dressler, A post-myocardial infarction syndrome; preliminary report of a complication resembling idiopathic, recurrent, benign pericarditis, *J. Am. Med. Assoc.* 160 (16) (1956) 1379–1383.
15. Jahanzeb Malik a, Syed Muhammad Jawad Zaidi b , Abdul Sattar Rana a , Ali Haider a , Saleha Tahir c "Post-cardiac injury syndrome: An evidence-based approach to diagnosis and treatment" *American Heart Journal Plus* Volume 12, December 2021, 100068
16. Jordi Broncano , Sanjeev Bhalla, Pilar Caro, Alberto Hidalgo and al " Cardiac MRI in Patients with Acute Chest Pain" Vol. 41, No. 1, RSNA, 2020
17. Ari D. Leib ; Lisa A. Foris ; Tran Nguyen ; Karam Khaddour " Dressler Syndrome " July 3, 2023.