

# Multiple intracranial aneurysms :Experience of the Neurosurgery Department of Specialty Hospital, Rabat, Morocco

## Abstract :

Multiple intracranial aneurysms (MIA) are a cerebrovascular condition characterized by the presence of two or more aneurysms in the arteries of the brain. L'incidence des anévrismes cérébraux multiples est de 10,7 à 34 % des cas avec une hémorragie méningée ; les facteurs de risque sont représentés par l'hypertension artérielle, le tabagisme, le stress et aussi l'âge et le sexe féminin. The aim of this work is to report the experience of the Specialty Hospital of patients with multiple intracranial aneurysms, to discuss the epidemiological, clinical, diagnostic, and therapeutic aspects. This is a retrospective descriptive study, carried out within the neurosurgery department at the Rabat Specialty Hospital, over a period between January 2016 and December 2023. Multiple brain aneurysms pose an even greater risk than a single aneurysm because patients with multiple lesions have a higher associated mortality rate. Furthermore, in this group of patients, the risk of hemorrhagic recurrence of the initial aneurysm is greater and occurs earlier. The clinical condition of the patient and the size and location of the aneurysms are important factors that should be evaluated before surgery.

**Keywords :** Multiple intracranial aneurysms, hemorrhagic recurrence, polygon of Willis

## Introduction :

An intracranial aneurysm corresponds to any loss of parallelism of the edges of the arterial walls of an artery of the polygon of Willis (PW) or one of its branches. This loss of parallelism results in an expansion that is fusiform or sacciform.

Multiple intracranial aneurysms (MIA) are a cerebrovascular condition characterized by the presence of two or more aneurysms in the arteries of the brain. Under the influence of numerous factors, notably hemodynamics, the arterial wall becomes weakened and becomes increasingly distended. It can lead to subarachnoid hemorrhage (SAH), a serious emergency.

AMIs account for approximately 3% to 5% of all intracranial aneurysms and are associated with an increased risk of rupture and death.

The diagnosis and management of intracranial aneurysmal pathology benefit today from the development of microsurgical techniques, diagnostic radiology, interventional radiology, and the improvement of neuroanesthesia and neuroresuscitation measures. The aim of this work is therefore, by reporting the experience of the Specialty Hospital of patients with multiple intracranial aneurysms, to discuss the epidemiological, clinical, diagnostic, and therapeutic aspects.

## Material and methods

This is a retrospective descriptive study, carried out within the neurosurgery department at the Rabat Specialty Hospital, over a period between January 2016 and December 2023, with a duration of 8

years. During this period, 28 cases of multiple intracranial aneurysms were recorded among 392 cases of aneurysmal subarachnoid hemorrhage treated in the department.

## **Results :**

### **I-Epidemiology**

#### **1. Age:**

In this series, the age ranged from 29 to 88 years.

The average age is 47.5 years.

In our study, 14 patients, which represents 50%, are aged 40 to 60 years. 8 patients, or 28.5%, are aged 20 to 40 years; 4 patients, or 14.28%, are aged 60 to 80 years. And 1 patient, or 3.5%, is over 80 years old.

#### **2. Sex**

There is a predominance of females in this study.

There are 17 patients, or 60.70% female, and 11 patients, or 39.20% male. The sex ratio is 0.64.

### **II- Background**

9 patients, or 32.14%, are known to be hypertensive, including 4 patients who were poorly monitored.

4 patients, or 14.2%, are chronic smokers.

1 patient, or 3.5%, is followed for nephrotic syndrome.

1 patient is followed for MS.

2 patients, or 7.14%, are diabetic.

### **III- Clinical**

#### **1. The mode of revelation**

This mode is:

- Brutal in 20 cases (71%),
- Insidious in 7 cases (25%),
- The discovery was fortuitous in one case.

## 2. The telltale symptoms

The typical picture of subarachnoid hemorrhage is reported in 20 patients, which corresponds to 71.42% of the series.

The initial table consists only of headaches in 18 patients (64.28%), convulsions in 1 patient (3.57%), headaches associated with III disease in 2 patients (7.14%), and incidental discoveries .in 1 patient (as part of the assessment of another pathology).

<b>Clinical data</b>	<b>Number and percentage of patients</b>
Acute headache	24(85.71%)
Nausea/vomiting	21(75%)
Neck stiffness	20(71.42%)
Disturbance of consciousness	3(10.7%)
Seizure	1(3.5%)
Dizziness	4(14.28%)
Neck stiffness	20(71.42%)
Paresis/paralysis	6(21.42%)
Ptosis dt	1(3.5%)
BAV	3(10.7%)

**Table 1: Distribution of patients according to clinic**

## 3.Clinical examination:

### 3.1. Neurological status on admission:

For the most part, patients were alert during admission. Thus, 14 patients had a GCS of 15/15. This score is 14/15 for 3 patients, 12/15 for one patient, 9/15 for 2 patients, and 7/15 for 2 patients.

### 3.2. Physical examination.

Meningeal stiffness is found in 71.42%.

Six patients (21.42%) presented a motor deficit.

Two patients (7.14%) presented with damage to the third cranial pair.

#### **IV. Paraclinical examinations:**

##### **1. Brain CT**

All patients in this series underwent brain CT performed in a referral center or within our hospital structure. This examination was carried out urgently on 22 patients.

Subarachnoid hemorrhage alone is seen in six cases. This subarachnoid hemorrhage is associated with an intraparenchymal hematoma in 7 cases. In 3 cases, there was ventricular flooding, and in 6 cases, the brain CT appeared normal.

##### **2. Cerebral angiography**

This examination is performed on the majority of our patients. Aneurysms were not always found.

##### **3. Brain MRI/Angio-MRI**

Carried out on a patient as part of the assessment of another pathology (patient monitored for MS)

##### **4. Cerebral arteriography.**

Cerebral arteriography is performed in all patients in this series; a puncture of the femoral artery is performed to study the arterial axes using the Seldinger technique.

Patients are fasted and sedated when they are noncompliant for the examination. A hemostasis assessment and an ionogram are systematically carried out before carrying out this examination.

It made it possible to find 70 aneurysms in our 28 patients, with an average number of 2.5 aneurysms per patient.

Of the 70 aneurysms, 59 (84%) were evaluated for size and shape (in addition to condition).

19 cases have 2 aneurysms, 6 cases have 3 aneurysms, 1 case has 4 aneurysms, and 1 case has 5 aneurysms.

The mean diameter of these aneurysms was 5.8 mm (range: 0.8 mm to 16.39 mm). Distributed as follows:

35 (59.32%) small aneurysms,

21 (35.59%) medium and 3 (5.1%) large aneurysms

#### **The location of aneurysms:**

The angiographic analysis of the cases in our series allowed us to distribute the aneurysms according to laterality at the level of the cerebral circulation (right and left). We found that:

32% of patients (9 cases) had multiple ipsilateral aneurysms on the left.

17.85% of patients (5 cases) had multiple ipsilateral aneurysms on the right.

50% of patients (14 cases) had aneurysms located bilaterally (right and left circulation).

The analysis of these aneurysms according to their location in the anterior and posterior circulation found that:

67.85% of patients (19 cases) had multiple aneurysms located in the anterior circulation.

32% of patients (9 cases) had multiple aneurysms located in both the anterior and posterior circulations.

No cases with multiple aneurysms were found in the post-circulation.

### **Common locations of multiple aneurysms:**

In decreasing order of frequency, we found that the common site of aneurysms in our series is:

The middle cerebral artery: 35.71% (10 cases)

The posterior communicating artery: 32.14% (9 cases)

The ophthalmic artery: 28.57% (8 cases)

Carotid-cavernous: 17.85% (5 cases)

### **The ruptured aneurysm:**

The analysis of the cases in our series found:

- 28 ruptured aneurysms and 31 unruptured aneurysms.
- The average diameter for ruptured aneurysms is 8 mm; for unruptured aneurysms, it is 4.5 mm.
- There is a statistically significant difference in size between ruptured aneurysms and unruptured aneurysms.

The aneurysm located at the posterior communicating artery is the most common rupture. 25% (7 cases)

Anterior cerebral artery (ACA): 25% (7 cases)

Location in the end-carotid and supra-clinoid: 17.85% (5 cases)

Arterycarotid-ophthalmic: 14.28% (4 cases)

Middle cerebral artery (MCA): 14.28% (4 cases)

Vertebro-basilar system: 3.5% (1 case).

**Table 2: Location of ruptured aneurysms at the level of the vessels**

Aneurysm site	Number of cases
Posterior communicating	25% (7 cases)
TO THAT	25% (7 cases)
Termino-carotid and supra-clinoid	17.85% (5 cases)
Carotid-ophthalmic artery	14.28% (4 cases)
ACM	14.28% (4 cases)
Vertebro-basilar system	3.5% (1 case).

- For ruptured aneurysms, 64.28% (18) affect the left circulation, and 25% (7) affect the right circulation.

### **Associated malformations**

Agenesis of the right internal carotid artery with vascular dysplasia is described in a patient

The dysplastic appearance of the ICA was found in two patients.

### **Arterial vasospasm**

Two patients presented with arterial vasospasm.

### **V-Complications before any security action.**

#### **1. Arterial vasospasm**

It is found in three patients. One patient died in intensive care.

#### **2. Hydrocephalus.**

This complication occurred in one patient.

### 3. **Rebleeding.**

There are no cases of rebleeding in our series.

## **VI- The care**

### 1. **Medical treatment**

Almost all patients are hospitalized in a quiet, dimly lit room with family support.

One patient was admitted to intensive care because his neurological condition was very altered.

The established medication protocol includes:

- An analgesic treatment based on paracetamol
- A calcium channel blocker: 1 to 2 tablets/4 hours of nimodipine;
- Anti-convulsant treatment: phenobarbital;
- And antiemetic treatment in case of vomiting.

### 2. **Endovascular treatment**

In our series:

Six patients benefited from embolization of only the aneurysm that bled.

1 patient benefited from embolization of the aneurysm, which bled, then the 2nd in a second phase.

One patient benefited from the embolization of two aneurysms.

One patient benefited from embolization of an aneurysm, followed by a surgical approach as a second step for the second aneurysm.

### 3. **Surgical treatment**

We describe a single case in our series who presented with hydrocephalus postmeningitis, and it was derived.

7 cases in our series benefited from the clipping of the aneurysm that bled.

Three cases benefited from the clipping of two aneurysms.

One case benefited from the clipping of three aneurysms.

One case benefited from the clipping of an aneurysm, followed by embolization in the second stage of the second aneurysm.

#### **3.1. The surgical technique**

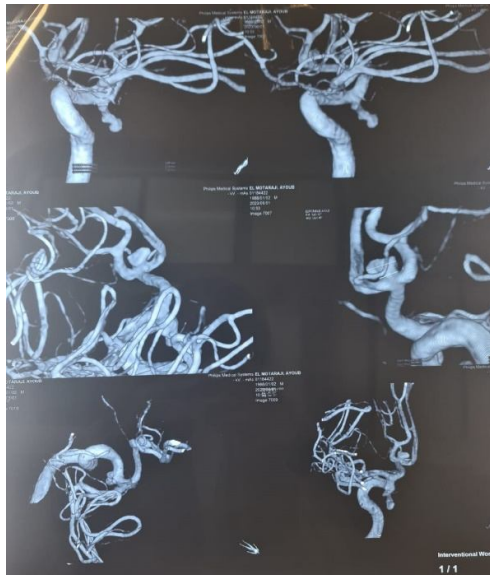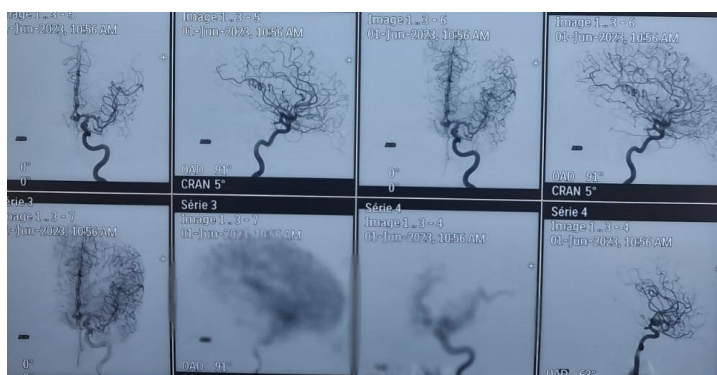
The pterional or frontolateral approach was used in 12 patients with different head tilt angles depending on the location of the aneurysm.

A patient with an end-basilar aneurysm benefited from embolization of this aneurysm, followed by a surgical approach to the communicating aneurysm.

The neck of the aneurysm is clipped in 12 patients.

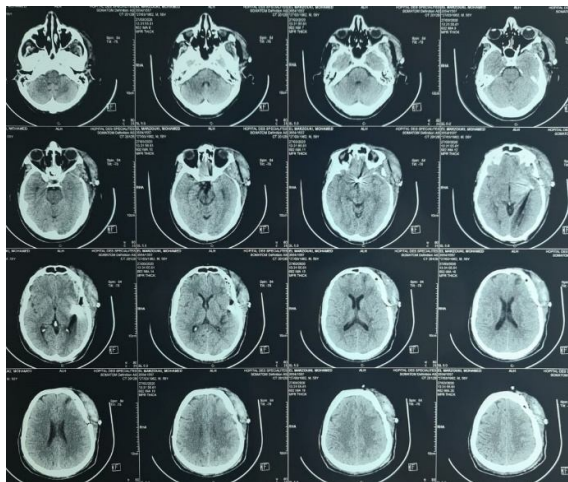
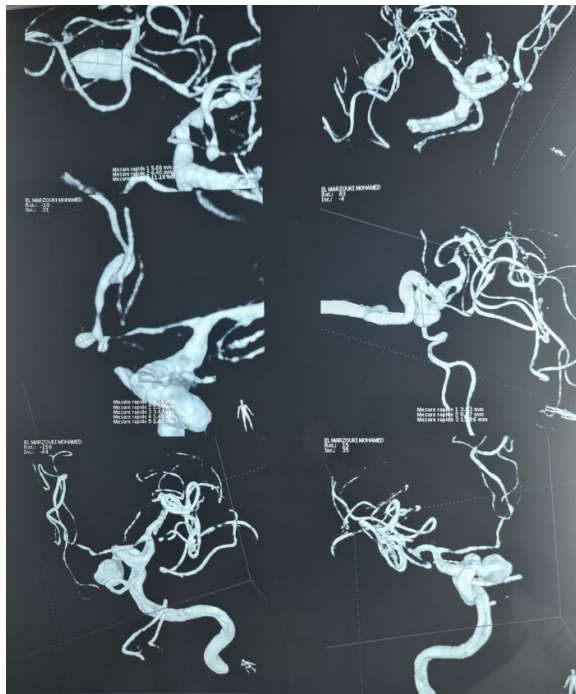### 3.2. Immediate postoperative course

The immediate postoperative course was marked by the occurrence of deterioration of GCS on an intra-parenchymal hematoma in a patient operated on with clipping of a middle cerebral aneurysm who was admitted to intensive care and then died following meningitis.



**Figure 1: Treatment of headaches with bilateral BAV**

A patient aged 35 was admitted for treatment of headaches with bilateral BAV. Arteriography shows double aneurysms of the left anterior and posterior communicating, the most irregular of which is that of the posterior communicating. The patient benefited from the clipping of the two aneurysms with simple consequences without a neurological deficit.



**Figure (2):Subarachnoid hemorrhage**

Patient aged 57, admitted for treatment of a subarachnoid hemorrhage WFNS I FISHER III, following multiple aneurysms of the 2 carotid territories: Left carotid: saccular aneurysm with irregular contours of the 3rd Sylvian bifurcation. +2 saccular aneurysms of regular contours of the A1-A2 junction with wide necks. right carotid artery: +post carotid-ophthalmic aneurysm. The patient benefited from complete clipping of the aneurysms, with simple outcomes.

## Discussion :

### Epidemiology

#### 1. Age and sex:

Approximately 2% of the general population has intracranial aneurysms [1, 2, 3], and approximately a quarter to a third have more than one aneurysm [4, 5, 6].

A study on multiple aneurysms carried out at the University Hospital of Zurich, Switzerland, over 9 years, found ninety-nine patients with a total of 265 aneurysms (average: 2 aneurysms per patient). There were three times as many women as men, and the average age for both sexes was 53 years [7].

In our series, 39.20% are male and 60.70% are female. That is a sex ratio of 0.64.

- Impact of AMIs:

In Suzuki's series of 1080 cases, single aneurysms accounted for 85% and multiple aneurysms for 15%. He reviewed seven other clinical series, totaling 10,795 cases, of which the incidence of multiple aneurysms was overall 14.1%, with a range of 7.7% to 29.8%. [9].

The incidence of multiple aneurysms ranges from 14 to 45% in patients with subarachnoid hemorrhage [10, 11].

In our series, we found 28 cases of multiple aneurysms out of 392 cases of aneurysms treated in our department between January 2016 and December 2023, i.e., an incidence of 0.4 to 0.6 per 100,000 people per year.

#### Natural History:

Multiple brain aneurysms pose an even greater risk than a single aneurysm because patients with multiple lesions have a higher associated mortality rate. Furthermore, in this group of patients, the risk of hemorrhagic recurrence of the initial aneurysm is greater and occurs earlier [12].

Multiple aneurysms are often seen in patients with diseases such as vasculopathy, fibromuscular dysplasia, and polycystic kidney disease [11].

#### Risk factors:

Risk factors for multiple intracranial aneurysms are:

The female gender,

Smoking at any time [21],

Hypertension and family history of cerebrovascular disease [7].

Connective tissue diseases, such as Marfan syndrome and neurofibromatosis, can increase the risk of developing AIM.

Atherosclerosis.

Polycystic kidney disease (PKD): This is an inherited kidney disease that can also increase the risk of developing AIM [12].

In our series, we found HTA in 32.1% of patients, tobacco in 21.4% of patients, alcohol in 7.14%, and nephrotic SD in 3.5% of patients.

## **Clinic:**

In a series of patients operated on for multiple aneurysms at the University Hospital of Zurich, Switzerland, the most common symptom was acute headache (74%), followed by altered consciousness (54%), and nausea and vomiting (40%). A quarter of the patients had no symptoms.

The number one complaint of patients with incidental aneurysms was chronic headache (40%). On admission of SAH patients, meningismus was the most common neurological sign, present in 40% of cases. Paresis, or paralysis of a cranial nerve, was found in 12%. Just over a quarter did not suffer from any neurological disorder [7].

Unruptured intracranial aneurysms may be discovered incidentally following unrelated complaints, or they may be noticed when they expand and put pressure on nearby brain structures. Middle cerebral artery aneurysms can cause hemiparesis, visual field defects, or seizures; aneurysms of the posterior and anterior communicating artery or basilar artery can cause third cranial nerve palsy; cavernous sinus aneurysms can cause cavernous sinus syndrome; aneurysms of the basilar distribution can cause brainstem compression; and, on rare occasions, aneurysm sac embolism can cause transient ischemia or permanent stroke [12].

## **In our series:**

More than 70% of patients are admitted with subarachnoid hemorrhage with acute headaches (85.71%), nausea/vomiting (75%), and neck stiffness (71.42%).

Disorder of consciousness (10.7%).

Paresis/paralysis (21.42%).

Visual disturbances: ptosis (3.5%), decreased visual acuity (10.7%).

## **PARACLINICAL:**

### **1. The brain scanner**

A brain CT without the injection of contrast products should be performed as a first-intention procedure in the event of subarachnoid hemorrhage.

In the case of multiple aneurysms, the location of bleeding on the scanner points towards the aneurysm that has bled.[11]

The scanner also makes it possible to look for complications such as rebleeding, hydrocephalus, or areas of ischemia in cases of severe vasospasm.

### **2. Cerebral angiogram:**

It has a sensitivity of 92.8 to 100% and a specificity of 83 to 100%.

### **3. Brain angio-MRI:**

This examination also has a special place, especially in the event of an allergy to iodized products or if the patient's renal function is impaired.

MRI is useful in diagnosing subacute to distant SAH after 4 to 7 days. In cases of multiple aneurysms, it may be helpful to determine which one has bled [14, 15].

#### 4. Cerebral angiography:

It is the gold standard in imaging when diagnosing an intracranial aneurysm.

It provides information on the aneurysm, its number, size, projection, and relationships with the vessels surrounding it.

The angiography tells us which aneurysm has bled.

How do you know which aneurysm has ruptured? No clinical method can predict with 100% accuracy which aneurysm has bled.

Traditionally, the largest aneurysm has ruptured [11].

Other angiographic signs of rupture are a local mass or vasospasm, an irregular shape of aneurysm, or an intra-aneurysmal clot. [11].

#### Location of aneurysms:

A sex-specific analysis was carried out of the location of aneurysms in patients with multiple aneurysms. Table 1 shows a series of 2,037 patients [8] (aged 20 to 89 years) presenting with a ruptured intracranial aneurysm who had been treated in 11 hospitals in Nagasaki Prefecture between 1989 and 1998. Multiple aneurysms were found in 361 of these patients [8].

Men	Broken	Not broken
ACOA	23 (28.8%)	13 (14.6%)
I CA	14 (17.5%)†	29 (32.6%)
MCA	27 (33.8%)‡	30 (33.7%)
Distal ACA	9 (11.3%)	8 (9.0%)
NOT	3 (3.8%)	3 (3.4%)
Others	4 (5.0%)	6 (6.7%)

Women	Broken	Not broken
ACOA	59 (21.0%)	37 (11.4%)
I CA	101 (35.9%)	128 (39.5%)
MCA	64 (22.8%)	114 (35.2%)
Distal ACA	26 (9.3%)	22 (6.8%)
NOT	20 (7.1%)	12 (3.7%)
Others	11 (3.9%)	11 (3.4%)

#### List 1 : Sex-specific aneurysm sites in patients with multiple aneurysms.

The most common location was MCA-bif, with 27% of all aneurysms, followed by Acomm (18%), Pcomm (11%), and MCA-M1 (6.5%).

The most common location of rupture was Acomm (35% of all ruptured aneurysms), followed by MCA-bif (22%), Pcomm (13%), and MCA-M1 (7%). Rupture rates were 65% for Acomm aneurysms, 40% for Pcomm aneurysms, and 28% for MCA-bif aneurysms [7].

In the Suzuki series of multiple aneurysms, patients with two aneurysms constitute 71–77%; three aneurysms, 15–23%; and four or more aneurysms, 6–7%. Multiple aneurysms are relatively more common in women (74%) than men (20). The same study showed that 47% of multiple aneurysms are on opposite sides. 21% are on the same side. 29% have one midline and one lateral aneurysm, and 3% have both midline [11].

As for multiple aneurysms, the most common location for women was always the ICA; in men, however, it is the middle cerebral artery (MCA) [7].

In the series of XUN SHEN1, Common locations of multiple aneurysms were the ophthalmic artery (25%), middle cerebral artery (19.0%), and posterior communicating artery (14.3%) [16].

#### Our series:

32% (9) of patients had multiple ipsilateral left aneurysms.

17.85% (5) patients had multiple ipsilateral aneurysms on the right.

50% (14) patients had multiple aneurysms located bilaterally (right and left circulation).

67.85% (19) cases had multiple aneurysms located in the anterior circulation.

32% (9) cases had multiple aneurysms located in both the anterior and posterior circulation.

No cases with multiple aneurysms were found in the post-circulation.

Common locations for multiple aneurysms in our series:

- The posterior communicating artery: 32.14% (9 cases)
- The average cerebral artery is 35.71% (10 cases).
- The ophthalmic artery is 28.57% (8 cases).
- Carotid-cavernous: 17.85% (5 cases)

#### **Ruptured aneurysm:**

In 1998, the large International Study of Unruptured Intracranial Aneurysms found that aneurysms with a diameter less than 10 mm had an annual rupture rate of less than 0.05%, while aneurysms of 10 mm or more had an annual rupture rate of less than 0.05%. rupture at 1% per year [7]. In contrast, studies with small numbers of patients concluded that aneurysms were likely to rupture at much smaller sizes [7].

A more recent study found that almost 90% of all ruptured aneurysms were less than 10 mm in diameter [7]. Therefore, large aneurysms (size greater than 10 mm) are more likely to rupture, perhaps due to an increase in aneurysm size over time [7].

The location of the ruptured aneurysm was determined on CT by the distribution of subarachnoid blood, the location of intracerebral hemorrhage, the irregular multi-lobular appearance of the aneurysm, associated vasospasm, and direct extravasation of contrast products. on angiograms, as well as the localization of the clot intraoperatively at the site of rupture of the aneurysm [7].

The most common location of rupture is Acomm (35% of all ruptured aneurysms), followed by MCA-bif (22%), Pcomm (13%), and MCA-M1 (7%). Rupture rates were 65% for Acomm aneurysms, 40% for Pcomm aneurysms, and 28% for MCA-bif aneurysms [7].

Age greater than 60 years, female gender, Finnish or Japanese ancestry, aneurysm size greater than 5 mm, location in the posterior circulation, and unruptured symptomatic aneurysms all had a higher risk of rupture, according to a major meta-analysis of currently available research. [17].

The common locations of aneurysms in cases of multiple aneurysms are the ophthalmic artery (25%), the middle cerebral artery (19.0%), and the posterior communicating artery (14.3%). However, the locations with the highest probability of rupture are the anterior communicating artery (25%) and the posterior communicating artery (25%). The middle cerebral artery is the least likely site of rupture (6.5%) [16].

#### In our series:

- 28 ruptured aneurysms, and 31 were not ruptured.
- The average diameter for ruptured aneurysms is 8 mm; for unruptured aneurysms, it is 4.5 mm.
- There is a statistically significant difference in size between ruptured aneurysms and unruptured aneurysms.

The aneurysm located at the post-communication artery is the most common site of rupture. 25% (7 cases)

ACA: 25% (7 cases)

end-carotid and supra-clinoid: 17.85% (5 cases)

carotid-ophthalmic artery: 14.28% (4 cases)

ACM: 14.28% (4 cases)

Vertebro-basilar system: 3.5% (1 case).

## **TREATMENT :**

### **1-surgery:**

The natural history of patients with multiple intracranial aneurysms was established by Heiskanen et al. [18], who found that untreated, unruptured aneurysms bled at a rate of 3% per year, with a cumulative mortality rate of 20%. In one series, 83% of patients with multiple inoperable intracranial aneurysms died within 1 year of the initial subarachnoid hemorrhage [19].

According to the ISUIA, 1917 patients with an average age of 50 years, 32.3% of whom had multiple aneurysms, were operated on. At 1 year, morbidity and mortality rates in patients who underwent open surgical repair were 10.6 to 12.6%. Patient age has a significant influence on overall surgical outcome, with a significant increase in risk for those 50 years and older and a significant increase in risk after age 60 to 70 years. Other indicators of poor surgical prognosis are the large size of the aneurysm, its position in the posterior circulation (especially the basilar tip), a history of ischemic cerebrovascular disease, and the presence of aneurysmal symptoms other than rupture.

Orz et al. [20] reported the surgical treatment of unruptured aneurysms in 310 patients, 57 of whom had multiple aneurysms, as follows: the aneurysms were enveloped in 21 patients, and the parent artery was trapped in 7 and trapped after bypass surgery in 3; the rest was clipped. No neurological deficit remained in 262 patients (84.5%), and one "death" occurred in one patient (0.3%) [12].

The type of surgical approach as well as the timing of surgical intervention have been widely discussed in the neurosurgical literature [22]. The clinical condition of the patient, as well as the size and location of the aneurysms, are important factors that should be assessed before surgical intervention [16].

The favorable development was documented with the following: 1—patient aged 60 years or younger; 2—small (<6 mm) or medium-sized (6 to 15 mm) aneurysms; 3—anterior circulation aneurysms; 4—aneurysms—single unruptured aneurysms (96% versus 88% for multiple aneurysms). Drake [30] found a morbidity rate of 14.3% in the posterior circulation after surgery for multiple asymptomatic unruptured aneurysms, compared to 0% morbidity in the anterior circulation [22].

Mizoi et al. [19] recommend surgery for all multiple intracranial aneurysms in a single session when possible, or with a second surgery if necessary to clip unruptured aneurysms. They reported an overall morbidity rate of 14 to 19% and a mortality rate of 6 to 8% in 372 patients who underwent surgery for unilateral or bilateral multiple intracranial aneurysms after SAH, which were comparable to rates observed in surgery for a single aneurysm [16].

The mortality rate in patients with multiple intracranial aneurysms involving the posterior circulation was as high as 27%. In their study, 78% of patients received treatment for all aneurysms in a single session, 7% underwent complete treatment in two sessions, and 15% did not receive treatment for all aneurysms [16].

Orz et al. [23] reported an excellent or good overall outcome in 67.9% of patients with SAH, compared to 86.5% in patients with unruptured aneurysms.

Several factors negatively affect outcomes after surgery in these patients, such as single-stage surgery in patients with aneurysms located in the posterior circulation. Misdiagnosis of the bleeding aneurysm, among several intracranial aneurysms, also leads to poorer outcomes [24]. It has been reported that the use of multiple surgical approaches during the acute phase after SAH is one of the factors leading to poor outcomes [24].

Némoto et al. [24] reported that the size of unruptured aneurysms among multiple intracranial aneurysms is also an important prognostic factor.

A larger series of patients reported by Inagawa [25] also confirmed a poorer surgical outcome in patients older than 60 years.

Aneurysms that are at risk of rupture are always treated first [16].

According to previous studies, surgical morbidity was significantly higher in cases of multiple aneurysms; this can be justified by brain manipulations in one or more sessions. Giant size (>15 mm) and elderly patients (60 to 70 years) are at higher risk of surgical morbidity and are therefore poor surgical candidates. The presence of AC in places that are not accessible and technically difficult to access surgically, such as the cavernous carotid, the vertebrobasilar trunk, or the basilar apex, also amplifies the risks. On the other hand, the MCA is a favorable and accessible site for surgical clipping [12].

## **2-Endovascular treatment:**

In the treatment of multiple intracranial aneurysms, endovascular techniques can be used to treat ruptured aneurysms and aneurysms that are technically difficult to operate on [16].

Another advantage of the endovascular approach for the treatment of multiple intracranial aneurysms is the elimination of the risk of diagnostic error and, therefore, non-treatment of the aneurysm that has bled [16].

This technique also eliminates the problems associated with multiple craniotomies or surgical approaches, which may be necessary in some cases.

Experience with endovascular techniques in the treatment of multiple intracranial aneurysms, particularly those involving the vertebrobasilar system, suggests that they may be a particularly suitable therapeutic method for this high-risk condition. However, endovascular treatment of MCA aneurysms remains controversial due to favorable surgical outcomes with low rates of morbidity, mortality, and recurrence at follow-up [16].

## **3-Multidisciplinary approach:**

When open surgery and endovascular methods are combined in the same or different sessions, they can be mutually beneficial in the treatment of multiple aneurysms. To maximize patient benefit, researchers attempt to strike a delicate balance between improving aneurysm obliteration and reducing treatment-related morbidity. This could include reconstruction of the parent artery or bypass treatments followed by coil implantation, or vice versa. The creation of surgical access for coil embolization through a transcranial approach has also been reported [12].

## **CONCLUSION**

In the case of a single or multiple aneurysm, our results show that female gender and age 50 are important risk factors for SAH. The female gender per se is also associated with an increased incidence of multiple aneurysms.

The natural history of the disease has led to a consensus that, when technically possible, all aneurysms should be treated. The clinical condition of the patient and the size and location of the aneurysms are important factors that should be evaluated before surgery.

### **Ethical Approval:**

As per international standards or university standards written ethical approval has been collected and preserved by the author(s).

### **Consent**

As per international standards or university standards, patient(s) written consent has been collected and preserved by the author(s).

### **Disclaimer (Artificial intelligence)**

Option 1:

Author(s) hereby declare that NO generative AI technologies such as Large Language Models (ChatGPT, COPILOT, etc.) and text-to-image generators have been used during the writing or editing of this manuscript.

Option 2:

Author(s) hereby declare that generative AI technologies such as Large Language Models, etc. have been used during the writing or editing of manuscripts. This explanation will include the name, version, model, and source of the generative AI technology and as well as all input prompts provided to the generative AI technology

Details of the AI usage are given below:

- 1.
- 2.
- 3.

## References :

1: Inagawa T, Hirano A (1990) Autopsy study of unruptured incidental intracranial aneurysms. *Surg Neurol* 34:361–365

2: Juvela S, Porras M, Heiskanen O (1993) Natural history of undisturbed intracranial aneurysms: a long-term follow-up study. *J Neurosurg* 79:174–182

3: McCormick WF, Acosta-Rua GJ (1970) The size of intracranial saccular aneurysms. An autopsy study. *J Neurosurg* 33:422–427

4: Ostergaard JR, Hog E (1985) Incidence of multiple intracranial aneurysms. Influence of arterial hypertension and gender. *J Neurosurg* 63:49–55

5: Rinne J, Hernesniemi J, Niskanen M, Vapalahti M (1995) Management outcome for multiple intracranial aneurysms. *Neurosurgery* 36:31–37

6: Rinne J, Hernesniemi J, Puranen M, Saari T (1994) Multiple intracranial aneurysms in a defined population: prospective angiographic and clinical study. *Neurosurgery* 35:803–808

7: Baumann F, Khan N, Yonekawa Y (2008). Patient and aneurysm characteristics in multiple intracranial aneurysms. Department of Neurosurgery, University Hospital Zurich, Zurich, Switzerland. *Acta Neurochir Suppl* (2008) 103:19–28  
#Springer-Verlag 2008  
Printed in Austria

8: Makio Kaminogo, MD; Masahiro Yonekura, MD; Shobu Shibata, M.D. (2002). Incidence and Outcome of Multiple Intracranial Aneurysms in a Defined Population. Department of Neurosurgery, Nagasaki University School of Medicine, 1-7-1 Sakamoto, Nagasaki 852-850.

9: Suzuki J. Multiple aneurysms: treatment. In Pia HW, Langmaid C, Zierski J (eds): Cerebral aneurysms: advances in diagnosis and therapy, Berlin: Springer. 1979; 352-363.

10: Ellamushi HE, Grieve JP, Jager HR, Kitchen ND. Risk factors for the formation of multiple intracranial aneurysms. J Neurosurg. 2001; 94:728-732.

11: DA Nica<sup>1</sup>, Tatiana Rosca<sup>1</sup>, A. Dinca<sup>2</sup>, M. Stroi<sup>3</sup>, Mirela Renta<sup>4</sup>, AV Ciurea<sup>5</sup>. Multiple cerebral aneurysms of middle cerebral artery. Case report. Romanian Neurosurgery (2010) XVII 4:449-455

12: Mohamed Adel Deniwar<sup>1</sup> (2022). Management of multiple and unbrokencerebral aneurysms. Deniwar Egyptian Journal of Neurosurgery 2022, 37(1):26

13: Qureshi AI, Suarez JJ, Parekh PD, Sung G, Geocadin R, Bhardwaj A, Tamargo RJ, Ulatowski JA (1998) Risk factors for multiple intracranial aneurysms. Neurosurgery 43:22-27

14: Morris P. Practical neuroangiography. Philadelphia: Lippincott Williams & Wilkins; 2007.

15: Gibbs GF, Huston J III, Bernstein MA, Riederer SJ, Brown RD Jr. 3.0-Tesla MR angiography of intracranial aneurysms: comparison of time-offlight and contrast-enhanced techniques. J Magn Reson Imaging. 2005; 21(2):97-102.

16: XUN SHEN<sup>1</sup>, TAO XU<sup>2</sup>, XUAN DING<sup>3</sup>, WENLEI WANG<sup>1</sup>, ZHI LIU<sup>1</sup>, HUAIHAI QIN<sup>1</sup>. Multiple Intracranial Aneurysms: Endovascular Treatment and Complications. *Interventional Neuroradiology* 20:442-447, 2014

17: Wermer MJ, van der Schaaf IC, Algra A, Rinkel GJ. Risk of rupture of unruptured intracranial aneurysms in relation to patient and aneurysm characteristics: an updated meta-analysis. Stroke. 2007; 38(4):1404-10.

18: Heiskanen O, Marttila I. Risk of rupture of a second aneurysm in patients with multiple aneurysms. J Neurosurg. 1970; 32 (3): 295-299. doi:10.3171/jns.1970.32.3.0295.

19: Mizoi K, Suzuki J, Yoshimoto T. Surgical treatment of multiple aneurysms. Review of experience with 372 cases. Acta Neurochir. 1989; 96 (1-2): 8-14. doi:10.1007/BF01403489

20: Orz Y, Kobayashi S, Osawa M, Tanaka Y. Aneurysm size: a prognostic factor for rupture. Br J Neurosurg. 1997; 11(2):144-9.

21: Morris P. Practical neuroangiography. Philadelphia: Lippincott Williams & Wilkins; 2007.

- 22: Orz YI, Hongo K, Tanaka Y, Nagashima H, Osawa M, Kyoshima K, Kobayashi S. Risks of surgery for patients with unruptured intracranial aneurysms. *Surg Neurol.* 2000;53(1):21-9
- 23: Orz Y, Osawa M, Tanaka Y, et al. Surgical outcome for multiple intracranial aneurysms. *Acta Neurochir.* 1996; 138 (4): 411-417. doi:10.1007/BF01420303.
- 24: Nemoto M, Yasui N, Suzuki A, et al. Problems of surgical treatment for multiple intracranial aneurysms. *Neurol Med Chir (Tokyo).* 1991; 31 (13): 892-898 [Article in Japanese]. doi: 10.2176/nmc.31.892.
- 25: Inagawa T. Multiple intracranial aneurysms in elderly patients. *Acta Neurochir (Wien).* 1990; 106 (3-4): 119-126.