

# Case report

## Bilateral Mooren ulcer: a difficult care approach

---

### ABSTRACT

**Aims:** Bilateral Mooren's Ulcer Following Pterygium Surgery: Challenges in Management

**Study design:** Observational case report

**Case :** We present the case of a 45-year-old patient who presented with decreased visual acuity, and in whom ophthalmological examination revealed bilateral peripheral ulcerative keratitis. The search for a systemic disease was negative and the diagnosis of bilateral Mooren's ulcer was established.

The patient was treated with topical and systemic corticosteroids in addition to local cyclosporine and conjunctival resection. After four weeks of treatment, a corneal perforation of the right eye occurred, and patient underwent an amniotic membrane graft, in addition to immunosuppressive medical treatment.

**Discussion and Conclusion:** Mooren's ulcer is known to be more severe and more likely to be bilateral in young patients. Several treatment strategies are available; Unfortunately, there is no definitive treatment to ensure complete resolution or prevent recurrences in cases of Mooren's ulcer.

*Keywords: peripheral ulcerative keratitis, Mooren's ulcer, graft, amniotic membrane*

### 1. INTRODUCTION

Mooren's ulcer is a rare and potentially blinding eye disease. Mooren's ulcer may be unilateral or bilateral and is characterized by a painful peripheral corneal ulcer that progresses circumferentially and centrally, destroying the corneal stroma and leaving only a thin fibrovascular membrane.[1]

The etiopathogenesis of this type of peripheral ulcerative keratitis remains unclear but prior ocular surgery, trauma, or corneal infection are found in one third of patients[2] suggesting an organ-specific autoimmune response.

We dispose of a wide range of therapies to control the inflammation, and to prevent the progression and recurrences. However, there is not enough evidence to determine which remedy is most effective.

As it is a rare disease, the literature contains little information. In the present article, we provide a detailed description of this condition, and the difficulty of its management.

## 2. PRESENTATION OF CASE

We describe the case of a 45-year-old patient with a previous history of ocular redness and pain associated to decreased visual acuity in the follow up of a pterygium excision in the right eye, seven months prior to his visit. The patient reported a bilateralization of the symptoms for the past month, which led to a consultation in our department.

Ophthalmological examination revealed a visual acuity of hand motion perception in the right eye and 5/10 in the left. Ocular pressure was within normal range. Examination of the anterior segment in the right eye showed a diffuse corneal thinning with a small persistent central island, neovascular appeal, and conjunctival injection with no underlying scleral involvement. The Rest of the elements and the Fundus examination was not accessible due to the corneal opacification. (Figure 1 a-b)

Biomicroscopy of the left eye revealed a crescent-shaped ulcer with sharp borders in the nasal cornea near limbus, stomal infiltrates at the advancing margin with a pseudopterygium nasally. The anterior chamber was clear, and the lens was transparent, fundus examination of the left eye was unremarkable. (Figure 1 c-d)

The diagnosis of peripheral ulcerative keratitis PUK was made, and the patient was put on topical and oral corticosteroids: dexamethasone ophthalmic drops every 2 hours, oral prednisolone 60 mg every day, ofloxacin drops and lubricant.

To rule out the possibility of a systemic disease, we referred him to the internal medicine department. Physical examination was normal, Serological tests were negative for Anti-double-stranded DNA, anti-neutrophil cytoplasmic antibodies ANCA, anti-nuclear, rheumatoid factor, lupus anticoagulant, anti-Ro/SSA, syphilis. Viral markers and titers including HIV, hepatitis B, and hepatitis C were negative. Hemogram, liver and renal function tests, erythrocyte sedimentation rate, and the levels of C-reactive protein, angiotensin-converting enzyme, tuberculosis interferon gamma test quantiferon-TB GOLD\* , were within normal range.

Thoracic CT scan was normal.

As all the tests were negative and no etiology for the PUK was found, the diagnosis of Mooren ulcer was established.

One week after the initiation of the treatment, the ulcer continued to progress. In the right eye the remaining stroma melted, leaving only an epithelized descemet membrane, while in the left eye the ulcer progressed circumferentially and centrally, and visual acuity dropped to 2/10 due to the irregular astigmatism. (Figure 2 and 3 a-b-c)

The patient underwent a conjunctival resection and was put on i.v. methylprednisolone 500 mg per day, for three days, followed by oral prednisolone, in addition to local cilosporine 2% four times a day.

The ulcer seemed to have stabilized, however one month later a spontaneous punctiform perforation occurred in the left eye.

An amniotic membrane graft was performed and cyclophosphamide treatment was started. (Figure 3 d)

The patient was followed up closely, the conjunctival injection resolved, the corneal ulcer stopped progressing, and no epithelial defect was noted. However, visual acuity in the left eye continued to drop, and was below 0.5/10 due to the presence of a dense cataract. (Figure 3e)

Corneal grafts were not available; therefore, only a cataract extraction was performed, which was a very challenging procedure due to the corneal opacities. Post-operative follow up was unremarkable, local and general treatment was slowly tapered, and the patient was left only on lubricant and immunosuppressant. A year after his first presentation to our department, the patient preserves a visual acuity of 2/10 in his left eye, and no other recurrence was noted.

### 3. DISCUSSION

Mooren's ulcer is an uncommon cause of peripheral ulcerative keratitis (PUK) [3], characterized by a painful, progressive ulcerative keratitis that begins peripherally and advances circumferentially and centrally, with minimal or no scleral involvement. It can be either unilateral or bilateral such as our case.

Various studies suggest that Mooren ulcer develops after corneal trauma, infection, or surgery, however the exact etiopathogenesis is yet unclear [4], [5], [6].

An autoimmune condition triggered by cornea-specific antigens that become exposed due to trauma or surgery have been linked to the pathogenesis of Mooren's ulcers [7]

Due to the rarity of this entity and the limited published literature, the surgical and medical management of Mooren's ulcer is still challenging and no high-quality evidence supports the use of any treatment option [8]

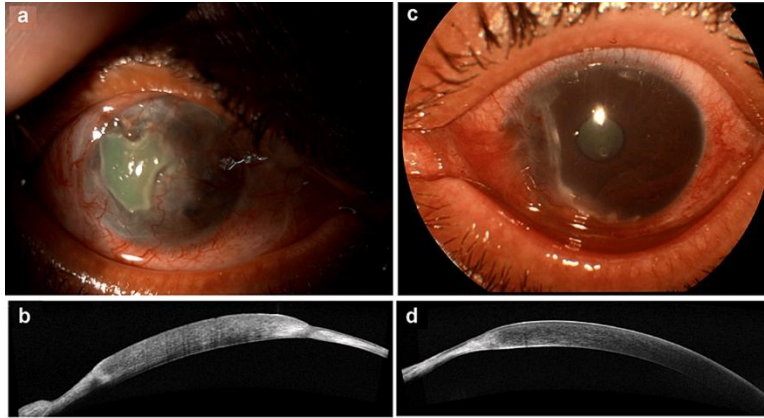
Combined methods are often required [9] including topical and systemic corticosteroids, local and systemic immunosuppressive agents, resection of adjacent inflamed conjunctiva, amniotic membrane grafting, cyanoacrylate tissue adhesive application in case of perforation, and lamellar or full thickness keratoplasty in advanced cases [10], [11], [12]

A recent study conducted by Guindolet et al introduces rituximab as a new interesting therapeutic option when all treatments were previously proposed [13]

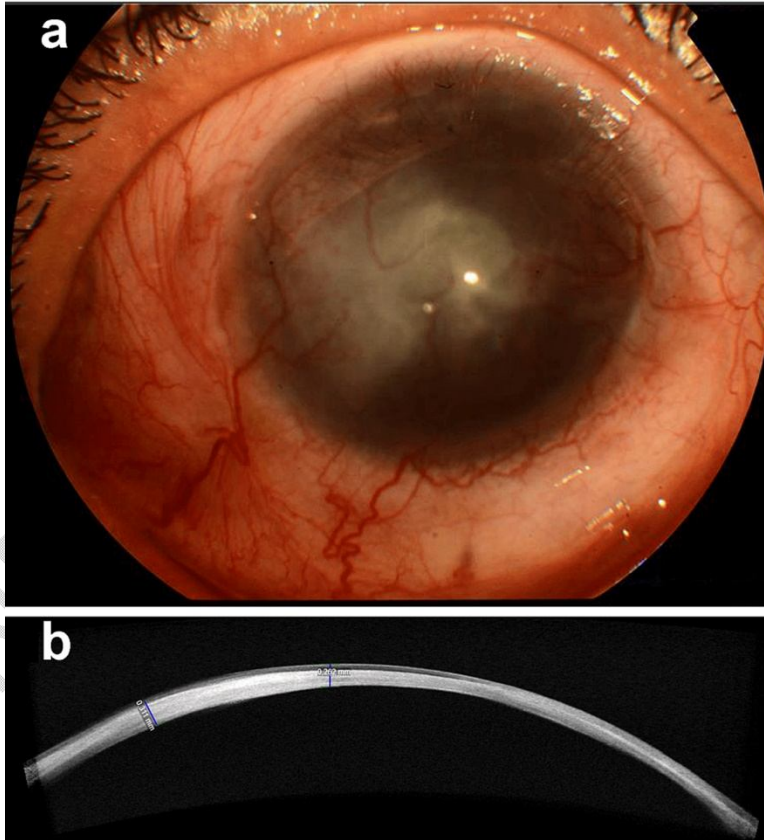
Despite intensive care, Mooren's ulcer carries a poor prognosis with frequent recurrences. Early diagnosis and appropriate treatment are crucial to prevent severe outcomes. [14], [15]

**Figure 1.** clinical photographs and OCT images of both eyes  
**a: clinical photograph and b: OCT scan of the persistent central island in the right eye with circumferential thinning.**

**c: clinical photograph and d: OCT scan showing peripheral corneal thinning.**

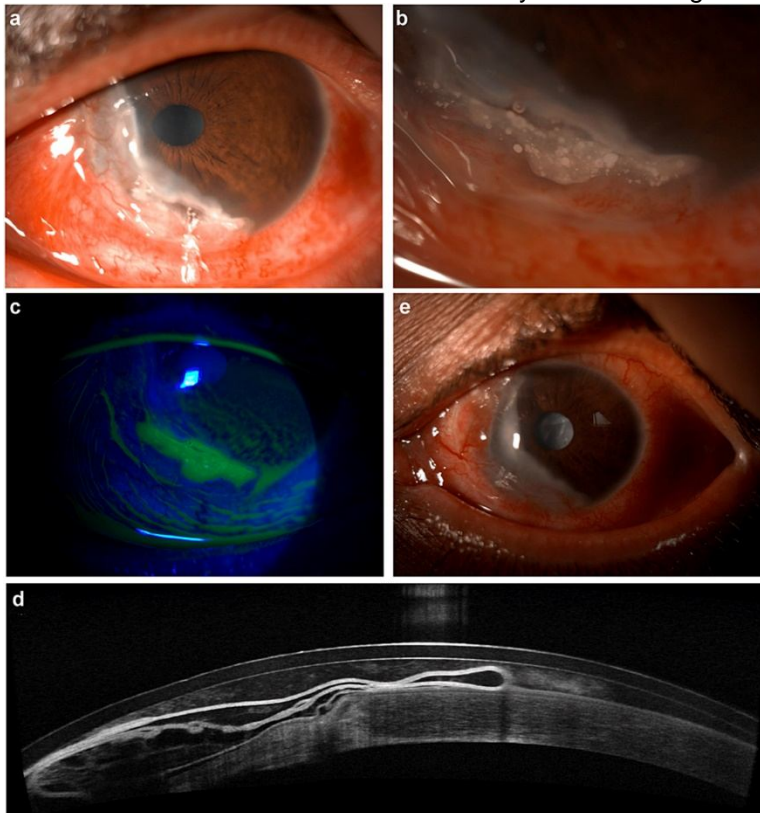


**Figure 2.a:** clinical photograph and b: OCT scan showing complete melting of the stroma



**figure3.a:** progression of the ulcer b: infiltrates at the advancing margin c: fluorescein staining of the active ulcer d: OCT scan of the amniotic graft e: A complete healing of the

ulcer with a dense cataract in the left eyelevel heading.



#### 4. CONCLUSION

This case highlights the complexity involved in managing Mooren's ulcer. To date, no consensus exists on the most appropriate treatment approach. The current practice of employing a stepwise approach, tailored to the patient's individual characteristics, will need to continue.

#### CONSENT

As per international standards or university standards, patient(s) written consent has been collected and preserved by the author(s).

#### ETHICAL APPROVAL

It is not applicable.

Disclaimer (Artificial intelligence)

Option 1:

Author(s) hereby declare that NO generative AI technologies such as Large Language Models (ChatGPT, COPILOT, etc.) and text-to-image generators have been used during the writing or editing of this manuscript.

## REFERENCES

- [1] Y. Gupta *et al.*, "Peripheral ulcerative keratitis," *Survey of Ophthalmology*, vol. 66, no. 6, pp. 977–998, Nov. 2021, doi: 10.1016/j.survophthal.2021.02.013.
- [2] M. Srinivasan, M. E. Zegans, J. R. Zelefsky, A. Kundu, T. Lietman, and J. P. Whitcher, "Clinical characteristics of Mooren's ulcer in South India," *Br J Ophthalmol*, vol. 91, no. 5, pp. 570–575, May 2007, doi: 10.1136/bjo.2006.105452.
- [3] E. T. Cunningham, M. Agarwal, D. P. Smit, I. Tugal-Tutkun, and J. E. Thorne, "Mooren's Ulcer," *Ocular Immunology and Inflammation*, vol. 31, no. 4, pp. 673–674, Apr. 2023, doi: 10.1080/09273948.2023.2193129.
- [4] V. Aaltonen, M. Alavesä, L. Pirilä, E. Vesti, and M. Al-Juhaish, "Case report: bilateral Mooren ulcer in association with hepatitis C," *BMC Ophthalmol*, vol. 17, p. 239, Dec. 2017, doi: 10.1186/s12886-017-0633-x.
- [5] J. Kim, M. K. Kim, W. R. Wee, and J. Y. Oh, "Mooren Ulcer in a Child Wearing Orthokeratology Contact Lenses," *Eye & Contact Lens: Science & Clinical Practice*, vol. 44, no. 4, pp. e13–e15, Jul. 2018, doi: 10.1097/ICL.0000000000000341.
- [6] F. Alliti, A. Mchachi, L. Benhmidoune, A. Chakib, R. Rachid, and M. El Belhadji, "Perforation cornéennesurulcère de Mooren en post-vaccination anti-COVID-19 : à propos d'un cas," *J Fr Ophtalmol*, vol. 46, no. 1, pp. e1–e3, Jan. 2023, doi: 10.1016/j.jfo.2022.07.007.
- [7] K. Hassanpouret *al.*, "Peripheral Ulcerative Keratitis: A Review," *J Ophthalmic Vis Res*, vol. 17, no. 2, pp. 252–275, Apr. 2022, doi: 10.18502/jovr.v17i2.10797.
- [8] M. B. Alhassan, M. Rabiou, and I. O. Agbabiaka, "Interventions for Mooren's ulcer," *Cochrane Database Syst Rev*, no. 6, p. CD006131, Jun. 2011, doi: 10.1002/14651858.CD006131.pub2.
- [9] J. N. Ashar, A. Mathur, and V. S. Sangwan, "Immunosuppression for Mooren's ulcer: evaluation of the stepladder approach—topical, oral and intravenous immunosuppressive agents," *British Journal of Ophthalmology*, vol. 97, no. 11, pp. 1391–1394, Nov. 2013, doi: 10.1136/bjophthalmol-2012-302627.
- [10] C. N. McGhee and D. V. Patel, "Mooren's ulcer and amniotic membrane transplant: a simple surgical solution?," *Clinical Exper Ophthalmology*, vol. 39, no. 5, pp. 383–385, Jul. 2011, doi: 10.1111/j.1442-9071.2011.02605.x.
- [11] A. Xia, T. Dietrich-Ntoukas, and U. Pleyer, "Effect of Anti-TNF Treatment on Mooren's Ulcer: A Case Series and Review of the Literature," *Ocular Immunology and Inflammation*, vol. 31, no. 4, pp. 675–681, Apr. 2023, doi: 10.1080/09273948.2021.2023581.
- [12] C. D. Kalogeropoulos, V. D. Malamou-Mitsi, M. B. Aspiotis, and K. G. Psilas, "Bilateral Mooren's Ulcer in Six Patients: Diagnosis, Surgery and Histopathology," *IntOphthalmol*, vol. 25, no. 1, pp. 1–8, Jan. 2004, doi: 10.1023/B:INTE.0000018510.06715.c9.
- [13] D. Guindoletet *al.*, "Management of severe and refractory Mooren's ulcers with rituximab," *Br J Ophthalmol*, vol. 101, no. 4, pp. 418–422, Apr. 2017, doi: 10.1136/bjophthalmol-2016-308838.
- [14] L. Yang, J. Xiao, J. Wang, and H. Zhang, "Clinical Characteristics and Risk Factors of Recurrent Mooren's Ulcer," *J Ophthalmol*, vol. 2017, p. 8978527, 2017, doi: 10.1155/2017/8978527.

[15] K. Dh, K. Mk, W. Wr, and O. Jy, "Mooren's Ulcer in a Cornea Referral Practice in Korea," *Ocular immunology and inflammation*, vol. 24, no. 1, 2016, doi: 10.3109/09273948.2014.926938.

UNDER PEER REVIEW