

# Original Research Article

## Subacute toxicity study of *Alchornea Cordifolia* ethanolic leaf extract on the pituitary gland of Wistar rats.

### ABSTRACT

**Introduction:** Herbal medicines are plant-based products used to treat various illnesses and their uses have dramatically increased over the past years in many developed and developing nations. *Alchornea cordifolia* is one of these plants with reports of its use in health promotion. Some plants exhibit toxicity due to the presence of phytochemicals inherent in them, therefore further studies are necessary in evaluating their toxicity levels. In this study, the sub-acute toxicity of ethanolic extract of *Alchornea cordifolia* leaves was investigated on the pituitary gland of adult male Wistar rats. The objective was to determine its effect on the histology of the anterior pituitary gland.

**Method:** Twenty (20) adult male Wistar rats weighing 140-200 were used for the research and were randomly divided into four groups labelled A, B, C, and D. Each group consisted of five (5) rats. Group A (normal control) received normal saline, while group B, C and D received 500 mg/kg, 1,000 mg/kg and 1,500 mg/kg body weight of *Alchornea cordifolia* extract respectively with the aid of an oral gavage. This was done for a duration of 28 days after which the rats were sacrificed and the pituitary gland obtained for histological analysis using H&E and PAS Orange G staining methods.

**Result:** Histological observations showed that the various doses of the extract used had no detrimental effect of the anterior pituitary gland microstructure in groups B, C, and D when compared to group A.

**Conclusion:** The findings showed that the various doses of *Alchornea cordifolia* leaf extract used in this study are non-toxic to the anterior pituitary gland in Wistar rats.

**Keywords:** *Alchornea cordifolia*, anterior pituitary, histology, toxicity.

## INTRODUCTION

The application of medicinal herbs has been popular from ancient times among people and in recent years a multilateral approach has emerged on using medicine with natural and especially herbal origin (2, 3). Medicinal herbs like industrial drugs may cause some irretrievable tissue damage through its unwanted side effects (4). Evaluating side and toxic effects of medicinal herbs by performing experimental tests on animal models will have an effective advantage on the identification and recognition of their harmful effects on humans (4). In Africa more than 2000 plants have been identified and used as herbal medicines. The World Health Organization (WHO) estimates that nearly 70% of the world population depends on traditional medicine, especially medicinal plants for primary health care needs. Herbs are as old as human civilizations and have provided a complete store house of remedies to cure acute and chronic diseases in man (5). Currently, there is a growing interest in the use of plant and plant products as alternative to most synthetic agents in disease management and control around the world. This is because of the therapeutic efficiency of their bioactive constituents. The gradual shift from synthetic drugs to herbal therapies could also be as a result of the widespread availability of medicinal plants worldwide (6). Some plants which were once considered safe with no adverse effects began exhibiting toxic potentials when ingested over a period of time, and this led to valid concerns (6). Furthermore, a number of saponin-rich plant extracts were seen to cause weight loss, diarrhoea, loss of appetite and haematological disorders (7).

*Alchornea cordifolia* is a shrub native to the coastal regions of West Africa. Traditionally its powdered leaves have been used to treat wounds and sores. Phytochemical analysis of the leaves has shown the presence of several health-promoting compounds including flavonoids which are known for their uses medicinally (8). Many studies have illustrated the tissue-protective attributes of plants rich in flavonoids (9,10,11,12,13,14,15,16). Reports on the biological activities of *Alchornea cordifolia* have revealed its antibacterial, hepato-protective, anti-diarrheal, antioxidant, anti-inflammatory and anti-microbial properties. A study has disclosed that *Alchornea cordifolia* alcoholic extract caused hepatic tissue damage in mice (8).

The pituitary gland is a gland that performs essential life-sustaining functions in the human body, and its anterior lobe secretes vital hormones such as adrenocorticotrophic hormone, prolactin, luteinizing hormone, follicle stimulating hormone, somatotropin and thyroid stimulating hormone which direct many bodily processes (17) It is a part of the hypothalamic-pituitary gonadal axis (HPG) axis which also includes

structures such as the hypothalamus and gonadal glands. The hypothalamic-pituitary gonadal axis starts in the brain, and it allows the brain communicate with the gonads using molecules called hormones (18). The normal functioning of the pituitary gland can be obstructed by exposure to toxic substances which can induce lesions on its endocrine cells, thereby interfering with its regulation of endocrine activities. Some substances are able to stimulate pituitary cell proliferation leading to hyperplasia and tumour formation (19). This study therefore serves to investigate its subacute toxic potential on the anterior pituitary gland.

## **MATERIALS AND METHODS**

### **Plant acquisition, identification and preparation of extract:**

Fresh leaves of *Alchornea cordifolia* were obtained from a residence in Yarkur Local Government Area of Cross River state, Nigeria and was confirmed and authenticated at the Department of Botany, Faculty of Science, University of Calabar, Calabar. The leaves were washed and air-dried after which they were grounded and sieved to fine powder. The powdered plant material (330g) was extracted with ethanol by maceration. The maceration mixture was filtered and the filtrate evaporated in a carefully regulated water bath maintained at a temperature of 60°C to yield 21g of darkened solid extract. The extract was stored in a refrigerator until required. The extraction of *Alchornea cordifolia* was carried out in the main laboratory of Biochemistry Department, University of Calabar.

### **Experimental design**

Twenty (20) matured male Wistar rats obtained from the Department of Physiology, University of Calabar, Calabar, weighting 140-200g were used for the study. These animals were housed in wooden cages at 27°C-30°C under natural 12-hour daylight/night cycles in the animal house of College of Medical Sciences, University of Calabar. After an acclimatization period, they were randomly divided into four groups of five (5) animals each, labelled as group A, B, C, and D. Group A (normal control) received normal saline, while group B, C and D received 500 mg/kg, 1,000 mg/kg and 1,500 mg/kg body weight of *Alchornea cordifolia* extract respectively with the aid of an oral gavage. This was done for a duration of 28 days after which the rats were sacrificed and the pituitary gland obtained for histological analysis using hematoxylin and eosin "H&E" and periodic acid Schiff "PAS" Orange G staining methods.

### **Histological study with hematoxylin and eosin stain "H&E"**

The tissue was fixed in 10% neutral formal saline for 3 days to prevent autolysis. The tissues were then trimmed and dehydrated in ascending grades of alcohol (70%, 80%, 90% and absolute alcohol). They were then cleared in xylene and afterward embedded in molten wax. Upon solidification, the tissue blocks were sectioned to 5µm thick with a rotary microtome. They were then floated in a water bath and incubated at 60°C for 30 minutes. The cut sections were then cleared in xylene and rehydrated through descending grades of alcohol (90%, 80% and 70%). Furthermore, the sections were stained in hematoxylin for 15 minutes. Bluing was done with ammonium chloride, while differentiation was done with 1% acid alcohol before counterstaining with eosin. Mounting was done on greased glass slides using a dibutylphthalate polystyrene "DPX" (20).

#### **Periodic acid schiff orange G. method for the demonstration of anterior pituitary gland:**

Sections were dewaxed and brought to water via xylene and ethanol. They were then placed into period acid for 10 minutes, rinsed with tap water and then placed in Schiff reagent for 10-20 minutes. Counterstaining with celestine blue-hamalum sequence was carried out. The sections were afterward rinsed in tap water for 5 minutes. After this, the tissues were placed in orange G for 20 seconds each, then rinsed with tap water until. They were then dehydrated with ethanol and cleared in xylene. Cover slips were then placed on the sections using a resinous medium (21).

## **RESULTS AND DISCUSSION**

### **Results:**

The histological examination of the anterior pituitary gland sections across the experimental groups revealed a normal histology in group A rats (plate 1). Structures seen were cell clusters with oval to round nuclei having abundant cytoplasm. The cell clusters were separated by thin dilated and congested capillaries. The predominant cells have prominent nuclei with an abundant eosinophilic cytoplasm. Sparsely populated basophilic cells were scattered within the field with few cells having clear cytoplasm. The anterior pituitary gland sections of rats in groups B (plate 2), C (plate 3) and D (plate 4) also revealed normal histological features similar with that of group A, indicative of non-toxicity. Staining with the PAS Orange G method also showed normal anterior pituitary histology in group A (plate 5) rats. Structures seen were acidophilic cells with deeply stained orange cytoplasm (Orange G-POSITIVE) and basophilic cells which were lightly stained blue (PAS-POSITIVE). The acidophilic cells out-numbered the basophilic cells. This normal anterior pituitary gland histology was also observed in groups B (plate 6), C (plate 7) and D (plate 8) indicative of non-toxicity.

### **Discussion:**

The assessment of subacute toxicity of *Alchornea cordifolia* leaf extract in this study involved investigating any possible adverse effects on the anterior pituitary gland in Wistar rats. This study involved the administration of three doses (500mg/kg, 1,000mg/kg and 1,500mg/kg) of the leaf extract in order to compare the histological results with that of the normal control group A. The findings of this study revealed that there was no deviation in the anterior pituitary gland micro-architecture of the test groups (groups B, C and D) when compared to group A. This was observed in the histological examinations involving both the H&E and PAS Orange G staining methods. This findings agree with studies by Goueh *et al* (22), Ejeh *et al* (6), Akanmu *et al* (23) and Ezeokeke *et al* (24) who revealed that doses of *Alchornea cordifolia* leaf extract below 1,500mg/kg body weight have non-toxic effects on many bodily tissues. A study by Ajibade and Olayemi (25) gave a contrasting observation in their study that *Alchornea cordifolia* methanolic leaf extract is in fact toxic at doses of 800mg/kg and 1,600mg/kg. Their study was on some reproductive and haematological parameters in male rats. They opined that doses of the extract equal to or lower than 400mg/kg can be considered safe as regards its oral administration. Another report of toxicity was given in a study by Ansah *et al* (8) and Ansah *et al* (26) who showed that *Alchornea cordifolia* ethanolic extract doses of 2,000mg/kg caused histopathologic changes to the liver in rats. They observed cloudy swelling of hepatocytes with vacuolar hydropic degeneration which are indicative of hepato-toxicity. They suggested that safer doses are those below 2,000mg/kg and that higher doses have the propensity to induce hepatic injury. The reason for this toxicity is not clear but it may be due to its bio-constituents. It has been suggested that some medicinal plants are intrinsically toxic by virtue of their constituents and can cause adverse reactions if inappropriately utilized (27). It is therefore necessary for more studies to be conducted on toxicity potential of *Alchornea cordifolia* leaf extract on bodily tissues so as to ensure safety in usage.

### **Conclusion**

The findings of this study showed that the various doses of *Alchornea cordifolia* leaf extract used in this study were non-toxic to the anterior pituitary gland in Wistar rats.

### **ETHICAL CONSIDERATION**

All authors hereby declare that “Principles of laboratory animal care” (NIH publication No. 85-23, revised 1985) were followed as well as specific national laws where applicable. All experiments have been examined and approved by Faculty Animal Research Ethics committee, Faculty of Basic Medical Sciences, University of Calabar, Cross River state, Nigeria and given a registration number (08ANA2321).

### ***Implication for health policy/practice/research/medical education***

The administration of ethanolic leaf extract of *Alchornea cordifolia* caused no structural damage to the anterior pituitary gland in the experimental groups. It therefore shows that doses of 1,500mg/kg of *Alchornea cordifolia* leaf extract and below has no toxic effect of the pituitary gland.

### **Disclaimer (Artificial intelligence)**

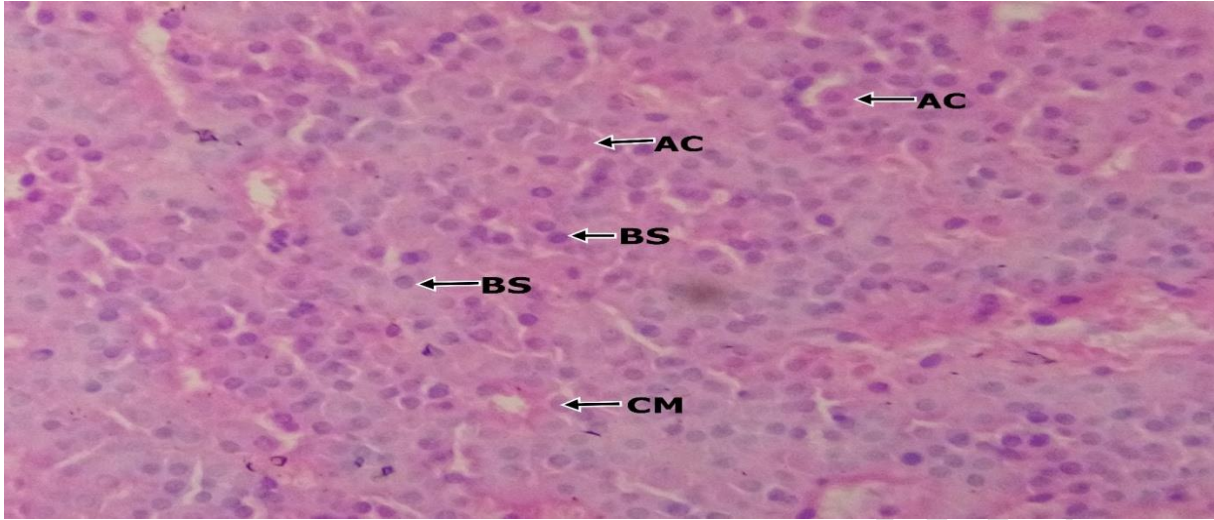
Author(s) hereby declare that NO generative AI technologies such as Large Language Models (ChatGPT, COPILOT, etc.) and text-to-image generators have been used during the writing or editing of this manuscript.

### **REFERENCES:**

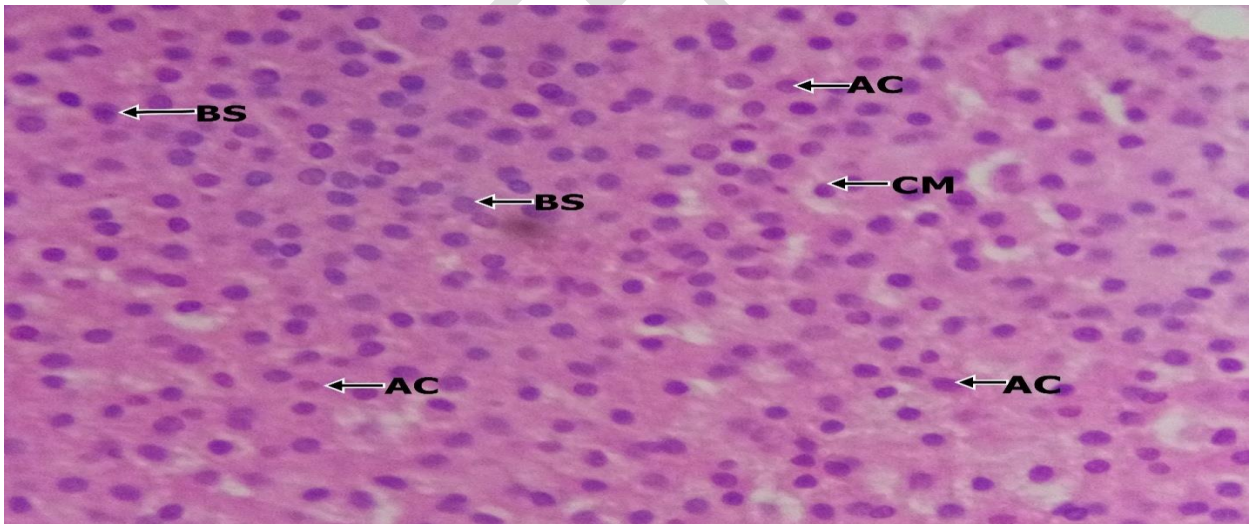
1. Iwu MM. The antimalarial activity of *Azadirachta indica* mode of action. *Pharma World*. 1993, 3: 16-20.
2. Mohajeri D, Mousavi G, Mesgari M, Doustar Y, Nouri MHK. Subacute toxicity of *Crocus Sativus* L. (Saffron) stigma ethanolic extract in rats. *AMJ. Pharmacol Toxicol*, 2007, 2 (4): 189-93.
3. Mohajeri A, Hemmateenejad B, Mehdipour A. Effects of Saffron (*Crocus Sativus* L.) and its active constituent, crocin on recognition and spatial memory after chronic cerebral hypo-effusion in rats. *Phytother Res*, 2008, 26 (3): 381-386.
4. Khayatnouri M. Seyed ES, Safarmashaei S, Darvough BB. The effects of Saffron orally administration on spermatogenesis index in rats. *Adv Environ Biol*. 2011, 5: 1514-1521.
5. Sindiga I. Traditional medicine in Africa: an introduction. Pp. 1995, 1-15 in *Traditional Medicine in Africa*. East African Educational Publishers Limited.

6. Ejeh SA, Abu HA, Onyeyili PA, Abenga JN, Ogbe RJ, Abalaka SE. Acute and sub-acute toxicological evaluation of ethanol extract of *Alchornea cordifolia* leaves in Wistar rats. *Scientific African*. 2023, 19: e01575.
7. Olayele MT, Adegboye OO, Akindahunsi AA. *Alchornea cordifolia* extract protects Wistar albino rats against acetaminophen-induced liver damage. *Afri J Biotechnol*. 2006, 5: 2439-2445.
8. Ansah C, Woode E, Oppong E. Subacute oral toxicity assessment of *Alchornea cordifolia* (Schumacher and Thonn) Mull Arg (Euphorbiaceae) extract in rats. *Trop J Pharm Res*. 2011, 10 (5): 587-594.
9. Anani SE, Oku ME, Eru EM, Uruakpa KC, Bassey IF, Udo-affah GU et al. Neuroprotective effect of *Dacryodes edulis* ethanolic leaf extract on the prefrontal cortex and long-term learning and memory in Wistar rats of ketamine-induced neurotoxicity. *Asian J Res Rep Neurol*. 2024, 7 (1): 86-97.
10. Anani SE, Nnenna WA, Agaba EA, Umoh NM, Bassey IF, Eru EM et al. Neuroprotective effect of *Dacryodes edulis* ethanolic leaf extract on the hippocampus of rats of Ketamine-Induced neurotoxicity. *Asian J Res Rep Neurol*. 2024, 7 (1): 130-145.
11. Eru EM, Gabriel UU, Ifiok FB, Kelechi CU, Samson OP, Michael EO et al. Efficacy of aqueous extract of *Talinum triangulare* on the microanatomy of the hippocampus and short-term memory of scopolamine hydrobromide-induced Alzheimer's type cognitive dysfunction rats. *Niger. J. Physiol. Sci*. 2024;39 (in press).
12. Paulinus SO, Eru EM, Udo-Affah GU, Oku ME, Bassey IF, Uruakpa KC. Lipid peroxidation and glutathione level following scopolamine-induced cognitive dysfunction in rats: potentials of *Telfairia occidentalis* seeds and *Talinum triangulare* leaves aqueous extracts. *Asian J Res Rep Neurol*. 2024, 7 (1): 98-106.
13. Eru EM, Anani SE, Paulinus SO, Otu ME, Uruakpa KC, Umoh NM, et al. Scopolamine-induced Alzheimer's disease in Wistar rats: aqueous *Talinum triangulare* potency on the hippocampal Nissl bodies and long-term learning and memory. *Trop J Nat Prod Res*. 2022, 6 (11): 117-122.
14. Eru EM, Paulinus SO, Udo-affah GU, Uruakpa KC, Oku ME, Anani SE, et al. Hippocampal astroglial reduction in scopolamine hydrobromide-induced Alzheimer's cognitive dysfunction Wistar rats following administration of *Telfairia occidentalis* (Hoof F.) *Niger J Physiol Sci*. 2021, 36: 241-244.
15. Eru EM, Udo-Affah GU, Paulinus SO, Uruakpa KC, Oku ME, Anani SE, et al. Restorative potentials of aqueous *Telfairia occidentalis* seeds extract on the hippocampal Nissl granules and short-term memory in Scopolamine hydrobromide-induced Alzheimer's type cognitive dysfunction rats. *Trop J Nat Prod Res*. 2021; 5(1):182-187.
16. Bassey IF, Udo-affah GU, Eru EM, Umoh NM, Mathias OA, Nnenna WA et al. Histochemical study of Nissl substance and astrocytes in a pentylenetetrazole-induced model of epilepsy treated with *Musa paradisiaca* stem juice. *Niger. J. Physiol. Sci*. 2024;39: (in press).

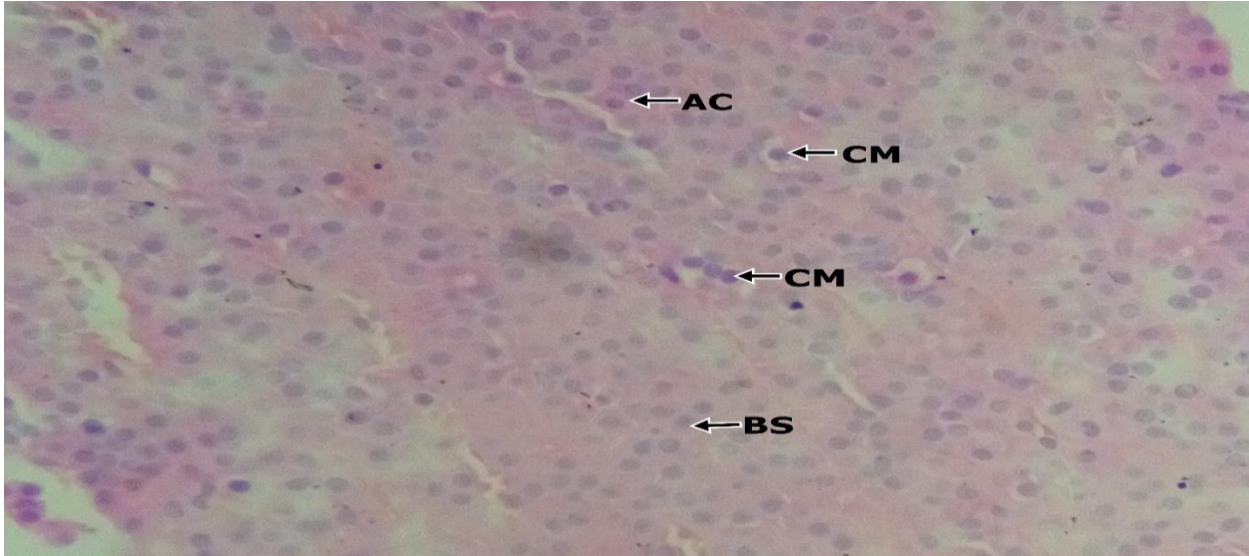
17. Chin BM, Orlandi RR, Wiggins RH. Evaluation of the sellar and parasellar regions. *Magn Reson Imaging Clin N Am*. 2012, 20 (3): 515-543.
18. Charlton H. Hypothalamic Control of Anterior Pituitary Function; A History. *Journal Neuroendocrinology*, 2008 20 (6): 641-6 Dio: 10.1111/j.1365-2826.01718.x PMID.18601683
19. Stefaneanu L, Kovacs K. Effects of drugs on pituitary fine structure in laboratory animals. *J Electron Microscop Tech*. 1991, 19 (1): 80-89.
20. Pamela O, Francis A, Celestine A, Ifeoma A, Choice N, Pamella A. et al. The effect of aqueous leaf extract of *Adansonia digitate* (baobab) on diabetes mellitus and the anterior pituitary of adult male Wistar rats. *J Diabet Endocrinol*. 2019, 10 (3): 18-19.
21. Pearse AGE. PAS. *Histochem Theoretical Appl*. 1953, 329-358.
22. Goueh G, Allassane K, John KK, Koffi K. Assessment of the acute, subacute and subchronic toxicity of a total aqueous extract of leaves of *Alchornea cordifolia* (Schumach and Thonn) Mull Arg (Euphorbiaceae) on Wistar rats. *J Pharmacog Phytochem*. 2021, 10 (1): 1609-1614.
23. Akanmu MA, Adeloye AO, Obuotor EM, Adelusola KA, Iwalewa EO, Ukponmwan OE. et al. Acute and sub-chronic toxicity potential effects of *Alchornea cordifolia* (Euphorbiaceae) in rats. *Niger J Nat Prod Med*. 2010, 14.
24. Ezeokeke EE, Ene AC, Igwe CU. Subacute toxicity studies of *Alchornea cordifolia* leaf extract in Swiss albino rats. *J Anal Bioanal Tech*. 2017, 8: 353.
25. Ajibade TO, Olayemi FO. Reproductive and toxic effects of methanol extract of *Alchornea cordifolia* leaf in male rats. *Andrologia*. 2014, 47 (9): 1034-1040.
26. Ansah C, Oppong E, Woode E, Duwiejua M. Toxicity studies on *Alchornea cordifolia* leaf extract in Mice. *J Sci Tech*. 2009, 29 (1).
27. Mensah MLK, Komlaga G, Forkuo AD, Firempong C, Anning AK, Dickson RA. Toxicity and safety implications of herbal medicines used in Africa. [Online]. 2019 [cited on 2024 October 10]. Available: <https://www.intechopen.com/chapters/58270>.



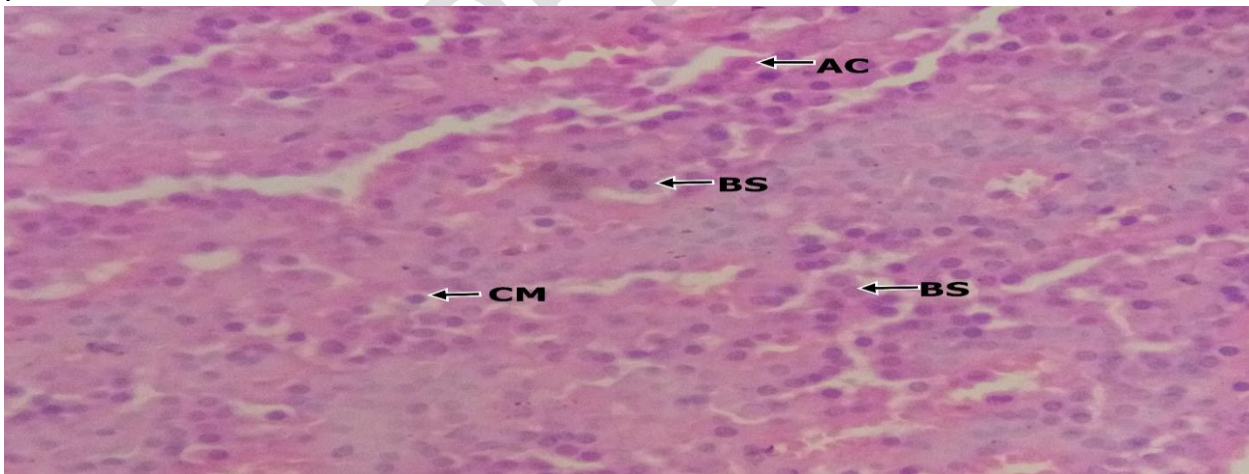
**Plate 1:** Photomicrograph (X400) of a section of anterior pituitary gland (H&E stain section) of group A rats (normal control group) showing cell clusters with oval to round nuclei having abundant cytoplasm. The cell clusters are separated by thin dilated and congested capillaries. The predominant cells have prominent nuclei with an abundant eosinophilic cytoplasm. Sparsely populated basophilic cells are scattered within the field with few cells having clear cytoplasm. AC= Acidophilic cells, BS= Basophilic cells, CM= Chromophils.




**Plate 2:** Photomicrograph (X400) of a section of anterior pituitary gland (H&E stain section) of group B rats (500mg/kg of extract). Section shows cell clusters with round to oval nuclei having abundant cytoplasm and separated by blood vessels. The predominant cells have abundant basophilic cytoplasm with deeply stained nuclei. There are few acidophilic cells with deeply eosinophilic nuclei having fine chromatin patterns. Sparse population of chromophils are seen. AC= Acidophilic cells, BS= Basophilic cells, CM= Chromophils.



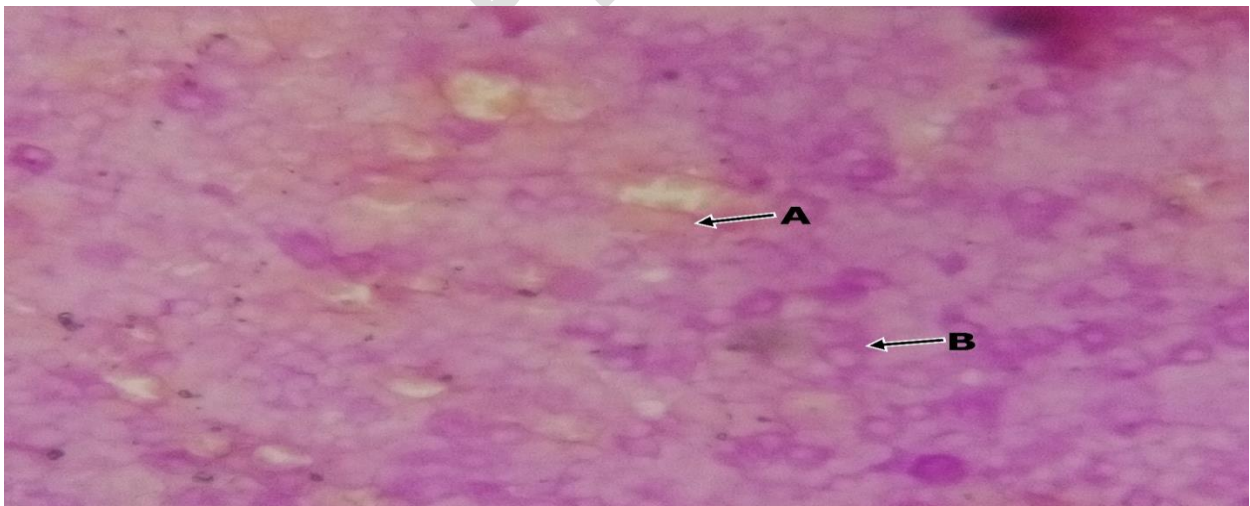
**Plate 3** Photomicrograph (X400) of a section of anterior pituitary gland (H&E stain section) of group C rats (1,000mg/kg of extract) showing cell clusters with oval to round nuclei having abundant cytoplasm and separated by blood vessels. The predominant cells are the basophilic cells which are densely populated having abundant cytoplasm and prominent nuclei. The chromophils are also sparsely distributed among the fields and the acidophils are scanty. BS= Basophilic cells, AC= Acidophilic cells, CM= Chromophils.



**Plate 4:** Photomicrograph (X400) of a section of anterior pituitary gland (H&E stain section) of group D rats (high dose group) section showing cell clusters and cords with oval to round nuclei having abundant cytoplasm and separated by blood vessels. The acidophils are densely populated with abundant eosinophilic cytoplasm. The chromophils are also sparsely distributed among the fields and the basophils are scanty. AC= Acidophilic cells, BS= Basophilic cells, CM= Chromophils.

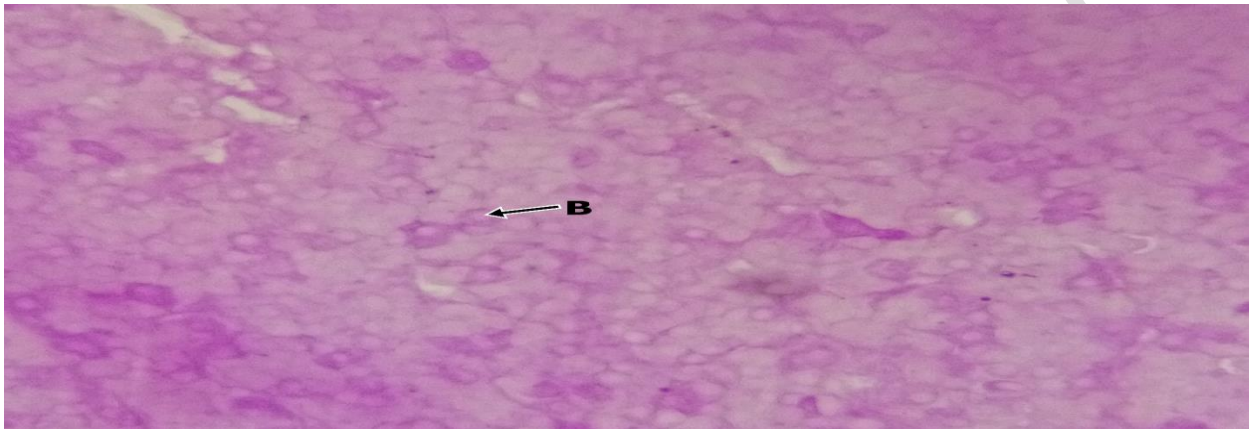


**Plate 5:** Photomicrograph (X400) of a section of anterior pituitary gland (PAS orange G. stained section) of group A rats (normal control group) showing the acidophilic cells with deeply stained orange cytoplasm (OG-POSITIVE). The basophilic cells were lightly stained blue (PAS-POSITIVE). The acidophilic cells out-number the basophilic cells. A= Acidophilic, B=.Basophilic

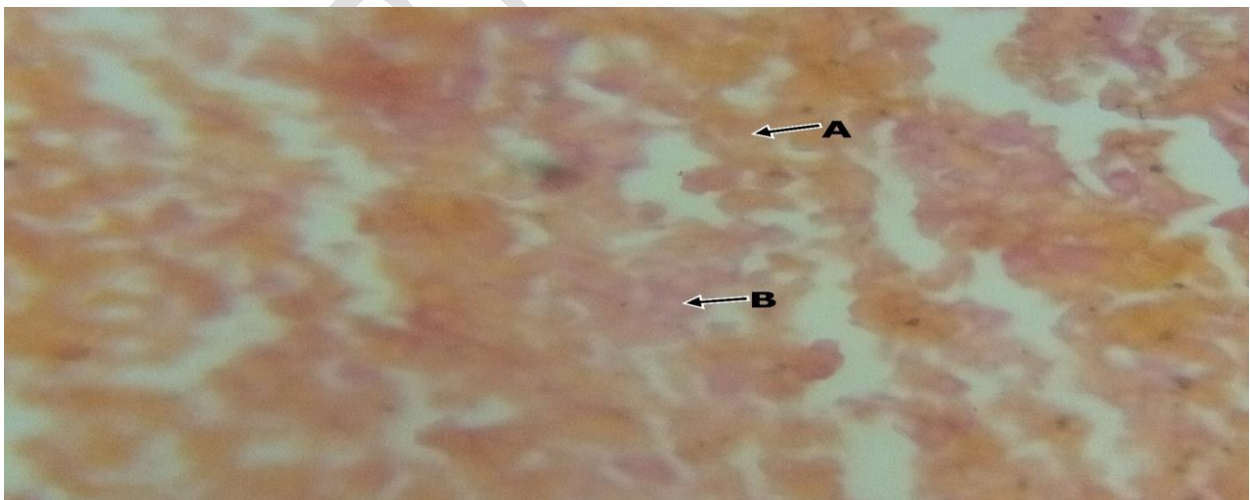


**Plate 6:** Photomicrograph (X400) of a section of anterior pituitary gland (PAS orange G stained section) of group B rats (500mg/kg of extract) showing basophilic cells that are deeply stained blue. The acidophilic cells are scanty and lightly-stained orange. The basophilic cells out-number

the acidophilic cells, hence the basophilic cells are predominant. A= Acidophilic cells, B= Basophilic cell.



**Plate 7:** Photomicrograph (X400) of a section of anterior pituitary gland (PAS orange G stained section) of group C rats (1,000mg/kg of extract) showing basophilic cells that are deeply stained blue. Also seen are prominent basophilic cells. B= Basophilic cells.



**Plate 8:** Photomicrograph (X400) of a section of anterior pituitary gland (PAS orange G stained section) of group D rats (1,500mg/kg of extract) showing acidophilic cells with deeply stained orange. A= Acidophilic cells, B= Basophilic cell.

orange cytoplasm. The basophilic cells are scanty and lightly stained blue. The acidophilic cells are predominant. A= Acidophilic cell, B= Basophilic cells.

UNDER PEER REVIEW