

Vaginal hysterectomy for uterine inversion caused by uterine leiomyosarcoma about a case.

ABSTRACT :

We report a case of uterine leiomyosarcoma initially diagnosed on pathological examination of a vaginally performed interannexal total hysterectomy specimen for a giant 10 cm/8 cm fibroid delivered through the cervix prolapsed out of the vulva and causing acute neglected uterine inversion in a 30-year-old nulliparous patient with a history of a 4x3x2 cm submucosal myoma on pelvic ultrasound.

Keywords : vaginal total hysterectomy; neglected acute non-puerperal uterine inversion; uterine leiomyosarcoma; submucosal myoma; giant fibroid delivered through the cervix; uterine cervix.

INTRODUCTION :

Vaginal hysterectomy is the surgical removal of the uterus using the vagina as an approach, and is the preferred approach according to several studies [1,2].

Non-puerperal or acute gynaecological uterine inversion is a rare clinical situation. Leiomyosarcoma is a possible etiology. Given the urgency of the situation in most cases, especially hypovolemic shock, vaginal total hysterectomy is the safest and most reliable surgical technique.

Uterine leiomyosarcoma is a rare malignant conjunctival tumor with a poor prognosis, representing between 2 and 6% of malignant tumors of the uterine body [3,4]. It is the most frequent type of uterine sarcoma, developing from the myometrium and most often presenting as a banal myoma or in necrobiosis. Anatomopathological diagnosis is often made on the surgical specimen. The gold standard of treatment is surgery, while the role of adjuvant therapies remains debated [3,5,6].

CASE REPORT :

A 30-year-old nulliparous patient with a history of submucosal myoma measuring 4x3x2 cm, discovered on pelvic ultrasound one year ago, presented to the gynaecological emergency department with a 2-day history of a mass outside the vulva, pelvic pain and genital haemorrhage.

General examination revealed a pale facies, arterial hypotension 90/50 mmHg, heart rate 150 bpm and dizziness. Gynaecological examination revealed a whitish, hard, bumpy, irregular, pedunculated mass, externalized outside the vulva, measuring 10/8 cm, independent of the vaginal walls and connected to the left side of the cervix prolapsed outside the vulva by a thick pedicle, clinically suggestive of a giant uterine fibroid delivered through the cervix prolapsed outside the vulva. Examination revealed incipient necrosis of the prolapsed cervix. Attempts to reduce and reposition the mass were unsuccessful.

An emergency laboratory workup showed a hemoglobin of 7 g/dl. The patient was transfused with 4 packed red blood cells, and an indwelling urinary catheter was inserted.

Suprapubic ultrasound revealed no uterus or ovaries, but an intravaginal mass. After clinical examination and pelvic ultrasound, the diagnosis was that of acute uterine inversion secondary to a giant submucosal fibroid delivered through the cervix prolapsed outside the vulva, given the patient's previous history.

The patient was admitted to hospital and her hemodynamic status was restored. The decision to perform a total inter-annexal vaginal hysterectomy was taken after consultation and consent from the patient.

The patient was transfused during the operation, which began with exeresis of the giant fibroid, reduction and repositioning attempts were again unsuccessful, and the hysterectomy began with an anterior colpotomy with careful vesico-uterine detachment, followed by an annular incision of the posterior lip of the uterine cervix and posterior detachment of the douglas cul de sac, then ligation-section of the right and left uterosacral ligaments, then ligation-section of the right and left uterine arteries, then

opening of the vesico-uterine peritoneum and of the douglas, then ligation-section of the right and left round ligaments, then ligation-section of the right and left utero-ovarian pedicles, and finally a total inter-annexal hysterectomy and closure of the vaginal slice. The operation was carried out without any notable incident. Surgical specimens were sent for anatomopathological study.

Post-operative monitoring showed an improvement in the patient's condition, with hb=8.6g/dl two days after surgery. Given the positive evolution, the patient was discharged from hospital on the fifth day after the operation.

Pathology of the surgical specimens showed a leiomyosarcoma, and the patient underwent further work-up concluding in stage 1 leiomyosarcoma. After discussion of the patient's case, chemotherapy and pelvic radiotherapy were ruled out, and it was decided to see the patient every 3 months for 3 years, then every 6 months for 3 years, then once a year for up to 10 years.

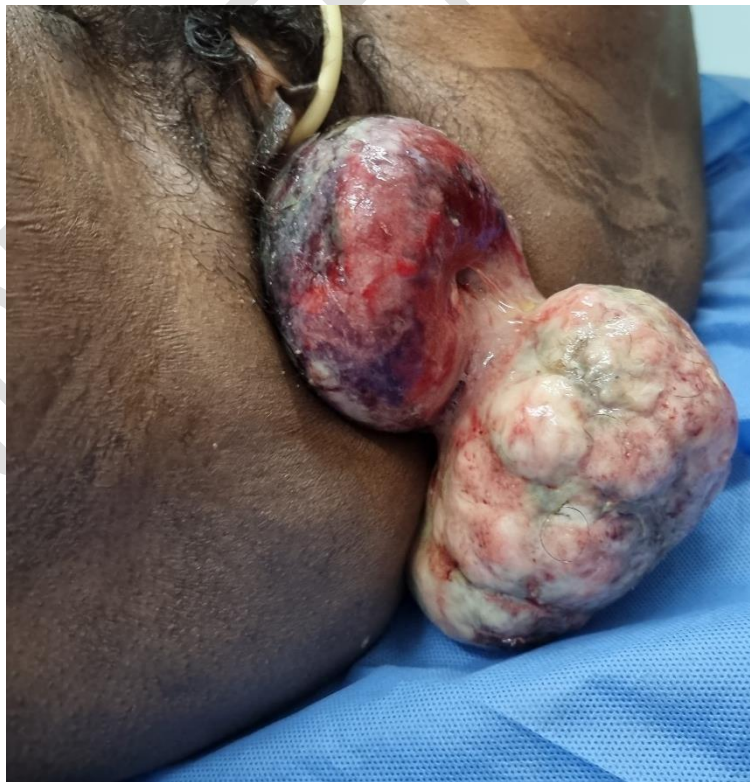

Figure 1 : Uterine leiomyosarcoma presenting as a giant 10/8 cm uterine fibroma delivered through the cervix which is also prolapsed out of the vulva.

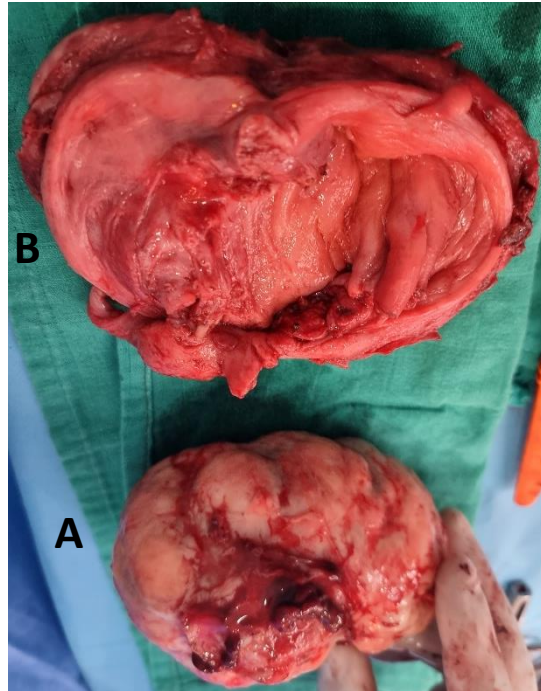


Figure 2 : Leiomyosarcoma presenting as a uterine fibroid delivered through the cervix (A), inverted uterus excised (B).

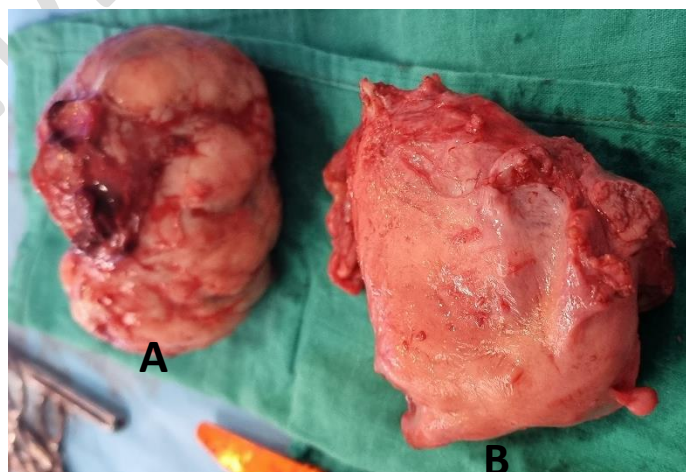


Figure 3 : Surgical specimens from vaginal myomectomy (A) and total hysterectomy (B) sent for anatomopathological study. The uterus is reshaped after excision.

DISCUSSION :

The classic technique of vaginal hysterectomy has been described for many years and is now widespread throughout the world [7]. Récamier performed the first regulated vaginal hysterectomy in 1829, on a prolapsed uterus carrying a malignant fungus [8]. Czerky performed the first hysterectomy on a non-prolapsed uterus in 1878 [9].

The advantages of vaginal hysterectomy are numerous : shorter operating time, shorter hospital stay, shorter convalescence, no abdominal scarring. Reiner [10] and Hancock [11] have even reduced the hospital stay for their vaginal hysterectomies to one day. Disadvantages include : limited operative field, limited uterine volume and patient history, more frequent bladder wounds.

Patient positioning is of paramount importance : upper limbs in supination fixed on armrests, supine position, buttocks overhanging the table, thighs flexed over abdomen, legs at the zenith, pedal pulses checked before drapes are applied, indwelling bladder catheter inserted after drapes are applied.

The surgical technique consists of infiltration of the cervix, pericervical incision, opening of the posterior cul de sac, ligation and section of the uterosacral ligaments, ligation and section of the uterine vessels, posterior tilting of the uterus, opening of the anterior cul de sac, ligation and section of the utero-ovaries, followed by vaginal closure [12].

Vaginal hysterectomy is the least invasive option. It begins by opening the bottom of the vagina around the cervix, then freeing the body of the uterus from its lateral ligamentous and vascular attachments to extract the entire uterus.

The anatomical conditions recognized as favorable for the vaginal route are classically an open pubic ogive, a supple perineum and vagina, and a uterus that can be mobilized in all directions and is of reasonable volume. These notions are in fact highly subjective, and there is no substitute for the surgeon's experience. As far as uterine volume is concerned,

a polymyomatous uterus is preferable to an overall increase in volume, as it is more accessible to morcellation.

The technique of vaginal hysterectomy has been extensively described in numerous surgical textbooks. Specific instrumentation is available (vaginal Deschamps needle, Mangiagalli posterior valve, Breisky valves), and in the case of large uteri, additional volume-reduction procedures are of interest, such as : first amputation of the cervix followed by hemisection of the uterine body, single or multiple internal myomectomy, morcellation. These procedures, usually performed after ligation of the uterine pedicles to limit blood loss, enable hysterectomy of uteruses whose volume precludes “monobloc” removal.

Increased caution is recommended during the anterior stage of bladder detachment and opening of the vesico-uterine peritoneal cul-de-sac. For several authors, Caesarean section is not a particular factor of failure for vaginal hysterectomy [13, 14].

However, the vaginal approach is often difficult in cases of voluminous polymyomatous and/or non-prolapsed uterus, with uterine arteries and adnexal pedicles sometimes difficult to control vaginally.

Vaginal hysterectomy using the V-NOTES technique (Vaginal-Natural Orifice Transluminal Endoscopic Surgery) is an innovative technique in the field of minimally invasive surgery, offering a number of advantages. The excellent view of the peritoneal cavity, with easy vaginal access, gives surgeons and operating assistants a comfortable, ergonomic and safe working environment. It also makes it possible to envisage vaginal hysterectomy using a combined laparoscopic-vaginal approach [15]. It was first described in gynecology in 2012 [16,17]. It uses conventional laparoscopic and vaginal surgical instruments, an Alexis retractor and an access platform specifically designed for vaginal laparoscopy (Gel point V-Path™, Applied Medical, Santa Margherita, USA). This technique enables permanent visual inspection of adjacent structures, complete exploration of the peritoneal cavity and better control of lumbo-ovarian pedicles when performing adnexectomy or salpingectomy.

Uterine inversion is defined as the inverting of the uterus into a finger or “uterine invagination”. It is a rare pathology, more frequent in obstetrics than in gynecology. Uterine inversion is serious, and can be life-threatening due to the hypovolemic shock it causes [18].

The etiology found in 70 to 85% of cases of gynaecological uterine inversion, depending on the author, is submucosal myoma [19]. In 15 to 30% of cases, malignant tumors are involved, with uterine sarcomas (leiomyosarcoma, embryonal rhabdomyosarcoma, endometrial stromal sarcoma) at the forefront.

Depending on severity, four degrees of inversion are distinguished [19] : first degree : the uterine fundus is depressed into a “cul de fiole” or cupula, second degree : the inverted uterus passes through the external orifice of the cervix, third degree : the uterine body becomes intravaginal and may become completely externalized, fourth degree or total inversion : the vaginal walls participate in the inversion. Hysterectomy is virtually indispensable in cases of 3rd and 4th degree uterine inversion [20].

Uterine leiomyosarcoma is a rare malignant tumour of connective nature, developed at the expense of mesenchymal elements of the myometrium [21]. The relative frequency is 1.3% of all uterine cancers [22] and corresponds to 40-50% of uterine sarcomas. There is Classical uterine leiomyosarcoma and the epithelioid and myxoid variants.

There are 2 leiomyosarcomas per 1,000 uterine fibroids [22,23]. They are characterized by great anatomopathological heterogeneity. Their prognosis is poor, with a five-year survival rate of around 30% [3,24]. They must be diagnosed early, as patient survival correlates with tumour stage [3]. Recurrence rates for leiomyosarcomas vary from 35 to 70%, depending on the author. Most often affecting the pelvis, they occur within two years of diagnosis.

Treatment is essentially surgical, and must be complete from the outset [25,26]. The first stage of the operation involves peritoneal cytology and exploration of the abdomen. Most authors perform a non-conservative hysterectomy, although some have shown that ovarian conservation does not affect survival. Complementary procedures depend on the degree of exploration : visceral excision depending on extension, and pelvic curage if adenopathies are palpated. Radiotherapy reduces the incidence of pelvic recurrence, but does not improve overall survival [25,27,28] : its place should be discussed on a case-by-case basis. Post-operatively, radiotherapy may be proposed when exeresis is incomplete due to disease extension, and in the absence of surgical revision. When surgery is contraindicated or refused by the patient, exclusive radiotherapy may also be discussed.

Chemotherapy may be offered before surgery if the tumour is deemed unresectable from the outset, or after surgery if tumour resection was less than optimal, or in the case of

distant metastases. The main protocols include cis-platinum, adriamycin and ifosfamide, and more recently gemcitabine and docetaxel [27]. When a leiomyosarcoma is found histologically on a hysterectomy specimen, no adjuvant treatment is required, and in particular, there is no need to reintervene for lymph node staging, as leiomyosarcomas are not very lymphophilic. However, it is preferable to carry out an extension work-up to ensure that there are no pulmonary or abdominal metastases (chest X-ray and abdomino-pelvic CT scan). Depending on the histological risk of uterine invasion, postoperative radiotherapy may be proposed.

In stage 1, the tumor is located only in the uterus. Stage 1 is divided into stages 1A and 1B. In stage 1A, the tumor measures 5 centimeters or less. In stage 1B, the tumor measures more than 5 centimeters.

In our patient, the leiomyosarcoma presented as a giant fibroma delivered through the cervix prolapsed out of the vulva with acute uterine inversion neglected. Total vaginal hysterectomy is the technique of choice and represents the radical treatment given that the extension workup concludes stage 1.

CONCLUSION :

Leiomyosarcoma is a rare cancer with a poor prognosis. It is rarely diagnosed preoperatively, and most often presents as a benign myoma or necrobiosis. The main prognostic factor is mitotic activity. Treatment is dominated by surgery. Radiotherapy can only reduce local recurrence without altering survival, and chemotherapy has not proved effective.

When the tumor is confined to the uterus (stage 1), as described in our case and presenting as a giant fibroid delivered through the cervix prolapsed out of the vulva and causing uterine inversion, treatment consists of total hysterectomy via the vaginal route, which deserves to be taught as a reference technique in surgical schools.

REFERENCES :

1- Cosson. M, Hysterectomy: past, present, future. Lille 1991 thesis.

- 2-** Lansac J, Lecomte P Gynaecology for the Practitioner; 3rd Edition. November 1988, page 13 to 42.
- 3-** Salazar OM, Bonfiglio TA, Patten SF, Keller BE et al. Uterine Sarcomas: natural history, treatment and prognosis. *Cancer*. 1978 Sept; 42(3):1152-60. PubMed | Google Scholar
- 4-** Livi L, Paiar F, Shah N, Blake P et al. Uterine sarcoma: twenty-seven years of experience. *Int J Radiat Oncol Biol Phys*. 2003 Dec 1;57(5):1366-73. PubMed | Google Scholar
- 5-** Acharya S, Hensley ML, Montag AC, Fleming GF. Rare uterine cancers. *Lancet Oncol*. 2005 Dec;6(12):961- 71. PubMed | Google Scholar
- 6-** Livi L, Andreopoulou E, Shah N, Paiar F et al. Treatment of uterine sarcoma at the Royal Marsden Hospital from 1974 to 1998. *Clin Oncol (R Coll Radiol)*. 2004 Jun;16(4):261- 8. PubMed | Google Scholar
- 7-** Aarts JWM, Nieboer TE, Johnson N, Tavender E, Garry R, Mol BWJ, et al. Surgical approach to hysterectomy for benign gynaecological disease. *Cochrane database Syst Rev* 2015;2015(8):CD003677.
- 8-** Recamier JCA. Observation of a fungus of the matrix cured by extirpation of this organ with the aid of ligatures. *Rev Med Fr Etr* 1825; 4: 39.
- 9-** Pozzi S. *Traité de gynécologie clinique et opératoire*. Paris: Masson; 1905.
- 10-** Reiner JJ. Early discharge after vaginal hysterectomy. *Obstet Gynecol* 1988 ; 71 : 416-8.
- 11-** Hancock KW, Scott JS. Early discharge following vaginal hysterectomy. *Br J Obstet Gynaecol* 1993 ; 100 : 262-5.
- 12-** M.COSSON, inter-university diploma in vaginal surgery, lille, march 2023.
- 13-** Sheth SS, Malpani AN. Vaginal hysterectomy following previous cesarean section. *Int J Gynaecol Obstet* 1995 ; 50 : 165-9.
- 14-** Unger JB, Meeks GR. Vaginal hysterectomy in women with a history of previous cesarean delivery. *Am J Obstet Gynecol* 1998 ; 179 : 1473-8.
- 15-** Baekelandt JF, De Mulder PA, Le Roy I, Mathieu C, Laenen A, Enzlin P, et al. Bosteels hysterectomy by transvaginal natural orifice transluminal endoscopic surgery versus laparoscopy as a day-care procedure: a randomised controlled trial. *J BJOG* 2019;126(1):105–13.
- 16-** Zorro'n R, Filgueiras M, Maggioni LC, Pombo L, Lopes Carvalho G, Lacerda Oliveira A. NOTES. Transvaginal cholecystectomy: report of the first case. *Surg Innov* 2007;14(4):279–83.
- 17-** Su H, Yen C-F, Wu K-Y, Han C-M, Lee C-L. Hysterectomy via transvaginal natural orifice transluminal endoscopic surgery (NOTES): feasibility of an innovative approach. *Taiwan J Obstet Gynecol* 2012;51(2):217–21.
- 18-** Beringer RM, Patteril M. Puerperal uterine inversion and shock. *Br J Anaesth*. 2004;92(3):439-4. PubMed | Google Scholar
- 19-** Lupovitch A, Edwin R, Ruey C. Non-puerperal uterine inversion in association with uterine sarcoma: case report in a 26-year-old and review of the literature. *Gynecol Oncol*. 2005;97(3):938- 41. PubMed | Google Scholar

- 20-** Pelissier-Komorek A, Lucereau-Barbier M, Diab J, Gavillon N, Graesslin O. Acute non-puerperal uterine inversion the third degree. *Gynécologie Obstétrique & Fertilité*. 2013;41(2):130- 2. PubMed | Google Scholar
- 21-** Van Dinh T, Woodruff JD. Leiomyosarcoma of the uterus. *Am J Obstet Gynecol*. 1982 Dec 1;144(7):817- 23. PubMed | Google Scholar
- 22-** Schwartz LB, Diamond MP, Schwartz PE. Leiomyosarcomas: clinical presentation. *Am J Obstet Gynecol*. 1993 Jan;168(1 Pt 1):180-3. PubMed | Google Scholar
- 23-** Leibsohn S, Ablain G, Mishell DR Jr, Schlaerth JB. Leiomyosarcoma in a series of hysterectomies performed for presumed uterine leiomyomas. *Am J Obstet Gynecol*. 1990 Apr;162(4):968-74 discussion 974-6. PubMed | Google Scholar
- 24-** Nordal RR, Thoresen SO. Uterine sarcomas in Norway 1956- 1992: incidence, survival and mortality. *Eur J Cancer*. 1997 May;33(6):907-11. PubMed | Google Scholar
- 25-** Socolov RV, Pricop FZ, Stratan D. The malignancy of uterine sarcoma compared with suspected leiomyomas: an anatomo-clinical study of 16 cases. *Rev Fr Gynecol Obstet*. 1992 Oct;87(10):457-60. PubMed | Google Scholar
- 26-** Gerst PH, Levy J, Swaminathan K, Kshetry V, Albu E. Metastatic leiomyosarcoma of the uterus: an usual presentation of a case with late endobronchial and small bowel metastases. *Gynecol Oncol*. 1993 May;49(2):271- 5. PubMed | Google Scholar
- 27-** Echt G, Jepson J, Steel J, Langholz B et al. Treatment of uterine sarcoma. *Cancer*. 1990 Jul 1; 66(1):35- 9. PubMed | Google Scholar
- 28-** Major FJ, Blessing JA, Silverberg SG, Morrow CP et al. Prognostic factors in early-stage uterine sarcoma; A Gynecologic Oncology Group study. *Cancer*. 1993 Feb 15;71(4 Suppl):1702-9. PubMed | Google Scholar