

TRANSIENT BRUGADA-LIKE AFTER SCORPION STING: AN UNEXPECTED CONNECTION

ABSTRACT :

Introduction :Brugada syndrome was described in 1992 as a new clinical and electrocardiographic syndrome involving susceptibility to ventricular arrhythmias and sudden cardiac death in patients without obvious structural heart disease. Brugada phenocopy (BrP) is an evolving term for Brugada-like ECG patterns due to reversible causes. In this article, we will illustrate the case of a patient presenting with a transient Brugada pattern following a scorpion sting.

Observation du cas : A 65-year-old woman with age and menopause as cardiovascular risk factors, but no notable medical history, presented to the emergency department with atypical chest pain five hours after a scorpion sting. She had no associated symptoms such as dyspnoea, syncope, or palpitations, nor a personal or family history of sudden death. On admission, she was conscious, hemodynamically stable, normotensive, and tachycardic, with no signs of heart failure. Her ECG showed a 2 mm elevation at the J point and an inverted T wave in V1 and V2, indicating a Brugada pattern. She was admitted to the ICU for close monitoring. An echocardiogram revealed normal left and right ventricular function. Lab tests showed negative troponins, a normal blood ionogram, and normal renal and hepatic function. The Brugada pattern resolved within a few hours, and the patient remained stable.

Discussion and Conclusion : Our case highlights the importance of conducting a thorough medical history to rule out the presence of arrhythmia, syncope, or a family history of sudden cardiac death in similar situations. If the history raises concerns, cardiological follow-up is essential to investigate the possibility of Brugada syndrome. Performing a follow-up ECG at discharge is beneficial to confirm the reversibility of the findings. This distinction is crucial as it helps differentiate between Brugada syndrome and the Brugada pattern, the latter being a condition that may occur in patients with scorpion stings or other triggers.

Key words: scorpion sting, venom, chest pain, brugada pattern, reversibility

INTRODUCTION :

Brugada syndrome was described in 1992 as a new clinical and electrocardiographic syndrome involving susceptibility to ventricular arrhythmias and sudden cardiac death in patients without obvious structural heart disease. Brugada phenocopy (BrP) is an evolving term for Brugada-like ECG patterns due to reversible causes.

In this article, we will illustrate the case of a patient presenting with a transient Brugada pattern following a scorpion sting.

CASE OBSERVATION:

The patient was 65 years old, with a cardiovascular risk factor of age and menopause, and no particular pathological history. She presented to the emergency department with atypical chest pain, which had appeared 5 hours after a scorpion sting, with no other associated signs, notably no dyspnoea, syncope or palpitation.

The patient had no previous history of syncope, and no family history of sudden death.

On admission, the patient was conscious, hemodynamically and respiratory stable, normotensive at 123/65mmhg, tachycardic at 95 bpm with no signs of right or left heart failure. The ECG on admission showed a 2 mm elevation of the domed J point and an inverted T wave in V1 and V2, suggestive of a Brugada pattern.

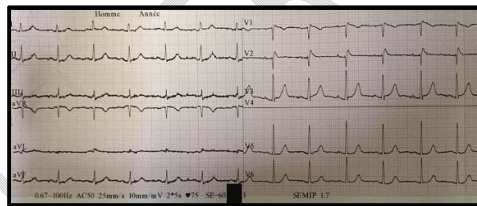


Figure 1: ECG shows a regular sinus rhythm with a 2 mm elevation of the domed J point and an inverted T wave in V1 and V2, suggestive of Brugada.

Initial management was to admit the patient to the intensive care unit for close clinical and rhythmic monitoring.

Transthoracic echocardiography revealed a non-dilated, non-hypertrophied left ventricle with preserved systolic function, 60% LVEF, no segmental or global kinetic disturbances, and a

right ventricle of preserved size and systolic function.

A laboratory work-up was ordered for this patient, with negative ultra-sensitive troponins, a normal blood ionogram, preserved renal and hepatic function, and normal CPK.

The patient remained clinically stable, with regression of the brugada pattern a few hours after admission.

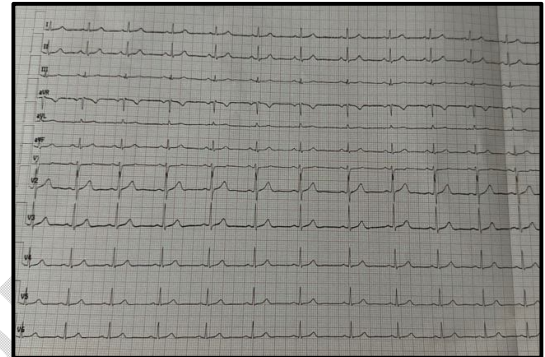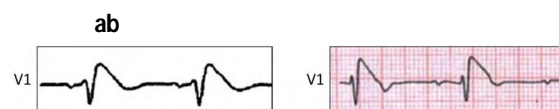


Figure 2: ECG taken a few hours later, showing resolution of the Brugada pattern.

DISCUSSION :

Brugada syndrome is characterized by an inherited sodium ion channel defect (SCN5A gene mutation) identified by a wide QRS associated with ST-segment elevation and T-wave inversion in the right precordial leads.

Brugada syndrome (BrS) is an inherited cardiac channelopathy characterized by type 1 and type 2 ECG patterns in leads V1-V3 that predispose individuals to malignant ventricular disease arrhythmias and sudden cardiac death (Fig 3, a) [1]. Phenocopy Brugada (BrP), however, there are clinical entities whose ECG patterns are identical to true congenital BrS but are caused by various factors such as electrolyte disturbances, sodium channel-blocking drugs, mechanical compression, poor ECG filters, myocardial ischemia (Fig 3, b) [2], and secondary to a scorpion sting (Fig 3, c) [3].



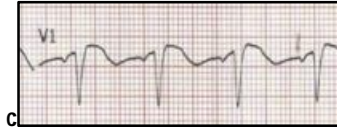


Figure 3: Comparison of true congenital Brugada syndrome and Brugada phenocopy. Classic congenital type 1. Notched Brugada ECG pattern (a) [1]. Brugada phenocopy in the setting of ischemic cardiomyopathy (b) [5]. Secondary to a scorpion sting [3]. V1 lead is identical to Brugada ECG pattern type 1. [1, 4].

The term Phenocopy was chosen because it was previously used to describe an environmental condition that mimics that produced by a gene; it has therefore served as a reasonable and succinct description of all acquired Brugada-type ECG manifestations [2].

ST-segment elevation in the right precordial leads and Brugada-type ECG patterns have already been associated with various pathologies (e.g. fever, myocarditis toxicity, metabolic disorders, certain drugs). These Brugada-like patterns usually disappear once the triggering event has been removed [5].

A scorpion sting can cause life-threatening ventricular arrhythmias. Rarely, severe scorpion envenomation can unmask Brugada phenocopy. Close follow-up is therefore warranted.

The onset of Brugada phenocopia after scorpion stinging has already been reported. It has been proposed that the intense and persistent depolarization of autonomic nerves by scorpion venom depletes intracellular sodium, manifesting as Brugada phenocopy on the ECG. Stimulation of α_3 receptors plays an important role in the pathogenesis of refractory pulmonary edema induced by scorpion sting [6]. Prazosin is a phosphodiesterase inhibitor and postsynaptic receptor blocker that acts as a physiological and pathological antidote to the actions of venom [7]. Scorpion antivenom is a venom-specific antidote, neutralizing both circulating venom and venom deposited at the sting site. Simultaneous administration of scorpion antivenom and oral prazosin has been shown to accelerate recovery from severe scorpions [8].

One possibility of Brugada like secondary to a scorpion sting lies in the effect of the venom, which acts by activating neuronal sodium channels and inhibiting calcium-dependent potassium channels. This causes a sudden release of endogenous catecholamines, resulting in an autonomic storm characterized by transient parasympathetic and prolonged sympathetic stimulation. Excessive catecholamines lead to myocardial damage, manifesting as heart failure, cardiogenic shock, conduction abnormalities, QTc prolongation and ventricular tachycardias [9]. Post-stimulation fatigue of cardiac sodium neuronal channels leads to transient Brugada phenocopy, as illustrated in our case.

Several other cases of Brugada-like patterns have been reported. Ortega-Carnicer et al [10] noted transient Brugada-like electrocardiographic abnormalities in renal failure, reversed by dialysis. They reported a patient with a history of epilepsy treated with psychotropic drugs (with a sodium channel-blocking effect) and chronic renal failure on hemodialysis who developed hyperkalemia and ECG findings resembling Brugada syndrome. These ECG changes disappeared after hemodialysis when potassium returned to normal. They concluded that hyperkalemia, as well as drugs active on the cardiac membrane, can cause ECG changes mimicking Brugada syndrome.

As a result, a Brugada-like ECG pattern presents an additional diagnostic and therapeutic challenge, as it can be observed in patients with chest pain, mimicking ST-segment elevation.

CONCLUSION :

Our case highlights the importance of conducting a thorough medical history to rule out the presence of arrhythmia, syncope, or a family history of sudden cardiac death in similar situations. If the history raises concerns, cardiological follow-up is essential to investigate the possibility of Brugada syndrome. Performing a follow-up ECG at discharge is beneficial to confirm the reversibility of the findings.

This distinction is crucial as it helps differentiate between Brugada syndrome and the Brugada pattern, the latter being a condition that may occur in patients with scorpion stings or other triggers.

REFERENCES

- [1] Bayés de Luna A, Brugada J, Baranchuk A, et al. Current electrocardiographic criteria for diagnosis of Brugada pattern: a consensus report. *J Electrocardiol*, 2012; 45: 433.
- [2] Baranchuk A, Nguyen T, Ryu MH, et al. Brugada phenocopy: new terminology and proposed classification. *Ann Noninvasive Electrocardiol*, 2012; 17:299.
- [3] Himmatrao Saluba Bawaskar, Pramodini H. Bawaskar, and Parag H. Bawaskar, 4 (1) 54–58, *Stung to the Heart, J Am Coll Cardiol Case Rep*. 2022 Jan, 4 (1) 54–58
- [4] Anselm DD, Barbosa-Barros R, de Sousa Belém L, Nogueira de Macedo R, PérezRiera AR, Baranchuk A. Brugada Phenocopy induced by acute inferior ST-segment elevation myocardial infarction with right ventricular involvement. *Inn Card Rhythm Manag*, 2013; 4: 1092.
- [5] Baranchuk A, Nguyen T, Ryu MH, et al. Brugada phenocopy: new terminology and proposed classification. *Ann Noninvasive Electrocardiol* 2012; 17:299–314.
- [6] Freire-Maia L, Campos JA, Amaral CF. Approach to the treatment of scorpion envenoming. *Toxicon*. 1994; 32(9):1009–1014.
- [7] Bawaskar HS, Bawaskar PH. Management of the cardiovascular manifestations of poisoning by Indian red scorpion (*Mesobuthus tumulus*). *Brit Heart J*. 1992; 68:478–480.
- [8] Bawaskar HS, Bawaskar PH. Efficacy and safety of scorpion antivenin plus prazosin compared with prazosin alone for venomous scorpion (*Meso-buthus Tamulus*) sting: randomised open label clinical trial. *Brit Med J*. 2010; 341:c7136
- [9] Al-Khatib SM, Stevenson WG, Ackerman MJ, et al. 2017 AHA/ACC/HRS guideline for management of patients with ventricular arrhythmias and the prevention of sudden cardiac death: a report of the American College of Cardiology/American Heart Association Task Force on Clinical Practice Guidelines and the Heart Rhythm Society. *J Am Coll Cardiol* 2018; 72:e91–220.
- [10] J Ortega-Carnicer 1, J Bertos-Polo, C Gutiérrez-Tirado, Aborted sudden death, transient Brugada pattern, and wide QRS dysrhythmias after massive cocaine ingestion, *J Electrocardiol* 2001 Oct; 34(4):345-9.