

Case Report

Facial trauma with Total Maxillectomy and Z-Pillar Rehabilitation: A Case Report

ABSTRACT

Aims: Facial trauma is one of the leading causes of mortality that affects young male adults. It has a multifactorial etiology, and the predominant causes are motor vehicle accidents (MVAs) and physical assault. Maxillectomy is a surgical procedure, partial or total removal of the jaw, either due to trauma or pathology (oral cancer). The surgical defect created can cause psychological, functional, and aesthetic disorders for the patient, making rehabilitation essential.

Case Presentation: This case report is about a 45-year-old Caucasian patient who was a victim of facial trauma due to an MVA and underwent three hospital surgeries. Prosthetic rehabilitation was done using conventional implants anchored in zygomatic bones associated with the Z-pillar and the Facco Technique. It is a rehabilitative treatment option for total maxillectomy, as it restores aesthetics and function to the patient.

Discussion: Facial trauma represents almost 9% of emergency care in Brazil's hospitals, and among the leading causes are car accidents, as occurred in the present Case Report. Maxillectomy is classified into three types (25): 1) with preservation of the orbital floor, 2) with loss of orbital support, and 3) with orbital exenteration and ethmoidectomy, as occurred in the Clinical Case Report of the present research. The Facco Technique was performed in three stages. Subsequently, the component's mini pillar was installed.

Conclusion: It can be concluded that conventional implants installed in the zygomatic bone and using the Z-pillar (Facco Technique) were a great option to rehabilitate patients who were victims of a car accident without a jawbone and reduced their treatment time. It also gave him a new chance to find his way back into society and improved his quality of life.

Keywords: Facial trauma. Jaw. Zygomatic bone.

1. INTRODUCTION

Facial trauma is the name given to any injury located on the face [1]. In Brazil, it is considered a public health problem [2] and is among the leading causes of death and morbidity in the world, according to data from the World Health Organization (WHO) [3]. The etiological factors of these facial fractures are multifactorial, but the most significant predominance is due to MVAs [4]. Studies show that the prevalence, in Brazil, of facial trauma is higher in males [5] and young adults (18 and 40 years old) [6]; its diagnosis and treatment are carried out by the Craniomaxillofacial team [7].

Maxillectomies are classified into three types [8]: 1) preservation of the orbital floor, 2) loss of orbital support, and 3) removal of orbital contents and ethmoidectomy. The procedure results in significant aesthetic and functional defects; its consequences can be nasal speech, leakage of fluids from the nasal cavity, impairment of masticatory function, and aesthetic deformity, requiring surgical and prosthetic rehabilitation [9].

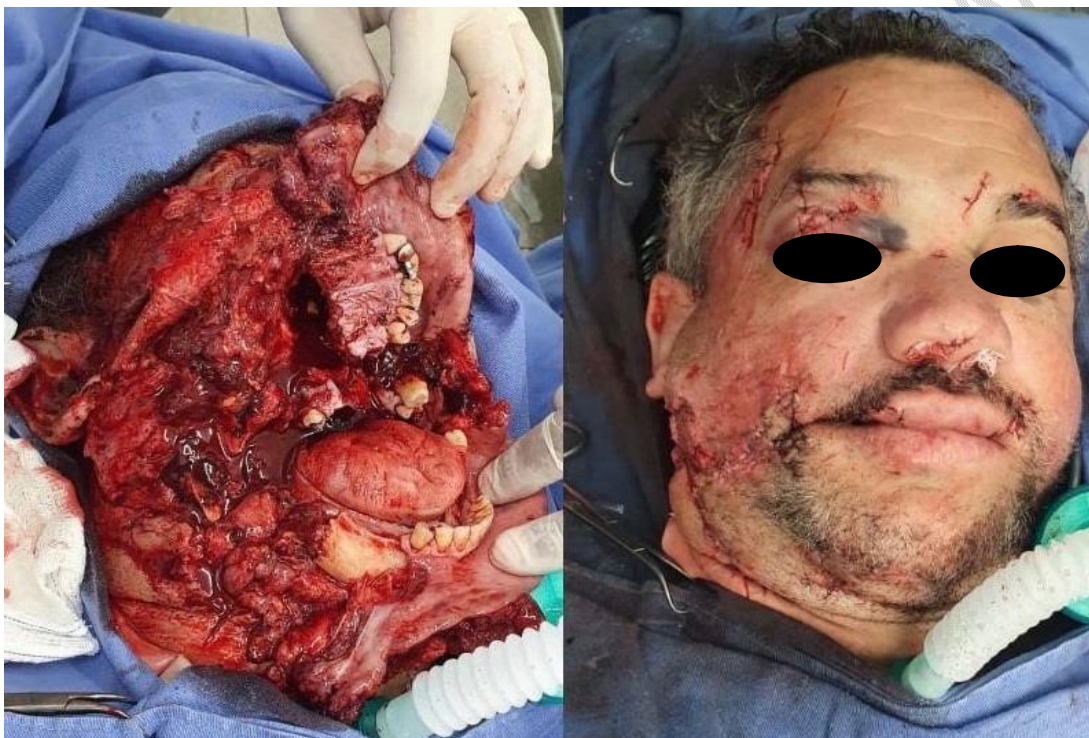Rehabilitation is performed using the zygomatic pillar (Z-pillar) and the Facco Technique [10], which is designed and developed to reduce the difficulty of zygomatic anchorage techniques [11]. In this case, an intermediate capable of connecting the implant to the alveolar ridge was used due to the previously performed maxillectomy [12].

The Z-pillar Technique consists of a zygomatic anchorage system composed of three parts [13]: a conical implant with a cone-morse connection, an initial piece of the Z-pillar, and the final piece of the Z-pillar to adjust the length of the prosthetic platform with a connection external hexagonal. The implant is installed in the zygomatic bone bilaterally [14], associated with the Z-pillar. The main advantage of this Technique is the rehabilitation of edentulous jaws, which means there is no need for bone grafting, reducing the patient's treatment time [15].

2. CASEPRESENTATION

The patient was a truck driver involved in anMVA on Via Dutra in Volta Redonda, Rio de Janeiro, Brazil, in 2021. First aid was performed at the local hospital (hemostasis, facial sutures, reduction of face fractures, and occlusal splint) (Figure 1). Patient with panfacial fractures (hemi Le Fort III on the left side, naso-orbito-ethmoid (NOE) on the right side, complete maxillary avulsion, mandibular angle fracture on the right side, and mandibular corpus on the left side).

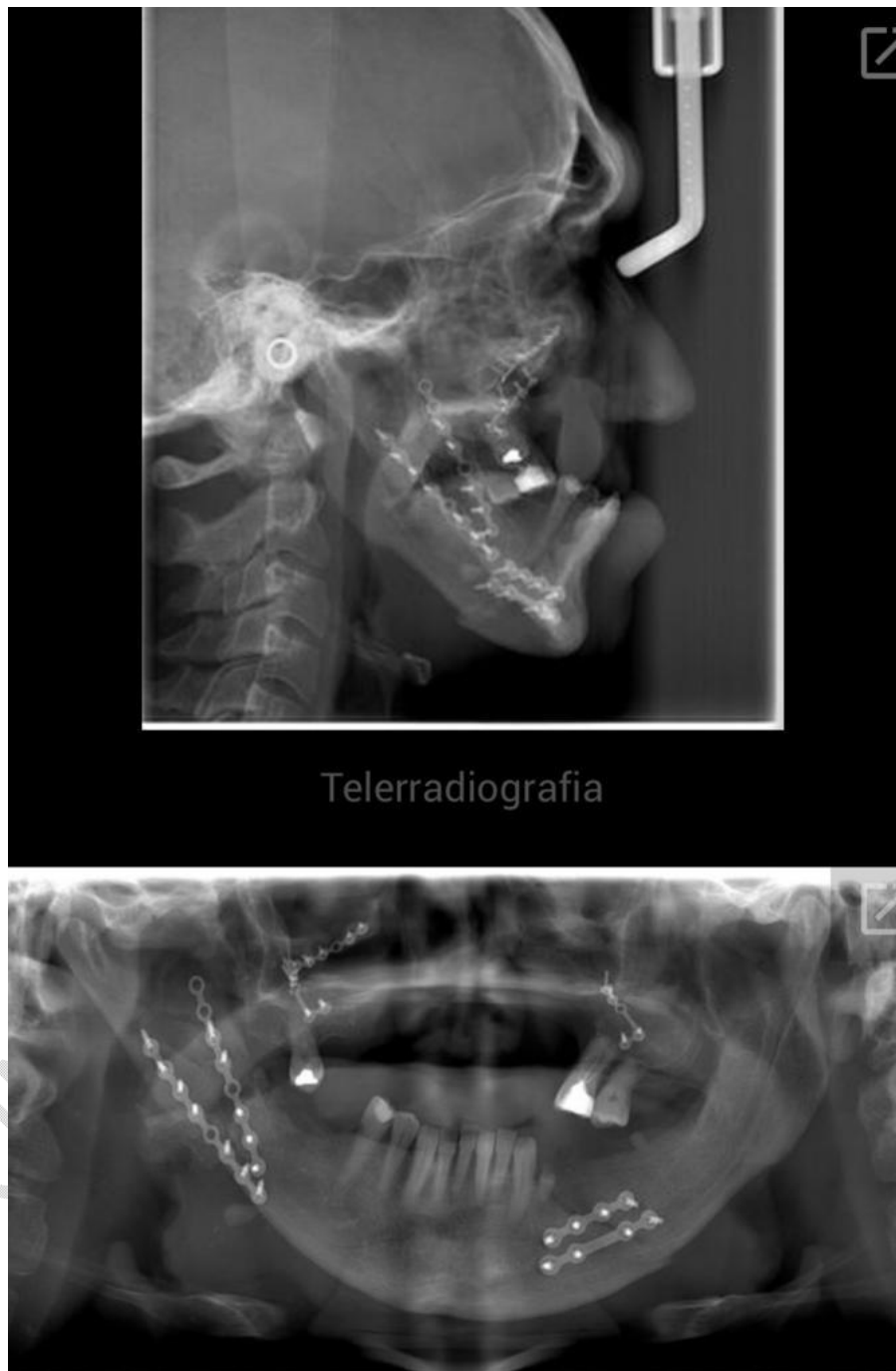
Figure 1 Emergency service (before x after surgery).



Source: Own Author

However, the maxilla was not fixed satisfactorily due to a lack of stable internal fixation material in the first hospital in Rio de Janeiro, Brazil (Figure 2). He remained in the intensive care unit for a month and presented psychomotor agitation generated by the discontinuous use of amphetamines due to his profession (truck driver). In fact, for the first surgery, the only exams available to the patient were two-dimensional images (panoramic radiography and lateral telerradiograph).

Figure 2 Unsatisfactory fixation of the jaw.

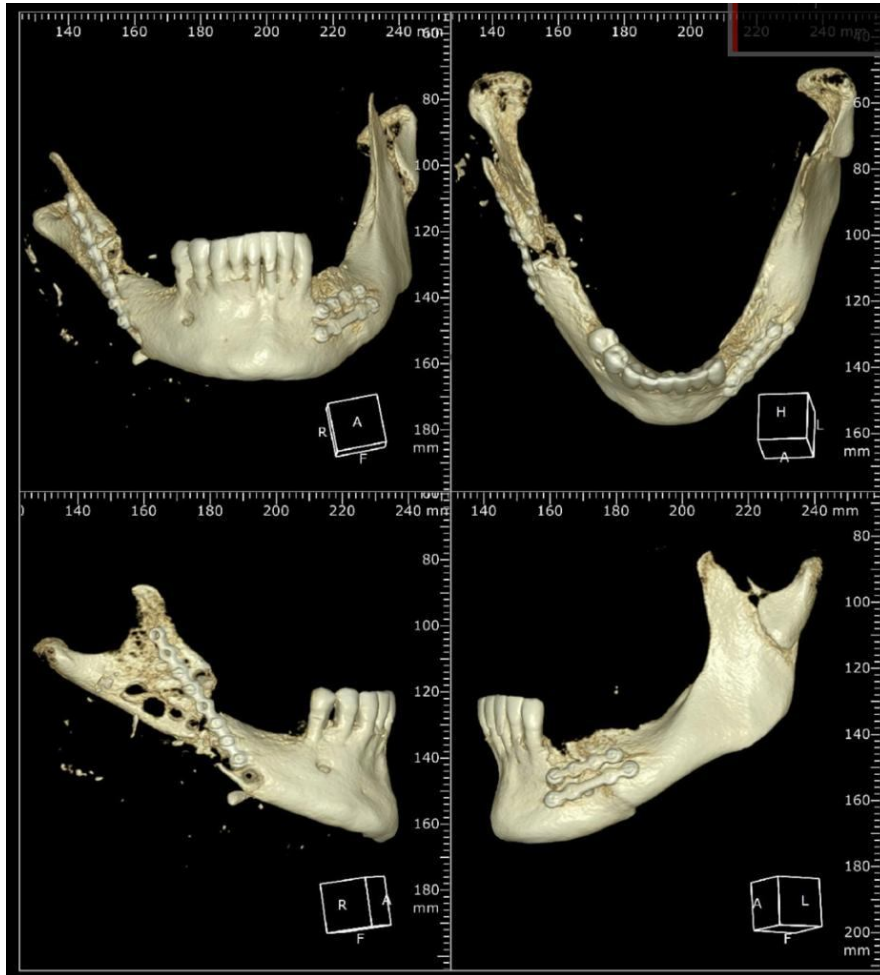


Source: Own Author

After, he was transferred to Hospital Santa Bárbara, in Santa Bárbara d'Oeste, São Paulo, Brazil, near his residence. Upon examination by a new Craniomaxillofacial team, tissue necrosis and loss of the maxilla were found due to inadequate fixation. There was nonunion of two bone segments of the mandibular corpus (right side) and malunion of

mandibular para-symphysis (left side)(Figure 3), nonunion of the nose (without the stability of fixation),malunion of the right orbit, with misalignment of the eyes, and loss of the right eyeball.

Figure 3: Nonunion of the mandibular corpus (right side)and malunion of mandibular para-symphysis (left side).



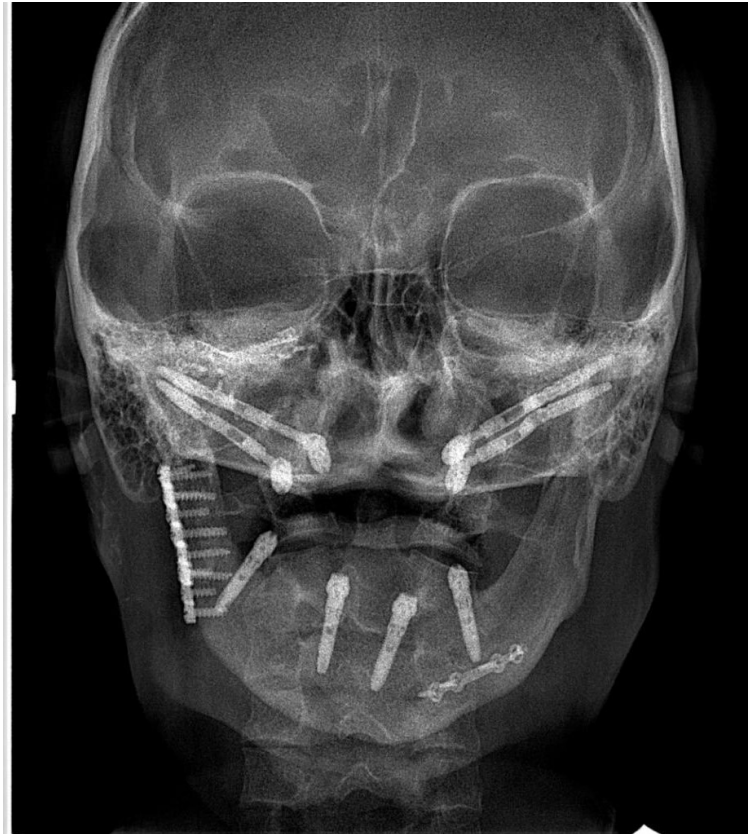
Source: Own Author

For the second surgery (correction surgery), the following procedures were adopted:1) removal of the occlusal splint, 2) removal of all previous fixation material (plates and screws) in the jaw, 3) ocular enucleation in the right orbit, 4) placement of a titanium mesh to support the globe eyepiece, in the right orbit, 5) closed reduction of the nasal bone fractures and, 6) extraction of the lower dental remnant.

One plate 2.0 was used in the para-symphysis region (left side), and one 2.4 lock plate was used in the angle jaw (right side). Thus, four implants were positioned in the mandible, two on each side, to rehabilitate with a lower protocol prosthesis.

The implants were positioned in the right and left zygomatic bone, using **four conventional** 4x17mm morse cone implants(**two for each side**), with 80N locking and Implacil Z-arm® – FACCO technique (with movement above 180°). (Figure 4). Pilar Z comprises three parts: 1) a morse taper implant; and 2) a Z-angled pillar with a length of 18mm. At one extremity, it contains an internal morse taper connection without indexing; at the other, it includes a connection with a 12-mm internal thread. There is also a passant screw of 1.4-mm diameter and; 3) a 15-mm long rod, with a 10-mm thread at one end that connects to part 2. It contains a self-threading nut for height delimitation and an external hexagon prosthetic platform with a height of 0.7mm [9]. **Due to the absence of a maxilla, it was impossible to follow the complete Technique and place the two anterior implants to avoid the cantilevering of the prosthesis.**

Figure 4 Osseointegrated implants in the maxilla (FACCO technique) and mandible (inferior protocol).



Source: Own Author

3. DISCUSSION

Trauma appears in third place [16] as the leading cause of death worldwide, behind only cardiovascular diseases and cancer. However, when separated by age group, between 20 and 40 years old, trauma starts to lead to the statistics [17]. Facial trauma represents almost 9% of emergency care in **Brazil's hospitals**[18], and among the leading causes are **MVAs** [16, 18-20], as occurred in the present Case Report. The association of alcohol, drugs, dangerous driving, and urban violence is increasingly related to the etiology of trauma [20-21].

The greater the tissue destruction of the face, the greater the sequelae, and consequently, for a good prognosis, multidisciplinary and integrated care is necessary to restore aesthetics and function [17]. Prosthetic rehabilitation restores the physical separation between the oral and nasal cavities, normalizes speech and swallowing, and supports the lips and cheeks. It must be performed after the healing period, **04 to 08 weeks** [22], according to factors like **patient stability, edema, the systemic situation of the patient and anesthesiologist consultation, and case severity.**

Traumas represent the leading causes of death, as well as disability, throughout the world [23], and facial traumas are the most devastating types found in hospitals [24]. **Possible errors in conduct or diagnosis can further aggravate cases of multiple facial trauma. However, preventing MVAs is the best way. It must be associated with effective public policies such**

as the application of severe punishments to drivers who drive under the influence of psychotropic substances, under the influence of alcohol, and at speeds above the permitted speed, for example.

Maxillectomy is classified into three types [25]: 1) with preservation of the orbital floor, 2) with loss of orbital support, and 3) with orbital exenteration and ethmoidectomy, as occurred in the Clinical Case Report of the present research. The first form of maxillectomy can be further divided into low or high, depending on the extent of the osteotomy, respectively, below or above the infraorbital foramen.

Post-surgical jaw defects predispose the patient to nasal speech, fluid leakage into the nasal cavity, impaired masticatory function, and, in some patients, varying degrees of aesthetic and psychological deformity [21, 25].

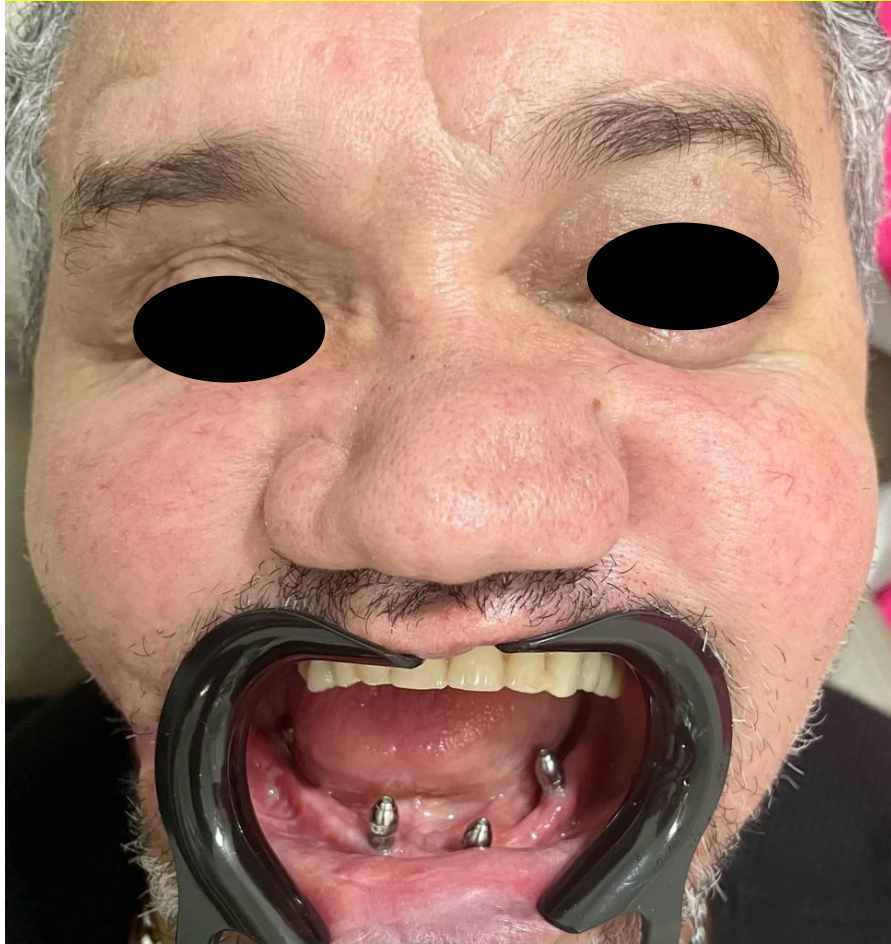The present case was rehabilitated with conventional implants (morse cone implants) anchorage in the zygomatic bone. Flacco's Technique [10] was performed in three stages: conventional implant, intermediate 18-mm-long piece, and 15-mm-long piece to define the height of the external hexagon-type prosthetic platform [10]. Subsequently, the component's mini pillar was installed. The great advantage of Facco's Technique is that there is no need for maxillary reconstruction surgery with bone grafts before placing osseointegrated implants. Another advantage is the installation of conventional implants in the zygomatic region (morse cone) instead of using zygomatic implants. There are no disadvantages associated with this treatment plan.

Even though the first surgery (emergency), which is the most crucial part of obtaining better results, was not carried out satisfactorily in the case in question, The loss of the maxilla was treated with Facco's Technique. Thus, the patient's masticatory and speaking capacity could be restored.

4. CONCLUSION

It can be concluded that conventional implants installed in the zygomatic bone and using the Pillar Z(Facco Technique) were a great option to rehabilitate patients who were victims of MVAs without a jawbone and reduce their treatment time. It also gave him a new chance to find his way back into society and improved his quality of life (Figure 5). This clinical case has a three-year follow-up with bone, implant, and prosthetic stability.

Figure 5 Pré final prosthetics rehabilitation.



Source: Own Author.

CONSENT

The patient has informed consent for this case report to be published.

All authors declare that the patient gave written informed consent to publish this case report and accompanying images.

ETHICAL APPROVAL

All authors declare that all experiments have been examined and approved by the Centro de Pesquisas Odontológicas São Leopoldo Mandic SS Ethics Committee, CAAE number 73491423.7.0000.5374 and have, therefore, been performed following the ethical standards laid down in the 1964 Declaration of Helsinki.

DISCLAIMER (ARTIFICIAL INTELLIGENCE)

As a result, the author declares that no generative AI technologies such as large language models (ChatGPT, COPILOT, etc.) and text-to-image generators were used during the writing or editing of this manuscript.

REFERENCES

1. Khan TU, Rahat S, Khan ZA, Shahid L, Banouri SS, Muhammad N. Etiology and pattern of maxillofacial trauma. *PLoS One*. 2022 Sep 29;17(9): e0275515
2. Da Silva AC, Passeri LA, Mazzone R, De Moraes M, Moreira RW. Incidence of dental trauma associated with facial trauma in Brazil: a 1-year evaluation. *Dent Traumatol*. 2004 Feb;20(1):6-11.
3. Ukpong DI, Ugboko VI, Ndukwe KC, Gbolahan OO. Health-related quality of life in Nigerian patients with facial trauma and controls: a preliminary survey. *Br J Oral Maxillofac Surg*. 2008 Jun;46(4):297-300.
4. Choi SH, Gu JH, Kang DH. Analysis of Traffic Accident-Related Facial Trauma. *J Craniofac Surg*. 2016 Oct;27(7):1682-1685.
5. Wusiman P, Maimaituerxun B, Guli, Saimaiti A, Moming A. Epidemiology and Pattern of Oral and Maxillofacial Trauma. *J Craniofac Surg*. 2020 Jul-Aug;31(5): e517-e520.
6. Moura, TFL, Daltro RM, Almeida TF. Facial trauma: a systematic review of the literature. *University of Passo Fundo*. 2016 Sept. /Dec.;21(3):1-8.
7. Tobar, M.E.S, Court, D.R, Olea, V.S. Epidemiology of surgical pathology affecting the maxillofacial region, treated under general anesthesia at the Public Emergency Hospital between 2014 and 2016. *Chilean Journal of Surgery*. 2017; 69(4): 289-296 Bidra AS, Jacob RF, Taylor TD. Classification of maxillectomy defects: a systematic review and criteria necessary for a universal description. *J Prosthet Dent*. 2012 Apr;107(4):261-70.
8. Carvalho, Abrahão Cavalcante Gomes de Souza et al. Immediate oral rehabilitation after partial maxillectomy: case report. *Immediate oral rehabilitation after partial maxillectomy: case report, Rev. Cir. Traumatol. Buco-Maxilo-fac., Camaragibe, v. 9, n. 2, p. 33-38, April/June 2009. Available at: <https://www.revistacirurgiabmf.com/2009/v9n2/04.pdf>. Accessed on: June 16, 2023.*
9. Costa EF, Penteadó MM, Maior BS. Comparative analysis of biomechanical response between the zygomatic implant and Facco technique through the three-dimensional finite element method. *J Clin Exp Dent*. 2023 Feb 1;15(2): e96-e101.
10. Gaur V, Doshi AG, Palka L. Zygomatic approach with single-piece implants: A technical note. *Natl J Maxillofac Surg*. 2022 Jan-Apr;13(1):153-161.
11. Vosselman N, Glas HH, Merema BJ, Kraeima J, Reintsema H, Raghoobar GM, Witjes MJH, de Visscher SAHJ. Three-Dimensional Guided Zygomatic Implant Placement after Maxillectomy. *J Pers Med*. 2022 Apr 6;12(4):588.
12. Brånemark P. *Surgery and fixture installation: zygomaticus fixture clinical procedures (vol. 1)*. Göteborg: Nobel Biocare, 1998.
13. Costa, Elton Facco Alves, et al. New Facco technique: study evaluates in vitro the compressive strength and fatigue behavior of the implant-prosthetic abutment assembly. [Internet]. 2021 Aug 10 [cited 2023 Jun 16]; Available from: <https://revistaimplantnews.com.br/nova-tecnica-facco-de-implante-convencional-em-osso-zigomatico-avaliacao-mecanica-do-pilar-z/>.
14. Nakai H, Okazaki Y, Ueda M. Clinical application of zygomatic implants for rehabilitation of the severely resorbed maxilla: a clinical report. *Int J Oral Maxillofac Implants*. 2003 Jul-Aug;18(4):566-70.
15. Scherbaum Eidt JM, De Conto F, De Bortoli MM, Engelmann JL, Rocha FD. Associated injuries in patients with maxillofacial trauma at the hospital são Vicente de Paulo, Passo Fundo, Brazil. *J Oral Maxillofac Res*. 2013 Oct 1;4(3): e1.
16. Mello Filho FV, Ricz H. Epidemiological modifications of facial trauma and its implications. *Braz J Otorhinolaryngol*. 2014 May-Jun;80(3):187-8.
17. Zamboni RA; Wagner JCB; Volkweis MR; Gerhardt EL; Buchmann EM; Bavaresco CS. Epidemiological study of facial fractures at the Oral and Maxillofacial Surgery Service, Santa Casa de Misericórdia Hospital Complex, Porto Alegre-RS-Brazil. *Revista do Colégio Brasileiro de Cirurgiões*. 2017; 44(00):491-7
18. Moura, TFL, Daltro RM, Almeida TF. Facial trauma: a systematic review of the literature. *University of Passo Fundo*. 2016 Sep. /Dec.;21(3):1-8
19. da Silva Júnior FCS; Soares FAF; da Silva Filho WS; Batista EV. Características clínicas e epidemiológicas de pacientes com traumatismo facial: uma revisão integrativa da literatura. *Brazilian Journal of Development*; 2020 Oct. 7;6(10):75923-35.
20. Miracca RAA; Sobrinho JA; Gonçalves AJ. Reconstruction with immediate prosthesis after maxillectomy. *Rev Col Bras Cir*. 2007 Sep;34(5):297-302.
21. Bezerra ALD; Ribeiro RC; de Sousa MNA; Alves AN; Pereira OHG; Sobreira T. Epidemiological profile of facial trauma/Perfil epidemiológico dos traumas faciais/Perfil epidemiológico del trauma facial. *Revista de Enfermagem da UFPI*. 2017;6(2):57-64
22. Wulkan M, Parreira JG Jr, Botter DA. Epidemiologia do trauma facial [Epidemiology of facial trauma]. *Rev Assoc Med Bras (1992)*. 2005 Sep-Oct;51(5):290-5. Portuguese.
23. Carvalho, ACGDS; Castro Filho FMD; Sousa FB; Magro-Filho O; Romio K; Nogueira, RLM. Immediate oral rehabilitation after partial maxillectomy: case report. *Rev. cir. traumatol. buco-maxilo-fac*.2009:33-38

24. Sharma AB, Beumer J 3rd. Reconstruction of maxillary defects: the case for prosthetic rehabilitation. J Oral Maxillofac Surg. 2005 Dec;63(12):1770-3.

ABBREVIATIONS

WHO: World Health Organization.

MVA: motor vehicle accident.

UNDER PEER REVIEW