

Case Report

Facial trauma with total maxillectomy and Z-pillar rehabilitation – Case Report

ABSTRACT

Aims: Facial trauma is one of the leading causes of mortality that affects young male adults. Its multifactorial etiology and the predominant causes are traffic accidents and physical aggression. Maxillectomy is a surgical procedure, partial or total removal of the jaw, either due to trauma or pathology (oral cancer). The surgical defect created can cause psychological, functional, and aesthetic disorders for the patient, making rehabilitation essential.

Presentation of Case: This case report is about a 45-year-old Caucasian patient who was a victim of facial trauma due to a traffic accident and underwent three hospital surgeries. Prosthetic rehabilitation was done using conventional implants anchored in zygomatic bones associated with the Z-pillar and the Facco Technique. It is a rehabilitative treatment option for total maxillectomy, as it restores aesthetics and function to the patient.

Discussion: Facial trauma represents almost 9% of emergency care in hospitals, and among the leading causes are car accidents, as occurred in the present Case Report. Maxillectomy is classified into three types (25): 1) with preservation of the orbital floor, 2) with loss of orbital support, and 3) with orbital exenteration and ethmoidectomy, as occurred in the Clinical Case Report of the present research. The Facco Technique was performed in three stages. Subsequently, the component's mini pillar was installed.

Conclusion: It can be concluded that conventional implants installed in the zygomatic bone and using the Z-pillar (Facco Technique) were a great option to rehabilitate patients who were victims of a car accident without a jawbone and reduced their treatment time. It also gave him a new chance to find his way back into society and improved his quality of life.

Keywords: Facial trauma. Jaw. Zygomatic bone.

Comment [M1]: It has

Comment [M2]: In text book MVA(motor vehicle accident) used

Comment [M3]: assault

Comment [M4]: Case Presentatiom

Comment [M5]: Which contry

1. INTRODUCTION

Facial trauma is the name given to any injury located on the face [1]. It is considered a public health problem in Brazil [2] and is among the leading causes of death and morbidity in the world, according to data from the World Health Organization (WHO) [3]. The etiological factors of facial fractures are multifactorial, but the most significant predominance is due to automobile accidents [4]. Studies show that the prevalence of facial trauma is higher in males [5] and young adults (18 and 40 years old) [6]; its diagnosis and treatment are carried out by the Craniomaxillofacial team [7].

Comment [M6]: Which country

Maxillectomies are classified into three types [8]: 1) preservation of the orbital floor, 2) loss of orbital support, and 3) removal of orbital contents and ethmoidectomy. The procedure results in significant aesthetic and functional defects; its consequences can be nasal speech, leakage of secretion from the nasal cavity, impairment of masticatory function, and aesthetic deformity, requiring surgical and prosthetic rehabilitation [9].

Comment [M7]: fluids

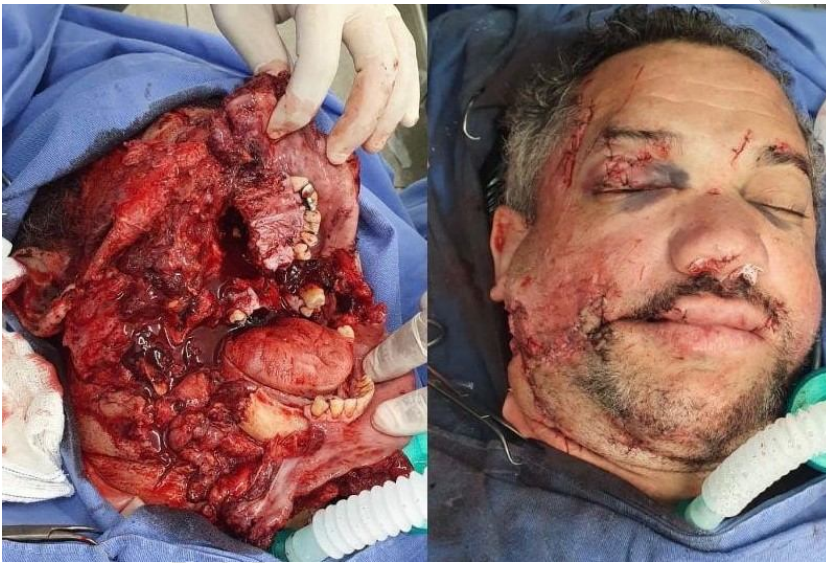Rehabilitation is performed using the zygomatic pillar (Z-pillar) and the Facco Technique [10], which is designed and developed to reduce the difficulty of zygomatic anchorage techniques [11]. In this case, an intermediate capable of connecting the implant to the alveolar ridge was used due to the previously performed maxillectomy [12].

The Z-pillar technique consists of a zygomatic anchorage system composed of three parts [13]: a conical implant with a cone-morse connection, an initial piece of the Z-pillar, and the final piece of the Z-pillar to adjust the length of the prosthetic platform with a connection external hexagonal. The implant is installed in the zygomatic bone bilaterally [14], associated with the Z-pillar. The main advantage of this technique is the rehabilitation of edentulous jaws with no need for bone grafting, reducing the patient's treatment time [15].

2. PRESENTATION OF CASE

The patient was a truck driver in a traffic accident on Via Dutra in Volta Redonda, Rio de Janeiro, Brazil, in 2021. First aid was performed at the local hospital (hemostasis, facial sutures, reduction of face fractures, and maxillomandibular block) (Figure 1).

Figure 1 Emergency service (before x after surgery).



Source: Own Author

Comment [M8]: case presentation or presentation the case

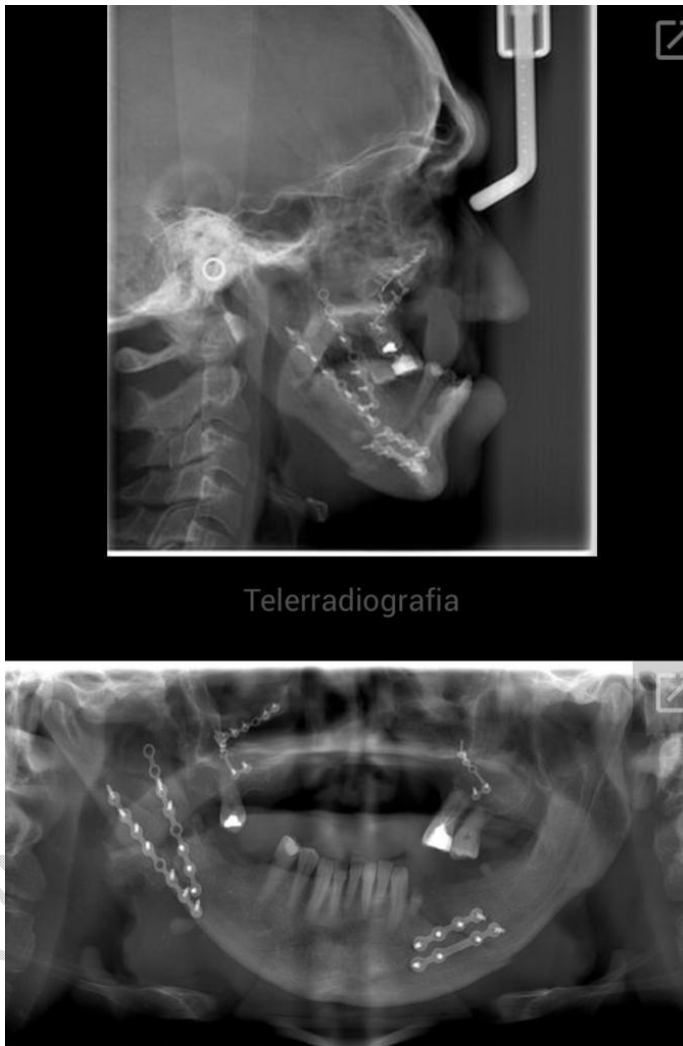
Comment [M9]: does it means splint?

Comment [M10]: In every facial fx DX must be noted, overall it is panfacial fx, but in details: hemifort3, NOE, avulsion, mandibular fx and so. also results from eye exam must be noted.

Comment [M11]: It is better to add one 3D ct scanning cut in frontal view to evaluate facial fx by readers.

However, the maxilla was not fixed satisfactorily due to a lack of stable internal fixation material in the first hospital in Rio de Janeiro, Brazil (Figure 2), where he remained in the intensive care unit for a month and presented psychomotor agitation generated by the discontinuous use of amphetamines due to his profession (truck driver).

Figure 2 Unsatisfactory fixation of the jaw.

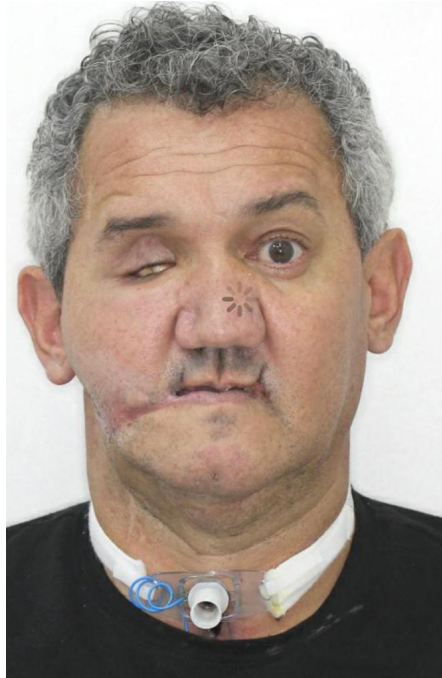

Source: Own Author

Comment [M12]: In any facial fx, first surgery is most important to best results and golden time is this time, here malpractice happened due to absence of maxillofacial surgeon and author must noted and suggested this necessity in discussion or conclusion.

After, he was transferred to Hospital Santa Bárbara, in Santa Bárbara d'Oeste, São Paulo, Brazil, near his residence. Upon examination by a new Craniomaxillofacial team, tissue necrosis and loss of the maxilla were found, due to inadequate fixation, as well as arthrosis of the left mandibula para symphysis, **pseudarthrosis** of the nose (without the stability of fixation), **misalignment** of the orbits, and loss of the right eyeball (Figure 3).

Figure 3 Arthrosis of the left mandibula para symphysis, pseudarthrosis of the nose (without the stability of fixation), misalignment of the orbits, and loss of the right eyeball.

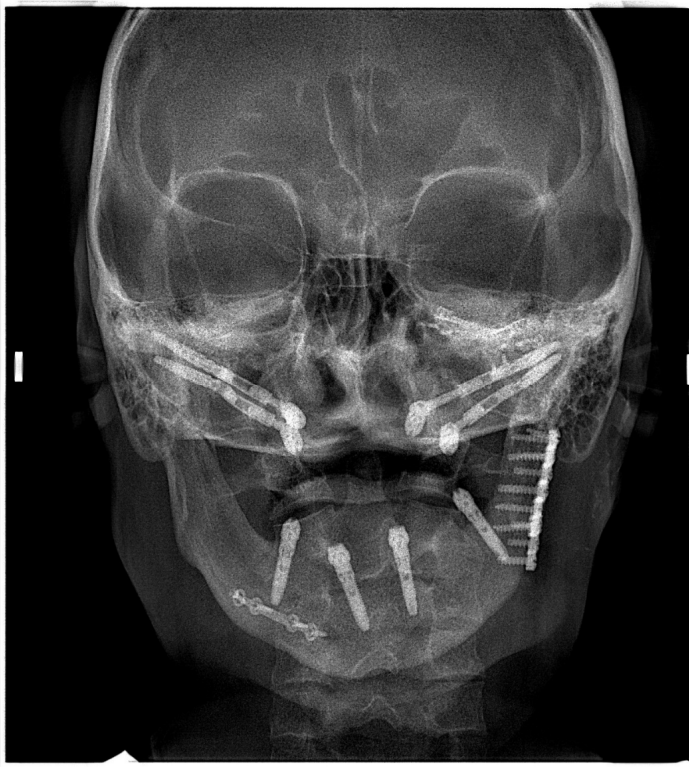


Source: Own Author

Comment [M13]: If soft tissue is between two bone segments, called nonunion. If two segments fused in bad position, called malunion.

The procedures adopted were removal of the maxillomandibular block and all previous fixation material; reduction of the sequelae of fractures with 2.4 plates (jaw body) in four surgical stages: 1) extraction of lower dental remnants; 2) placement of osseointegrated implants in the maxilla and mandible (inferior protocol), ocular enucleation and, 4) placement of mesh to support the globe eyepiece. The implants were positioned in the right and left zygomatic bone, using conventional 4x17mm morse cone implants, with 80N locking and Implacil Z-arm® – FACCO technique (with movement above 180°) (Figure 4).

Figure 4 Osseointegrated implants in the maxilla (FACCO technique) and mandible (inferior protocol).



Source: OwnAuthor

3. DISCUSSION

Trauma appears in third place [16] as the leading cause of death worldwide, behind only cardiovascular diseases and cancer. However, when separated by age group, between 20 and 40 years old, trauma starts to lead to the statistics [17]. Facial trauma represents almost 9% of emergency care in hospitals [18], and among the leading causes are car accidents [16, 18-20], as occurred in the present Case Report. The association of alcohol, drugs, dangerous driving, and urban violence is increasingly related to the etiology of trauma [20-21].

The greater the tissue destruction of the face, the greater the sequelae, and consequently, for a good prognosis, multidisciplinary and integrated care is necessary to restore aesthetics and function [17]. Prosthetic rehabilitation restores

Comment [M14]: What did they do for orbit and nasal bones?

Comment [M15]: Why one miniplate has been used in RTS body of mandible, we must use two miniplates, one at inferior border and one at superior border of the fx line for rigid fixation. What type of plate has been used in LTS ramus and what type of fx was there.

Comment [M16]: It is better to add frontal 3Dview cut after last surgery to see and evaluate the facial skeleton and orbit.

the physical separation between the oral and nasal cavities, normalizes speech and swallowing, and supports the lips and cheeks. It must be performed after the healing period, **four to eight weeks** [22].

Traumas represent the leading causes of death, as well as disability, throughout the world [23], and facial traumas are the most devastating types found in hospitals [24].

Maxillectomy is classified into three types [25]: 1) with preservation of the orbital floor, 2) with loss of orbital support, and 3) with orbital exenteration and ethmoidectomy, as occurred in the Clinical Case Report of the present research. The first form of maxillectomy can be further divided into low or high, depending on the extent of the osteotomy, respectively, below or above the infraorbital foramen.

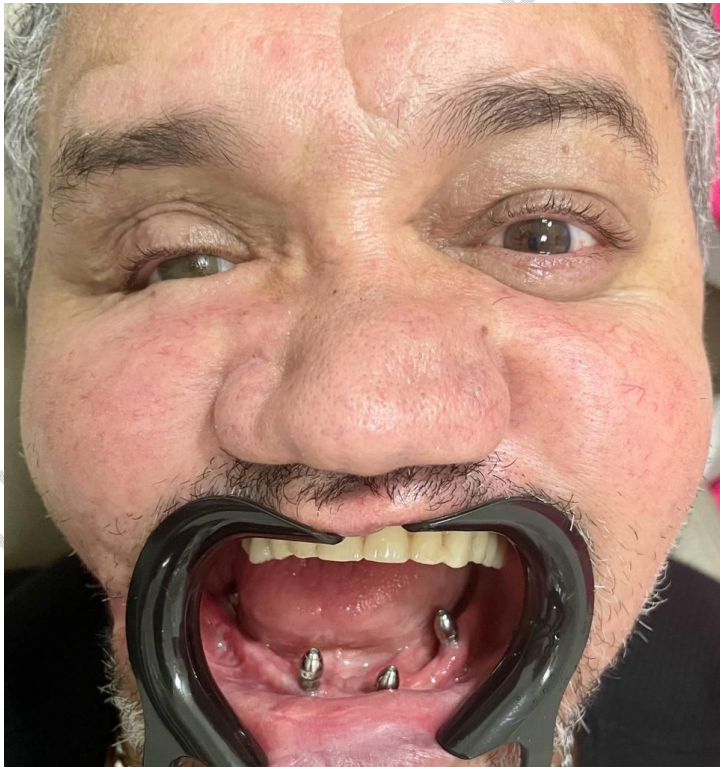Post-surgical jaw defects predispose the patient to nasal speech, fluid leakage into the nasal cavity, impaired masticatory function, and, in some patients, varying degrees of aesthetic and psychological deformity [21, 25].

The present case was rehabilitated with conventional implants (morse cone implants) anchorage in the zygomatic bone. The Facco Technique [10] was performed in three stages: conventional implant, intermediate 18-mm-long piece, and 15-mm-long piece to define the height of the external hexagon-type prosthetic platform [10]. Subsequently, the component's mini pillar was installed.

4. CONCLUSION

It can be concluded that conventional implants installed in the zygomatic bone and using the Z-pillar (Facco Technique) were a great option to rehabilitate patients who were victims of a car accident without a jawbone and reduced their treatment time. It also gave him a new chance to find his way back into society and improved his quality of life (Figure 5).

Figure 5 Pré final prosthetics rehabilitation.



Source: Own Author

Comment [M17]: It is up to many factors like: patient stability, edema, systemic situation of patient and anesthesiologist consultation and severity and ...

Comment [M18]: Here author must discussed about the mistakes happened and note her or his suggestion for prevention.

Comment [M19]: Author must note the different types of treatment for this patient and compare advantages and disadvantages of them.

Comment [M20]: I dont see anterior implans. with zygomatic implants we use 2 short implant according to patients bone in anterior of the maxilla to avoid cantilever, it is needed that author explains about this problem and also what type of connection has been used between imolants an dentures in both jaws.

Comment [M21]: If there is cantilever in anterior of maxilla, it needs follow-up to determine longevity.

CONSENT

The patient has informed consent for this case report to be published.

All authors declare that the patient gave written informed consent to publish this case report and accompanying images.

A copy of the written consent is available for review by this journal's Chief Editor.

ETHICAL APPROVAL

All authors declare that all experiments have been examined and approved by the Centro de Pesquisas Odontológicas São Leopoldo Mandic SS Ethics Committee, CAAE number 73491423.7.0000.5374 and have, therefore, been performed following the ethical standards laid down in the 1964 Declaration of Helsinki.

DISCLAIMER (ARTIFICIAL INTELLIGENCE)

As a result, the author declares that no generative AI technologies such as large language models (ChatGPT, COPILOT, etc.) and text-to-image generators were used during the writing or editing of this manuscript.

REFERENCES

1. Khan TU, Rahat S, Khan ZA, Shahid L, Banouri SS, Muhammad N. Etiology and pattern of maxillofacial trauma. *PLoS One*. 2022 Sep 29;17(9): e0275515
2. Da Silva AC, Passeri LA, Mazzonetto R, De Moraes M, Moreira RW. Incidence of dental trauma associated with facial trauma in Brazil: a 1-year evaluation. *Dent Traumatol*. 2004 Feb;20(1):6-11.
3. Ukpong DI, Ugboko VI, Ndukwe KC, Gbolahan OO. Health-related quality of life in Nigerian patients with facial trauma and controls: a preliminary survey. *Br J Oral Maxillofac Surg*. 2008 Jun;46(4):297-300.
4. Choi SH, Gu JH, Kang DH. Analysis of Traffic Accident-Related Facial Trauma. *J Craniofac Surg*. 2016 Oct;27(7):1682-1685.
5. Wusiman P, Maimaituerxun B, Guli, Saimaiti A, Moming A. Epidemiology and Pattern of Oral and Maxillofacial Trauma. *J Craniofac Surg*. 2020 Jul-Aug;31(5): e517-e520.
6. Moura, TFL, Daltro RM, Almeida TF. Facial trauma: a systematic review of the literature. *University of Passo Fundo*. 2016 Sept./Dec.;21(3):1-8.
7. Tobar, M.E.S, Court, D.R, Olea, V.S. Epidemiology of surgical pathology affecting the maxillofacial region, treated under general anesthesia at the Public Emergency Hospital between 2014 and 2016. *Chilean Journal of Surgery*. 2017; 69(4): 289-296 Bidra AS, Jacob RF, Taylor TD. Classification of maxillectomy defects: a systematic review and criteria necessary for a universal description. *J Prosthet Dent*. 2012 Apr;107(4):261-70.
8. Carvalho, Abrahão Cavalcante Gomes de Souza et al. Immediate oral rehabilitation after partial maxillectomy: case report. Immediate oral rehabilitation after partial maxillectomy: case report, *Rev. Cir. Traumatol. Buco-Maxilo-fac., Camaragibe*, v. 9, n. 2, p. 33-38, April/June 2009. Available at: <https://www.revistacirurgiabmf.com/2009/v9n2/04.pdf>. Accessed on: June 16, 2023.
9. Costa EF, Penteadó MM, Maior BS. Comparative analysis of biomechanical response between the zygomatic implant and Facco technique through the three-dimensional finite element method. *J Clin Exp Dent*. 2023 Feb 1;15(2): e96-e101.
10. Gaur V, Doshi AG, Palka L. Zygomatic approach with single-piece implants: A technical note. *Natl J Maxillofac Surg*. 2022 Jan-Apr;13(1):153-161.
11. Vosselman N, Glas HH, Merema BJ, Kraeima J, Reintsema H, Raghoobar GM, Witjes MJH, de Visscher SAHJ. Three-Dimensional Guided Zygomatic Implant Placement after Maxillectomy. *J Pers Med*. 2022 Apr 6;12(4):588.
12. Brånemark P. Surgery and fixture installation: zygomaticus fixture clinical procedures (vol. 1). Göteborg: Nobel Biocare, 1998.

13. Costa, Elton Facco Alves, et al. New Facco technique: study evaluates in vitro the compressive strength and fatigue behavior of the implant-prosthetic abutment assembly. [Internet]. 2021 Aug 10 [cited 2023 Jun 16]; Available from: <https://revistaimplantnews.com.br/nova-tecnica-facco-de-implante-convencional-em-osso-zigomatico-avaliacao-mecanica-do-pilar-z/>.
14. Nakai H, Okazaki Y, Ueda M. Clinical application of zygomatic implants for rehabilitation of the severely resorbed maxilla: a clinical report. *Int J Oral Maxillofac Implants*. 2003 Jul-Aug;18(4):566-70.
15. Scherbaum Eidt JM, De Conto F, De Bortoli MM, Engelmann JL, Rocha FD. Associated injuries in patients with maxillofacial trauma at the hospital são Vicente de Paulo, Passo Fundo, Brazil. *J Oral Maxillofac Res*. 2013 Oct 1;4(3): e1.
16. Mello Filho FV, Ricz H. Epidemiological modifications of facial trauma and its implications. *Braz J Otorhinolaryngol*. 2014 May-Jun;80(3):187-8.
17. Zamboni RA; Wagner JCB; Volkweis MR; Gerhardt EL; Buchmann EM; Bavaresco CS. Epidemiological study of facial fractures at the Oral and Maxillofacial Surgery Service, Santa Casa de Misericórdia Hospital Complex, Porto Alegre-RS-Brazil. *Revista do Colégio Brasileiro de Cirurgiões*. 2017; 44(00):491-7
18. Moura, TFL, Daltro RM, Almeida TF. Facial trauma: a systematic review of the literature. *University of Passo Fundo*. 2016 Sep. /Dec.;21(3):1-8
19. da Silva Júnior FCS; Soares FAF; da Silva Filho WS; Batista EV. Características clínicas e epidemiológicas de pacientes com traumatismo facial: uma revisão integrativa da literatura. *Brazilian Journal of Development*; 2020 Oct. 7;6(10):75923-35.
20. Miracca RAA; Sobrinho JA; Gonçalves AJ. Reconstruction with immediate prosthesis after maxillectomy. *Rev Col Bras Cir*. 2007Sep;34(5):297–302.
21. Bezerra ALD; Ribeiro RC; de Sousa MNA; Alves AN; Pereira OHG; Sobreira T. Epidemiological profile of facial trauma/Perfil epidemiológico dos traumas faciais/Perfil epidemiológico del trauma facial. *Revista de Enfermagem da UFPI*. 2017;6(2):57-64
22. Wulkan M, Parreira JG Jr, Botter DA. Epidemiologia do trauma facial [Epidemiology of facial trauma]. *Rev Assoc Med Bras* (1992). 2005 Sep-Oct;51(5):290-5. Portuguese.
23. Carvalho, ACGDS; Castro Filho FMD; Sousa FB; Magro-Filho O; Romio K; Nogueira, RLM. Immediate oral rehabilitation after partial maxillectomy: case report. *Rev. cir.traumatol. buco-maxilo-fac*.2009:33-38
24. Sharma AB, Beumer J 3rd. Reconstruction of maxillary defects: the case for prosthetic rehabilitation. *J Oral Maxillofac Surg*. 2005 Dec;63(12):1770-3.

ABBREVIATIONS

WHO: World Health Organization.