

Case report

Nine months Follow-Up of Root Perforation Repair Using MTA-HP in a singleretreatment session: A Case Report

ABSTRACT

Aims: Root perforations are accidents and complications that can occur during endodontic treatment. With the advent of calcium silicate-based repair cements, there is a possibility to effectively seal and preserve the affected tooth. The objective of this case report was to evaluate the success and repair of a root perforation sealed with a calcium silicate-based repair cement of a tooth that had been indicated for extraction.

Presentation of Case: A 59-year-old healthy female without systemic diseases, presented to the dental service with a fistula, spontaneous pain, and pain upon vertical and horizontal percussion in the tooth 24, which had a metal-ceramic crown, a metal post, and inadequate endodontic treatment. The crown was sectioned, and the post was removed with ultrasonic tips. A perforation in the palatal root and bone resorption were observed through a cone-beam computed tomography (CBCT). The perforation was sealed with MTA HP (Angelus) and the canals were retreated using mechanized systems and filled with BioRoot RCS sealer (Sepdotont) in a single session. The tooth was rehabilitated using a digital workflow based on scanning and 3D printing of the restoration/crown. Follow-up was performed after six and nine months, and the patient showed no painful symptoms upon horizontal and vertical percussion tests, with CBCT showing regression of the bone resorption.

Discussion and Conclusion: The bone repair and the absence of signs and symptoms of periradicular pathologies indicate treatment success after nine months follow up of the root perforation sealed with a calcium silicate-based repair cement.

Keywords: Retreatments; Dental Cement; Cone Beam Computed Tomography; Periapical Diseases; Bone Resorptions.

1. INTRODUCTION

Endodontic perforations, according to the American Association of Endodontists, are communications between the root canal system and the external surface of the tooth. Perforations can be of iatrogenic cause or pathological conditions, such as extensive caries and root resorption (Mente et al., 2010; Estrela et al., 2018). Root perforations occur in 2-12% of endodontic treatments (Gorni et al., 2022) and can happen during coronal access, root canal instrumentation, and post space preparation (Estrela et al., 2018; Clauder, 2022). Post space

preparations are the most common cause, responsible for 53% of the cases (Kvinnslund et al., 1989).

Perforations trigger the destruction of periodontal fibers, bone resorption, the formation of granulation tissue, and the development of periodontal defects (Arens & Torabinejad, 1996; Beavers et al., 1986; Seltzer et al., 1970). If not sealed, they induce inflammatory and infectious processes (Estrela et al., 2018) and lead to the loss of the tooth, accounting for 2.9 to 4.2% of teeth extractions (Olcay et al., 2018; Touré et al., 2011).

Various materials have been used to seal perforations. However, since its introduction in 1993 (Lee et al., 1993; Torabinejad et al., 1993), mineral trioxide aggregate (MTA) has become the material of choice for these cases (Mente et al., 2010) due to its biocompatibility and bioactivity (Camilleri, 2007). Initially, this cement was indicated for retrograde filling in periradicular surgeries, and later its use expanded to cases of pulp capping, pulpotomy, apexification, and sealing of perforations (Camilleri et al., 2017; Estrela et al., 2018; Clauder, 2022). MTA is a calcium silicate-based hydraulic cement (CSHC) that tolerates the moisture of tissue fluids well, requiring water to initiate the setting reaction, which is completed in 28 days (Chen et al., 2009; Camilleri, 2007; 2011; 2017).

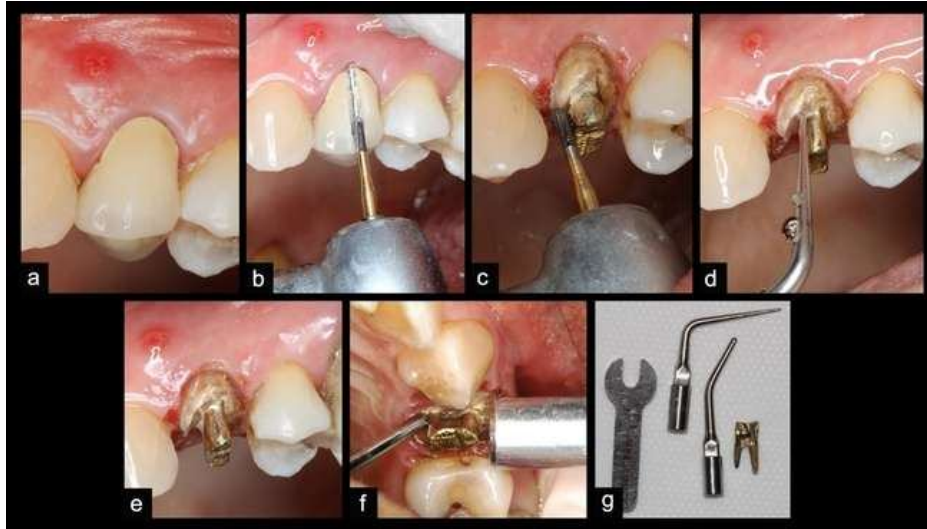
Traditional MTA presented some limitations such as handling difficulties, tooth discoloration, and long setting time (Palczewska-Komsa et al., 2021). MTA HP (Angelus, Londrina, Paraná, Brazil) was developed to address these issues. According to the manufacturers, the material was improved by adding plasticizers to the liquid and reducing the particle size, which enhances its sandy consistency and handling. The smaller particles increase reactivity, thereby decreasing the setting time and enhancing calcium ion release (Saghiri et al., 2015a, 2015b). Additionally, the replacement of the radiopacifier bismuth oxide with calcium tungstate resolved the issue of tooth discoloration (Marciano et al., 2014).

Regarding root perforations during post preparation, the development of CSHC with improved compositions, and the use of technologies in dentistry, this study aimed to report a clinical case of a second upper premolar with a root perforation that occurred during post preparation. The case was managed using MTA HP cement and subsequently rehabilitated through 3D-printed crown.

2. PRESENTATION OF CASE

A 40-year-old female patient attended the clinic complaining of pain in tooth 24 and swelling in the gingival region above the tooth. The patient reported that she had undergone endodontic treatment and the placement of a prosthetic crown a long time ago. A detailed medical and dental history was taken. The patient reported no systemic health problems or regular medication use. Her blood pressure was 120/80 mmHg. During the intraoral clinical examination, a fistula (figure 1a) was observed at the apex of tooth 24, with sensitivity and

discomfort upon vertical and horizontal percussion. During the periodontal probing of the tooth, the probing depth was 4 mm on the mesio-buccal surface and 1 mm on the other surfaces, accompanied by 1 mm of mobility. The crown was properly adapted to the tooth. On extraoral clinical examination, no deviations from normality were identified. A digital periapical radiograph

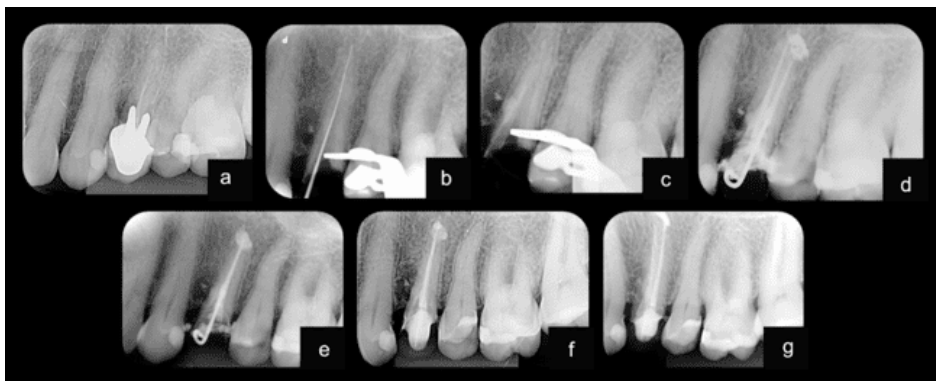


was taken using a size 2 phosphor plate (Micro Imagem, Indaiatuba, São Paulo, Brazil), and bone rarefaction was observed on the mesial aspect of tooth 25 (figure 2a). Additionally, the endodontic treatment was found to be inadequate on the radiograph, showing a lack of taper in the preparation and an absence of filling material in the buccal canal.

Figure 1. Presence of a fistula above tooth 24 (a). Sectioning of the metal-ceramic crown with a transmetal bur (b). Reduction of the post to expose the cementation line with an E-8 insert (c, d, e). Removal of the post with an E-12 insert and clinical mirror handle (f). Post removed and ultrasonic inserts E-8 and E-12.

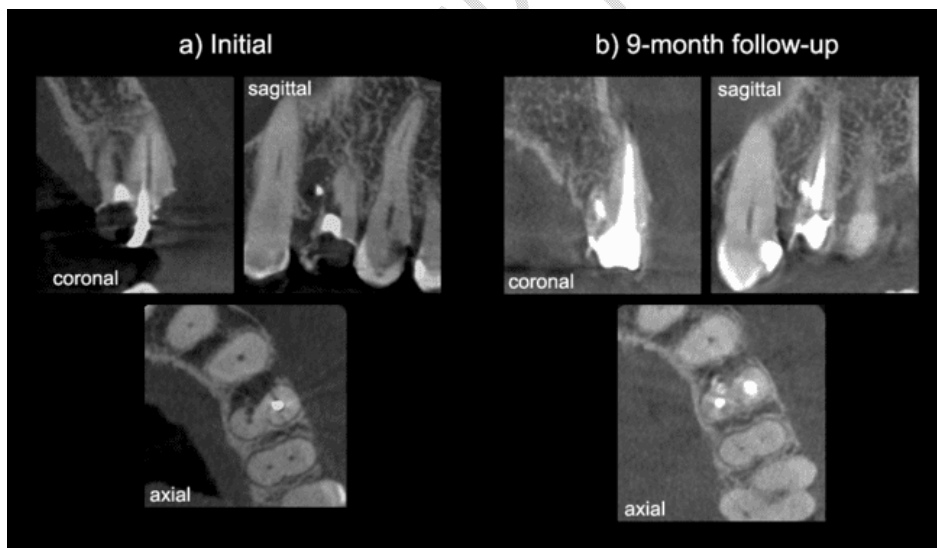
Figure 2. Initial radiograph (a). Odontometry of the palatal canal (b). Perforation sealed with MTA HP (c). Final radiograph with temporary crown (d and e). Follow-up after 6 months (f). Follow-up after 9 months (g).

For a better understanding of the clinical and diagnostic situation, a cone-beam computed tomography scan was requested. To avoid the formation of artefacts, it was necessary to remove the metal-ceramic crown and the cast metal core. The crown was removed using a transmetal drill (Dentsply Maillefer, Ballaigues, Switzerland), sectioning it in the buccal-palatal



direction (figure 1b). Once the metal core was exposed, it was reduced in thickness with the same drill to reveal the cementation line (figure 1c). The cementation line between the post and dentin was removed using an ultrasonic tip Scouter E-8 (Helse Dental Technology, Santa Rosa de Viterbo, São Paulo, Brazil) activated at 60% power, with cooling, through the ultrasonic device SatelecNewtron Booster (Satelec, Mérignac, Gironde, France) (figure 1d and e). For post removal, an E12 insert (Helse Dental Technology, Santa Rosa de Viterbo, São Paulo, Brazil) was used horizontally on the palatal surface of the core at 85% power with cooling (figure 1f and g). Simultaneously, a dental mirror handle was horizontally pressed on the buccal surface of the core. The core was removed in one minute. A temporary coronal seal was then placed using Maxxion R glass ionomer (FGM, Joinville, Santa Catarina, Brazil).

Upon examining the tomographic images (OnDemand 3D, CyberMed, Seoul, Republic of Korea), extensive bone resorption was noted in the mesial area, with inadequate obturation of the buccal canal and root perforation in the palatal canal (figure 3a). The perforation, measuring 3.4 mm, was likely caused during the preparation for the intraradicular post. The case was discussed, and tooth extraction followed by replacement with dental implant was proposed as a potential solution. However, the patient declined this therapeutic approach. In an attempt to preserve the tooth, all available technological resources were employed,



emphasizing to the patient that the prognosis of the case was uncertain.

Figure 3. Initial cone beam computed tomography (a) and after 9 months of follow-up (b) of tooth 24, showing coronal, sagittal, and axial slices.

In the second session, the region of the tooth was anesthetized with a vestibular infiltration using 2% lidocaine with 1:100,000 epinephrine (Alphacaine, DFL, Rio de Janeiro, Brazil). The provisional glass ionomer restoration was removed, and an absolute isolation was

achieved by applying a light-curing gingival barrier (FGM, Joinville, Santa Catarina, Brazil) around the tooth 24. For better visibility of the perforated area, an operating microscope (Alliance, São Paulo, São Paulo, Brazil) was used.

The root coronal area was flooded with 2.5% sodium hypochlorite (Asfer, São Caetano do Sul, São Paulo, Brazil), and the gutta-percha from the cervical third of the palatal canal and from the cervical and middle thirds of the buccal canal was removed using the ultrasonic tip R1-Clearsonic Black R1 (Helse Dental Technology, Santa Rosa de Viterbo, São Paulo, Brazil) at 10% power without cooling. A #15 K-file (Dentsply Maillefer, Ballaigues, Switzerland) was inserted into the palatal canal to confirm the correct path, and a periapical radiograph was taken (figure 2b). After visualizing the perforation, located in the cervical third of the root (figure 4a and b), the palatal canal was instrumented in the cervical and middle thirds with a Reciproc R-25 instrument (VDW GMBH, Munich, Germany). The palatal root canal length was measured with an electronic apex locator (Finepex-Schuster, Santa Maria, Rio Grande do Sul, Brazil). This canal was temporally sealed in the cervical third with Coltosol, a temporary restorative cement (Vigodent, Rio de Janeiro, Rio de Janeiro, Brazil) above a cotton pellet, to protect the canal (figure 4c). The root perforation was cleaned with 2.5% sodium hypochlorite (NaOCl) and a dentin spoon, dried with sterile paper tips, and sealed with MTA HP cement (Angelus, Londrina, Paraná, Brazil). For this, at first, a collagen sponge (Maquira, Maringá, Paraná, Brazil) was placed in the periodontal ligament area (figure 4d). Following, the MTA cement was mixed in a portion of powder for two drops of liquid, and then the cement was applied and condensed with a Schilder condenser (Odous de Deus, Belo Horizonte, Brazil) (figure 4e and 2c). A periapical radiograph was taken to assess the quality of the seal. Afterward, the cement was covered with a layer of glass ionomer (FGM, Joinville, Santa Catarina, Brazil) (figure 4f). The coltosol was removed and instrumentation of the palatal canal was finished with Reciproc R-40 used at the foramen with 2.5% sodium hypochlorite (NaOCl) irrigation. The instrumentation of the buccal canal was completed with Reciproc R25 also at the foramen after odontometry using an electronic apex locator (FinePex; Schuster Medical Equipment and Dental, Santa Maria, Rio Grande do Sul, Brazil) with a size #15 K-file (Dentsply Maillefer, Ballaigues, Switzerland). Medium gutta-percha cones (Dentsply Maillefer, Ballaigues, Switzerland) were calibrated to be 1 mm short of the canal foramen, and a cone fit radiograph was performed.

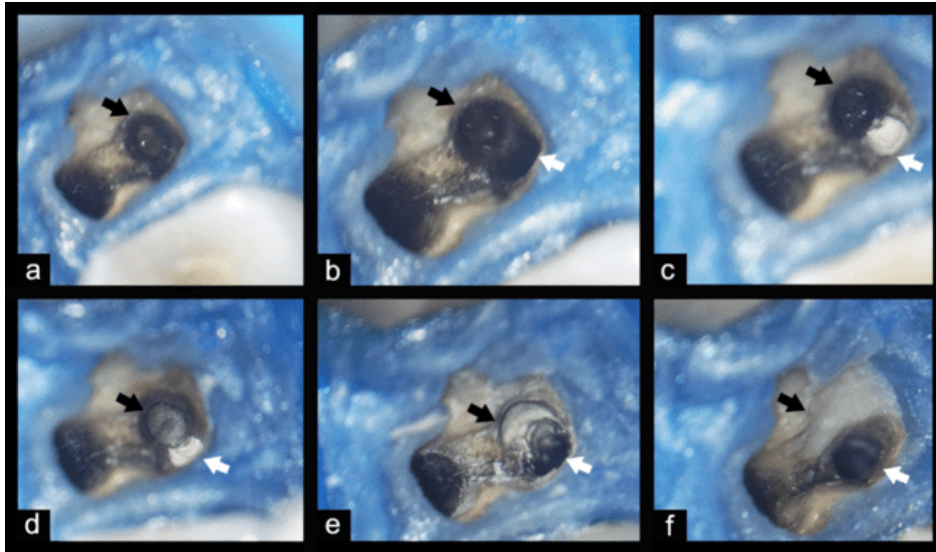


Figure 4. Perforation in the palatal root - black arrow (a). Radicular perforation - black arrow; palatal canal - white arrow (b). Radicular perforation - black arrow; palatal canal protected with Coltosol - white arrow (c). Collagen sponge barrier - black arrow; palatal canal protected with Coltosol - white arrow (d). Perforation filled with MTA HP - black arrow; palatal canal - white arrow (e). MTA superficially protected with a layer of glass ionomer - black arrow; free palatal canal - white arrow (f).

After instrumentation, passive ultrasonic irrigation was performed using a 20/.01 E1-Irrisonic tip (Helse Ultrasonic, Santa Rosa de Viterbo, São Paulo, Brazil) attached to a Newtron Booster ultrasonic unit, set at 2 mm from the working length and at 10% power. For the final irrigation, 2 mL of 2.5% NaOCl was introduced into the canal, and the ultrasonic tip was used to agitate the solution for 20 seconds. This process was repeated 3 times, totaling 6 mL of NaOCl and 1 min of agitation. The same procedure was then repeated with 17% EDTA and again with 2.5% NaOCl. After this protocol, the canals were irrigated with 0.9% saline solution. Absorbent paper points size #40 and #35 (Dentsply Maillefer, Ballaigues, Switzerland) were placed and maintained into the palatal and buccal canals, respectively, for 15 seconds. Once the canal dryness was confirmed, the gutta-percha cones were cemented using BioRoot RCS (Septodont, Saint-Maur-des-Fossés, France) by mixing one portion of powder with 5 drops of liquid. A quality control radiograph for root canal filling was then taken. The cones were cut and compacted using vertical condensation with a thermoplastic device (Woodpecker Medical Instrument Co., Guangxi, China) at 180°C. A provisional crown with orthodontic wire in the buccal canal was prepared to ensure long-term stability until the completion of the rehabilitation, and a final periapical radiograph was taken (figure 2d and e).

In the third session, the prosthetic rehabilitation began with the cementation of a prefabricated fibreglass post #2 (Angelus, Londrina, Paraná, Brazil). The temporary crown with orthodontic wire was removed, and local infiltration anaesthesia was administered using 2%

Comment [C1]: ???OBTURATION NOT CEMENTATION

Comment [C2]: SHEARED OFF

lidocaine with 1:100,000 epinephrine (Alphacaine, DFL, Rio de Janeiro, Brazil) for possible absolute isolation. The vestibular canal was reopened using a Gates drill #3 (Angelus), leaving 4mm of filling at the root apex, then prepared with a Largo drill #4 (Angelus), matching the diameter of the selected post. The post was adapted to the prepared canal, and excess coronal was removed with a high-speed diamond bur (KG Sorensen). Following the manufacturer's instructions, the post was cleaned with 70% alcohol, silane (Angelus) was applied and left to dry for 1 minute, followed by the application of 3M ESPE Single Bond Universal adhesive (3M, Sumaré, São Paulo, Brazil). The root canal was etched with 37% phosphoric acid (Biodinâmica) for 15 seconds, rinsed with water, dried with air and paper points (Dentsply Maillefer), and the adhesive was applied. The chosen cement was RelyX Ultimate Dual Cure Resin Cement (3M), mixed on a glass slab and applied to the prepared canal with the fibreglass post. Excess cement was removed, and each side was light-cured (SDI Limited) for 20 seconds. In the same session, a core build-up was done using 3M ESPE Filtek Z250 composite resin (3M) A3 and prepared coronally with diamond bur #2135 (KG Sorensen). A temporary crown was made using the antagonist tooth impression technique, ensuring proper occlusion. After removing excess acrylic resin, the margin was relined for a good fit, and the provisional crown was polished and cemented temporarily with Hydcal calcium hydroxide paste (Maquira).

In the initial restorative appointment, a sequence of three intraoral scans was performed (Primescan, Dentsply Sirona, Bensheim, Germany). The first scan, referred to as the preoperative scan of the maxilla, was conducted with the provisional crown in place, allowing its functional anatomy to be later replicated during the digital design phase. Subsequently, the scan of the antagonist arch was carried out. Following these initial scans, the crown was removed, and final preparation was performed using high-speed diamond burs of fine and extra-fine grit (KG Sorensen, São Paulo, Brazil), aimed at achieving better margin delineation for the restoration (Renne et al., 2012). The scanning of the arch with the final preparation was performed using the triple cord retraction technique (Ultradent, South Jordan, United States), wherein a sequence of three retraction cords of increasing diameters is placed between the gingiva and preparation, with removal of the largest cord immediately before scanning. The scan files were exported in STL format at maximum resolution (100%).

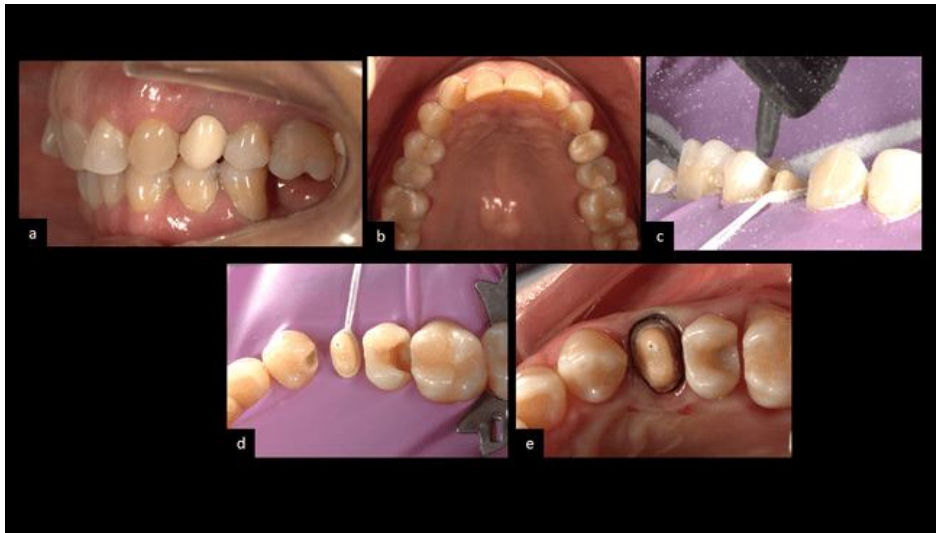
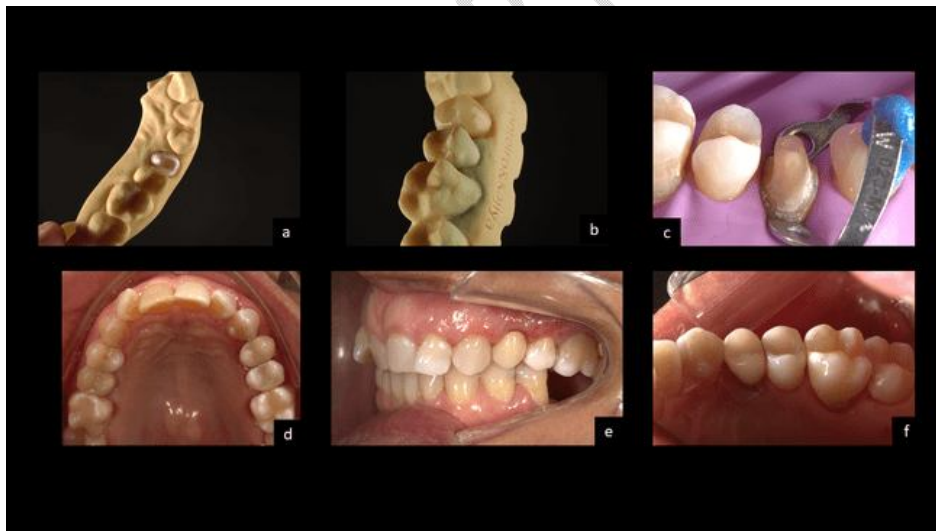
Figure 5. Initial aspect of temporary restoration - lateral view with retractors (a). Initial aspect of temporary restoration - occlusal view with retractors and mirror (b). Aluminum oxide sandblasting of preparations (c). Aspect of preparations after aluminum oxide sandblasting (d). Crown preparation margin in triple cord retraction technique after removal of thicker cords (e).

The digital design of the premolar crown was conducted using DentalCADExocad software (Exocad GmbH, Darmstadt, Germany). Initially, the three scans were imported, and the final crown design was based on the anatomy of the provisional crown captured during the preoperative scan. Additionally, articulated models were designed: one without a die for adjusting occlusal and interproximal contacts of the restoration, and one with a Geller die for verifying restoration adaptation, adjusting the finish line, and facilitating restoration manipulation during the laboratory phase. The STL file of the restoration and the models was sent to LycheeSlicer software for support placement and slicing for printing on an Anycubic Photon Mono 4K 3D printer (Anycubic Technologies, Shenzhen, China) using MakertechPrizmaBioprov resin A2 shade (Makertech Labs, São Paulo, Brazil) for the restoration and 3DCure Dental resin (3DCure, Belo Horizonte, Brazil) for the model.

After 3D printing the crown and models, the pieces were washed in isopropyl alcohol for 5 minutes using a Wash&Cure wash and cure chamber (Anycubic Technologies, Shenzhen, China), followed by a 15-minute curing cycle in the same machine. After the post-curing process, the supports were carefully removed with an orthodontic cutting plier. Crown finishing and adjustment were performed using a micromotor and handpiece. Initially, remaining supports were removed with a tungsten carbide minicut drill (American Burs, Santa Catarina, Brazil). Initial finishing and polishing were carried out using a sequence of abrasive rubber points (American Burs, Santa Catarina, Brazil). Occlusal and interproximal contact adjustments were made using the same rubber points. Final polishing and shine were achieved with felt wheels (Jota Brasil, Santa Catarina, Brazil) and polishing paste (FGM, Santa Catarina, Brazil).

In the final restorative session, the printed restoration was adhesively cemented. Initially, the provisional crown was removed, and the dental preparation was cleaned with 0.12% chlorhexidine and pumice (Biodinâmica, Paraná, Brazil) using a Robinson brush (American Burrs, Santa Catarina, Brazil). The preparation was isolated with rubber dam and stabilized with a modified clamp. Then, the surface of the preparation was sandblasted with 50-micron aluminum oxide (BioArt, São Carlos, Brazil) at a controlled distance, pressure, and time. Next, 37% phosphoric acid (Biodinâmica, Ibiporã, Paraná) was applied to the enamel for 30 seconds and rinsed abundantly with a water jet for the same conditioning time. Excess moisture was removed with a light air jet at a controlled distance. A layer of Single Bond Universal adhesive (3M, São Paulo, Brazil) was applied to the enamel and dentin using a microbrush (Kg Sorensen, São Paulo) for 20 seconds. Then, a light air jet was applied. For cementation, RelyX Ultimate cement (3M, São Paulo, Brazil) was dispensed onto a glass plate, and the pastes were mixed. The cement was applied inside the restoration, which was seated onto the remaining dental structure, and the excess resin cement was removed with a brush. The light-curing (Radii Cal, SDI, São Paulo, Brazil) was done following the manufacturer's recommendations. After photopolymerization, occlusal adjustment was performed with a 3118FF diamond bur (KG Sorensen, Espírito Santo, Brazil), and the restoration was finished with a 30-blade multilayer



bur 9904FF (Microdont, São Paulo, Brazil).

Figure 6. Occlusal view of 3d-printed model with Geller die (a). 3d-Printed restorations adapted to 3d-printed rigid model (b). Isolated crown preparations with rubber dam and stabilized clamp (c). Final aspect of 3d-printed restorations - occlusal view with retractors and mirror just after adhesive cementation (d). Final aspect of 3d-printed restorations - lateral view with retractors immediately after adhesive cementation (e). Final aspect of 3d-printed restorations (f).

2.1. Follow-Up

After 6 months, a periapical radiograph of the tooth was taken (figure 2f), and clinical tests of vertical and horizontal percussion, as well as palpation, were conducted. The patient did not present any painful symptoms in any of the tests, and there was no presence of periodontal pockets. After nine months, the same tests were performed, and the patient did not exhibit any painful symptoms or pain upon vertical and horizontal percussion. During the periodontal probing, a depth of 1 mm was recorded on all surfaces. The periapical radiograph showed bone tissue formation (figure 2g). In the same session, to confirm the repair observed on the periapical radiograph, a cone beam computed tomography was performed, which clearly showed bone tissue formation in the perforated region (figure 3b).

3. DISCUSSION

Root perforations are endodontic complications that present significant challenges in treatment efforts aimed at saving the tooth (Gorni et al., 2022). The prognosis depends on the timing, location, and size of the perforation (Bakhtiar et al., 2017). The presence of large perforations involving bone tissue destruction, periodontal pockets, and delayed sealing of the perforation from its onset contribute to a poorer prognosis (Bakhtiar et al., 2017; Mente et al., 2010; Gorni et al., 2022; AAE). In this case report, the conditions were unfavorable due to a large perforation in the palatal root and significant destruction of the alveolar crest. Additionally, the extended time interval between the perforation and the commencement of the treatment was one of the challenges to achieving success in the case. The requirements for maintaining the tooth included thoroughly cleaning the area with sodium hypochlorite solution, sealing the perforation, retreatment of the canals, and achieving effective rehabilitative treatment.

Regarding the visualization of images suggestive of bone resorption, this case report clearly demonstrates the difference between periapical radiography and CBCT. In the radiographic image, a radiolucent area was visible on the mesial side of tooth 24, indicating bone rarefaction and loss of trabecular bone. However, when observing the tomographic images, the extent of the resorption was much greater than the one suggested by the periapical radiograph. In addition to indicating the location of the perforation, the CBCT diagnostic tool was essential for understanding the magnitude of the case. Similar situations are confirmed in clinical studies, demonstrating the accuracy of CBCT in identifying the size of periapical lesions that are not perceptible in conventional periapical radiographs (Tsai et al., 2009; de Paula-Silva et al., 2012).

MTA is a material of choice for sealing root canal perforations because it is biocompatible, exhibits good sealing ability, is bioactive, induces the formation of mineralized tissue, and has an alkaline pH during and after the setting reaction, contributing to its antimicrobial effect (Hansen et al., 2011; Delfino et al., 2021). Given the extensive and difficult-to-access perforation in this case report, the cement used facilitated clinical management. MTA HP is available in powder/liquid form. The tricalcium silicate and dicalcium silicate particles react

with water immediately after mixing the two components, solid and liquid, resulting in a hydrated calcium silicate gel and calcium hydroxide that raise the cement's pH to 9 (Camilleri et al., 2007; Guimarães et al., 2018; Jiménez-Sánchez et al., 2019). This gel forms a rigid structure after the setting reaction, which is reported to be around 22 minutes (Ferreira et al., 2019). Although in vitro studies have shown higher solubility of MTA HP compared to conventional MTA (Guimarães et al., 2018), in this case report, the periapical radiograph showed that the material remained intact and did not dissolve over a one-year period.

Regarding the positive aspects of tissue repair with this cement, its biomineralization potential has been demonstrated in both in vivo and in vitro studies (Cintra et al., 2017; Santiago et al., 2021). It has been shown to stimulate the differentiation of osteoblasts (Santiago et al., 2021) and promote the proliferation of fibroblasts, the most abundant cells in the periodontal ligament, which is significant for the connective tissue repair process in a root perforation (Cintra et al., 2017; Delfino et al., 2023). Additionally, the material stimulates the immunoexpression of interleukin 10 (IL-10), an anti-inflammatory cytokine that suppresses the expression of inflammatory cytokines such as IL-1 and IL-6, creating a favorable environment for bone repair (Martinho et al., 2014; Delfino et al., 2023). These findings in the literature corroborate our present case report, in which MTA HP provided bone and periodontal repair and reduced inflammation.

The perforation site in this case report was narrow and difficult to access for cement placement, necessitating the use of an operative microscope and delicate pluggers. In addition to these tools, the plasticity of MTA HP contributed to the management of the material within the perforation. Conventional MTA contains only distilled water in its liquid component, resulting in a sandy cement that disintegrates during the sealing process. In contrast, MTA HP includes a polymer (polyvinylpyrrolidone) added to the liquid, which ensures plasticity and better handling, maintaining its integrity, consistency, and ease of insertion into the perforation cavity (Guimarães et al., 2018).

In addition to using a calcium silicate-based repair cement in powder and liquid form, a root canal sealer with solid and liquid components, BioRoot RCS, was also used. This cement shows high biocompatibility with periodontal ligament stem cells (Collado-González et al., 2017), which is advantageous since the cement extruded into the buccal canal. This cement maintains an alkaline pH, but exhibits high solubility in in vitro tests (Siboni et al., 2017). However, after six months and nine months of treatment follow-up, the cement did not dissolve and was not resorbed by the body in this case report.

The final rehabilitation of an endodontically treated tooth should be carefully planned, considering special factors such as the presence of a ferrule and the need for an intracanal post (Dietschi et al., 2007). In this reported case, the tooth had previously undergone endodontic treatment and had an intracanal preparation and a full coverage crown. Nonetheless, additional strategies were employed to enhance the longevity of the restoration and preserve the remaining dental structure, including the use of magnification and digital technologies for

increased precision, also isolation and immediate dentin sealing to optimize adhesion (Carvalho et al., 2018).

The restoration was manufactured using a fully digital workflow. The crown was 3D printed using a ceramic-filled resin, as 3D printing, an additive manufacturing method, offers advantages over subtractive milling. These advantages include lower equipment acquisition costs, reduced material waste and cost, and the benefits associated with digital production methods such as fewer or faster appointments and treatments with greater predictability (Rekow, 2019). In addition, indirect restorations printed in resin with filler have shown mechanical properties similar to milled indirect restorations, along with good marginal adaptation, a critical factor for the longevity and fit of a restoration (Daher et al., 2022).

Saving a tooth with a root perforation presents many challenges that involve the multidisciplinary collaboration of various fields of dentistry working together. Removing the crown and post, as well as sealing the perforation so close to the palatal canal, was one of the difficulties that required the technological resources available in endodontics, such as ultrasound, a microscope, and high-quality repair materials. Undoubtedly, without these tools, managing the case would have been limited.

4. CONCLUSION

After nine months of follow-up, this report concludes that it is possible to save a tooth that appears to be hopeless due to root perforations through decontamination, the use of calcium silicate cements, and the technologies available in both endodontics and rehabilitation.

ETHICAL APPROVAL

All authors hereby declare that all experiments have been examined and approved by the appropriate ethics committee and have therefore been performed in accordance with the ethical standards laid down in the 1964 Declaration of Helsinki. For this case, approval was obtained from the local ethics committee of the Piracicaba Dental School, FOP-UNICAMP, with the CAAE: 75732523.4.0000.5418.

CONSENT

All authors declare that written informed consent was obtained from the patient (or other approved parties) for publication of this case report and accompanying images. A copy of the written consent is available for review by the Editorial office/Chief Editor/Editorial Board members of this journal.

REFERENCES

- American Association of Endodontists (2003) Glossary of Endodontic Terms Chicago, IL, USA.
- Arens DE, Torabinejad M. Repair of furcal perforations with mineral trioxide aggregate: two case reports. *Oral Surg Oral Med Oral Pathol Oral Radiol Endod.* 1996 Jul;82(1):84-8.
- Bakhtiar H, Mirzaei H, Bagheri MR, Fani N, Mashhadiabbas F, BaghabanEslaminejad M, Sharifi D, Nekoofar MH, Dummer P. Histologic tissue response to furcation perforation repair using mineral trioxide aggregate or dental pulp stem cells loaded onto treated dentin matrix or tricalcium phosphate. *Clin Oral Investig.* 2017 Jun;21(5):1579-1588.
- Beavers RA, Bergenholtz G, Cox CF. Periodontal wound healing following intentional root perforations in permanent teeth of *Macaca mulatta*. *Int Endod J.* 1986 Jan;19(1):36-44.
- Camilleri J. Characterization and hydration kinetics of tricalcium silicate cement for use as a dental biomaterial. *Dent Mater.* 2011 Aug;27(8):836-44.
- Camilleri J. Hydration mechanisms of mineral trioxide aggregate. *Int Endod J.* 2007 Jun;40(6):462-70.
- Camilleri J. Will bioceramics be the future root canal filling materials? *Curr Oral Health Rep* 2017;4:228-38.
- Carvalho MA, Lazari PC, Gresnigt M, Del Bel Cury AA, Magne P. Current options concerning the endodontically-treated teeth restoration with the adhesive approach. *Braz Oral Res.* 2018 Oct 18;32(suppl 1):e74. doi: 10.1590/1807-3107bor-2018.vol32.0074.
- Chen CC, Ho CC, David Chen CH, Ding SJ. Physicochemical properties of calcium silicate cements for endodontic treatment. *J Endod.* 2009 Sep;35(9):1288-91.
- Cintra LTA, Benetti F, de Azevedo Queiroz ÍO, de Araújo Lopes JM, Penha de Oliveira SH, Sivieri Araújo G, Gomes-Filho JE. Cytotoxicity, Biocompatibility, and Biomineralization of the New High-plasticity MTA Material. *J Endod.* 2017 May;43(5):774-778.
- Clauder T. Present status and future directions - Managing perforations. *Int Endod J.* 2022 Oct;55 Suppl 4:872-891.
- Collado-González M, García-Bernal D, Oñate-Sánchez RE, Ortolani-Seltenerich PS, Lozano A, Forner L, Llana C, Rodríguez-Lozano FJ. Biocompatibility of three new calcium silicate-based endodontic sealers on human periodontal ligament stem cells. *Int Endod J.* 2017 Sep;50(9):875-884.

de Paula-Silva FW, Wu MK, Leonardo MR, da Silva LA, Wesselink PR. Accuracy of periapical radiography and cone-beam computed tomography scans in diagnosing apical periodontitis using histopathological findings as a gold standard. *J Endod.* 2009 Jul;35(7):1009-12.

Delfino MM, de Abreu Jampani JL, Lopes CS, Guerreiro-Tanomaru JM, Tanomaru-Filho M, Sasso-Cerri E, Cerri PS. Comparison of Bio-C Pulpo and MTA Repair HP with White MTA: effect on liver parameters and evaluation of biocompatibility and bioactivity in rats. *Int Endod J.* 2021 Sep;54(9):1597-1613.

Delfino MM, Jampani JLA, Lopes CS, Guerreiro-Tanomaru JM, Tanomaru-Filho M, Sasso-Cerri E, Cerri PS. Participation of fibroblast growth factor-1 and interleukin-10 in connective tissue repair following subcutaneous implantation of bioceramic materials in rats. *Int Endod J.* 2023 Mar;56(3):385-401.

Dietschi D, Duo O, Krejci I, Sadan A. Biomechanical considerations for the restoration of endodontically treated teeth: a systematic review of the literature--Part 1. Composition and micro-and macrostructure alterations. *Quintessence international.* 2007 Oct 1;38(9).

E Daher R, Ardu S, di Bella E, Krejci I, Duc O. Efficiency of 3D-printed composite resin restorations compared with subtractive materials: Evaluation of fatigue behavior, cost, and time of production. *J Prosthet Dent.* 2022 Nov 1:S0022-3913(22)00481-4. doi: 10.1016/j.prosdent.2022.08.001.

Estrela C, Decurcio DA, Rossi-Fedele G, Silva JA, Guedes OA, Borges ÁH. Root perforations: a review of diagnosis, prognosis and materials. *Braz Oral Res.* 2018 Oct 18;32(suppl 1):e73.

Ferreira CMA, Sassone LM, Gonçalves AS, de Carvalho JJ, Tomás-Catalá CJ, García-Bernal D, Oñate-Sánchez RE, Rodríguez-Lozano FJ, Silva EJNL. Physicochemical, cytotoxicity and in vivo biocompatibility of a high-plasticity calcium-silicate based material. *Sci Rep.* 2019 Mar 8;9(1):3933.

Gorni FG, Ionescu AC, Ambrogi F, Brambilla E, Gagliani MM. Prognostic Factors and Primary Healing on Root Perforation Repaired with MTA: A 14-year Longitudinal Study. *J Endod.* 2022 Sep;48(9):1092-1099.

Guimarães, B.M., Prati, C., Duarte, M., Bramante, C.M. & Gandolfi, M.G. (2018) Physicochemical properties of calcium silicate-based formulations MTA Repair HP and MTA Vitalcem. *Journal of Applied Oral Science*, 26, e2017115.

Hansen SW, Marshall JG, Sedgley CM. Comparison of intracanal EndoSequence Root Repair Material and ProRoot MTA to induce pH changes in simulated root resorption defects over 4 weeks in matched pairs of human teeth. *J Endod.* 2011 Apr;37(4):502-6. doi: 10.1016/j.joen.2011.01.010. PMID: 21419298.

Jiménez-Sánchez MDC, Segura-Egea JJ, Díaz-Cuenca A. Physicochemical parameters - hydration performance relationship of the new endodontic cement MTA Repair HP. *J Clin Exp*

Dent. 2019 Aug 1;11(8):e739-e744. doi: 10.4317/jced.56013. PMID: 31598203; PMCID: PMC6776399.

Kvinnslund I, Oswald RJ, Halse A, Grønningsaeter AG. A clinical and roentgenological study of 55 cases of root perforation. *Int Endod J*. 1989 Mar;22(2):75-84.

Lee SJ, Monsef M, Torabinejad M. Sealing ability of a mineral trioxide aggregate for repair of lateral root perforations. *J Endod*. 1993 Nov;19(11):541-4.

Marciano MA, Costa RM, Camilleri J, Mondelli RF, Guimarães BM, Duarte MA. Assessment of color stability of white mineral trioxide aggregate angelus and bismuth oxide in contact with tooth structure. *J Endod*. 2014 Aug;40(8):1235-40.

Martinho FC, Leite FR, Chiesa WM, Nascimento GG, Feres M, Gomes BP. Signaling pathways activation by primary endodontic infectious contents and production of inflammatory mediators. *J Endod*. 2014 Apr;40(4):484-9.

Mente J, Hage N, Pfefferle T, Koch MJ, Geletneky B, Dreyhaupt J, Martin N, Staehle HJ. Treatment outcome of mineral trioxide aggregate: repair of root perforations. *J Endod*. 2010 Feb;36(2):208-13.

Olçay K, Ataoglu H, Belli S. Evaluation of Related Factors in the Failure of Endodontically Treated Teeth: A Cross-sectional Study. *J Endod*. 2018 Jan;44(1):38-45.

Palczewska-Komsa M, Kaczor-Wiankowska K, Nowicka A. New Bioactive Calcium Silicate Cement Mineral Trioxide Aggregate Repair High Plasticity (MTA HP)-A Systematic Review. *Materials (Basel)*. 2021 Aug 14;14(16):4573.

Rekow ED. Digital dentistry: The new state of the art - Is it disruptive or destructive? *Dent Mater*. 2020 Jan;36(1):9-24. doi: 10.1016/j.dental.2019.08.103.

Renne W, McGill ST, Forshee KV, DeFee MR, Mennito AS. Predicting marginal fit of CAD/CAM crowns based on the presence or absence of common preparation errors. *J Prosthet Dent*. 2012 Nov;108(5):310-5. doi: 10.1016/S0022-3913(12)60183-8.

Saghiri MA, Asatourian A, Orangi J, Lotfi M, Soukup JW, Garcia-Godoy F, Sheibani N. Effect of particle size on calcium release and elevation of pH of endodontic cements. *Dent Traumatol*. 2015a Jun;31(3):196-201.

Saghiri MA, Gutmann JL, Orangi J, Asatourian A, Sheibani N. Radiopacifier particle size impacts the physical properties of tricalcium silicate-based cements. *J Endod*. 2015b Feb;41(2):225-30.

Santiago MC, Gomes-Cornélio AL, de Oliveira LA, Tanomaru-Filho M, Salles LP. Calcium silicate-based cements cause environmental stiffness and show diverse potential to induce osteogenesis in human osteoblastic cells. *Sci Rep*. 2021 Aug 18;11(1):16784.

Seltzer S, Sinai I, August D. Periodontal effects of root perforations before and during endodontic procedures. *J Dent Res*. 1970 Mar-Apr;49(2):332-9.

Siboni F, Taddei P, Zamparini F, Prati C, Gandolfi MG. Properties of BioRoot RCS, a tricalcium silicate endodontic sealer modified with povidone and polycarboxylate. *Int Endod J*. 2017 Dec;50 Suppl 2:e120-e136.

Torabinejad M, Watson TF, Pitt Ford TR. Sealing ability of a mineral trioxide aggregate when used as a root end filling material. *J Endod*. 1993 Dec;19(12):591-5.

Touré B, Faye B, Kane AW, Lo CM, Niang B, Boucher Y. Analysis of reasons for extraction of endodontically treated teeth: a prospective study. *J Endod*. 2011 Nov;37(11):1512-5.

Tsai P, Torabinejad M, Rice D, Azevedo B. Accuracy of cone-beam computed tomography and periapical radiography in detecting small periapical lesions. *J Endod*. 2012 Jul;38(7):965-70.

UNDER PEER REVIEW