

Case report

A case study of clinical mastitis in 2-Year-Old Sahel Goat in Nigeria and its Implication on Public Health and Economic

Abstract

Mastitis, a common inflammation of the udder in goats, is a significant economic concern. Primiparous goats, especially, are susceptible to this disease. *Staphylococcus*, *Streptococcus*, and *Escherichia coli* are primary culprits. In this article, we report a case of mastitis in a two-year-old Sahel goat. Symptoms observed include swollen, painful udders, abnormal milk, and fever. Diagnosis involves physical examination and laboratory tests. Milk sample from the affected udder was cultured on mannitol salt agar and incubated at 37°C for 24 hours. The case was confirmed as staphylococci mastitis following biochemical test and Gram's staining. Treatment often includes antibiotics and analgesics. Prevention is crucial. Proper hygiene, timely milking, and vaccination can significantly reduce the risk of mastitis. Early detection and treatment are essential to prevent further complications and ensure the health of both the goat and its offspring.

Keywords: Mastitis; Staphylococcus species; Milk; Sahel goat; Public health

Introduction

Primiparous goat is a goat that is given birth for the first time. The goat has the tendency to develop infectious mastitis (Machado, 2018). Mastitis is the inflammation of the udder caused by infectious agents such as *Staphylococcus*, *Streptococcus*, *Escherichia coli*, and some Fungi (Machado, 2018). Mastitis is the most important economic health problem in dairy goats. The disease leads to a decrease in milk quality and production volume. Milk from animals that is suffering from mastitis may be rejected due to reduce quality and high chance of transmitting zoonotic diseases to milk consumers (Udoh *et al.*, 2019).

The predisposing factors are genetics, environment, teat injury, poor hygiene and milking procedure (Machado, 2018). The prevalence of sub-clinical mastitis was highest (Ameh *et al* 1993, DanMallan&Pimenov, 2019) compared to clinical mastitis (Ameh *et al.*, 1999, Dan mallam *et al*,

2019). In this article, we report a case of staphylococci mastitis in a primiparous Sahel goat in Maiduguri, Nigeria.

Material and Methods

The case presented describes the case of a 2 year old Sahel goat which presented unilateral sub-clinical mastitis infection (figure 1). The case was brought to the large animal clinic of the Veterinary Teaching Hospital, University of Maiduguri, Nigeria. The doe kidded about a month before the presentation of the case. The goat was managed semi intensively with other animals including sheep (3), ram (1), and other goats (4 does and 2 bucks.). The farmer feeds the animals with maize bran, groundnut hay and left over from the kitchen and farm byproducts. The farm has had history of previous Mastitis in goat. The animals had no history of vaccination and previous medication in the farm.



Figure 1: unilateral right uddermastitis at the point of presentation to the clinic

Physical examination

The physical examination includes palpation of udder and an examination of milk samples for consistency and color change. On palpation, it was observed that the mammary lymph nodes were enlarged, the affected udder appeared larger than the unaffected udder. The swollen udder was warm, tender to touch, and the doe resisted on palpation due to pain. The udder was firm and hard. The milk was purulent and contained flakes, and clots. Based on historical investigations, and physical examinations, the case was diagnosed as clinical mastitis.

Clinical Examination

The rectal temperature (41.8°C), respiratory rate 34 cycles per minute, pulse rate (85 beats per minute) and PCV (32.3%) were measured.

Laboratory Examination

Milk was collected aseptically from affected udder by hand milking. The sample was cultured on brilliant green agar (BGA) for coliform bacteria count (Figure 2) and on mannitol salt agar (MSA) for isolation of staphylococcus species. The inoculated plates were incubated at 37°C for 24 hours. An isolated colony was characterized by morphological and biochemical tests (Figure 3). The isolate on MSA was identified as staphylococcus species based on biochemical tests.

We carried out an antimicrobial susceptibility testing of isolates against 10 panels of antimicrobials by using KirbyBauer's disc diffusion method. The result is presented in tables I. The infected udder's milk had coliform count $> 3.0 \times 10^6$ CFU/ml. and bacteria count $> 4.5 \times 10^6$ CFU/ml. Milk from the uninfected udder yielded no viable bacteria growth on nutrients and brilliant green agar plates.

Table 1 Antimicrobial susceptibility profile of Staphylococcus Isolated from Mastitis Sahel goat

S/N	ANTIBIOTICS	READINGS	SENSITIVE	INTERMEDIATE	RESISTANT
1	Chloramphenicol	14mm	≥ 18 mm	13-17mm	≤ 12 mm
2	Streptomycin	14.5mm	≥ 15 mm	12-14mm	≤ 11 mm
3	Rifampin	12.5mm	≥ 20 mm	17-19mm	≤ 16 mm
4	Erythromycin	16.5mm	≥ 23 mm	14-22mm	≤ 13 mm
5	Amoxicillin	12.5mm	≥ 18 mm	14-17mm	≤ 13 mm

6	Levofloxacin	26mm	$\geq 17\text{mm}$	14-16mm	$\leq 13\text{mm}$
7	Gentamycin	16.5mm	$\geq 15\text{mm}$	13-14mm	$\leq 12\text{mm}$
8	Ciprofloxacin	26mm	$\geq 21\text{mm}$	21-30mm	$\leq 20\text{mm}$
9	Ampiclox	17mm	$\geq 17\text{mm}$	14-16mm	$\leq 13\text{mm}$
10	Norfloxacin	18mm	$\geq 17\text{mm}$	13-16mm	$\leq 12\text{mm}$

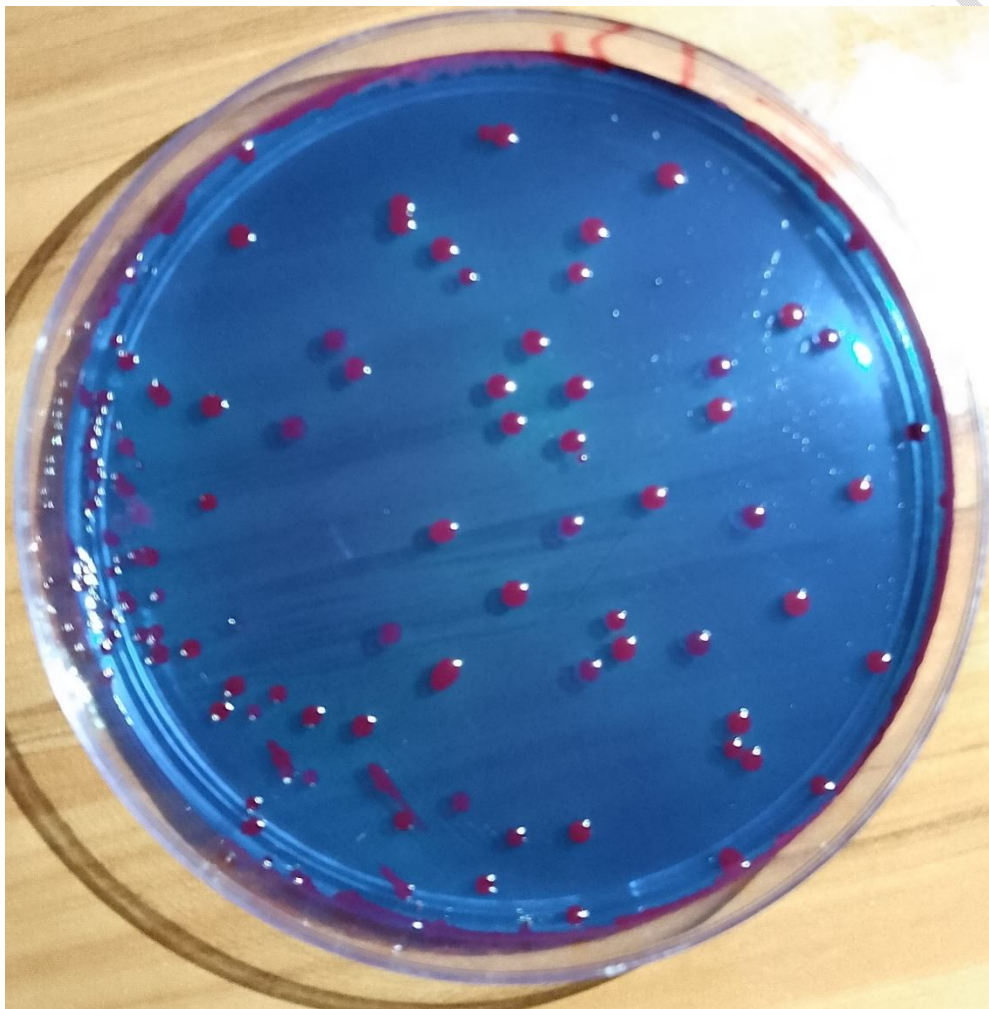


Figure 2: Bacteria Count on Brilliant Green Agar (BGA)

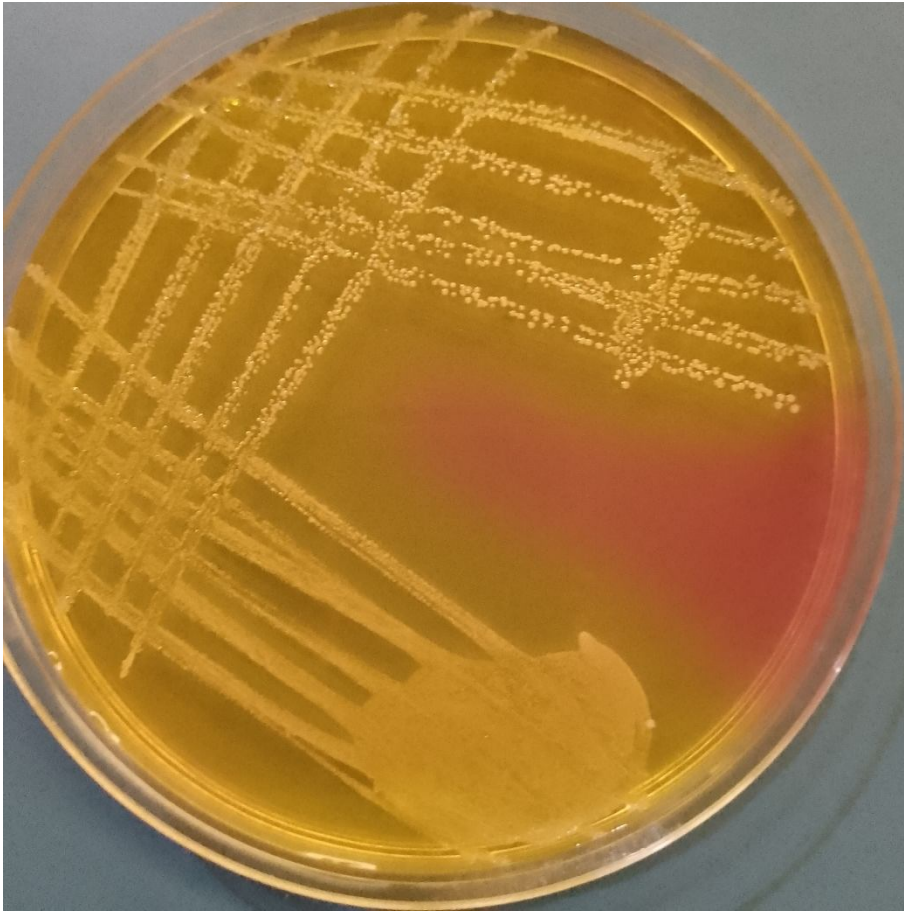


Figure 3: Isolation of Staphylococcus Species from Mastitis udder Using Mannitol Salt Agar (MSA)

Treatment/Clinicals Management

The animal was treated according to the treatment plan presented in table 2 below.

Table 2: Treatment Plan

S/N	Drugs Used (Conc.)	Therapeutic Category	Dosage (mg/kg)	Dose (ml)	Route Of Admin/ Duration
1	Oxytetracycline L A (20%)	Antibiotic	20	2	I.M once
2	Diclofenac sodium 25 mg/ml	Analgesic	2.5	2	I.M x3/7
3	Gentamicin sulphate 40 mg/ml	Antibiotic	5	2.5	I.M x5/7

Four days following treatment, the goat had gradual reduction in the size of the udder restoration of normal milk and temperature returned to normal.

Discussion.

Mastitis is an economic disease in dairy goat Worldwide (Ameh *et al.*, 1999; Yoksaet *al.*, 2024) And the disease has caused serious economic and veterinary losses in small ruminant industry in Nigeria (Ameh *et al.*, 1999). Hence there is need to develop resistant goat breed and vaccine against staphylococcus mastitis by the National Veterinary Research Institute (NVRI) Vom and National Animal Production Research Institute (NAPRI), Shika in Nigeria. The NVRI and NAPRI have the mandate to develop animal vaccines and development of quality animal breeds in Nigeria. (Sennugaet *al.*, 2022; Olowu, 2008).

Goat milk is gaining acceptance in Nigeria as awareness on the importance of goat milk on social media is on the rise (Igwegbeet *al.*, 2015). Therefore, factors that may affect the production of quality milk are of importance to the stakeholder in the goat industry.

The isolation of *Staphylococcus* species from mastitis udder is of serious public health concern because humans can be infected by consuming unpasteurized contaminated milk from early infection (Hameed *et al.*, 2017; Ahmed *et al.*, 2024). Hence, we recommend that goat milk be pasteurized before use. Also, the doe may transmit resistant staphylococci strain to the kid. This may affect the health of and proper development of the kid and adversely impact the economy of the farmer.

We recommend prompt and early reporting to the nearest veterinary hospital or clinic for effective action. Also, previous case reports have suggested that antenatal care will ensure a healthy udder for the wellbeing of the doe and kids (Shittu *et al.*, 2008).

Conclusion: The isolation of *Staphylococcus* species from a mastitis udder that demonstrated multiple antimicrobial resistance have severe economic and public health implications. Humans may be infected by consumption of contaminated milk. The animal may also transmit resistant strain to other animals including humans.

Disclaimer (Artificial intelligence)

Author(s) hereby declare that NO generative AI technologies such as Large Language Models (ChatGPT, COPILOT, etc.) and text-to-image generators have been used during the writing or editing of this manuscript.

References

- Ahmed, A. D., Hiko, A., Belina, D., Gebremeskel, H. F., & Kebede, I. A. (2024). Identification and antimicrobial susceptibility profiles of Staphylococcus species isolated from raw cow milk, and swabs in smallholder dairy farms in Meta district, Eastern Ethiopia. *BMC microbiology*, 24(1), 284.
- Ameh, J. A., & Tari, I. S. (1999). Observations on the prevalence of caprine mastitis in relation to predisposing factors in Maiduguri. *Small Ruminant Research*, 35(1), 1-5.
- Ameh, J. A., Addo, P. B., Adekeye, J. O., & Gyang, E. O. (1993). Prevalence of clinical mastitis and of intramammary infections in Nigerian goats. *Preventive Veterinary Medicine*, 17(1-2), 41-46.
- Ameh, J. A., Addo, P. B., Adekeye, J. O., & Gyang, E. O. (1993). Prevalence of clinical mastitis and of intramammary infections in Nigerian goats. *Preventive Veterinary Medicine*, 17(1-2), 41-46.
- Danmallam, F. A., & Pimenov, N. V. (2019). Study on prevalence, clinical presentation, and associated bacterial pathogens of goat mastitis in Bauchi, Plateau, and Edo states, Nigeria. *Veterinary World*, 12(5), 638.
- Hameed, K. G., Sender, G., & Korwin-Kossakowska, A. (2017). Public health hazard due to mastitis in dairy cows. *Animal science papers and rep*, 25(2), 73-85.
- Igwegbe, A. O., Maina, F. J., Kassum, A. L., Agbara, G. I., Chibuzo, E. C., & Badau, M. H. (2015). Evaluation and acceptability of yoghurt drink processed from goat milk and a combination of goat and cow milks. *International Journal of Biotechnology and Food Science*, 3(4), 41-48.
- Machado, G. P. (2018). Mastitis in small ruminants. *Anim. Husb. Dairy Vet. Sci*, 2(4), 1-9.
- Olowu, T. A. (2008). Assessment of Agricultural Information Needs in African, Caribbean and Pacific (ACP) States: Eastern Africa: Country study Nigeria.
- Sennuga, S. O., Lai-Solarin, W. I., Adeoye, W. A., & Alabuja, F. O. (2022). Extension's role in improving livestock production: information needs, institutions and opportunities. *Int. J Agric. Nutr*, 4(2), 43-51.
- Shittu, A., Chafe, U. M., Buhari, S., Junaidu, A. U., Mgaji, A. A., Salihu, M. D., ... & Jibril, A. (2008). An overview of mastitis in Sokoto red goat, Nigeria. *Sokoto Journal of Veterinary Sciences*, 7(1).

Udoh, E. K., Kwaga, J. K. P., Umoh, J. U., & Raji, M. A. (2019). Occurrence of mastitis and methicillin resistant *Staphylococcus aureus* in Goats in Zaria, Kaduna State, Nigeria. *Nigerian Veterinary Journal*, 40(2), 164-177.

Yoksa, D. T., Mohzo, D. L., Igbokwe, N. A., James, M. N., & Igbokwe, I. (2024). Subclinical mastitis of lactating Sahel goats from urban smallholder herds in Maiduguri, Nigeria: Prevalence and intramammary infections. *VETERINARIA*, 73(2), 129-137.

UNDER PEER REVIEW