

INTRIGUES AND CHALLENGES OF KAPOSI SARCOMA MANAGEMENT IN A RESOURCE-POOR CLINICAL SETTING – A CASE SERIES.

Comment [ak1]: Intrigues and Challenges of Kaposi Sarcoma Management in Resource-poor Clinical Setting - A Case Series

ABSTRACT

Comment [ak2]: "The background, case presentation, and conclusions are written in one paragraph under the heading 'ABSTRACT'."

Background

Kaposi sarcoma (K.S) is a rare type of cancer with four clinical variants which has a link to Human Herpes Virus (HHV-8) in the etiology. Commonly seen are the acquired immunodeficiency syndrome (AIDS) -related variants. Kaposi Sarcoma occurring after solid-organ transplant is a cause of public health concern as immunosuppressive medications especially the Calcineurin inhibitors play a key role in the development of Kaposi Sarcoma after organ transplantation.

Case presentation

In this series, six patients with Kaposi Sarcoma were presented. Four patients had retro-viral disease; sero-positive to HIV 1 & 2 who were not compliant with their Highly Active Retro-viral Therapy (HAART) and a male patient with post-transport K.S.

Comment [ak3]: From which country and location were the cases collected? And during what time period? (Ethical approval mention there)

Comment [ak4]: Only Five patients mention in this paragraph!

Conclusion

In patients with Kaposi Sarcoma, early detection and switching Transplant recipient on Calcineurin inhibitors to mTOR inhibitors are basic parameters for successful management.

Key words

Kaposi Sarcoma, Retroviral disease (RVD), Renal transplantation, Calcineurin inhibitors, mTOR inhibitors.

Comment [ak5]: The two words (Key words) are merged into one word (Keywords) and italicized.

Comment [ak6]: All Keywords are written in italics and separated by semicolon (;).

INTRODUCTION:

Kaposi Sarcoma (K.S) is a neoplasm with strong relationship with Human Herpes Virus -8 (HHV-8) and a multi-factorial pathogenesis linked to immune dysfunction. K.S is a multi-focal disease which could run an indolent course(1) The relevance of Kaposi sarcoma stems from the effects of immunosuppression either from medications or disease conditions and the body's immunological response.

Worldwide, K.S ranks 31 in cancer incidence and mortality with a prevalence of 71% in Africa, 8.8% in Europe and Latin 8.3% in Latin America(2,3) Sub-Saharan Africa has experienced a significant increase in mobility and mortality of K.S following the emergence of HIV/AIDS epidemic(4,5). Sub-Saharan Africa accounts for about 70% of the global HIV

infection burden and this correlates with the increase K.S incidence in the region(4,5). Epidemic K.S has been identified due to co-infection of both HIV and Kaposi's sarcoma associated herpes virus (KSHV) (5). The male gender and older age are considered a risk factor in endemic and classical K.S while epidemic K.S is commoner in the young age group(3,4,6–8).

The iatrogenic K.S develops as a result of medications causing immunosuppression. The use of calcineurin inhibitors have been implicated in the aetiopathogenesis of K.S following solid organ transplantation.

Comment [ak7]: Where is the reference?

Immunosuppressive medications given in rheumatologic conditions like seropositive rheumatoid arthritis also plays a role in the pathophysiology of K.S. Kaposi's Sarcoma has been recorded among patients with rheumatologic conditions as they receive long-term steroids and biologics such as Rituximab (9–11).

Calcineurin inhibitors such as cyclosporine often administered for prevention of graft rejection post solid organ transplantation have been implicated in the development of K.S due to its direct tumorigenic effects. It also accelerates the development of tumours through transforming growth factor-beta (TGF-beta) production(12). There is a hypothesis of the tumour growth induction by calcineurin inhibitors through over-expression of the angiogenic cytokine vascular growth factor(13).

Case presentation

Case 1: -- (Post-transplant K.S)

The first case is a 47-year-old male of Igbo tribe, a teacher, who presented with a 2-year history of hyperpigmented rashes on the right leg with associated pustular lesions discharging seropurulent fluid and unilateral leg swelling. He was known to be living with diabetes mellitus and hypertensive of 10 and 7 years respectively and had a right renal transplant four years prior to his presentation to the dermatology clinic. Following renal transplantation, he was placed on cyclosporine, methylsulfonylmethane and prednisolone. Upon examination, he had right leg swelling up to the knee with multiple hyperpigmented plaques and discrete skin nodules and with peau d'orange appearance. Histology reviewed sections of tissue covered by epidemics that exhibited papillomatosis and acanthosis. In the dermis, fibrocollagenous bundle and vascular spaces lined by plump spindle shaped cells were seen. A diagnosis of iatrogenic K.S was entertained and a review of his immunotherapy was conducted. Cyclosporine was switched to sirolimus prior to the commencement of chemotherapy. There was remarkable improvement in his skin lesions following the switch from a calcineurin inhibitor (cyclosporine) to mTOR inhibitor (sirolimus).

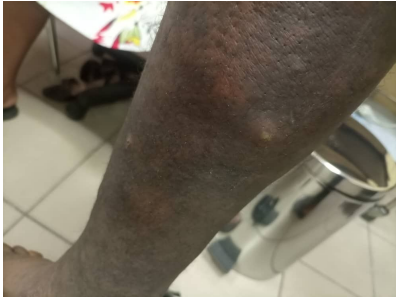

Fig 1 :Post-transplant K.S
Case 2: -- (Suspected classic K.S)

The second case is an 84-year-old retired fisherwoman who presented with tender nodules in both legs with background exfoliative dermatitis. Histology showed spindle cells and a diagnosis of K.S was entertained. She was treated with **IV Doxorubicin** monthly for two years with regression of the lesion. However, she declined further treatment when she developed cough and was diagnosed radiologically of tuberculosis.

Comment [ak8]: Has the treatment been switched from cyclosporine to IV Doxorubicin? Explain that.

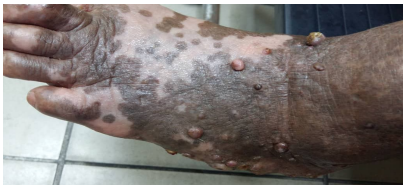

Fig 2 :Suspected classic K.S

Before treatment

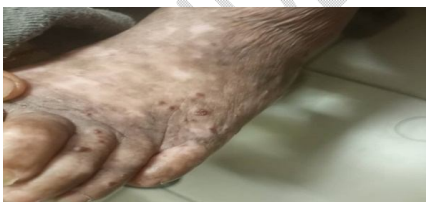

Fig 3 :Pre-treatment

After treatment

Case 3

This is a 47-year-old known retroviral disease patient who was on highly active anti-retroviral therapy (HAART) and defaulted on his HAART for 4 years, presenting with extensive nodules on both lower limbs.

Histology showed a malignant vascular proliferation within the dermis with lesions consisting of spindle shaped cells. He was treated as a case of K.S and was commenced on IV Doxorubicin. After three sessions of treatment there was an acknowledgeable improvement in his mobility as well as reduction in size of the Kaposi's sarcoma nodules.

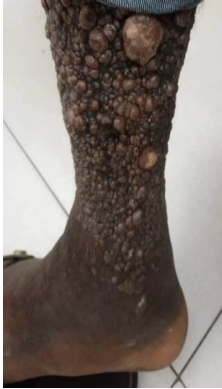

Fig 4 :Post treatment

Case 4

This is a 43-year-old male, diagnosed with HIV, presenting with multiple skin eruptions on his trunk and back. Dermatological examination showed multiple well-defined non-scaly, non-tender, discrete hyperpigmented patches of variable size over the trunk and back. From the morphology of the skin lesions, in addition to a background history of retroviral disease, a diagnosis of K.S was entertained. Skin biopsy showed proliferation of small caliber vessels without the superficial dermis with vessels containing red blood cells and some seemed to be forming around pre-existing vessels (Promontory sign). This appearance favoured the early stage (Patch stage) of K.S.

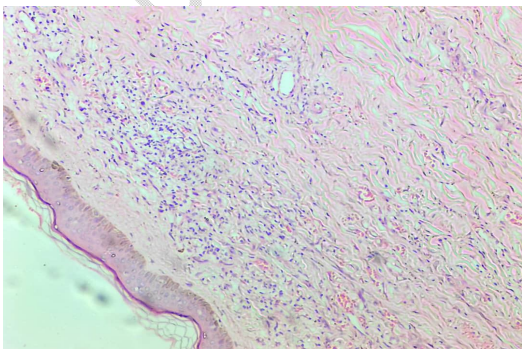


Fig 5 :Promontory sign shown on histology

Case 5: -- (Suspected Oral Kaposi)

This was a 34-year-old male, postgraduate student of mixed race with a history of unprotected multiple sexual partners including men. He presented on account of multiple non-scaly, discrete, hyperpigmented patches on his hard palate and around his face. Further history revealed unintentional weight loss. Following laboratory investigations, he was HIV-positive with CD4 count less than 100 cells/ml. Patient however declined further care including skin biopsy and self-discharged.

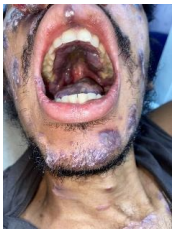

Fig 6 :Suspected Oral Kaposi

Case 6

This was a 48-year-old female civil servant diagnosed with RVD but defaulted to HAART and presented with multiple hyperpigmented coalescing nodules in the lower limbs. A diagnosis of Kaposi sarcoma was confirmed histologically. Unfortunately, she could not commence treatment due to inability to provide medications from severe financial constraints.

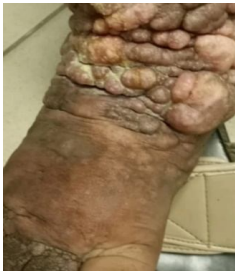

Fig 7 :multiple hyperpigmented coalescing nodules

Discussion

A diagnosis of Kaposi sarcoma is made by biopsy of affected lesion showing spindle cells with abnormal proliferation of new blood vessels.

As demonstrated by the first case, K.S could arise following solid organ transplants with a mean time between transplantation and development of K.S being 18.7 ± 25.2 months. Immunosuppressive agents given to prevent allograft rejection is a co-factor for the development of K.S. Calcineurin inhibitors such as cyclosporine have been implicated due to their direct tumorigenic effects and promotion of tumour growth through Transforming growth Factor beta production (TGF-) and may induce tumour growth through over expression of the androgenic cytokine vascular endothelial growth factor (VEGF).

Comment [ak9]: Reference ?

Oral K.S is frequently seen in HIV patients and is associated with higher mortality rate with the palate and gingiva been the most commonly affected sites. Both oral and extra-oral manifestation can occur concomitantly. This is as demonstrated in the fifth case. Kaposi sarcoma is an AIDS-defining tumour and is noted to occur at CD4 counts less than 200 cells/ml. However, though CD4 levels are a risk factor, K.S has been reported even among patients with robust CD4 count.

K.S can present in the various stages. Lesions usually starts at macules and then progress to papule, plaques and nodules. In the patch stage, lesions are flat with numerous new vessel formation. The patch stage as demonstrated by the fourth case showed the classical promontory sign.

In the treatment of iatrogenic K.S, switching immunosuppressive medications from Calcineurin inhibitors to mTOR such as sirolimus has shown to be of great benefits(14) as demonstrated by case one.

Systemic treatments alone have demonstrated potential to regress lesions of KS irrespective of the sites. These include chemotherapy and immunomodulators.

Impact on the quality of life

K.S particularly occurring in the lower limbs limit mobility and symptoms such as pain and discomfort can affect the general well-being of patients(15).

Challenges of management

RVD and the cosmetic embarrassment posed by Kaposi sarcoma causes stigmatization with resultant delay in seeking adequate healthcare.

Financial constraint is a major issue in resource-poor settings as health care is not subsidized. The patient in case six faced this challenge and was subsequently lost to follow up.

Conclusion:

In patients with Kaposi Sarcoma, early detection and switching transplant recipient on Calcineurin inhibitors to mTOR inhibitors are basic parameters for successful management. More research is needed to study optimization of immune system even in

disease conditions and advocacy for national health insurance policy is needed to aid healthcare delivery in resource-limited settings.

Ethical approval:

This was duly obtained from ethical committee of the Rivers State University Teaching Hospital.

References:

1. Ruocco E, Ruocco V, Tornesello ML, Gambardella A, Wolf R, Buonaguro FM. Kaposi's sarcoma: Etiology and pathogenesis, inducing factors, causal associations, and treatments: Facts and controversies. *Clin Dermatol*. 2013 Jul;31(4):413–22.
2. Báez MVJ. Kaposi's sarcoma a series of cases and review of the literature. *MOJ Clinical & Medical Case Reports*. 2021;11(4):104–8.
3. Rogena EA, Simbiri KO, De Falco G, Leoncini L, Ayers L, Nyagol J. A review of the pattern of AIDS defining, HIV associated neoplasms and premalignant lesions diagnosed from 2000–2011 at Kenyatta National Hospital, Kenya. *Infect Agent Cancer*. 2015 Dec 24;10(1):28.
4. Motlhale M, Sitas F, Bradshaw D, Chen WC, Singini MG, de Villiers CB, et al. Epidemiology of Kaposi's sarcoma in sub-Saharan Africa. Vol. 78, *Cancer Epidemiology*. Elsevier Ltd; 2022.
5. Sissolak G, Mayaud P. AIDS-related Kaposi's sarcoma: epidemiological, diagnostic, treatment and control aspects in sub-Saharan Africa. *Tropical Medicine & International Health*. 2005 Oct 6;10(10):981–92.
6. Sitas F, Carrara H, Beral V, Newton R, Reeves G, Bull D, et al. Antibodies against Human Herpesvirus 8 in Black South African Patients with Cancer. *New England Journal of Medicine*. 1999 Jun 17;340(24):1863–71.
7. Lidenge SJ, Tran T, Tso FY, Ngowi JR, Shea DM, Mwaiselage J, et al. Prevalence of Kaposi's sarcoma-associated herpesvirus and transfusion-transmissible infections in Tanzanian blood donors. *International Journal of Infectious Diseases*. 2020 Jun;95:204–9.
8. Ziegler J, Newton R, Bourbouli D, Casabonne D, Beral V, Mbide E, et al. Risk factors for Kaposi's sarcoma: A case-control study of HIV-seronegative people in Uganda. *Int J Cancer*. 2003 Jan 10;103(2):233–40.
9. Joo M, Soon Lee S, Jin Park H, Shin HS. Iatrogenic Kaposi's sarcoma following steroid therapy for nonspecific interstitial pneumonia with HHV-8 genotyping. *Pathol Res Pract*. 2006 Feb;202(2):113–7.
10. Pantanowitz L, Früh K, Marconi S, Moses A V, Dezube BJ. Pathology of rituximab-induced Kaposi sarcoma flare. *BMC Clin Pathol*. 2008 Dec 23;8(1):7.

Comment [ak10]: Add DOIs to thereferences.

11. Barozzi P, Potenza L, Riva G, Vallerini D, Quadrelli C, Bosco R, et al. Changes in T-Cell Responses Against Human Herpesvirus-8 Correlate with the Disease Course of Iatrogenic Kaposi's Sarcoma in a Patient with Undifferentiated Arthritis. *Semin Arthritis Rheum*. 2009 Dec;39(3):170–5.
12. Mariappan AL, Desai S, Locante A, Desai P, Quraishi J. Iatrogenic Kaposi Sarcoma Precipitated by Anti-Tumor Necrosis Factor-Alpha (Anti-TNF- α) Therapy. *Cureus*. 2021 Feb 16;
13. Ume AC, Pugh JM, Kemp MG, Williams CR. Calcineurin inhibitor (CNI)-associated skin cancers: New insights on exploring mechanisms by which CNIs downregulate DNA repair machinery. *Photodermatol Photoimmunol Photomed*. 2020 Nov 27;36(6):433–40.
14. Roy D, Sin SH, Lucas A, Venkataramanan R, Wang L, Eason A, et al. mTOR Inhibitors Block Kaposi Sarcoma Growth by Inhibiting Essential Autocrine Growth Factors and Tumor Angiogenesis. *Cancer Res*. 2013 Apr 1;73(7):2235–46.
15. Dezube B. Issue 3 1 Opinion Citation: Dezube B. Discussion on psychosocial implications of kaposi sarcoma. *J Pain Manage Ther* [Internet]. 2023;7(3):148. Available from: <https://www.alliedacademies.org/pain-management-and-therapy/>

UNDER PEER REVIEW