

Original Research Article

N-Acetyl Cysteine and Zinc Sulfate Attenuates Acute Crude Oil-Induced Oxidative Stress and Testicular Structural Damage in Male Wistar Rats

ABSTRACT

Introduction: Crude oil toxicity is caused by the production of reactive oxygen species (ROS), leading to oxidative stress and tissue damage. Both natural and synthetic antioxidants have shown potential in reducing the impact of this stress. This study evaluated the protective effects of N-Acetyl Cysteine (NAC) and Zinc Sulfate (ZnSO₄) in alleviating testicular cytoarchitecture damage and oxidative stress in male Wistar rats after short-term exposure to Bonny light crude oil (BLCO)

Materials and Methods: Fifty male Wistar rats (weighing 180–200g) were used in the study and divided into ten groups of five animals each. Group I served as the control, receiving distilled water, while Group II, the negative control, received BLCO (600mg/kg). Groups III and IV were given 100 and 200mg/kg NAC, respectively. Groups V and VI received BLCO (600mg/kg) along with 100 and 200mg/kg NAC, respectively. Similarly, Groups VII and VIII were administered 0.5mg/kg and 1mg/kg ZnSO₄, while Groups IX and X received BLCO (600mg/kg) combined with 0.5mg/kg and 1mg/kg ZnSO₄, respectively. All treatments were administered orally via an orogastric cannula for three weeks. Testicular tissue samples were stained with haematoxylin and eosin to obtain photomicrographs of the tissues. They were also homogenized for the assay of malondialdehyde (MDA), superoxide dismutase (SOD), glutathione peroxidase (GPx), glutathione (GSH) and total antioxidant capacity (TAC) by the method of ELISA.

Results: Exposure to BLCO resulted in a significant increase in MDA and GSH levels in BLCO-exposed animals compared to control ($P < 0.05$) which were mitigated by co-treatment with NAC and ZnSO₄. However, BLCO exposure caused a significant decrease in CAT and TAC levels compared to controls ($p < 0.05$), but this decrease was significantly mitigated in rats co-treated with NAC and ZnSO₄. Histological analysis of the testes from rats exposed to BLCO revealed notable alterations in testicular morphology, including interstitial exudates, and atrophic and degenerated seminiferous tubules which indicate testicular degeneration. However, this was improved on supplementation with NAC and ZnSO₄.

Conclusion: This study demonstrates that BLCO-exposed rats experienced toxicity affecting both testicular antioxidants and testicular structure. Our findings suggest that NAC and ZnSO₄ protected and improved testicular function in BLCO-exposed rats by thus enhancing testicular antioxidant levels and cytoarchitecture.

Comment [11]: - In general, the abstract should be brief and comprehensive.
- It should be in one paragraph, do not divide it into multiple paragraphs under headline.

Comment [12]: Prefer to rewrite the paragraph of methodology as the below:

The present study included fifty adult male rats classified into ten groups, each consisted of five rats, one used as a control group and the others as treated groups, the control animals (Group I) were received distilled water. Group II used as negative control and received (600 mg/kg) of BLCO. Groups III and IV were received 100 and 200 mg/kg of NAC, respectively. Groups V and VI were received (600mg/kg) of BLCO along with (100 and 200 mg/kg) of NAC, respectively. Similarly, Groups VII and VIII were received (0.5 mg/kg) and (1 mg/kg) of ZnSO₄, while Groups IX and X were received (600mg/kg) of BLCO combined with (0.5 mg/kg) and (1 mg/kg) of ZnSO₄, respectively. All treatments were administered for three weeks via the oral route. Testicular tissue was assessed by using histopathological examinations as well as some markers of oxidative stress and the antioxidant were evaluated by using ELISA technique.

Keywords: Bonny Light Crude Oil, N-Acetyl Cysteine, Zinc Sulfate, Testicular dysfunction, Antioxidants

INTRODUCTION

Environmental pollution from petroleum products is a significant issue in crude oil-producing regions, posing serious health risks to both aquatic and terrestrial animals, including humans [1, 2]. The Niger Delta region of Nigeria is particularly vulnerable to the harmful effects of crude oil spills. Although oil-producing regions are significantly affected by contamination, oil workers are at even greater risk. Furthermore, the practice of consuming crude oil for supposed medicinal benefits exacerbates this health threat [3-5]. The Bonny Light crude (BLCO) oil is a high-quality, light, sweet crude produced in Nigeria. Known for its low sulfur content and high American Petroleum Institute (API) gravity, it is highly sought after in global markets due to its ease of refining into high-value products like gasoline and diesel and remains one of Nigeria's key crude oil exports, playing a crucial role in the country's economy [6]. Bonny Light Crude Oil (BLCO) has the potential to cause both acute lethal and chronic sub-lethal toxicities, depending on the mode of exposure.

Comment [13]: This paragraph is not related to the topic and should be removed. (No need to summarize and mentioned the economic aspect)

Research has demonstrated that crude oil can cause toxic effects in multiple organs of both humans and animals, including the kidneys, liver, lungs, neuroendocrine system, blood, and reproductive system [4, 7-9]. These toxicities are known to occur by way of the generation of reactive oxygen species (ROS) which causes oxidative stress and ultimately, tissue damage [10]. Oxidative stress arises when there is an imbalance between the production of reactive species and the body's antioxidant defence system. [11-13]. Cellular damage is mainly caused by the failure of antioxidants to neutralize oxygen radicals, ultimately resulting in infertility when reproductive organs and tissues are affected [4, 10]. Lipid peroxidation is a chain reaction that produces free radicals all the time, which start more peroxidation. There is a correlation between oxidative stress and enhanced lipid peroxidation, protein breakdown, and other macromolecule degradation [14, 15]. The presence of polyunsaturated fatty acids in crude oil may be the cause of the observed rise in lipid peroxidation levels as the fatty acids function as excellent substrates for lipid peroxidation due to their content of bis-allylic methylene groups [16]. Antioxidants are molecules that prevent oxidative damage by scavenging reactive oxygen species (ROS) or inhibiting their production, thereby reducing or preventing the oxidation of other molecules [17-20]. N-acetylcysteine (NAC) and Zinc Sulfate ($ZnSO_4$) are widely used antioxidant compounds. N-acetylcysteine (NAC) is a powerful antioxidant that works by replenishing intracellular levels of glutathione, one of the body's most important antioxidants. NAC helps neutralize reactive oxygen species (ROS) and reduces oxidative stress by promoting the synthesis of glutathione, directly scavenging free radicals, and supporting the detoxification process in cells [21-23]. Zinc Sulfate on the other hand Zinc contributes to the function of various antioxidant enzymes, such as superoxide dismutase (SOD), which helps neutralize reactive oxygen species (ROS) [24, 25]. Research on the potential beneficial effects of these key antioxidant compounds on

Comment [14]: This paragraph needs to be rephrased to make it more clearly.

Comment [15]: Replace it with other word such as (elimination, removal)

Comment [16]: Used as antioxidant.....

Comment [17]: It's better to put this phrase in brackets to indicate that it is a definition of glutathione, or use a new alternative sentence that indicates the definition of glutathione.

reproductive health, particularly in relation to improving distorted testicular cytoarchitecture and oxidative stress caused by BLCO exposure, is limited. Our previous study emphasized their role in alleviating reproductive hormone and seminal fluid dysfunction resulting from BLCO exposure [4]. This study therefore, aims to evaluate the potential protective effects of NAC and ZnSO₄ in mitigating distorted testicular cytoarchitecture and oxidative stress in male Wistar rats following short-term exposure to Bonny light crude oil.

Comment [18]: Remove this word

MATERIALS AND METHODS

Experimental materials and research design

Bonny Light crude oil was sourced from the Nigerian National Petroleum Corporation (NNPC) in Warri, Nigeria. N-acetyl cysteine (A7250-10G) was obtained from Sigma Aldrich, USA, while Zinc Sulfate was sourced locally (Bactolac Pharmaceutical Inc, USA). Fifty (50) male Wistar rats (weighing 180–200g) were acquired from the Animal House of the Department of Physiology at Delta State University, Abraka, for the study. The rats underwent a three-week acclimatization period under standard animal husbandry conditions. They were housed in clean, well-ventilated wooden cages with optimal conditions, including a 12-hour light/dark cycle, temperatures ranging from 28–31°C, and humidity levels of 45–50%. The rats had unrestricted access to standard rat pellets and tap water. They were divided into ten (10) groups of five (5) animals each. Groups I and II served as control and negative control and received distilled water and BLCO (600mg/kg)[3, 5], respectively. Groups III and IV received 100 and 200mg/kg NAC [26] only while groups V and VII received BLOC (600mg/kg) in addition to 100 and 200mg/kg NAC respectively. Similarly, groups VII and VIII received ZnSO₄ at 0.5 ZnSO₄ and 1mg/kg[27] respectively while Groups IX and X received BLOC (600mg/kg) in combination with 0.5 and 1mg/kg ZnSO₄ respectively. All supplementations were done orally via an orogastric cannula between 8 am and 10 AM daily for three weeks.

Comment [19]:

- The Cages that made from the wooden are unacceptable for housing rats, because their urine will drip into the wood, and it may cause ammonia buildup, which can lead to different disease.
- The Rats may chew through the wood, allowing them to escape from the cages.

Comment [110]: This paragraph needs to be rephrased to make it more clearly.

Comment [111]: - What is the mechanism which was used to prepare the Suspension of BLOC, NAC and ZnSO₄?

- It's must be mentioned before summarize the treatment process.

Tissue Sample Collection, Laboratory Assay and Histological Study

The animals were subjected to overnight fasting and were euthanized through cervical dislocation and the testis was carefully dissected and used for tissue homogenate biochemical analysis and histological studies. Testicular tissue homogenate was done using 50mg of testis tissue in normal saline (3ml, 0.9% NaCl) in an ice water bath. The homogenate was then centrifuged at 3000 rpm for 10 min at 4°C[28, 29]. The clear supernatant was collected and used formalondialdehyde (MDA), superoxide dismutase (SOD), glutathione peroxidase (GPx), glutathione (GSH) and total antioxidant capacity (TAC) assay via ELISA following instructions from standard laboratory kits (Shanghai Sunred Biological Technology Co., Ltd.). The tissues were dehydrated in ethanol, cleared in xylene, embedded in paraffin and stained using haematoxylin and eosin for the histological study[30]. Photomicrographs of the desired results were obtained using the Olympus research photographic microscope(BX51, Olympus, Japan).

Comment [112]: Where is the fixation step?

Comment [113]: Mention the name of the technique or method with the reference.

Statistical Analysis

The data from this study were analyzed using GraphPad Prism 8 Biostatistics Software (GraphPad Software, Inc., La Jolla, USA, version 8.0). Results are expressed as Mean \pm SEM. Further analysis was performed using one-way analysis of variance (ANOVA), followed by Tukey's post hoc test for multiple comparisons. A significance level of $p < 0.05$ was applied to all tests.

Ethical Considerations

The animals were handled in compliance with the highest ethical standards for animal experimentation. The research protocol and study design received approval from the University of Port Harcourt Research Ethics Committee.

Results

Table 1: Effect of the effect of NAC and ZnSO₄ on sperm oxidative stress biomarkers, antioxidant enzymes of BLCO exposed-male Wistar rats

Groups/Doses/(kg)	MDA (unit/mg)	SOD (unit/mg)	Catalase (U/L)	Glutathione (mg/dL)	TAC (mmol/L)
Control	19.11 \pm 0.26	49.60 \pm 0.92	35.00 \pm 1.00	3.41 \pm 0.13	8.98 \pm 0.06
BLCO (600mg/kg)	29.96 \pm 0.66*	25.60 \pm 0.50*	20.20 \pm 0.58*	4.86 \pm 0.07*	4.12 \pm 0.03*
NAC (100mg/kg)	18.38 \pm 0.40 [#]	35.60 \pm 0.67 [#]	26.80 \pm 0.48 [#]	2.65 \pm 0.14 [#]	6.63 \pm 0.18 [#]
NAC (200mg/kg)	20.56 \pm 0.17 [#]	38.00 \pm 0.70 [#]	27.00 \pm 0.83 [#]	2.78 \pm 0.10 [#]	6.91 \pm 0.07 [#]
NAC(100mg/kg)+ BLCO(600mg/kg)	21.71 \pm 0.26 ^{#a}	28.02 \pm 0.53 ^{#aβ}	18.20 \pm 0.66 ^{#aβ}	3.01 \pm 0.06 [#]	4.51 \pm 0.22 ^{#aβ}
NAC(200mg/kg) + BLCO(600mg/kg)	19.14 \pm 0.49 ^{#ϕ}	29.56 \pm 0.52 ^{#aβ}	21.80 \pm 0.66 ^{#ϕaβ}	3.12 \pm 0.07 [#]	4.85 \pm 0.07 ^{#aβ}
ZnSO ₄ (0.5mg/kg)	17.88 \pm 0.47 [#]	27.64 \pm 0.92 [#]	25.40 \pm 0.50 [#]	3.12 \pm 0.07 [#]	6.26 \pm 0.22 [#]
ZnSO ₄ (1mg/kg)	17.59 \pm 0.14 [#]	30.70 \pm 0.68 [#]	23.40 \pm 0.81 [#]	2.61 \pm 0.14 [#]	6.24 \pm 0.21 [#]
ZnSO ₄ (0.5mg/kg) + BLCO(600mg/kg)	19.92 \pm 0.30 [#]	30.68 \pm 0.76 [#]	20.20 \pm 0.58 ^{#a}	3.06 \pm 0.06 [#]	4.62 \pm 0.14 ^{#ab}
ZnSO ₄ (1mg/kg) + BLCO(600mg/kg)	17.65 \pm 0.27 [#]	32.04 \pm 0.82 ^{#a}	22.80 \pm 0.86 [#]	2.82 \pm 0.06 [#]	5.19 \pm 0.04 ^{#ab}

Values are expressed as Mean \pm SEM (n = 5) (ANOVA followed by Tukey's test). BLCO (BLCO=Bony Light Crude Oil. NAC = N-acetylcysteine. ZnSO₄ = Zinc Sulfate).

* $P < 0.05$: significantly different when compared with the control group.

[#] $P < 0.05$: Significantly different when compared with BLCO.

^a $P < 0.05$: significantly different when compared with NAC_a (100mg/kg).

^{β} $P < 0.05$: significantly different when compared with NAC _{β} (200mg/kg).

^{ϕ} $P < 0.05$: Dose-dependent significant difference.

^a $P < 0.05$: significantly different when compared with ZnSO_{4a}(0.5mg/kg).

^b $P < 0.05$: significantly different when compared with ZnSO_{4b}(1mg/kg).

^c $P < 0.05$: significantly different when compared with ZnSO_{4c}(0.5mg/kg)

Comment [114]: In addition to the table, there should be more explanation in the results to show more accurate

Comment [115]: Duplicate words

Comment [116]: Since the study was conducted on the testicular tissue therefore, must be replace the 'sperm oxidative stress' with **testicular oxidative stress**.

Comment [117]: Are you sure there is no significant with control group?

For ex.

ZnSO₄(0.5mg/kg) 17.88 \pm 0.47[#]

ZnSO₄(1mg/kg) 17.59 \pm 0.14[#]

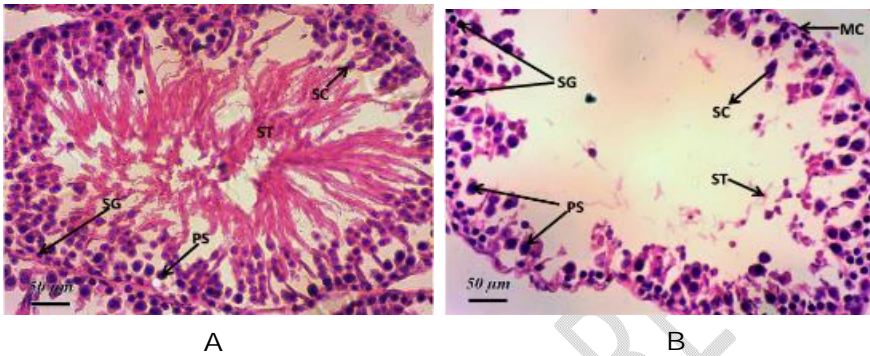
ZnSO₄(1mg/kg) + BLCO(600mg/kg) 17.65 \pm 0.27[#]

Needs to be reviewed for this MDA results and other parameters as well.

Table 1 presents the effects of NAC and ZnSO₄ on oxidative stress biomarkers in male Wistar rats exposed to BLCO for both short and long-term durations. Exposure to BLCO resulted in a significant increase in MDA levels compared to the control group ($p < 0.05$). However, co-treatment with NAC and ZnSO₄ significantly reduced MDA levels in BLCO-exposed rats compared to those exposed to BLCO alone. Similarly, BLCO exposure caused a significant decrease in catalase levels compared to controls ($p < 0.05$), but this decrease was significantly mitigated in rats co-treated with NAC and ZnSO₄. Short-term BLCO exposure led to a significant increase in GSH levels compared to controls, which was notably reduced in rats co-

treated with NAC and ZnSO₄. Additionally, the TAC of BLCO-exposed rats was significantly lower than that of the control group. Co-treatment with higher doses of NAC and ZnSO₄ significantly increased TAC levels in BLCO-exposed rats compared to those receiving only BLCO.

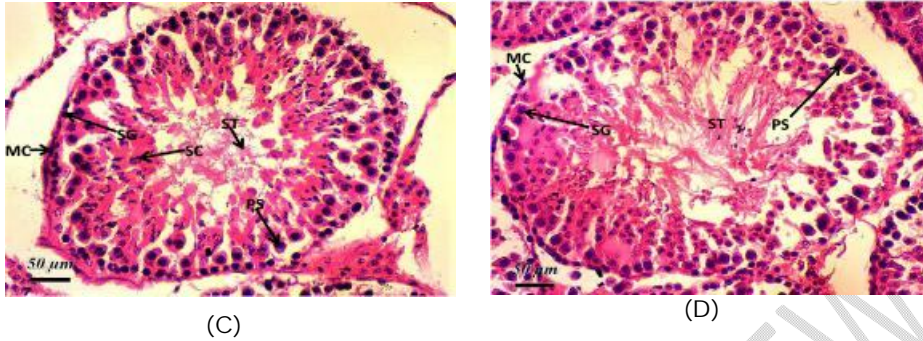
Comment [119]: The summarized of results must be conduct before the table.



MC – myoid cell, PS – primary spermatocyte, SG – spermatogonia, SC – Sertoli cells, ST - spermatids

Figure 1. Photomicrograph of a testicular section of control (A) and BLCO-exposed rats (B) stained with Haematoxylin and Eosin (H&E) at x100 magnification.

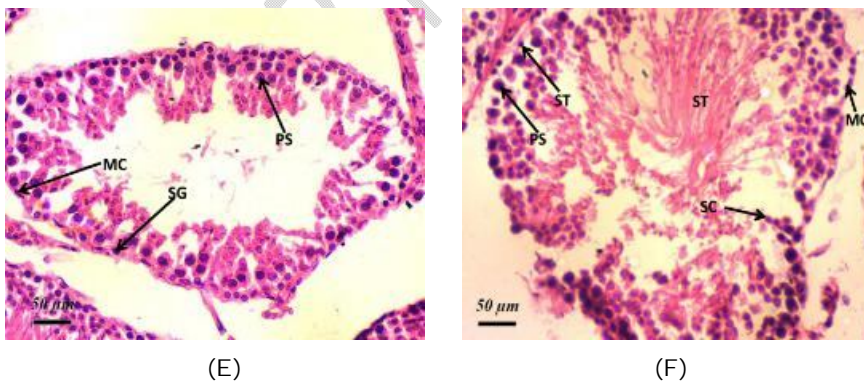
Slide A of the testicular histology photomicrograph displays normal testicular architecture, with seminiferous tubules surrounded by the tunica albuginea. Visible structures include seminiferous tubules, Sertoli cells, and spermatocytes. The Sertoli cells exhibit a normal tubular shape with round nuclei located in the cytoplasm, while the spermatocytes are round with nuclei present in the cytoplasm. In contrast, Slide B reveals poor testicular architecture, characterized by atrophic seminiferous tubules lined by a stratified germinal epithelium consisting of a basal spermatogonia layer, indicative of testicular degeneration. Longitudinal Sertoli cells are also evident among the sparse spermatids, along with fibroconnective tissue (composed of myoid cells) encasing the seminiferous tubules.



MC – myoid cell, PS – primary spermatocyte, SG – spermatogonia, SC – Sertoli cells, ST - spermatids

Figure 2: Photomicrograph of a testicular section of NAC (C:100mg/kg and D: 200mg/kg) administered to rats stained with Haematoxylin and Eosin (H&E) x100 magnification.

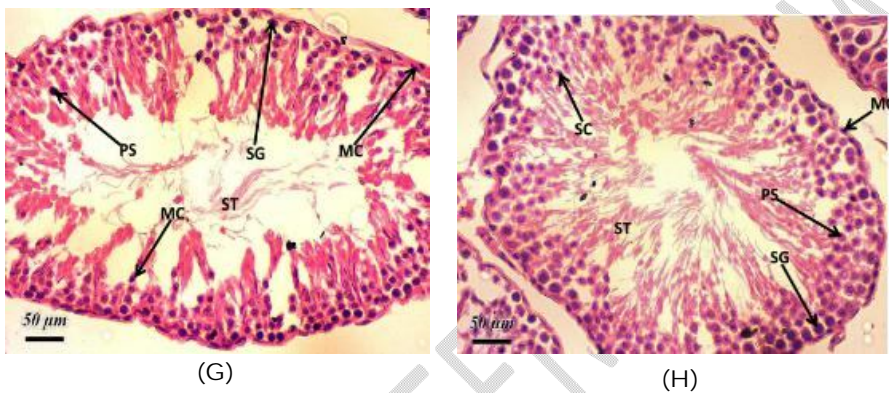
The photomicrograph(C and D) shows normal testicular architecture in both doses with seminiferous tubules surrounded by tunica albuginea with normal Sertoli cells and spermatocytes. Myoid cells and spermatogonia are also interspersed at the periphery of the tubule.



MC – myoid cell, PS – primary spermatocyte, SG – spermatogonia, SC – Sertoli cells, ST - spermatids

Figure 3: Photomicrograph of a testicular section evaluating the effect of NAC (100mg/kg) + BLCO(E) and NAC (200mg/kg) + BLCO(F) co-administration in rats stained with Haematoxylin and Eosin (H&E) x100 magnification.

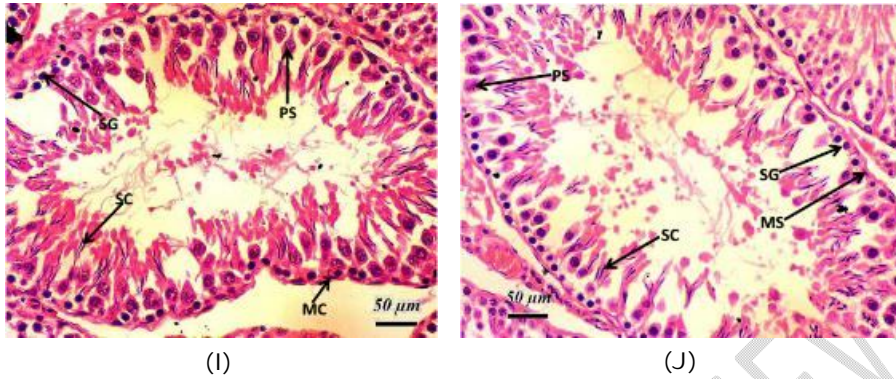
Slides E and F show poor testicular architecture with some normal seminiferous tubules. Seminiferous tubules with maturation arrest exhibiting widened lumen and interstitial space with normal Leydig cells are also seen. This is suggestive of the regenerative histoarchitecture feature of the testis which is more pronounced at NAC (200mg/kg).



MC – myoid cell, PS – primary spermatocyte, SG – spermatogonia, SC – Sertoli cells, ST - spermatids

Figure 4: Photomicrograph of a testicular section evaluating the effect of ZnSO₄ (0.5mg/kg)(G) and ZnSO₄ (1mg/kg)(H) co-administration, stained with Haematoxylin and Eosin (H&E) x100 magnification.

Section of the testes shows normal architecture with normal seminiferous tubules interspersed with Sertoli cells and spermatocytes which appear normal. The testes section suggests normal histoarchitecture displaying regenerative features (G) and complete regenerative property of testicular features (H).



MC – myoid cell, PS – primary spermatocyte, SG – spermatogonia, SC – Sertoli cells, ST - spermatids

Figure 5: Photomicrograph of a testicular section evaluating the effect of ZnSO₄ (0.5mg/kg) + BLCO(I) and ZnSO₄ (1mg/kg) + BLCO(J) co-administration in rats stained with Haematoxylin and Eosin (H&E) x100 magnification.

The testicular section displays poor testicular architecture with atrophic and degenerated seminiferous tubules and sloughed germinal cells. The interstitial spaces show normal Leydig cells with centrally placed spermatids which are scanty displaying regenerative properties in dose dose-dependent manner.

DISCUSSION

Crude oil toxicity is prevalent in the Nigeria's Niger Delta Region. These toxicities are known to arise through the generation of reactive oxygen species (ROS), leading to oxidative stress and, ultimately, tissue damage due to exposure to polycyclic aromatic hydrocarbons (PAHs) and volatile organic compounds (VOCs). Natural and synthetic antioxidants used as prophylactic or therapeutic measures have shown promise in the mitigation of the effects of oxidative stress [31, 32]. This present study assessed the potential protective effects of N-acetyl cysteine and Zinc Sulfate in mitigating distorted testicular cytoarchitecture and oxidative stress in male Wistar rats following short-term exposure to Bonny light crude oil (BLCO).

Our findings indicate that BLCO significantly increased malondialdehyde (MDA) levels while decreasing antioxidant enzymes such as superoxide dismutase (SOD), catalase (CAT), glutathione (GSH), and total antioxidant capacity (TAC) compared to the control group. This suggests that BLCO may have generated reactive oxygen species (ROS) in the testes of exposed rats, leading to lipid peroxidation and increased MDA levels, a by-product of this process. Consequently, this could result in Sertoli cell death in the testes, negatively affecting spermatogenesis and male fertility [33]. The findings of the current study are consistent with earlier research. The testicular disruptions caused by BLCO exposure correspond with previous

Comment [120]: In the table you are mentioned the level of GSH has been increase not decrease.

studies showing that the antioxidant systems in the testes and epididymal sperm of rats were impacted, evidenced by decreased levels of superoxide dismutase (SOD) and catalase (CAT), along with significantly increased levels of glutathione (GSH) and malondialdehyde (MDA) [29]. We also observed that NAC co-administration with BLCO significantly increased SOD, CAT, and TAC and decreased GSH levels in experimental animals when compared with BLCO as a result of its antioxidant activity. Antioxidants act by scavenging free radicals in the human system [34]. GSH is synthesized in the cytoplasm of the liver and thereafter distributed to other organs [35]. It is a non-enzymatic antioxidant known for ROS detoxification [36, 37] with studies showing that in light of exposure to different stressors causes markedly compromised defence mechanisms of GSH-related antioxidants, thus compromising GSH homeostasis [30, 38, 39]. Also, the observed increase in GSH level suggests stimulation of the antioxidant system in defence against the effect of stress, whereas, depletion of GSH level is an indication of tissue oxidative stress [40] which corroborates the results of increased GSH level following NAC co-administration from the present study. NAC has also been shown to reduce oxidative damage in sodium arsenide and tetracycline-induced oxidative stress [41, 42].

Comment [121]: The level of the CAT in the group that treated with NAC (100 mg/kg)+BLCO (600 mg/kg) has been decline not increase as mentioned in the table.

Our data reveal that experimental animals treated with ZnSO₄ and BLCO had significantly higher levels of SOD, CAT, and TAC compared to those given only BLCO. Zinc Sulfate acts as an antioxidant through several mechanisms: it competes with iron and copper for binding to cell membranes, protects biomolecules from oxidation, enhances antioxidant enzyme activity, reduces oxidant-promoting enzyme activity, and promotes the expression of metallothionein, which scavenges hydroxyl radicals [43, 44]. Zinc has also been demonstrated to reduce oxidative stress due to cadmium treatment as manifested by a decrease in blood hydroperoxide and testicular MDA, a good indicator of oxidative stress [45]. Decreased total antioxidant capacity (TAC) as observed in the BLCO-exposed rats could have a significant role in the aetiology of impaired sperm functions [46] as lower TAC in fructose-induced diabetic rats reduced sperm count, percentage motility and activity, suggesting that reduced antioxidant power was a major factor responsible for the impaired sperm quality, which could lead to infertility [47].

Histological analysis of the testes from rats exposed to BLCO revealed notable alterations in testicular morphology, including interstitial exudates, necrosis of spermatogenic interstitial (Leydig) cells, and degeneration. The current study similarly demonstrates that BLCO significantly disrupts testicular histology compared to the control group (Figure 1A & B). These findings suggest that BLCO exposure may contribute to infertility by altering testicular and sperm function, primarily through mechanisms such as oxidative stress and lipid peroxidation. These processes can lead to inflammation in the seminal fluid and trigger an immunological response, potentially resulting in the formation of antisperm antibodies (ASAs). Elevated levels of ASA can damage the sperm sheath, exhibiting cytotoxic effects on spermatozoa, causing seminal agglutination that immobilizes sperm cells, or even leading to sperm cell death [48, 49]. Our present finding is consistent with Orisakwe *et al.*, [50] where BLCO was found to have

Comment [122]: Fig. 1 (A & B)

negatively impacted testicular histopathology in a dose-dependent manner. They observed that the severity of the damage was dependent on the amount of BLCO with the connective tissues, seminiferous tubules, spermatogonia, and spermatids were either completely absent, mildly, severely, or grossly injured, or the sperm cells were coagulated and necrotic. They also observed that the basement membrane was disorganized, with some tubules empty of cells in the 400 and 800mg/kg BLCO exposed group while spermatocyte necrosis was observed in the 800mg/kg BLCO exposed group.

The control and NAC-supplemented groups displayed densely packed Leydig cells within the seminiferous tubules, along with normal spermatozoa development at all stages, maintaining typical testicular architecture (Figure 2C & 2D). The current study also shows that NAC was given alongside BLCO significantly improved the testes architecture (Figure 3E&3F). Two potential mechanisms may explain NAC's protective effect on testicular tissue: first, NAC acts as a free radical scavenger in response to oxidative stress, and second, it prevents the depletion of GSH[51, 52]. Similar reports have demonstrated the ability of NAC to improve testicular architecture busulfan-induced testicular dysfunction[53]. Similar to NAC, the present study also observed that ZnSO₄ caused noticeable improvement in the pathohistological structure of the testes in BLCO-exposed Wistar rats (Figure 5I&5J). Zinc sulfate supplementation may have influenced testicular anatomy and function by preventing testicular damage caused by free radicals caused by BLCO exposure by binding directly to protein sulfhydryl groups, thereby inhibiting oxidation[54, 55]. The current findings align with previous reports showing that ZnSO₄ supplementation alleviated disruptions in spermatogenesis caused by cisplatin (CP)-induced testicular dysfunction. This included improvements in the degeneration of seminiferous tubules, severe perivascular fibrosis, disorganization and hyalinization of intertubular connective tissue, reduced tunica albuginea thickness and tubular diameter, increased interstitial space, and sloughing of the germinal epithelium[56].

CONCLUSION

This study demonstrates that BLCO-exposed rats experienced toxicity affecting both testicular antioxidants and testicular structure, which could contribute to male infertility by impairing testicular function. It also highlights potential risks to the reproductive health of animals and humans exposed to this environmental pollutant, particularly in regions prone to oil spills. Our findings suggest that NAC and ZnSO₄ improved testicular function in rats, including spermatogenesis and steroidogenesis, by reducing testicular reactive oxygen species, thus enhancing antioxidant levels in BLCO-induced gonadal toxicity. NAC and ZnSO₄ also protected the testicular cytoarchitecture from the damaging effects of BLCO exposure.

REFERENCES

1. Ochiogu IS, Igwebuike UM, Mbegbu EC, Nnamani PF. Effects of Vitamin E Supplementation in Male Rats with Crude Oil-Induced Reproductive Toxicity. *Notulae Scientia Biologicae*. 2017;9(3):332-7.

Comment [123]: Fig. 2 (C & D)

Comment [124]: Based on the obtained results, what is the best compound or supplement that was applied to the treated groups and give the best result?

It is better to mention that in the conclusion

2. Terek O, Laphyna O, Velychko O, Bunyo L, Dovgaiuk-Semenuk M. Crude oil contamination and plants. *Journal of Central European Green Innovation*. 2015;3(3):175-84.
3. Raji Y, Hart VO. Influence of prolonged exposure to Nigerian Bonny light crude oil on fertility indices in rats. *Nigerian Journal of Physiological Sciences*. 2012;27(1):55-63.
4. Daubry TME, Adienbo OM, Ovili-Odili BZ, Chinko BC. Ameliorative Effects of N-Acetyl Cysteine and Zinc Sulfate on Reproductive Dysfunction Induced by Short-Term Crude Oil Exposure in Male Wistar Rats. *Asian Journal of Medicine and Health*. 2024;22(10).
5. Orisakwe OE, Akumka DD, Afonne OJ, Gamaniel KS. Investigation into the pharmacological basis for some of the folkloric uses of Bonny light crude oil in Nigeria. *Indian Journal of Pharmacology*. 2000;32(3):231-4.
6. Robinson PR, Hsu CS. Introduction to petroleum technology. *Springer handbook of petroleum technology*. 2017:1-83.
7. Sherman IW, Sherman VG. *Biology: A human approach*. (No Title). 1975.
8. Owu DU, Udoete UB, Azah N, Eyong EU. Effect of bonny light crude oil on some haematological parameters of guinea pigs. *Biokemistri*. 2005;17(2):165-70.
9. Orisakwe OE, Akumka DD, Njan AA, Afonne OJ, Okechi OO. Hepatotoxic and haematological effects of Nigerian Bonny light crude oil in male albino rats. *Toxicological & Environmental Chemistry*. 2005;87(2):215-21.
10. Saulsbury MD, Heyliger SO, Wang K, Johnson DJ. Chlorpyrifos induces oxidative stress in oligodendrocyte progenitor cells. *Toxicology*. 2009;259(1-2):1-9.
11. Zahra KF, Lefter R, Ali A, Abdellah E-C, Trus C, Ciobica A, Timofte D. The Involvement of the Oxidative Stress Status in Cancer Pathology: A Double View on the Role of the Antioxidants. *Oxidative Medicine and Cellular Longevity*. 2021;2021.
12. Bano A, Gupta A, Rai S, Fatima T, Sharma S, Pathak N. Mechanistic Role of Reactive Oxygen Species and Its Regulation Via the Antioxidant System under Environmental Stress. 2021.
13. Chinko BC, Umeh OU. Alterations in lipid profile and oxidative stress markers following heat stress on wistar rats: Ameliorating role of vitamin C. *Biomedical Sciences*. 2023;9(1):12-7.
14. Dasuri K, Zhang L, Keller JN. Oxidative stress, neurodegeneration, and the balance of protein degradation and protein synthesis. *Free Radical Biology and Medicine*. 2013;62:170-85.
15. Wolff SP, Garner A, Dean RT. Free radicals, lipids and protein degradation. *Trends in biochemical sciences*. 1986;11(1):27-31.
16. Dos Santos DM, Rocha CVJ, da Silveira EF, Marinho MAG, Rodrigues MR, Silva NO, et al. In vitro anti/pro-oxidant activities of *R. ferruginea* extract and its effect on glioma cell viability: correlation with phenolic compound content and effects on membrane dynamics. *The Journal of Membrane Biology*. 2018;251:247-61.

Comment [125]: This reference is duplicate with the reference No. 19.

17. Gulcin İ. Antioxidants And Antioxidant Methods: An Updated Overview. *Archives of Toxicology*. 2020;94(3):651-715.
18. Neha K, Haider MR, Pathak A, Yar MS. Medicinal Prospects Of Antioxidants: A Review. *European Journal Of Medicinal Chemistry*. 2019;178:687-704.
19. Bano A, Gupta A, Rai S, Fatima T, Sharma S, Pathak N. Mechanistic Role of Reactive Oxygen Species and Its Regulation Via the Antioxidant System under Environmental Stress. In: Hasanuzzaman M, Nahar MK, eds. *Plant Stress Physiology - Perspectives in Agriculture*: IntechOpen. <https://doi.org/10.5772/intechopen.101045>; 2021.
20. Awajiomowa J, Chinko BC, Green KI. Haematological Parameters and Oxidative Stress Changes in Apparently Healthy Pregnant Women in Bori, Nigeria. *International Journal of Research and Reports in Hematology*. 2022;5(4):30-9.
21. Moschou M, Kosmidis EK, Kaloyianni M, Geronikaki A, Dabarakis N, Theophilidis G. In vitro assessment of the neurotoxic and neuroprotective effects of N-acetyl-L-cysteine (NAC) on the rat sciatic nerve fibers. *Toxicology in vitro*. 2008;22(1):267-74.
22. Atkuri KR, Mantovani JJ, Herzenberg LA, Herzenberg LA. N-Acetylcysteine—a safe antidote for cysteine/glutathione deficiency. *Current opinion in pharmacology*. 2007;7(4):355-9.
23. Sadowska AM, Manuel-Y-Keenoy B, De Backer W. Antioxidant and anti-inflammatory efficacy of NAC in the treatment of COPD: discordant in vitro and in vivo dose-effects: a review. *Pulmonary pharmacology & therapeutics*. 2007;20(1):9-22.
24. Liaquat M, Ali I, Ahmad S, Malik AM, Ashraf HMQ, Parveen N, et al. Efficiency of exogenous zinc sulfate application reduced fruit drop and improved antioxidant activity of 'Kinnow' mandarin fruit. *Brazilian Journal of Biology*. 2021;83:e244593.
25. Powell SR. The antioxidant properties of zinc. *The Journal of nutrition*. 2000;130(5):1447S-54S.
26. Al-Hamdany MZ, Al-Hubaity AY. Protective Effects of N-acetylcysteine against 5-Fluorouracil-Induced Pulmonary Toxicity in Albino Rats. *Iraqi journal of medical sciences*. 2014;12(2).
27. Al-Ani NK, Al-Kawaz U, Saeed BT. Protective influence of zinc on reproductive parameters in male rat treated with cadmium. *American Journal of Medicine and Medical Sciences*. 2015;5(2):73-81.
28. Chinko BC, Precious-Abraham AD. Wound healing activity of hydromethanolic *Dioscorea bulbifera* extract on male wistar rat excision wound models. *Pharmacological Research-Modern Chinese Medicine*. 2024;11:100425.
29. Farombi EO, Adedara IA, Ebokaiwe AP, Teberen R, Ehwerhemuepha T. Nigerian Bonny light crude oil disrupts antioxidant systems in testes and sperm of rats. *Archives of environmental contamination and toxicology*. 2010;59:166-74.
30. Chukwuebuka NB, Elias DTM, Ijeko AE, Peggy OE, Ejime A-C, Omeru O. Changes in antioxidant enzymes activities and lipid peroxidase level in tissues of stress-induced rats. *Biomedical and Pharmacology Journal*. 2021;14(2):583-96.

31. Firuzi O, Miri R, Tavakkoli M, Saso L. Antioxidant therapy: current status and future prospects. *Current medicinal chemistry*. 2011;18(25):3871-88.
32. Modi M, Kaul RK, Kannan GM, Flora SJ. Co-administration of zinc and n-acetylcysteine prevents arsenic-induced tissue oxidative stress in male rats. *Journal of Trace Elements in Medicine and Biology*. 2006;20(3):197-204.
33. Cavalli VLdLO, Cattani D, Rieg CEH, Pierozan P, Zanatta L, Parisotto EB, et al. Roundup disrupts male reproductive functions by triggering calcium-mediated cell death in rat testis and Sertoli cells. *Free Radical Biology and Medicine*. 2013;65:335-46.
34. Tremellen K. Oxidative stress and male infertility—a clinical perspective. *Human reproduction update*. 2008;14(3):243-58.
35. Jafari M, Salehi M, Ahmadi S, Asgari A, Abasnezhad M, Hajigholamali M. The role of oxidative stress in diazinon-induced tissues toxicity in Wistar and Norway rats. *Toxicology mechanisms and methods*. 2012;22(8):638-47.
36. Şahin E, Gümüşlü S. Alterations in brain antioxidant status, protein oxidation and lipid peroxidation in response to different stress models. *Behavioural brain research*. 2004;155(2):241-8.
37. Chakraborti A, Gulati K, Ray A. Age related differences in stress-induced neurobehavioral responses in rats: modulation by antioxidants and nitrenergic agents. *Behavioural brain research*. 2008;194(1):86-91.
38. Kayhan FE. Biochemical evidence of free radical-induced lipid peroxidation for chronic toxicity of endosulfan and malathion in liver, kidney and gonadal tissues of wistar albino rats. *Fresenius Environ Bull*. 2008;17:1340-3.
39. Lobo V, Patil A, Phatak A, Chandra N. Free radicals, antioxidants and functional foods: Impact on human health. *Pharmacognosy reviews*. 2010;4(8):118.
40. Samson J, Sheeladevi R, Ravindran R. Oxidative stress in brain and antioxidant activity of *Ocimum sanctum* in noise exposure. *Neurotoxicology*. 2007;28(3):679-85.
41. Reddy PS, Rani GP, Sainath SB, Meena R, Supriya CH. Protective effects of N-acetylcysteine against arsenic-induced oxidative stress and reprotoxicity in male mice. *Journal of Trace Elements in Medicine and Biology*. 2011;25(4):247-53.
42. Farombi EO, Ugwuezunmba MC, Ezenwadu TT, Oyeyemi MO, Ekor M. Tetracycline-induced reproductive toxicity in male rats: effects of vitamin C and N-acetylcysteine. *Experimental and Toxicologic Pathology*. 2008;60(1):77-85.
43. Bao B, Ahmad A, Azmi A, Li Y, Prasad A, Sarkar FH. The biological significance of zinc in inflammation and aging. *Inflammation, advancing age and nutrition: Elsevier*; 2014:15-27.
44. Rostan EF, DeBuys HV, Madey DL, Pinnell SR. Evidence supporting zinc as an important antioxidant for skin. *International journal of dermatology*. 2002;41(9):606-11.
45. Saygili EI, Konukoglu D, Papila C, Akcay T. Levels of plasma vitamin E, vitamin C, TBARS, and cholesterol in male patients with colorectal tumors. *Biochemistry (Moscow)*. 2003;68:325-8.

46. Pahune PP, Choudhari AR, Muley PA. The total antioxidant power of semen and its correlation with the fertility potential of human male subjects. *Journal of clinical and diagnostic research: JCDR*. 2013;7(6):991.
47. Bassey IE, Ikpi DE, Isong IKP, Akpan UO, Onyeukwu CC, Nwankwo NP, Udofia IG. Effect of combined calcium, magnesium, vitamin C and E supplementation on seminal parameters and serum oxidative stress markers in fructose-induced diabetic Wistar rats. *Archives of Physiology and Biochemistry*. 2022;128(3):643-50.
48. Ita SO, Effiong FE, Udokang NE, Uzoma JC, Etim EE, Francis UE. Mitigating Toxic Effects of Nigerian Bonnylight Crude Oil on Sperm Motility and Morphology of Wistar Rats with Ethanol Leaves Extract of *Ageratum Conyzoides* Supplementation. *Biomedical Journal of Scientific & Technical Research*. 2020;29(1):22156-65.
49. Obidike IR, Maduabuchi IU, Olumuyiwa SS. Testicular morphology and cauda epididymal sperm reserves of male rats exposed to Nigerian Qua Iboe Brent crude oil. *Journal of Veterinary Science*. 2007;8(1):1-5.
50. Orisakwe OE, Akumka DD, Njan AA, Afonne OJ. Testicular toxicity of Nigerian bonny light crude oil in male albino rats. *Reproductive Toxicology*. 2004;18(3):439-42.
51. Wang A-L, Wang J-P, Wang H, Chen Y-H, Zhao L, Wang L-S, et al. A dual effect of N-acetylcysteine on acute ethanol-induced liver damage in mice. *Hepatology research*. 2006;34(3):199-206.
52. Arfsten DP, Johnson EW, Thitoff AR, Jung AE, Wilfong ER, Lohrke SM, et al. Impact of 30-day oral dosing with N-acetyl-L-cysteine on Sprague-Dawley rat physiology. *International journal of toxicology*. 2004;23(4):239-47.
53. Kim KH, Park MJ, Park NC, Park HJ. Effect of N-acetyl-L-cysteine on Testicular Tissue in Busulfan-Induced Dysfunction in the Male Reproductive System. *The World Journal of Men's Health*. 2023;41(4):882.
54. Tahmaz L, Gökalp A, Kibar Y, Kocak I, Yalçın O, Özeran Y. Effect of hypothyroidism on the testes in mature rats and treatment with levothyroxine and zinc. *Andrologia*. 2000;32(2):85-9.
55. Rossman TG, Goncharova EI. Spontaneous mutagenesis in mammalian cells is caused mainly by oxidative events and can be blocked by antioxidants and metallothionein. *Mutation Research/Fundamental and Molecular Mechanisms of Mutagenesis*. 1998;402(1-2):103-10.
56. Adelakun SA, Ogunlade B, Fidelis OP, Omotoso OD. Protective effect of nutritional supplementation of zinc-sulfate against cisplatin-induced spermatogonial and testicular dysfunctions in adult male Sprague-Dawley rats. *Endocrine and Metabolic Science*. 2022;6:100116.