

Evaluation of Immunohistochemical Expression of IDH, ATRX and Ki-67 in the Diagnosis and Classification of CNS Gliomas

Abstract:

Background: WHO blue book has emphasized on incorporating histopathological as well as molecular basis for accurately diagnosing and risk stratifying cases of brain gliomas. Using surrogate immunohistochemistry may substitute molecular testing especially in low-income countries. **Aim:** this retrospective cohort study was carried out at the Pathology department, Tanta university to evaluate the immunohistochemical expression of IDH, ATRX and KI-67 in diagnosis and classification of brain gliomas. **Materials and methods:** Two hundred and fifty (250) formalin-fixed paraffin-embedded tissue blocks from cases with CNS tumors were evaluated for immunohistochemical expression using IDH, ATRX and KI-67. **Results:** In cases of diffuse gliomas; tumor types showed significant difference as regard age of patients ($p < 0.001$), as well as IDH1 and ATRX immunohistochemical expression ($p < 0.001$). The proliferation index of Ki-67 also showed significant difference amongst groups ($p < 0.001$). One hundred and ninety-six cases of diffuse gliomas were classified following immunohistochemical staining into 89 IDH-mutant tumors (45.4%) and 107 IDH-wild type tumors (Glioblastomas) (54.6%). Eighty-nine cases of IDH-mutant gliomas were further sub classified based on cell of origin and WHO grade into astrocytomas; grades 2, 3 and 4, as well as oligodendrogliomas; grades 2 and 3. In cases of localized gliomas; No significant data were detected as regard age of affected patients, or tumor location. All cases showed negative staining for IDH1 and retained nuclear expression for ATRX. The proliferation index showed variance amongst tumors ($p < 0.001$). A comparison group of patients with reactive gliosis was also studied and showed negative staining for IDH1, retained ATRX expression with low Ki-67 proliferation index. **Conclusions:** IDH, ATRX and Ki-67 may be beneficial in categorizing and properly diagnosing patients with brain tumors; which may serve not only as a surrogate for molecular testing, but also can guide therapeutic decisions.

Key words: gliomas, isocitrate dehydrogenase (IDH), Alpha thalassemia/mental retardation syndrome X-linked (ATRX), KI-67, diagnosis

1. Introduction

The diagnosis of gliomas has entirely relied on their histologic appearance with regard to potential cell of origin and degree of differentiation taking into consideration nuclear atypia, mitotic activity, vascular proliferation, necrosis, proliferative potential, and clinical

course, as well as treatment outcome [1]. However, this approach showed significant interobserver variability and lacked precision in determining appropriate prognosis even for patients with the same diagnosis [2]. For the first time, the 2016 revised edition of World Health Organization (WHO) classification of brain tumors used molecular parameters in addition to traditional histology to achieve the so called “layered diagnosis” to diagnose central nervous system (CNS) tumors, resulting in major classification restructuring. Accordingly, nomenclature for selected entities now includes both histopathological diagnosis and defining molecular features [3]. Unfortunately, widespread availability of molecular testing is yet a dream to be achieved, which has led to the quest for alternative means to incorporate molecular testing. The availability and feasibility of the immunohistochemical (IHC) techniques has encouraged finding surrogates for molecular testing, and of the most eminent agents in this prospect are isocitrate dehydrogenase (IDH) and alpha thalassemia/mental retardation syndrome X-linked (ATRX) [4].

The isocitrate dehydrogenase (IDH) family of enzymes catalyzes reactions in the Krebs cycle and in the cytoplasm. Somatic mutations in genes encoding the 2 isoforms of isocitrate dehydrogenase (IDH1 and IDH2) are present in a variety of tumors. In gliomas, *IDH* mutations were first reported in 2009. They are considered early and common events in the etiopathology of gliomas and are associated with increased DNA methylation [5].

Alpha thalassemia/mental retardation syndrome X-linked (ATRX) is a member of the Switch/Sucrose Non-Fermentable (SWI2/SNF2) family of Deoxy ribonucleic acid (DNA) helicases that plays a role in chromatin modulation and maintenance of telomeres. Somatic ATRX mutations were first detected in pancreatic neuroendocrine tumors followed by pediatric glioblastomas in 2011 [6].

The present study aimed to study the immunohistochemical expression of IDH, ATRX and KI-67 in available glioma subtypes with assessment of their diagnostic significance; and to evaluate the potential role of such markers in the classification of gliomas.

2. Materials and methods

2.1. Patient cohort and tissue processing: 250 formalin-fixed paraffin-embedded tissue blocks from cases with brain tumors were retrieved during the period from January 2019 through December 2021. Approval from research ethics committee was taken antecedent to conduction of study (code 32288/04/18). Clinical data were obtained from requisition sheets enclosed with the specimens or from the final pathology reports including age and sex in addition to location of the tumor. Each paraffin block was re-cut by rotatory microtome at 4-5 microns' thickness, then mounted on glass slides and stained by hematoxylin and eosin for routine histopathological examination; or mounted on charged slides for immunostaining. The routine histopathological examination included assessment of the morphologic appearance of the tumor to identify the histological type and diagnosis as well as determining grade (G) of the lesion. Immunohistochemical staining was carried out using anti IDH (Mouse Monoclonal Primary Antibody clone R132H 132, GenomeMe, BC, CA), ATRX (Mouse Monoclonal Primary Antibody Clone D-5, Santa Cruz biotechnology, Tx, United States of America 'USA') and Ki-67 (Rabbit Monoclonal Primary Antibody Clone 30-9, Ventana, Roche, Az, USA) antibodies. Immunohistochemical staining was performed in an automated staining instrument (Ventana, BenchMark ULTRA). The antibody was detected using a VentanaultraView Universal (diaminobenzidine) DAB Detection Kit, and hematoxylin was used as counterstain.

2.2. Interpretation of immunohistochemistry staining results: IDH positivity was detected as nuclear and cytoplasmic staining [7]. Cases with $\geq 10\%$ overall positive tumor cells were rated as positive for IDH1 R132H mutation, while cases with less than 10% overall positive tumor cells were rated as negative for such mutation [8]. On the other contrary, positivity for ATRX antibody indicated absence of gene mutation; and detected as strong nuclear staining [9], a threshold of at least 10% of strong positive tumor nuclei was used to assign immunopositivity for ATRX [10]. This negative staining was considered specific if tumor cell nuclei were unstained while nuclei of non-neoplastic cells such as endothelia, microglia, lymphocytes and reactive astrocytes were strongly positive, which were served as internal positive control [11]. The Ki-67

index was calculated as the average percentage of positive nuclei out of the total number of nuclei in high power microscopic fields at 400x magnification [12].

2.3. Statistical analysis: was done using SPSS v27 (IBM©, Chicago, IL, USA). The Shapiro-Wilk test was used to evaluate normality of the distribution of data. Quantitative non-parametric data were presented as range and median and were analyzed by Kruskal-Wallis's test. Qualitative variables were presented as frequency and percentage (%) and were analyzed utilizing the Chi-square test. A two tailed P value < 0.05 was considered statistically significant.

3. Results

3.1. The study included 250 cases divided into 3 main groups: diffuse gliomas representing 78.4 % (196 cases), localized gliomas representing 19.6% (49 cases) and reactive gliosis representing 2% (5 cases).

3.2. Group A: Diffuse gliomas (Figure 1):

Tumors groups and patient demographics: represented in table (1) and Immunohistochemistry results: represented in table (2).

Table (1): Clinical data of the diffuse glioma group

Tumor type and grade	Number and percentage of cases	Age (median and range)	Tumor location
Astrocytoma G2	33 (16.8%)	33 (range 19-72 years)	Frontal 70% Temporal 11% Parietal 7% Posterior fossa 7% Corpus callosum 4%
Astrocytoma G3	30 (15.3%)	41 (range 18-65 years)	Frontal 58% Parietal 16% Temporal 11% Occipital 5% Insular 5% Brain stem 5%
Astrocytoma G4	7 (3.6%)	31 (range 17-61)	Frontal 100%
Oligodendroglioma G2	8 (4.1%)	36 (range 31-42 years)	Frontal 71% Temporal 14% Occipital 14%
Oligodendroglioma G3	11 (5.6%)	42 (range 22-72 years)	Frontal 80% Temporal 20%

Glioblastoma G4	107 (54.6%)	58 (range 11-87)	Frontal 27% Parietal 20% Temporal 18% Spinal 3% Occipital 2% Cerebellar 2% Pons 1% Ventricular 1% N/A 26%
P value	N/A	p<0.001	p=0.39

Table (2): IHC results in the diffuse glioma group

Tumor type and grade	IDH1	ATRX	Ki-67 (Median)
Astrocytoma G2	Positive 100%	Negative 100%	2% (1%-4%)
Astrocytoma G3	Positive 100%	Negative 90%	7% (5%-40%)
Astrocytoma G4	Positive 100%	Negative 100%	10% (5-15%)
Oligodendroglioma G2	Positive 100%	Positive 100%	3% (2%-4%)
Oligodendroglioma G3	Positive 100%	Positive 100%	15% (10%-20%)
Glioblastoma G4	Negative 100%	Positive 98.1%	15% (10%-60%)
P value	p<0.001	p<0.001	p<0.001

Summary of diffuse gliomas:

- Different tumor types showed significant difference as regard to age of affected patients ($p<0.001$), as well as difference in IDH1 and ATRX immunohistochemical expression ($p<0.001$).
- The proliferation index of Ki-67 also showed significant difference amongst groups ($p<0.001$).
- One hundred and ninety-six cases of diffuse gliomas were classified following immunohistochemical staining into 89 *IDH*-mutant tumors (45.4%) and 107 *IDH*-wild type tumors (Glioblastomas) (54.6%).
- Eighty-nine cases of *IDH*-mutant gliomas were further subclassified based on cell of origin and grade into astrocytomas, grades 2, 3 and 4, as well as oligodendrogliomas grades 2 and 3.

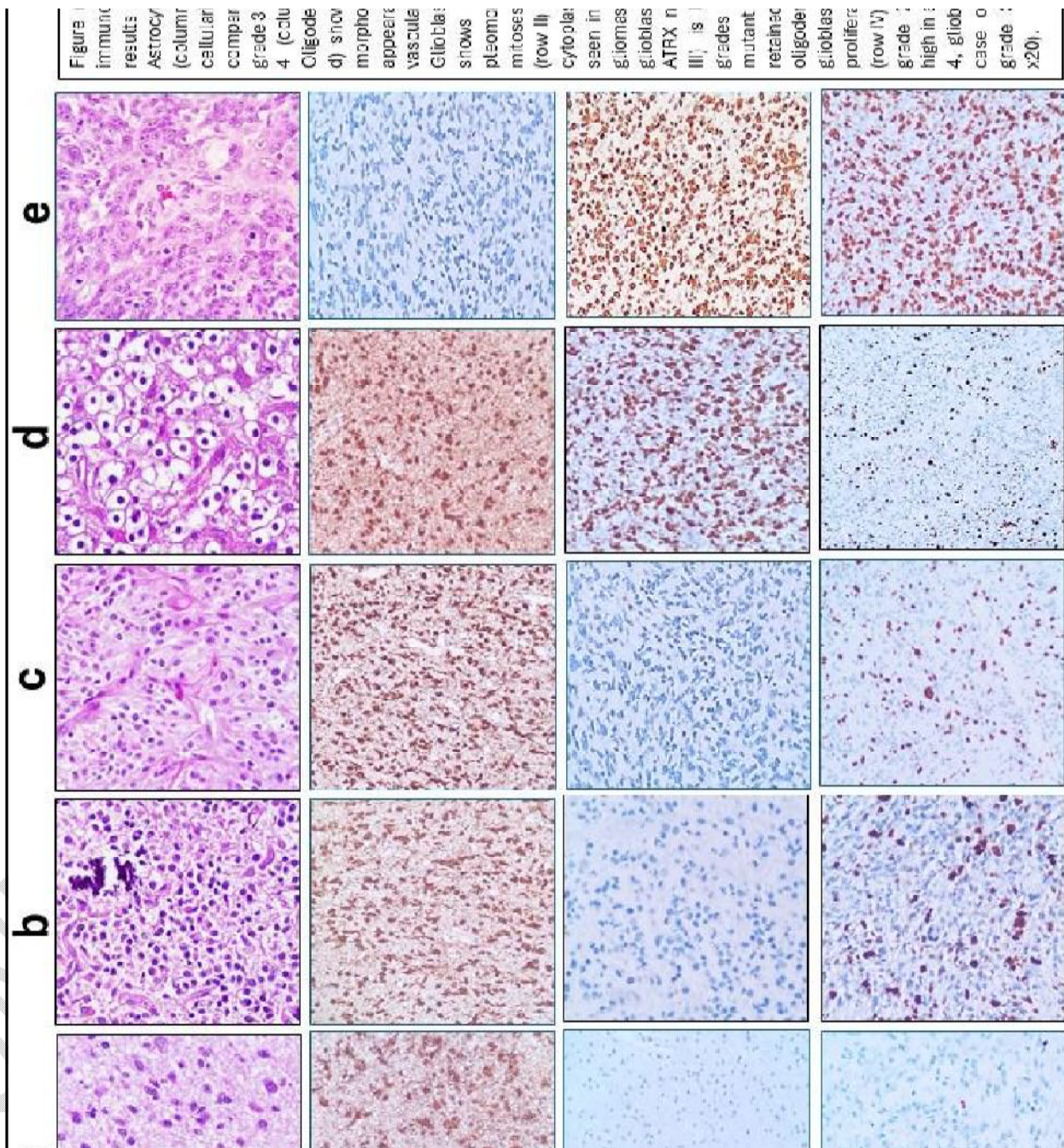


Figure 1
 Immunohistochemistry results: Astrocytoma (columnar cellular comparison grade 3-4) (cellular morphology appearance vasculature). Glioblastoma shows pleomorphic mitoses (row II) cytoplasmic inclusions seen in gliomas. Glioblastoma ATRX is negative (row III) is negative grades mutant retained oligodendrocyte glioblastoma proliferative (row IV) grade high in glioblastoma case 0 grade x20).

3.3. Group B: Localized gliomas (Figure 2):

Tumors groups and patient demographics: represented in table (3), and Immunohistochemistry results: represented in table (4)

Table (3): Clinical data of the localized glioma group

Tumor type and grade	Number and percentage of cases	Age (median)	Tumor location
Pilocytic Astrocytoma G1	10 (20.4%)	7.5 (range 3 to 29 years)	Posterior fossa 50% Ventricular 20% Frontal 10% Midbrain 10% Spinal 10%
Pleomorphic xanthoastrocytoma G2	5 (10.2%)	10 (range 9-27 years)	Temporal 60% Frontal 20% Parietal 20%
Pleomorphic xanthoastrocytoma G3	4 (8.2%)	36.5 (range 28-60 years)	Temporal 75% Parietal 25%
Subependymal giant cell astrocytoma G1	2 (4.1%)	15.5 (range 7-14 years)	Lateral ventricle 100%
Subependymoma G2	3 (6.1%)	34 (range 33-35)	Fourth ventricle 100%
Ependymoma G 2	10 (20.4%)	30.5 (range 3 to 65 years)	Posterior fossa 55.8% Cervical 22.2% Lumbar 11.1% Temporal 11.1%
Ependymoma G 3	11 (22.4%)	31 (range 2 to 64)	Posterior fossa 40% Parietal 20% Frontal 10% Temporal 10% Lumbar 10% Thoracic 10%
MyxopapillaryEpendymoma G 2	4 (8.2%)	35 (range 18-48 years)	Lumbosacral 100%
P value	N/A	p=0.54	p=0.08

Table (4): IHC results of the localized glioma group

Tumor type and grade	IDH	ATRX	Ki-67 (Median)
Pilocytic Astrocytoma G1	Negative 100%	Positive 100%	2% (1% to 5%)

Pleomorphic xanthoastrocytoma G2	Negative 100%	Positive 100%	2% (1%-3%)
Pleomorphic xanthoastrocytoma G3	Negative 100%	Positive 100%	15% (10%-30%)
Subependymal giant cell astrocytoma G1	Negative 100%	Positive 100%	2% (1-2%)
Subependymoma G2	Negative 100%	Positive 100%	1% (1-2%)
Ependymoma G 2	Negative 100%	Positive 100%	3% (2%-4%)
Ependymoma G 3	Negative 100%	Positive 100%	25% (10%-40%)
MyxopapillaryEpendymoma G 2	Negative 100%	Positive 100%	4% (3%-5%)
P value	N/A	N/A	p<0.001

Summary of localized gliomas:

- No significant data were detected as regard to age of affected patients, tumor location or immunohistochemical expression results of IDH and ATRX.
- The proliferation index of Ki-67 showed significant difference amongst different groups ($p<0.001$).

3.4. Group C: Reactive gliosis

Summary of patient demographics, location, underlying etiology and Immunohistochemistry results:

- The study included five cases of reactive gliosis accounting for 2% of the total cases; with median age was 43 years (range 6 to 60 years), and the occipital lobe was more commonly affected (40%).
- Gliosis occurred following infection with subsequent brain abscess formation in 3 cases (60%), while in the remaining 2 cases, reactive gliosis was secondary to infarction.
- All cases showed negative staining for IDH1 by IHC, ATRX staining showed retained nuclear expression, while the proliferation index of Ki-67 was low (ranging from 1% to 3%) (Figure 2).

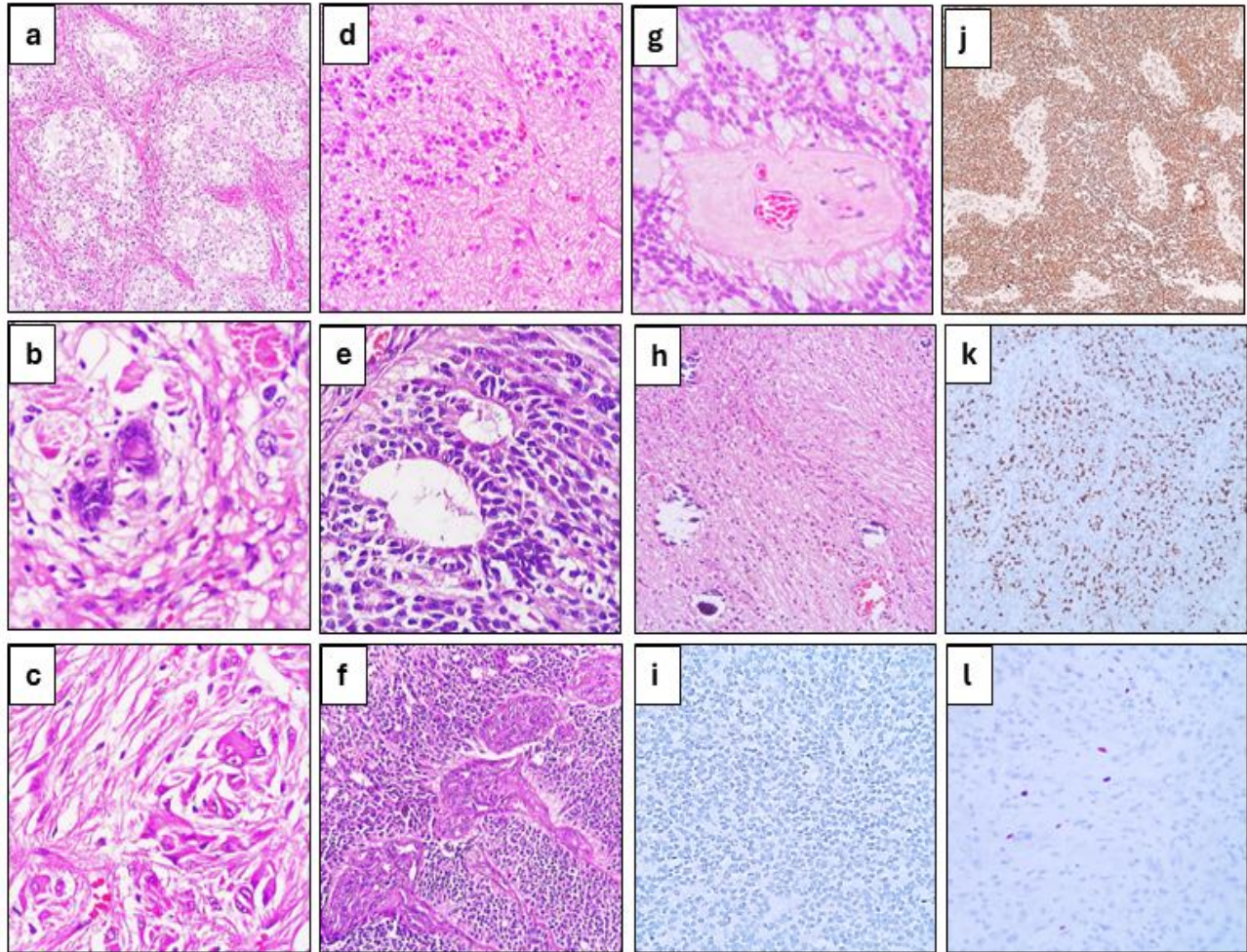


Figure (2): The morphologic spectrum and immunohistochemical expression observed in localized gliomas and reactive gliosis. Panel (a) pilocytic astrocytoma WHO grade 1 exhibiting the characteristic biphasic pattern with fibrillary and microcystic areas (H&E, x10). Panel (b) high power view from pleomorphic xanthoastrocytoma showing spindle cells and bizarre tumor cells with intranuclear inclusions (H&E, x40). Panel (c) a case of subependymal giant cell astrocytoma showing large and multinucleated tumor giant cells admixed with smaller spindle cells (H&E, x40). Panel (d) displaying a case of subependymoma with monotonous tumor cells arranged in lobulated pattern (H&E, x20). Panel (e) showing the characteristic true ependymal rosettes in which tumor cells are arranged around empty lumina in a case of ependymoma WHO grade 2 (H&E, x40). Panel (f) showing extensive microvascular proliferation in ependymoma, WHO grade 3 (H&E, x20). Panel (g) high power field in a case of myxopapillary ependymoma, WHO grade 2 showing the characteristic arrangement of tumor cells around blood vessels with hyaline and myxoid degeneration of vessel walls (H&E, x40). Panel (h) section from reactive gliosis showing bland astrocytic cells dispersed in fibrillary background (H&E, x10). Panel (i) as shown in this case of ependymoma, all cases of localized glioma and reactive gliosis showed negative expression of IDH1 by immunohistochemistry (IHC, x20). Panel (j) the previous case stained by ATRX showing retained nuclear expression, a staining pattern that was similar to all other cases of localized glioma and reactive gliosis (IHC, x10). Panel (k) showing high proliferation index of Ki-67 in the previous case, resembling the pattern observed in higher grade lesions in the localized glioma group (IHC, x10). Panel (l) a representative section for low Ki-67 expression, a pattern that was observed in low grade diffuse gliomas in addition to cases of reactive gliosis (IHC, x20).

4. Discussion:

The World Health Organization (WHO) classification of tumors of the CNS is the standard and universally used diagnostic system for the classification of brain tumors. It was originally built on the morphological appearance of tumor cells and their resemblance to normal brain cells, with a grading system based on the outcome of tumors [13]. Studies over the past two decades have clarified the genetic basis of

tumorigenesis that may contribute to an enhanced classification of these tumors [3]. In 2014, a meeting held in Haarlem (the Netherlands) under supervision of the International Society of Neuropathology, established guidelines for how to incorporate molecular findings into brain tumor diagnoses, setting the stage for the 2016 CNS WHO classification [14]. However, this approach is still not standardized given unavailability and/or cost constraints of molecular testing; therefore, an economical working formula is essential to reach a meaningful diagnosis especially in resource-limited settings [15]. In this context, the current study was carried out to evaluate IDH1, ATRX and Ki-67 immunohistochemical stains in the diagnosis and classification of gliomas and to determine the potential role of immunohistochemistry as a surrogate for molecular testing.

IDH1 (isocitrate dehydrogenase 1) gene mutations were first identified in a single case of colorectal cancer as part of an early investigation for protein-coding mutations in human cancers [16]. Later on, they were frequently detected in cancers of various origins, including acute myeloid leukemia, cholangiocarcinoma, chondrosarcoma and glioma [17].

In the present study, *IDH1* mutation was detected through surrogate immunohistochemical staining in all cases of diffuse astrocytoma, WHO grades 2 and 3, therefore these cases were assigned the diagnosis of *IDH*-mutant astrocytoma, and these findings match the results of many studies stating that up to 80% of World Health Organization (WHO) classified grade 2 and 3 gliomas harbor the *IDH* disease-defining clonal driver mutations [7, 18].

IDH1 immunohistochemical staining of grade 4 astrocytomas revealed positive staining in only 7 cases (representing 6.1%). These cases were assigned as per the new WHO classification the nomenclature of *IDH*-mutant Astrocytoma, WHO grade 4, whereas the former name “secondary glioblastoma or *IDH*-mutant glioblastoma” is no longer being used [19]. These patients had a median age of 31 years, and all cases showed frontal lobe affection, which is compatible with previous reports that found out that patients with the formerly named “secondary glioblastoma” are usually younger than patients with

primary glioblastoma, and that those tumors usually share a frontal lobe location similar to their precursors (astrocytomas, WHO grade 2 and grade 3) [20].

The majority of grade 4 astrocytoma cases (107/114 representing 93.9%) were negative for IDH1 by IHC thus exhibiting the IDH-wildtype phenotype, therefore were diagnosed as *IDH*-wildtype glioblastoma, WHO grade 4, and that corresponded to the general observation in prior literature that the majority glioblastomas (up to 90%) are *IDH*-wildtype tumors (primary glioblastoma) [21]. Similarly, all cases of glioblastoma subtypes (such as epithelioid glioblastoma and giant cell glioblastoma) were negative for *IDH1* mutation by immunohistochemistry which is consistent with previous reports documenting that histologic subtypes of glioblastoma are of *IDH*-wildtype genotype [22, 23].

According to **Louis et al.**, [14] in the WHO blue book, for practical reasons, it is sufficient to rely on the negativity of IDH1 testing by immunohistochemistry alone in older patients (above 54 years) with histologically classic glioblastoma provided that these patients have no history of a preexisting lower-grade glioma. They state that the designation of “*IDH*-wildtype” can therefore be safely applied in this setting, even in the absence of *IDH* gene sequencing. If we apply that concept to this study, absence of IDH1 staining by immunohistochemistry is sufficient to make the diagnosis of *IDH*-wildtype glioblastoma in 65.4% (70 cases of 107 glioblastoma cases) without the need for additional confirmation by molecular testing. The remaining cases (34.6%) would require confirmation of absence of *IDH* mutation and assessment of other mutations as well.

The incidence of IDH-positive diffuse gliomas in this study was 45.4% (89 cases of 196) emphasizing on the fact that *IDH* mutation evaluation in gliomas has become imperative to identify these tumors especially since secondary malignant transformation is almost inevitable in the many of WHO grade 2 or 3 astrocytomas necessitating close follow up of these patients [24]. Additionally, many of these tumors recur despite neurosurgical resection with adjuvant therapy leading to limited life expectancy of these patients. Therefore, it is of great significance to find new targets for diagnosis and treatment [25]. For all these reasons, *IDH* mutations have become one of the strongest prognostic

factors in gliomas and detection of *IDH* mutations can act as a useful predictive biomarker foreseeing chemosensitivity to alkylating chemotherapies [4]. Patients with *IDH*-mutant tumors can also benefit from any *IDH*-targeted treatment modalities such as small-molecule inhibitors, immunotherapy or vaccines that can prevent progression of lower grade tumors to more aggressive forms [26].

Regarding IDH status in oligodendrogliomas, all cases in this study whether grade 2 or 3 tumors showed positive staining for IDH1 indicating presence of *IDH* mutation and acquiring the nomenclature of *IDH*-mutant oligodendroglioma. Findings of this study matched the general agreement of many studies that up to 90% of oligodendrogliomas harbour *IDH* mutations [27]. This situation also highlights another diagnostic value of IDH evaluation; in conditions where the diagnosis of oligodendroglioma is suspected, negativity of IDH testing can be useful in excluding the diagnosis of oligodendroglioma from the start.

On the other hand, all cases of localized gliomas in this study showed negative expression for IDH indicating absence of the *IDH* gene mutation, which goes along with previous literature that reported *IDH*-wildtype phenotype in localized gliomas, with the rarity of *IDH* mutations in these tumors categories [28, 29 and 30].

In many circumstances, the diagnosis of one of the subtypes of localized glioma can be a challenging task, for example, in some cases of pilocytic astrocytoma, the pilocytic differentiation can be subtle and the histological appearance can resemble diffuse astrocytoma, grade 2. In other cases, pilocytic astrocytomas can show marked anaplasia with vascular proliferation and necrosis which are features suggestive of higher-grade glioma. Moreover, pleomorphic xanthoastrocytoma and ependymoma can pose a diagnostic dilemma especially in cases with marked anaplasia, necrosis and overlapping radiological appearance, and in these situations, IDH assessment can have a substantial diagnostic importance and positivity of IDH by immunohistochemistry can reliably exclude the diagnosis of any type of localized glioma and ensure the diagnosis of *IDH*-mutant diffuse glioma. In the same context, it is documented that *IDH* mutation is mutually exclusive with *BRAF* mutation and that it's exceptionally rare for a single tumor to have concomitant *BRAF* and *IDH* mutation emphasizing on the notion that the

presence of *IDH* mutation excludes other tumors where *BRAF* mutations are a common occurrence such as pilocytic astrocytoma and pleomorphic xanthoastrocytoma[31]. This concept adds more proof that diffuse and localized gliomas are entirely different on the molecular level even if they share the same cell lineage. Also, this highlights the role of *IDH* mutation status detection in predicting the genetic profile of different types of gliomas.

In the present study, IDH1 was negative in all cases of gliosis (3.8%) indicating absence of the mutation and highlighting the reactive nature of these lesions. These situations point to another fundamental diagnostic role for IDH1 assessment by immunohistochemistry in neuropathology which is accurate differentiation between diffuse astrocytoma grade 2 and one of its main histological mimickers (reactive gliosis), and in these situations, positivity for IDH confirms the neoplastic nature of these lesions. IDH1 staining in the current study have proven tremendous application for this IHC marker which has led us to believe that immunohistochemistry can be used as an available cost-effective alternative for molecular sequencing in wide range of patients and situations.

Similarly, in many other studies, sensitivity and specificity of IDH immunohistochemistry antibodies reached up to 100%. They recommend performing immunohistochemistry for IDH as an initial step in the diagnostic workup. Molecular sequencing is done as second step only when immunohistochemistry results are negative or equivocal [15, 32, 33].

The second investigated IHC stain in this study was ATRX. The alpha thalassemia/mental retardation syndrome X-linked (ATRX) gene was first discovered in 1995 through a study assessing patients with the x-linked mental retardation (MR) syndrome presenting with α -thalassemia, severe psychomotor impairments, urogenital abnormalities, and patterns of characteristic facial dysmorphism[34]. The gene plays a crucial role in normal telomere homeostasis acting as a core component of chromatin remodeling complex and regulates incorporation of histone H3.3 into telomeric chromatin [35]. Loss of function of *ATRX* gene leads to alternative lengthening of telomeres resulting in cellular immortality and tumorigenesis. Mutations in *ATRX* gene

have recently been described in at least 15 types of human tumors including neuroblastoma, osteosarcoma, pancreatic neuroendocrine tumors and gliomas [36].

In this study, ATRX showed lost nuclear expression in all diffuse astrocytomas, WHO grades 2 and 4 by immunohistochemistry indicating gene mutation, while grade 3 tumors showed loss of expression in the majority of cases (90%). These results were close to the findings of several other studies that reported high prevalence of *ATRX* mutations in *IDH*-mutant gliomas reaching up to 90% of cases. These studies state that *ATRX* and *IDH* mutations are common co-mutations occurring in a wide spectrum of adult gliomas [27, 37, 38]. On the other hand, 98.1% of *IDH*-wildtype glioblastoma cases showed intact nuclear expression by the antibody indicating absence of *ATRX* gene mutation which is compatible with the previous reports documenting the rarity of *ATRX* mutations in *IDH*-wildtype glioblastomas [39].

Regarding oligodendroglioma all cases showed retained nuclear expression of ATRX indicating absence of gene mutation. A finding that could be explained by the notion that *ATRX* mutation and 1p 19q codeletion is mutually exclusive, meaning that a single tumor cannot harbor both genetic alterations and that *ATRX* mutation is strongly correlated with astrocytic lineage [40].

Even though the recent WHO guidelines necessitate assessment of 1p 19q codeletion status in cases with oligodendroglioma morphology and recommend that cases where molecular testing is not done to be labelled as oligodendroglioma, non-otherwise specified [NOS] [41], some authors rely, however, on the former fact and advocate that *ATRX* mutation excluded by immunohistochemistry can be used as a surrogate for molecular testing for 1p 19q codeletion [42]. In the previous setting ATRX testing will not only influence prognosis but will also act as an important pillar in the diagnostic workup of diffuse gliomas.

By contrast, all cases of localized gliomas in the present study showed preserved nuclear staining by the ATRX antibody indicating absence of the mutation. This finding matches results of other studies that concluded *ATRX* mutation is rarely encountered in pilocytic astrocytoma [9], pleomorphic xanthoastrocytoma [43] and ependymomas [44]. Cases diagnosed with reactive gliosis in this study also showed intact ATRX expression

indicating a non-mutated gene. This finding can be explained by the fact that normal human cells as well as cells with reactive changes do not normally harbor *ATRX* mutations.

Similar to *IDH1* in this study, and taking into consideration its accuracy and usefulness, IHC for *ATRX* has been recommended by other authors who also had satisfactory results with detection of *ATRX* mutation status by immunohistochemistry to use the commercially available antibodies as a surrogate for molecular testing [45, 46]. These studies reported that *ATRX* protein expression correlated perfectly with *ATRX* gene mutation, and that *ATRX* immunoreactivity was associated significantly with histological subtypes and with other key molecular alterations known to occur in diffuse gliomas such as *IDH* mutations [47]. Some of these studies even recommended immunohistochemistry for *ATRX* as an early step in examining cases of gliomas suggesting that *ATRX* mutation status can help predict the *IDH* phenotype [10].

In general, assessment of *ATRX* mutations in gliomas has become a cornerstone in the diagnostic process. First, it plays a role in reaching the proper diagnosis in many circumstances. Second, tumors with *ATRX* mutations have unique features that drive them to grow faster but respond better to therapies that cause double strand DNA breaks. So, *ATRX* is an important prognostic indicator and patients with *ATRX* mutations have better outcome and prolonged survival than patients with *ATRX* wildtype genotype [48]. Finally, there is growing evidence that *ATRX* mutation can be used for personalized targeted therapeutic agents [49].

The last investigated IHC marker in this study was the proliferation index of Ki-67 which is a potent biomarker. It is the most reliable marker of cell proliferation, and it is commonly routinely performed as a part of the glioma diagnostic work up [50].

To simplify Ki-67 assessment in this study, we followed a common three-tiered expression segregation pattern of low, moderate and high labelling, in which low proliferation indicated expression in less than 4-5% of cells, moderate proliferation ranged from 5-10%, while high proliferation indices indicated that 10% or more of tumor cells showed nuclear expression of Ki-67.

Low grade tumors (grades 1 and 2) in both the diffuse and localized gliomas categories showed low proliferation index. Cases of gliosis also showed low proliferation which was compatible with the reactive nature of these lesions. In all these instances, the low proliferation index has helped to confirm the proper diagnosis and grade as well as avoid overdiagnosis of entities such as pleomorphic xanthoastrocytoma as malignant (given its bizarre morphological appearance). Many cases of diffuse astrocytoma, grade 3 showed moderate proliferation index of Ki-67, while some cases showed higher proliferation reaching up to 40%. Despite the elevated proliferation in these cases, they still didn't show necrosis or microvascular proliferation, so the morphological appearance was more conclusive than Ki-67 index, and the diagnosis was not changed to glioblastoma even after showing such high Ki-67 index.

The vast majority of glioblastoma and glioblastoma subtypes (98% of cases) showed proliferation index of 10% or higher in tumor cells. This finding closely correlates with the general understanding that higher levels of Ki-67 correlate with higher tumor grades **[51]**.

Establishing a Ki-67 cut-off value to differentiate low- and high-grade lesions in the CNS has been the topic of interest in prior literature, and many studies have concluded a 10% positivity in tumor nuclei as a clinically relevant cut point for differentiation **[52, 53]**. In the present study, only 11.8% of grade 3 and 4 cases across the diffuse and localized glioma categories showed proliferation index of less than 10%, in keeping with the previous observation.

Although the grading process of gliomas relies primarily on histological appearance; in some instances, this approach can be difficult and even inaccurate. An example of such situations is small biopsy specimens which is a commonly encountered problem in the practice of neuropathology, and in such cases, depending on morphological appearance alone can be misleading. Another commonly encountered scenario is inadequate sampling of heterogenous tumors. For instance, a non-representative biopsy can fail to sample an area of necrosis leading to underdiagnosis of a case of glioblastoma as a lower grade astrocytoma. The value of Ki-67 staining in these cases is of utmost importance. High proliferation index in a small biopsy accompanied by the

picture of radiologically aggressive looking tumors can help suggesting the diagnosis of higher-grade glioma in the setting of morphologically unequivocal tumors. The value of Ki-67 assessment for the prognostication process of gliomas is an agreed-upon fact. A very small subset of studies suggested that higher Ki-67 values in gliomas correlated with better survival [54]. On the other hand, the vast majority of studies indicated that higher values of Ki-67 correlated with higher tumor grades as well as worse overall survival. These studies reported that Ki-67 is an independent prognostic factor in glioma. Some studies attributed this to the ability of a cell to continue to proliferate after the time of tumor resection leading to higher incidences of recurrence [11, 55].

The results of one large metanalysis published in 2015 analyzed all the prior research related to assessment of Ki-67 in gliomas has also reached similar conclusion that linked higher Ki-67 levels with worse patient outcome and concluded that evaluating Ki-67 index by immunohistochemistry is reliable and can be used as a potential predictive factor in the prognosis of gliomas [56].

5. Conclusion:

- In a resource-limited setup where molecular testing is lacking, immunohistochemical staining is a useful, affordable and widely available option.
- Staining brain tumors for IDH, ATRX and Ki-67 is beneficial in categorizing and diagnosing patients with brain tumors, which not only serves as the basis of therapeutic decisions, but may also help to predict outcome of these patients.

Ethics approval And Consent

The current study was conducted after obtaining the approval from research ethics committee, Faculty of Medicine, Tanta University, Egypt (32288/04/18). Informed written consent was obtained from involved participants in the study.

Data availability

The datasets used and/or analyzed during this study are available from the corresponding author upon request.

Disclaimer (Artificial intelligence)

Option 1:

Author(s) hereby declare that NO generative AI technologies such as Large Language Models (ChatGPT, COPILOT, etc.) and text-to-image generators have been used during the writing or editing of this manuscript.

Option 2:

Author(s) hereby declare that generative AI technologies such as Large Language Models, etc. have been used during the writing or editing of manuscripts. This explanation will include the name, version, model, and source of the generative AI technology and as well as all input prompts provided to the generative AI technology

Details of the AI usage are given below:

- 1.
- 2.
- 3.

References:

1. Huttner, A. Overview of primary brain tumors: Pathologic classification, epidemiology, molecular biology, and prognostic markers. Hematology Oncology. Clinics of North America. 2012 Aug, 26(4):715-32. [doi: 10.1016/j.hoc.2012.05.004](https://doi.org/10.1016/j.hoc.2012.05.004).
2. Ostrom QT, Gittleman H, Fulop J, Liu M, Blanda R, Kromer C, Wolinsky Y, Kruchko C, Barnholtz-Sloan JS. statistical report: primary brain and central nervous system tumors diagnosed in the United States in 2008Y2012. Neuro-Oncology. 2015 Oct, 4:iv1-iv62. [doi: 10.1093/neuonc/nov189](https://doi.org/10.1093/neuonc/nov189).
3. Chen R, Smith-Cohn M, Cohen AL, Colman H. Glioma Subclassifications and Their Clinical Significance, Neurotherapeutics. 2017 Apr;14(2):284-297. [doi: 10.1007/s13311-017-0519-x](https://doi.org/10.1007/s13311-017-0519-x).
4. Karsy M, Guan J, Cohen AL, Jensen R, Colman H. New Molecular Considerations for Glioma: IDH, ATRX, BRAF, TERT, H3 K27M. Current Neurology and Neuroscience Reports. 2017 Feb;17(2):19. [doi: 10.1007/s11910-017-0722-5](https://doi.org/10.1007/s11910-017-0722-5).

5. Yang H, Ye D, Guan KL, Xiong Y. IDH1 and IDH2 mutations in tumorigenesis: mechanistic insights and clinical perspectives. *Clinical cancer research*. 2012 Oct 15;18(20):5562-71. [doi: 10.1158/1078-0432.CCR-12-1773](https://doi.org/10.1158/1078-0432.CCR-12-1773).
6. Heaphy CM, de Wilde RF, Jiao Y, Klein AP, Edil BH, Shi C, Bettegowda C, Rodriguez FJ, Eberhart CG, Hebbar S, Offerhaus GJ, McLendon R, Rasheed BA, He Y, Yan H, Bigner DD, Oba-Shinjo SM, Marie SK, Riggins GJ, Kinzler KW, Vogelstein B, Hruban RH, Maitra A, Papadopoulos N, Meeker AK. Altered telomeres in tumors with ATRX and DAXX mutations. *Science*. 2011 Jul 22;333(6041):425. [doi: 10.1126/science.1207313](https://doi.org/10.1126/science.1207313).
7. Malueka RG, Theresia E, Fitria F, Argo IW, Donurizki AD, Shaleh S, Innayah MR, Wicaksono AS, Dananjoyo K, Asmedi A, Hartanto RA. Comparison of Polymerase Chain Reaction–Restriction Fragment Length Polymorphism, Immunohistochemistry, and DNA Sequencing for the Detection of IDH1 Mutations in Gliomas. *Asian Pacific Journal of Cancer Prevention: APJCP*. 2020 Nov;21(11):3229–3234. [doi: 10.31557/APJCP.2020.21.11.3229](https://doi.org/10.31557/APJCP.2020.21.11.3229)
8. Mishra S, Rathi KR, Shelly D, Bharadwaj R. Immunohistochemical Expression of IDH1R132H in Astrocytic Tumours and its Association with Histopathological Grade, TP53 and EGFR Protein Expression. *Annals of Pathology and Laboratory Medicine*. 2017 Oct 27;4(5):A522-529. [doi:10.21276/APALM.1458](https://doi.org/10.21276/APALM.1458)
9. Chatterjee D, Radotra BD, Kumar N, Vasishta RK, Gupta SK. IDH1, ATRX, and BRAFV600E mutation in astrocytic tumors and their significance in patient outcome in north Indian population. *Surgical neurology international*. 2018 Feb 14;9:29. [doi: 10.4103/sni.sni_284_17](https://doi.org/10.4103/sni.sni_284_17).
10. Ebrahimi A, Skardelly M, Bonzheim I, Ott I, Mühleisen H, Eckert F, Tabatabai G, Schittenhelm J. ATRX immunostaining predicts IDH and H3F3A status in gliomas. *Actaneuropathologica communications*. 2016 Dec;4(1):1-0. doi.org/10.1186/s40478-016-0331-6
11. Cai J, Zhang C, Zhang W, Wang G, Yao K, Wang Z, Li G, Qian Z, Li Y, Jiang T, Jiang C. ATRX, IDH1-R132H and Ki-67 immunohistochemistry as a classification scheme for astrocytic tumors. *Oncoscience*. 2016 Sep 6;3(7-8):258-265. [doi: 10.18632/oncoscience.317](https://doi.org/10.18632/oncoscience.317).
12. Hu WM, Wang F, Xi SY, Zhang X, Lai JP, Wu HY, Liu LL, Sai K, Zeng J. Practice of the new integrated molecular diagnostics in gliomas: experiences and new findings in a single Chinese center. *Journal of Cancer*. 2020 Jan 1;11(6):1371-1382. [doi: 10.7150/jca.38603](https://doi.org/10.7150/jca.38603).

13. Van den Bent MJ, Weller M, Wen PY, Kros JM, Aldape K, Chang S. A clinical perspective on the 2016 WHO brain tumor classification and routine molecular diagnostics. *Neuro-oncology*. 2017 May 1;19(5):614-24. [doi: 10.1093/neuonc/now277](https://doi.org/10.1093/neuonc/now277).
14. Louis DN, Perry A, Reifenberger G, von Deimling A, Figarella-Branger D, Cavenee WK, Ohgaki H, Wiestler OD, Kleihues P, Ellison DW. The 2016 World Health Organization Classification of Tumors of the Central Nervous System: a summary. *Acta Neuropathologica*. 2016 Jun;131(6):803-20. [doi: 10.1007/s00401-016-1545-1](https://doi.org/10.1007/s00401-016-1545-1).
15. Rajeswarie RT, Rao S, Nandeesh BN, Yasha TC, Santosh V. A simple algorithmic approach using histology and immunohistochemistry for the current classification of adult diffuse glioma in a resource-limited set-up. *Journal of clinical pathology*. 2018 Apr 1;71(4):323-9. [doi: 10.1136/jclinpath-2017-204638](https://doi.org/10.1136/jclinpath-2017-204638).
16. Waitkus MS, Diplas BH, Yan H. Biological role and therapeutic potential of IDH mutations in cancer. *Cancer cell*. 2018 Aug 13;34(2):186-95. [doi: 10.1016/j.ccell.2018.04.011](https://doi.org/10.1016/j.ccell.2018.04.011).
17. Pirozzi CJ, Yan H. The implications of IDH mutations for cancer development and therapy. *Nature Reviews Clinical Oncology*. 2021 Oct;18(10):645-661. [doi: 10.1038/s41571-021-00521-0](https://doi.org/10.1038/s41571-021-00521-0).
18. Platten M, Bunse L, Wick W. Emerging targets for anticancer vaccination: IDH. *ESMO open*. 2021 Aug 1;6(4):100214. [doi: 10.1016/j.esmoop.2021.100214](https://doi.org/10.1016/j.esmoop.2021.100214).
19. Chen W, Guo S, Wang Y, Shi Y, Guo X, Liu D, Li Y, Wang Y, Xing H, Xia Y, Li J. Novel insight into histological and molecular astrocytoma, IDH-mutant, Grade 4 by the updated WHO classification of central nervous system tumors. *Cancer Medicine*. 2023 Sep;12(18):18666-78. [doi: 10.1002/cam4.6476](https://doi.org/10.1002/cam4.6476)
20. Gessler F, Zappi J, Konczalla J, Bernstock JD, Forster MT, Wagner M, Mittelbronn M, Seifert V, Senft C. Secondary glioblastoma: molecular and clinical factors that affect outcome after malignant progression of a lower grade tumor. *World neurosurgery*. 2017 Jun 1;102:49-55. [doi: 10.1016/j.wneu.2017.02.104](https://doi.org/10.1016/j.wneu.2017.02.104).
21. Oronsky B, Reid TR, Oronsky A, Sandhu N, Knox SJ. A review of newly diagnosed glioblastoma. *Frontiers in Oncology*. 2021 Feb 5;10:574012. [doi: 10.3389/fonc.2020.574012](https://doi.org/10.3389/fonc.2020.574012).

22. Peckham ME, Osborn AG, Palmer CA, Tsai A, Salzman KL. Gliosarcoma: neuroimaging and immunohistochemical findings. *Journal of Neuroimaging*. 2019 Jan;29(1):126-32. [doi: 10.1111/jon.12565](https://doi.org/10.1111/jon.12565).
23. Ogawa K, Kurose A, Kamataki A, Asano K, Katayama K, Kurotaki H. Giant cell glioblastoma is a distinctive subtype of glioma characterized by vulnerability to DNA damage. *Brain tumor pathology*. 2020 Jan;37(1):5-13. [doi: 10.1007/s10014-019-00355-w](https://doi.org/10.1007/s10014-019-00355-w).
24. Hamisch C, Ruge M, Kellermann S, Kohl AC, Duval I, Goldbrunner R, Grau SJ. Impact of treatment on survival of patients with secondary glioblastoma. *Journal of neuro-oncology*. 2017 Jun;133(2):309-13. [doi: 10.1007/s11060-017-2415-y](https://doi.org/10.1007/s11060-017-2415-y).
25. Berghoff AS, Kiesel B, Widhalm G, Wilhelm D, Rajky O, Kurscheid S, Kresl P, Wöhrer A, Marosi C, Hegi ME, Preusser M. Correlation of immune phenotype with IDH mutation in diffuse glioma. *Neuro-oncology*. 2017 Oct 19;19(11):1460-8. [doi: 10.1093/neuonc/nox054](https://doi.org/10.1093/neuonc/nox054).
26. Huang J, Yu J, Tu L, Huang N, Li H, Luo Y. Isocitrate dehydrogenase mutations in glioma: from basic discovery to therapeutics development. *Frontiers in oncology*. 2019 Jun 12;9:506. [doi: 10.3389/fonc.2019.00506](https://doi.org/10.3389/fonc.2019.00506).
27. Ohba S, Kuwahara K, Yamada S, Abe M, Hirose Y. Correlation between IDH, ATRX, and TERT promoter mutations in glioma. *Brain tumor pathology*. 2020 Apr;37(2):33-40. [doi: 10.1007/s10014-020-00360-4](https://doi.org/10.1007/s10014-020-00360-4).
28. Phillips JJ, Gong H, Chen K, Joseph NM, van Ziffle J, Bastian BC, Grenert JP, Kline CN, Mueller S, Banerjee A, Nicolaidis T. The genetic landscape of anaplastic pleomorphic xanthoastrocytoma. *Brain Pathology*. 2019 Jan;29(1):85-96. [doi: 10.1111/bpa.12639](https://doi.org/10.1111/bpa.12639).
29. Prayson RA. IDH-1 polymorphisms in pilocyticastrocytomas. *Annals of diagnostic pathology*. 2019 Dec 1;43:151411. [doi: 10.1016/j.anndiagpath.2019.151411](https://doi.org/10.1016/j.anndiagpath.2019.151411).
30. Weis S, Sonnberger M, Dunzinger A, Voglmayr E, Aichholzer M, Kleiser R, Strasser P. Ependymal Tumors. In *Imaging Brain Diseases 2019* (pp. 1481-1511). Springer, Vienna. eBook ISBN. 978-3-7091-1544-2 Published: 12 December 2019. [DOI. https://doi.org/10.1007/978-3-7091-1544-2](https://doi.org/10.1007/978-3-7091-1544-2)
31. Behling F, Schittenhelm J. Oncogenic BRAF alterations and their role in brain tumors. *Cancers*. 2019 Jun;11(6):794. [doi: 10.3390/cancers11060794](https://doi.org/10.3390/cancers11060794).

32. Takano S, Ishikawa E, Sakamoto N, Matsuda M, Akutsu H, Noguchi M, Kato Y, Yamamoto T, Matsumura A. Immunohistochemistry on IDH 1/2, ATRX, p53 and Ki-67 substitute molecular genetic testing and predict patient prognosis in grade III adult diffuse gliomas. *Brain tumor pathology*. 2016 Apr 1;33(2):107-16. doi.org/10.1007/s10014-016-0260-x.
33. DeWitt JC, Jordan JT, Frosch MP, Samore WR, Iafrate AJ, Louis DN, Lennerz JK. Cost-effectiveness of IDH testing in diffuse gliomas according to the 2016 WHO classification of tumors of the central nervous system recommendations. *Neuro-oncology*. 2017 Nov 29;19(12):1640-50. [doi: 10.1093/neuonc/nox120](https://doi.org/10.1093/neuonc/nox120).
34. Nandakumar P, Mansouri A, Das S. The role of ATRX in glioma biology. *Frontiers in oncology*. 2017 Sep 29;7:236. [doi: 10.3389/fonc.2017.00236](https://doi.org/10.3389/fonc.2017.00236).
35. Li F, Ge Y, Liu D, Songyang Z. The role of telomere-binding modulators in pluripotent stem cells. *Protein & cell*. 2020 Jan;11(1):60-70. [doi: 10.1007/s13238-019-0651-y](https://doi.org/10.1007/s13238-019-0651-y).
36. Purkait S, Miller CA, Kumar A, Sharma V, Pathak P, Jha P, Sharma MC, Suri V, Suri A, Sharma BS, Fulton RS. ATRX in diffuse gliomas with its mosaic/heterogeneous expression in a subset. *Brain Pathology*. 2017 Mar;27(2):138-45. [doi: 10.1111/bpa.12364](https://doi.org/10.1111/bpa.12364).
37. Haase S, Garcia-Fabiani MB, Carney S, Altshuler D, Núñez FJ, Méndez FM, Núñez F, Lowenstein PR, Castro MG. Mutant ATRX: uncovering a new therapeutic target for glioma. *Expert opinion on therapeutic targets*. 2018 Jul 3;22(7):599-613. [doi: 10.1080/14728222.2018.1487953](https://doi.org/10.1080/14728222.2018.1487953).
38. Wan-Ming H, Fang W, Shao-Yan X, Xiao Z, Jun-Peng L, Hui-Yu W, Ke S, Jing Z. The Immunohistochemical Expression of IDH1, ATRX, PHH3, P53, Ki67 and Molecular Status of IDH, 1p19q, MGMTp, TERTp in Gliomas: An Analysis of 568 Patients in a Single Center (September 9, 2018). Available at <http://dx.doi.org/10.2139/ssrn.3247871>
39. Gülten G, Yalçın N, Baltalarlı B, Doğu G, Acar F, Doğruel Y. The importance of IDH1, ATRX and WT-1 mutations in glioblastoma. *Polish Journal of Pathology*. 2020;71(2):127-37. [doi: 10.5114/pjp.2020.97020](https://doi.org/10.5114/pjp.2020.97020).
40. Anand N, Husain N, Varshney R, Malhotra KP, Kaif M. Molecular classification and stratification of adult diffuse gliomas: A tertiary care center study. *Journal of Carcinogenesis*. 2021 Oct;20:20. [doi: 10.4103/jcar.jcar_17_21](https://doi.org/10.4103/jcar.jcar_17_21).

41. Diamandis P, Aldape K. World Health Organization 2016 classification of central nervous system tumors. *Neurologic clinics*. 2018 Aug 1;36(3):439-47. [doi: 10.1016/j.ncl.2018.04.003](https://doi.org/10.1016/j.ncl.2018.04.003).
42. Pekmezci M, Rice T, Molinaro AM, Walsh KM, Decker PA, Hansen H, Sicotte H, Kollmeyer TM, McCoy LS, Sarkar G, Perry A. Adult infiltrating gliomas with WHO 2016 integrated diagnosis: additional prognostic roles of ATRX and TERT. *Actaneuropathologica*. 2017 Jun;133(6):1001-16. [doi: 10.1007/s00401-017-1690-1](https://doi.org/10.1007/s00401-017-1690-1).
43. Sasaki S, Tomomasa R, Nobusawa S, Hirato J, Uchiyama T, Boku E, Miyasaka T, Hirose T, Ohbayashi C. Anaplastic pleomorphic xanthoastrocytoma associated with an H3G34 mutation: a case report with review of literature. *Brain tumor pathology*. 2019 Oct;36(4):169-73. doi.org/10.1007/s10014-019-00349-8.
44. Jalal JA, Rowandizy AI, Ismael AT. Immunohistochemical expression of ATRX in gliomas. *Cellular and Molecular Biology*. 2020 Aug 31;66(7):131-5. [PMID: 33287933](https://pubmed.ncbi.nlm.nih.gov/33287933/).
45. Burford C, Laxton R, Sidhu Z, Aizpurua M, King A, Bodi I, Ashkan K, Al-Sarraj S. ATRX immunohistochemistry can help refine 'not elsewhere classified' categorisation for grade II/III gliomas. *British journal of neurosurgery*. 2019 Sep 3;33(5):536-40. doi.org/10.1080/02688697.2019.1600657.
46. Diaz JJ, Scoggin T, Ramos J. Characterization of ATRX polyclonal, application of immunohistochemical analysis on astrocytoma and glioblastoma. *Cancer Research*. 2021 81 (13): 458. doi.org/10.1158/1538-7445.AM2021-458.
47. Ikemura M, Shibahara J, Mukasa A, Takayanagi S, Aihara K, Saito N, Aburatani H, Fukayama M. Utility of ATRX immunohistochemistry in diagnosis of adult diffuse gliomas. *Histopathology*. 2016 Aug;69(2):260-7. [doi: 10.1111/his.12927](https://doi.org/10.1111/his.12927).
48. Brendle C, Hempel JM, Schittenhelm J, Skardelly M, Tabatabai G, Bender B, Ernemann U, Klose U. Glioma grading and determination of IDH mutation status and ATRX loss by DCE and ASL perfusion. *Clinical neuroradiology*. 2018 Sep;28(3):421-8. [doi: 10.1007/s00062-017-0590-z](https://doi.org/10.1007/s00062-017-0590-z).
49. Garbarino J, Eckroate J, Sundaram RK, Jensen RB, Bindra RS. Loss of ATRX confers DNA repair defects and PARP inhibitor sensitivity. *Translational Oncology*. 2021 Sep 1;14(9):101147. [doi: 10.1016/j.tranon.2021.101147](https://doi.org/10.1016/j.tranon.2021.101147).

50. Li Y, Qian Z, Xu K, Wang K, Fan X, Li S, Liu X, Wang Y, Jiang T. Radiomic features predict Ki-67 expression level and survival in lower grade gliomas. *Journal of neuro-oncology*. 2017 Nov;135(2):317-24. [doi: 10.1007/s00330-017-4964-z](https://doi.org/10.1007/s00330-017-4964-z).
51. Gates ED, Lin JS, Weinberg JS, Hamilton J, Prabhu SS, Hazle JD, Fuller GN, Baladandayuthapani V, Fuentes D, Schellingerhout D. Guiding the first biopsy in glioma patients using estimated Ki-67 maps derived from MRI: conventional versus advanced imaging. *Neuro-oncology*. 2019 Mar 18;21(4):527-36. [doi: 10.1093/neuonc/noz004](https://doi.org/10.1093/neuonc/noz004).
52. Tavares CB, Gomes FD, Sousa EB, de Oliveira Brito JN. Expression of Ki-67 in Low-Grade and High-Grade Astrocytomas. *Jbnc-Jornal Brasileiro De Neurocirurgia*. 2016;27(3):225-30. [url={https://api.semanticscholar.org/CorpusID:199412739}](https://api.semanticscholar.org/CorpusID:199412739).
53. Sun X, Pang P, Lou L, Feng Q, Ding Z, Zhou J. Radiomic prediction models for the level of Ki-67 and p53 in glioma. *Journal of International Medical Research*. 2020 May;48(5):0300060520914466. [doi: 10.1177/0300060520914466](https://doi.org/10.1177/0300060520914466).
54. Wong E, Nahar N, Hau E, Varikatt W, Gebiski V, Ng T, Jayamohan J, Sundaresan P. Cut-point for Ki-67 proliferation index as a prognostic marker for glioblastoma. *Asia-pacific Journal of Clinical Oncology*. 2019 Feb;15(1):5-9. [doi: 10.1111/ajco.12826](https://doi.org/10.1111/ajco.12826).
55. Yuan X, Liu D, Wang Y, Li X. Significance of nuclear magnetic resonance combined with Ki-67 and VEGF detection in the diagnosis and prognosis evaluation of brain glioma. *J BUON; official journal of the Balkan Union of Oncology*. 2018 Mar 1;23(2):410-5. [PMID: 29745085](https://pubmed.ncbi.nlm.nih.gov/29745085/).
56. Chen WJ, He DS, Tang RX, Ren FH, Chen G. Ki-67 is a valuable prognostic factor in gliomas: evidence from a systematic review and meta-analysis. *Asian Pacific Journal of Cancer Prevention*. 2015;16(2):411-20. [doi: 10.7314/apjcp.2015.16.2.411](https://doi.org/10.7314/apjcp.2015.16.2.411).

Abbreviation

ATRX; Alpha thalassemia/mental retardation syndrome X-linked

CNS; central nervous system

DAB; diaminobenzidine

DNA; deoxy ribonucleic acid

G; Grade

IDH; isocitrate dehydrogenase

IHC; immunohistochemistry/immunohistochemical

NOS; non otherwise specified

SWI2/SNF2; Switch/Sucrose Non-Fermentable

USA; United States of America

WHO; World Health Organization

UNDER PEER REVIEW