

Dystocia caused by uterine rupture due to overdose of oxytocin therapy in a Labrador bitch

ABSTRACT

A three-year-old Labrador bitch brought to the TVCC-FVAS-BHU-Mirzapur, with the history of whelped one dead puppy 12 hrs before further no progress of delivery. The bitch administered with a total dose of 30 IU of oxytocin intramuscularly but there was no progress. Abdominal palpation revealed presence of fetal like mass and per-vaginal examination revealed presence of fetal parts in the birth canal. The bitch was treated with oxytocin @ 0.2 IU/kg bodyweight slow IV with 25% dextrose 0.2ml/kg bodyweight slow IV, a dead male fetus was removed through mutational operation after 15 minutes, after that no puppies were palpable. Radiographic examination revealed presence of four fetuses in the abdominal cavity. It was then decided to go for cesarean section. The surgical site was prepared aseptically and the bitch was pre-medicated with inj. Xylazine @ 1 mg/kg i/m and inj. Atropine Sulphate @ 0.02 mg/kg s/c followed by induction with 2 to 4 % isoflurane, and maintenance with 2 % isoflurane. Skin, abdominal muscles and peritoneum was incised in a routine manner and exploration of uterus was done. After exploration right uterine horn was found severely ruptured followed by fetuses from the left uterine horn were removed. The uterus was sutured with cushing followed by lembert pattern. Peritoneum, abdominal muscles, and skin were sutured in a routine manner. The bitch was treated with antibiotic and analgesic for 3 days. The bitch had uneventful recovery with proper postoperative care. In the present study we concluded that the dystocia was due to uterine rupture and this can be corrected through exploratory laparotomy.

Key words: Dystocia, uterine rupture, exploratory laparotomy

1. INTRODUCTION

In bitches, the overall incidence of dystocia is around 5%. Further, in a clinic report, it was found around 7.80%, but it may be higher in some breeds of bitches selected for large heads. The maternal causes appear to be more common; they contribute around 75% [1], whereas the foetal

causes are quite less common; they contribute around 25% in bitches [2]. Uterine rupture is an unusual obstetrical condition that occurs during the whelping process in bitches [3]. Further, this can also occur long-standing cases of dystocia, uterine torsion [4], prolonged cases of uterine inertia [5], overdoses of oxytocin therapy [6], intrauterine foetal death [7], prolonged cases of foetal anasarca [8], long-standing cases of closed pyometra [9], and faulty mutational operations [10]. The present case was reported as dystocia caused by uterine rupture due to overdose of oxytocin therapy in a labrador bitch.

2.HISTORY AND OBSTETRICAL OBSERVATIONS

A three-year-old Labrador bitch was brought to the Teaching Veterinary Clinical Complex-FVAS-BHU-Barkaccha, Mirzapur, with the history of whelping one dead puppy 12 hours before further no progress of delivery. The bitch was dull, depressed, and severely dehydrated. The bitch was administered a total dose of 30 IU of oxytocin intramuscularly, but there was no progress. Abdominal palpation revealed the presence of foetal-like mass, and per-vaginal examination revealed the presence of foetal parts in the birth canal. Radiographic examination revealed the presence of four foetuses in the abdominal cavity.

3.TREATMENT AND DISCUSSION

The bitch was treated with oxytocin @ 0.2 IU/kg body weight slow IV with 25% dextrose 0.2 ml/kg body weight slow IV. A dead male foetus was removed through mutational operation after 15 minutes; after that, no puppies were palpable. Radiographic examination revealed the presence of four foetuses in the abdominal cavity. It was then decided to go for a caesarean section. The surgical site was prepared aseptically, and the bitch was pre-medicated with inj. Xylazine @ 1 mg/kg intramuscular and inj. Atropine sulphate @ 0.02 mg/kg subcutaneously, followed by induction with 2 to 4% isoflurane and maintenance with 2% isoflurane. After positioning the bitch in dorsal recumbency, laparotomy was performed by incising the skin cranial third from the umbilicus to the pubis; abdominal muscles and peritoneum were incised in a routine manner, and exploration of the uterus was done. After exploration, the right uterine horn was found severely ruptured, followed by foetuses from the left uterine horn being removed. The uterus was sutured with cushing followed by a lembert pattern using number 2-0 absorbable catgut. Peritoneum, abdominal muscles using number 2 absorbable catgut, and skin

were sutured with a silk horizontal mattress. The bitch was treated with Inj. Cefotaxime @ 50 mg/kg, body weight slow I/V, and Inj. Meloxicam @ 0.25 mg/kg, body weight slow I/M for 5 days. The bitch had an uneven full recovery. The bitch had uneventful recovery with proper postoperative care. Oxytocin injection is used therapeutically to treat dystocia caused by non-obstructive uterine inertia in bitches; in many cases, often exogenous oxytocin is used to stimulate the uterine contraction [6]. It should be administered 0.25 to 1 IU/kg body weight intramuscularly at an interval of 15 to 20 minutes, and it can be increased to a maximum of 2 IU/kg body weight [2]. While doses of 5 IU or more may cause prolonged tetanic uterine contraction rather than coordinated expulsive contractions, tumultuous contraction, uterine rupture, and foetal death [11]. Uterine rupture is a rare obstetrical condition in canine practice [7]. The causes of uterine rupture in bitches are associated with various factors, which include trauma, anomalies in uterine horn development, and uterine pathological conditions like pyometra. Although rupture of the gravid uterus is an uncommon finding in bitches, it has been observed occasionally during the periparturient period, often in patients with dystocia, after caesarean section [12]. Ruptured uterus during the whelping is most likely to occur when an erroneous or excessive dose of oxytocin or $\text{PGF}_{2\alpha}$ administration, forceful traction, trauma during late pregnancy, and normal whelping occur [13]. In the present case, the uterine rupture during whelping was over doses of oxytocin therapy. An excessive dose of oxytocin injection caused an incoordinated uterine condition that resulted in uterine rupture. In this case, we confirmed the clinical signs of brownish vaginal discharge, pale mucous membranes, becoming severely dehydrated, and the presence of solid structures to abdominal palpation, and also confirmed the retention of dead foetuses in the uterus through radiographic and ultrasonographic examinations. Therefore, we infer that the gravid uterus was ruptured during labor because of the tetanic contraction of the uterus. For a successful treatment of uterine rupture during whelping, early and correct diagnosis is crucial because these situations must be treated as an obstetrical emergency and lead to peritonitis, septicaemia, and foetal maceration. The most suitable therapeutic approach for uterine rupture is exploratory laparotomy followed by OHE with intravenous fluids and antibiotic therapy [14]. In this case, we have chosen to perform an emergency exploratory laparotomy at the median laparotomy. It was observed that a rupture of the right uterine horn and weakened areas in the left uterine horn.

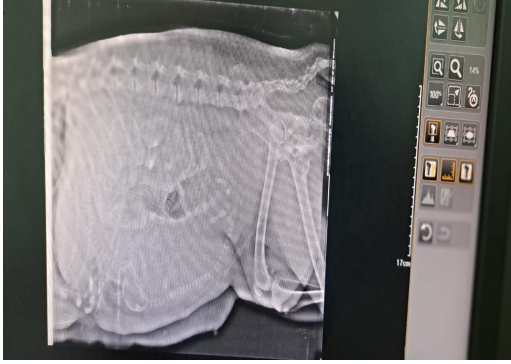


Fig.1. Presence of fetus in radiography

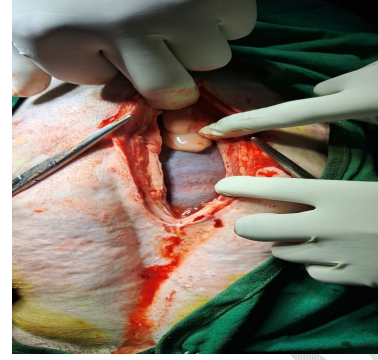


Fig.2. Incision of Abdominal muscles

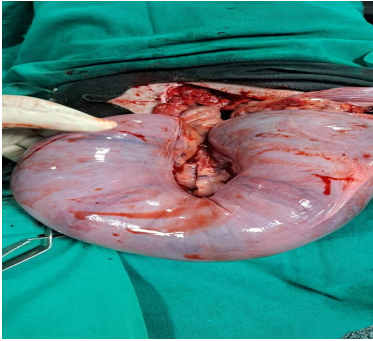


Fig.3. Exteriorization of gravid uterus

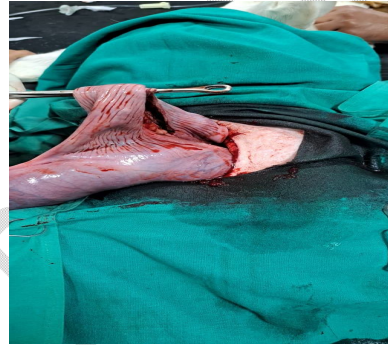


Fig.4. Exteriorization of ruptured uterus

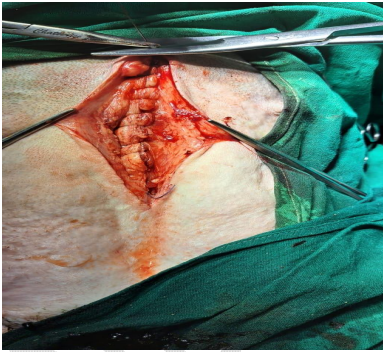


Fig.5. Suturing of abdominal muscles

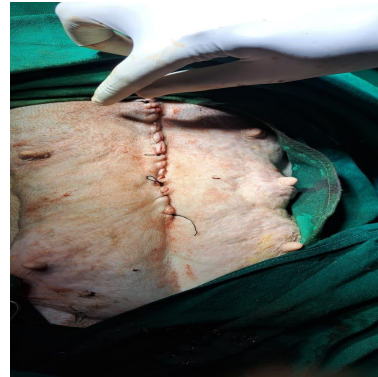

Fig.6. Suturing of skin

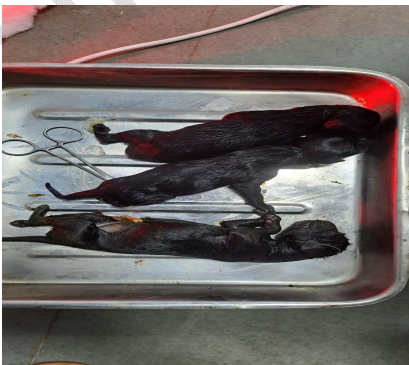

Fig.7. Dead fetus

4. CONCLUSION

In the present study, we concluded that the dystocia is caused by uterine rupture due to overdosage of oxytocin therapy, and this can be corrected through exploratory laparotomy. Appropriate diagnosis and treatment are essential to save the life of the bitch.

DISCLAIMER (ARTIFICIAL INTELLIGENCE)

Author (s) hereby declares that NO generative AI technologies such as Large Language Models (ChatGPT, COPILOT, etc) and text-to-image generators have been used during writing or editing of this manuscript.

REFERENCES

1. Jackson PGG. Post-parturient problems in the dog and cat. Handbook of Veterinary Obstetrics (2nd edn). London: WB Saunders. 2004; p. 233-237.
2. Balamurugan B and Maurya V. Canine Reproduction a book for practicing veterinarians and students. (1st edn.). Jaya Publishing house, New Delhi.2022; p.136-140.
3. Kim EY, Nam HS, Lee JW, Moon HC, Hong LG, Jung YJ, Jeong MJ, Lee BH, Jeong MS and Kim HD. Asymptomatic Uterine Rupture Caused by Trauma in a Small-Sized Non-Gravid Dog. Journal of Veterinary Clinics. 2024; 41:112-116.
4. Niwas R, JinagalS, Amandeep, Aniland Dutt R. Uterine Rupture Associated with Uterine Torsion in a Pregnant Bitch.The Indian Journal of Animal Reproduction. 2023; 44-2. DOI:10.48165/ijar.2023.44.02.18.
5. Balamurugan B, Narwade P, Mishra RM, Kumar V, Ravi SK, Kumar PR, and Jena D. Dystocia due to complete primary uterine inertia in an American bull bitch. International Journal of Science, Environment.2024;13:1.6-10.
6. Xavier S, Laiju MP, Jeyakumar C, and Abhilash RS. Uterine rupture from oxytocin overdose and successive management of post-surgical complications in a dog. Indian journal of canine practice. 2019; 11:2. DOI 10.29005/IJCP.2019.11.2.158-160.

7. Davies R, Rozanski E, Tseng F, Jennings S, Paul A. Traumatic uterine rupture in three felids. *Journal of Veterinary Emergency and Critical Care (San Antonio)*. 2016; 26: 782-786.
8. Murugan M, Periyannan M, Selvaraju M, Keshav prasad PR, Palanisamy M, Gopikrishnan D and Senthilkumar K. Successful management of dystocia with multiple uterine rupture in a French bulldog due to fetal anasarca. *The Pharma Innovation Journal* 2021; SP-10:12: 511-513.
9. Nokes DE, Parkinson TJ, And Gary CW and England. *Veterinary Reproduction and Obstetrics England* (10thedn.). Saunders Elsevier.2019; p.330-332.
10. Jinagal S, Yadav K, Bansal K N and Sharma R. Conquering uterine inertia and uterine rupture in a pregnant Rottweiler canine: Successful caesarean section approach. *International Journal of Veterinary Sciences and Animal Husbandry* 2023; 8(4): 83-85.
11. Sridevi P. *Canine Reproduction: The theory and Practice*, (1stedn) Active Ads and Printers Pvt.Ltd., Hyderabad, India. 2015; p.96-101.
12. Arun R, Methai A, Sowbharenaya C, Kalaivanan M, Arulanandam K and Richard Jegadeesan PN. Navigating uterine rupture challenges in a non-descriptive female dog. *International Journal of Veterinary Sciences and Animal Husbandry* 2024; 9:1: 28-29.
13. Park CH, Seok Oh K, and Son CH. Spontaneous Uterine Rupture in a Greyhound Bitch during Parturition. *Journal of Animal Reproduction and Biotechnology*.2014;29:393-395.
14. Carreira PR, Albuquerque C, Abreu H and Maltez L. Uterine prolapse with associated rupture in a Podengo bitch. *Reproduction in Domestic Animal*. 2012; 47: 51-55.doi.org/10.12750/JET.2014.29.4.393.