

# Case Report

## Management of odontogenic myxoma of lower jaw: Case Report

### ABSTRACT

**Aims:** Odontogenic myxoma is a benign tumor that affects the jaw bones. Although it is benign, it can cause great destruction to the tissues, creating deformities on the face. It can be easily confused with other fibro-osseous lesions, leading to inadequate treatment. **The treatment of choice is surgical resection of the lesion and reconstructive surgery.**

**Presentation of Case:** In the present work, a clinical case was addressed of a female patient, aged 38 years, with a primary complaint of painless volumetric increase in soft tissues in the posterior region of the body of the mandible on the right side, with progression for two years. After clinical and complementary examinations, an incisional biopsy diagnosed odontogenic myxoma. Total Resection surgery was performed with a safety margin, and reconstruction was done with a customized temporomandibular joint prosthesis with hemi mandibular prosthesis.

**Discussion:** **The OM lesion affects the mandible bone. The present research diagnosed it in the mandible, too.** We disagree that the radical treatment harmed the patient's quality of life; our study showed no functional or aesthetic damage because we simultaneously performed surgical reconstruction with customized prostheses.

**Conclusion:** As a result, total resection of the lesion was achieved with a safety margin (proven by biopsy), restoring the face's function and aesthetics.

**Keywords:** Myxoma. Odontogenic Tumors. Temporomandibular Joint. Mandibular Prosthesis. Mandibular Reconstructive Surgery.

### 1. INTRODUCTION

The term "myxoma" was created in 1863 due to mucin, like the umbilical cord. It can affect hard and soft tissues, such as the skin, heart, and facial bones [1]. Odontogenic myxoma (OM) is a benign neoplasm of mesenchymal origin with varied clinical and radiographic characteristics. Its growth can be slow or aggressive without risk of metastasis. It is one of the most common jaw tumors [2].

They can cause root divergence or resorption, tooth mobility, or displacement. They are asymptomatic and can cause paresthesia or asymmetry when they reach greater size [3-4]. The World Health Organization (WHO) defines OM as a benign tumor of the jaw bones composed of stellate and elongated cells in an abundant myxoid stroma. It originates from mesenchymal or ectomesenchyme cells in the dental follicle or periodontal ligament tissue. When the tumor contains a large amount of mature fibrous tissue, terms such as fibro myxoma or myxofibroma are used. Although considered rare, OM has a similar composition to the dental pulp and periodontal ligament tissues, the second most prevalent tumor of odontogenic origin worldwide [5].

This lesion is typical in the posterior region of the jaw, especially in young adults, and can be confused with other lesions due to its "honeycomb" radiographic appearance. Treatment usually involves surgery, depending on the prognosis and size of the injury [6].

Exams such as panoramic radiography, axial computed tomography, and magnetic resonance imaging are essential for an accurate diagnosis. They can reveal an oval-shaped radiolucent area, helping to identify the OM [7].

The primary treatment for OM is surgical resection (with a margin of at least 1cm of bone tissue around the lesion) due to the high risk of recurrence in approximately 25% of cases within two years following surgery [8]. However, it can also vary depending on the injury's size, location, and extent. Treatment can be done through a surgical approach, including curettage or enucleation of the lesion, with or without a bone graft [9].

UNDER PEER REVIEW

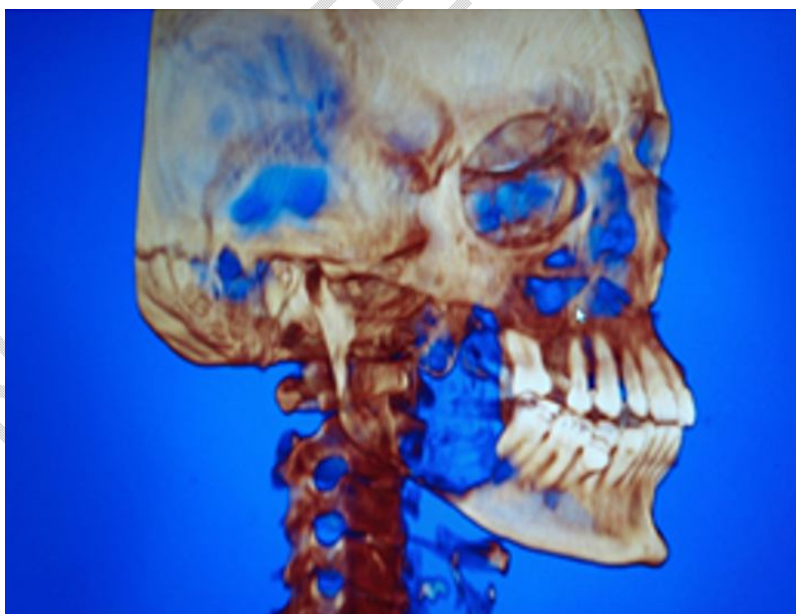
## 2. PRESENTATION OF CASE

The female patient, 38 years old and white, has had the main complaint of painless volumetric increase in soft tissues in the posterior region of the body of the mandible on the right side for two years. She was treated at the Oral and Maxillofacial Surgery and Traumatology Service in Hospital Irmandade da Santa Casa de Misericórdia in Araras, São Paulo, Brazil. She also reported intermittent episodes of paresthesia associated with the region of the right inferior alveolar nerve that had recently started, which led the patient to seek dental care.

On clinical examination, there is a slight facial asymmetry in the mandibular region on the right side in the extraoral aspect. In the intraoral aspect, a volumetric increase of fibrous consistency was observed partially covering tooth 47, extending from the right retromolar triangle region (lingual region) to the floor of the mouth. Exams such as tomography with axial and coronal sections were requested to diagnose accurately.

A multiloculated radiolucent bone lesion with diffuse limits was identified on radiographic examination. It extended from the condyle of the right mandible to the right lower second premolar, encompassing the entire extension of the alveolar ridge at the base of the mandible and the sunray appearance at the base of the jaw. On tomographic examination, a lesion with a multilocular appearance of hypodense and hyperdense areas involving the entire right hemimandible (body, angle, and branch), bone cortices with erosion and ill-defined margins, thin bone trabeculae with a perpendicular arrangement between them was observed (Figure 1).

Figure 1 Facial tomography reconstruction before surgery.



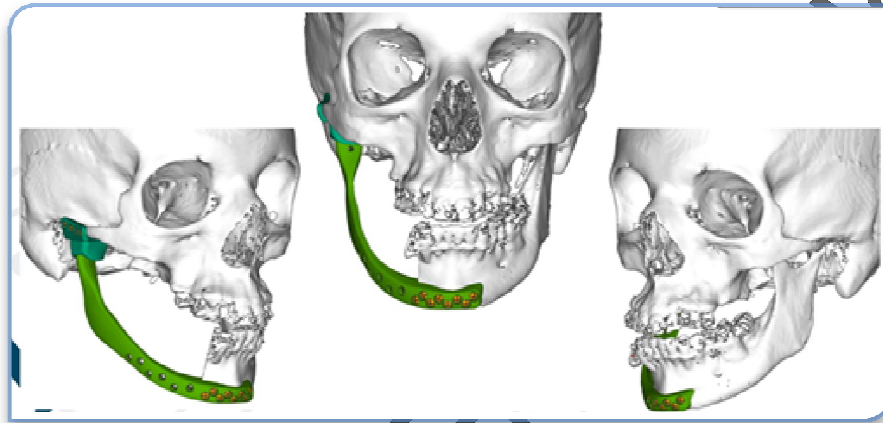
Source: Own Author

Given the clinical and imaging aspects, the diagnostic hypotheses were conventional solid or multicystic ameloblastoma, odontogenic myxoma, and osteosarcoma. Upon examination of the tomographic sections, an osteolytic lesion on the right mandible

was observed (Figure 1). Given the lesion's size, the OM treatment varies in the literature; however, the highest success rates are associated with resection, with an associated safety margin and long follow-up periods.

We opted for hemimandibulectomy with safety margins. To better delimit the margins for tumor resection and reduce surgical time, virtual surgical planning was carried out for mandibular reconstruction with a unilateral customized prosthesis (Figure 2), mandibular template on the right side, temporal template on the right side, mandibular cutting on the right side, and positioning guide on the right side.

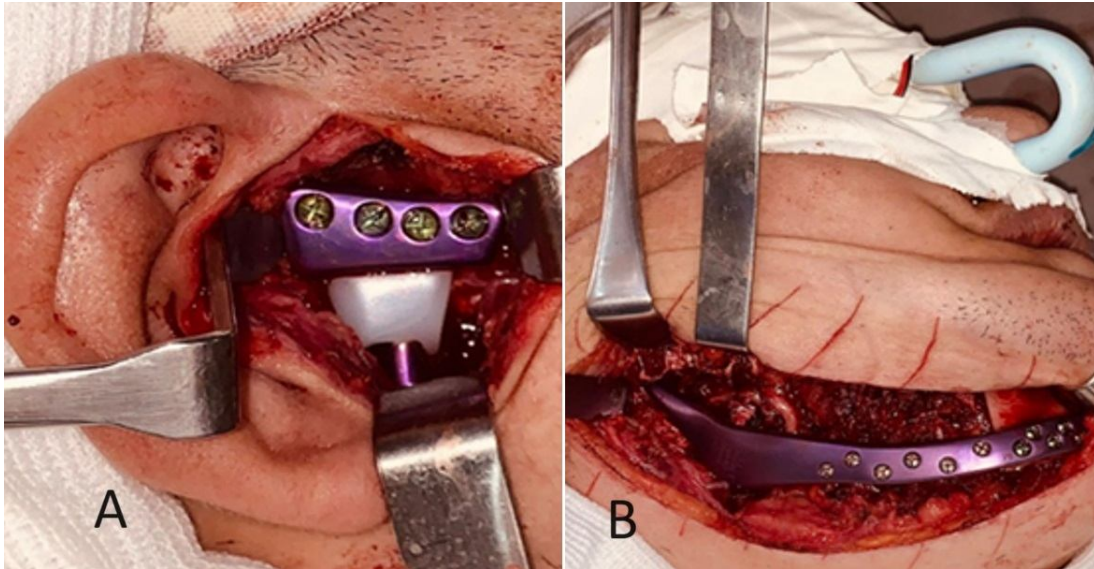
Figure 2 shows the planned reconstruction for a customized prosthesis.



Source: Own Author

The surgical procedure was performed under general anesthesia with nasotracheal intubation. A submandibular access (Risdon) was used, extending to the submental and pre-auricular regions. In the intraoral region, transoral access was performed bypassing the entire increase in tumor-like volume. After exposing the lesion, resection margins were defined. Then, the osteosynthesis plate was fixed (Figure 3A-B).

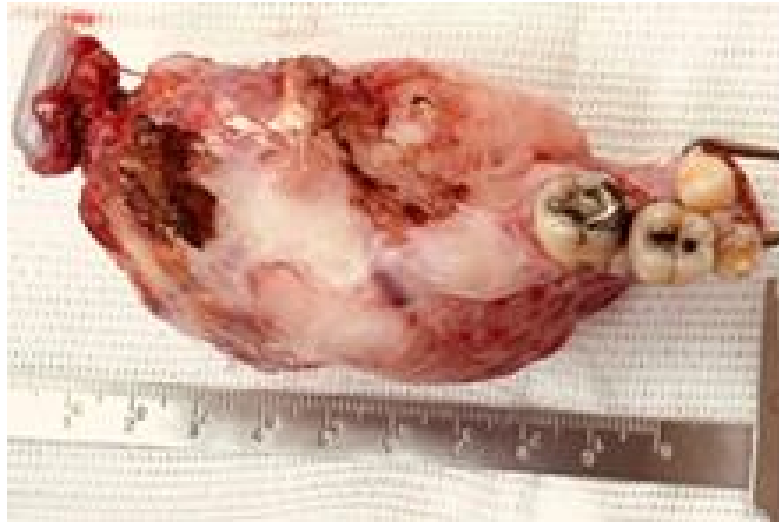Figure3 Temporomandibular joint prosthesis in position at the surgical site. B: Right hemimandible prosthesis in position at the surgical site.



Source: Own Author

The entire tumor mass was excised with safety margins in the bone and intra-oral soft tissue (Figure 4).

Figure4 Surgical piece in superior view approximately 9 cm long.



Source: Own Author

After regularizing the bone margins and irrigating the operative field, sutures were placed in the intra-oral region and, through muscular planes, in the extra-oral region with a 3.0-diameter absorbable thread. The skin was sutured with a 4.0-diameter nylon thread.

### 3. DISCUSSION

The histopathological diagnosis is fundamental [10-11], a statement corroborated by our research, as the differential diagnosis was based on histopathological analysis. CT is also essential for surgical planning [10-11]. Our research also corroborates this statement because the CT examination allowed us to perform 3D reconstruction and create a customized jaw reconstruction prosthesis.

The OM lesion affects the maxillary bone [12]. However, the present research diagnosed it in the mandible. There is no sex predilection [12]. OM slightly prefers the female sex [13], a finding corroborated by our study, as it is a female individual.

BM is a benign lesion [14] and asymptomatic [14]. As in our case report, the patient complained of painless enlargement in the jaw for two years. They disagreed, stating that the larger size of the OM is accompanied by pain and facial deformities [15].

In lesions smaller than 3cm [1,16], it is possible to perform conservative treatment, such as curettage. Above this value, surgical resection is indicated. Radical treatment [17] harms the patient's quality of life and is a significant disadvantage compared to conservative treatment. Conservative treatment is always the first choice [6]. In our research, the OM lesion was 12cm x 05cm x 06cm; therefore, the treatment was surgical resection with reconstruction [1,16]. We disagree with the findings that the radical treatment harmed the patient's quality of life [17]. Our research showed no functional or aesthetic damage because we simultaneously performed surgical reconstruction of the OM removal site with a customized prosthesis.

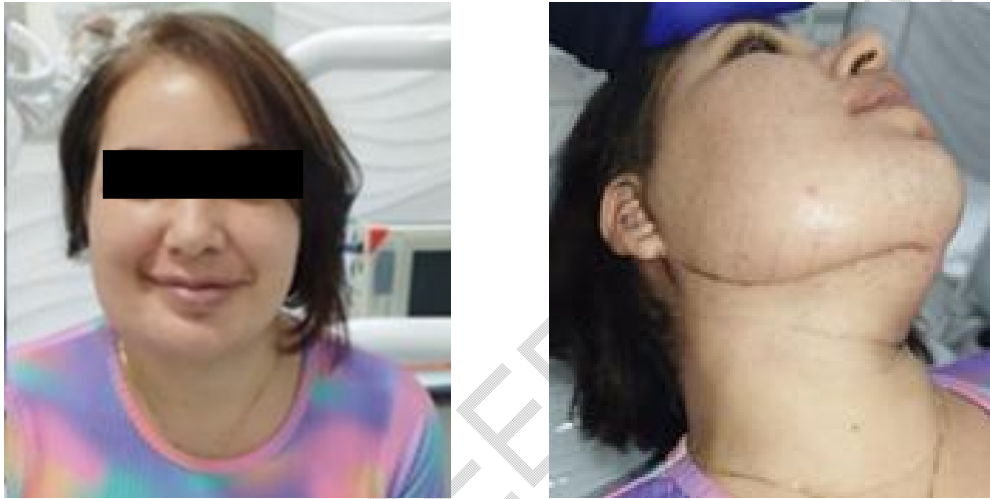Our research corroborates the fundamental importance of histopathological diagnosis [10-11]. The differential diagnosis was based on histopathological analysis, just as

CT is essential for surgical planning [10-11]. Our research also corroborates this statement because the CT examination allowed us to perform 3D reconstruction and create a customized jaw reconstruction prosthesis.

#### 4. CONCLUSION

The patient has a good outlook, with motor and chewing function return and minimal aesthetic impairment. Surgical treatment was essential to avoid recurrences, and strict patient monitoring in the first two years was crucial (Figure 5).

Figure 5 Mediate post-surgery: frontal and lower side view.



Source: Own Author

#### CONSENT

As per international standards or university standards, patient(s) written consent has been collected and preserved by the author(s).

#### ETHICAL APPROVAL

All authors declare that all experiments have been examined and approved by the Centro de Pesquisas Odontológicas São Leopoldo Mandic SS Ethics Committee, CAAE number 73287023.9.0000.5374 and have, therefore, been performed following the ethical standards laid down in the 1964 Declaration of Helsinki.

#### DISCLAIMER (ARTIFICIAL INTELLIGENCE)

The author hereby declares that NO generative AI technologies such as Large Language Models (ChatGPT, COPILOT, etc.) and text-to-image generators have been used during the writing or editing of this manuscript.

## REFERENCES

1. Melo GM; Tavares 1. TV; Curado TAF; Cherobin GB. Cervical soft tissue myxoma: Case report and review of the literature. 2008. Arq int Otorrinolaringol.:587– 90.
2. Kansy K, Juergens P, Krol Z, Paulussen M, Baumhoer D, Bruder E, Schneider J, Zeilhofer HF, Schwenzler-Zimmerer K. Odontogenic myxoma: diagnostic and therapeutic challenge in pediatric and adult patients--a case series and review of the literature. J Craniomaxillofac Surg. 2012; 40(3): 271-6.
3. Romero-Flores J, García-Huerta MA, Hernández-Miranda A. Odontogenic myxoma. Rev Med Inst Mex Seguro Soc. 2012 Jan-Feb;50(1):67-70.
4. Piatelli A, Scarano A, Antinori A, Trisi P. Odontogenic myxoma of the mandible. Report of a case and review of the literature. Acta Stomatol Belg 1994; 91:101-10.
5. Simon PT, Merckx MA, Vuhahula E, Ngassapa D, Stoelinga PJ. Odontogenic myxoma: clinical-pathological study of 33 cases. Int J Oral Maxillofac Surg. 2004 Jun; 33(4):333-7.
6. Brites FC. Odontogenic myxoma – Radical surgical treatment. Rev. Cir. Traumatol. Buco-Maxilo-Fac.2012;12(4):33–8.
7. Silveira FM; Barbosa LF; Gomes APN; Tarquinio SBC; Etges A & Vasconcelos ACU. 2017. Odontogenic myxoma: demographic profile in a Brazilian population and a review of the literature. Oral surgery, Oral medicine, Oral pathology and Oral radiology.124(2), e146.
8. Marx RE, Stern D (2003) Oral and maxillofacial pathology: a rationale for diagnosis and treatment. Quintessence Publishing, Hanover Park.
9. Nosé V, Lazar AJ. Update from the 5th Edition of the World Health Organization
10. Mourão CFAB & Júnior JWNR. Treatment for odontogenic myxoma: Literature review. 2010. Rev Bras Cir Head Neck 39(4):293-6.
11. Rowland A, Benjamin F, Athanasius-Chukwudi O, Uchenna-Kevin O, Modupeola-Omotara S. Central Myxoma/Myxofibroma of the Jaws: A Clinical-Epidemiologic Review. Iran J Otorhinolaryngol. 2017 Jan;29(90):35-42.
12. Neville; Brad W; Damm DD; Allen CM; Bouquet JE. Oral and Maxillofacial Pathology. 2009. Rio de Janeiro: Guanabara Koogan: 410-425.
13. Slootweg PJ. Maxillofacial fibro-osseous lesions: classification and differential diagnosis. Semin Diagnosis Pathol. 1996 May;13(2):104-12.
14. Chaudhary Z, Sharma P, Gupta S, Mohanty S, Naithani M, Jain A. Odontogenic myxoma: Report of three cases and retrospective review of literature in Indian population. Contemp Clin Dent. 2015 Oct-Dec;6(4):522-8.
15. Harokopakis-Hajishengallis E, Tiwana P. Odontogenic myxoma in the pediatric patient: a literature review and case report. Pediatr Dent. 2007 Sep-Oct;29(5):409-14.
16. Boffano P, 15. Gallesio C, Barreca A, Bianchi FA, Garzino-Demo P, Roccia F. Surgical treatment of odontogenic myxoma. J Craniofac Surg. 2011 May;22(3):982-7.
17. Leiser Y, Abu-El-Naaj I, Peled M. Odontogenic myxoma--a case series and review of the surgical management. J Craniomaxillofac Surg. 2009 Jun;37(4):206-9.

## ABBREVIATIONS

**OM:** Odontogenic myxoma;

**WHO:** World Health Organization.