

## Case report

### Atypical Presentation of Pre-Excited Atrial Fibrillation in an Elderly Patient: A Case Report

#### Abstract :

Pre-excited atrial fibrillation (AF) is a significant clinical condition associated with Wolff-Parkinson-White (WPW) syndrome, characterized by an accessory pathway that enables rapid conduction of atrial fibrillatory waves to the ventricles, leading to dangerously elevated ventricular rates. While WPW syndrome is typically diagnosed in younger individuals, its occurrence in elderly patients is rare and often underreported.

This case report discusses a 79-year-old male with well-controlled hypertension who was admitted for poorly tolerated irregular tachycardia with broad QRS complexes, indicative of pre-excited atrial fibrillation (AF). Urgent synchronized electrical cardioversion successfully restored sinus rhythm. Although catheter ablation was proposed as a definitive treatment, the patient chose to postpone the procedure, with close monitoring implemented afterward.

This case underscores the challenges of diagnosing WPW syndrome in elderly patients, the potential dangers of pre-excited AF, and the importance of individualized management strategies tailored to patient preferences and comorbidities.

*Keywords : Pre-excited atrial fibrillation, Wolff-Parkinson-White syndrome, Elderly patient, antiarrhythmic drugs, catheter ablation*

## **Introduction :**

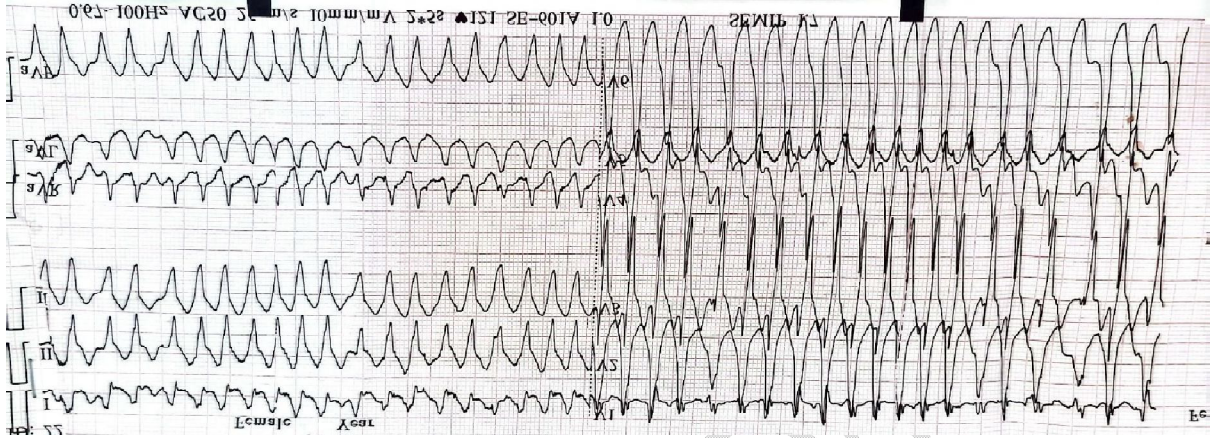
Pre-excited atrial fibrillation is a clinical entity that requires special attention due to its association with Wolff-Parkinson-White (WPW) syndrome. In patients with WPW, the presence of an accessory pathway can result in rapid transmission of atrial fibrillatory waves to the ventricles, bypassing the AV node and causing dangerously elevated ventricular rates. While WPW syndrome is typically diagnosed in younger individuals, the occurrence of pre-excited AF in elderly patients is rare and sparsely documented in the literature. This case report presents an unusual case of pre-excited AF in an elderly patient, highlighting the unique diagnostic and management challenges posed by her age and comorbidities.

## **Case Presentation:**

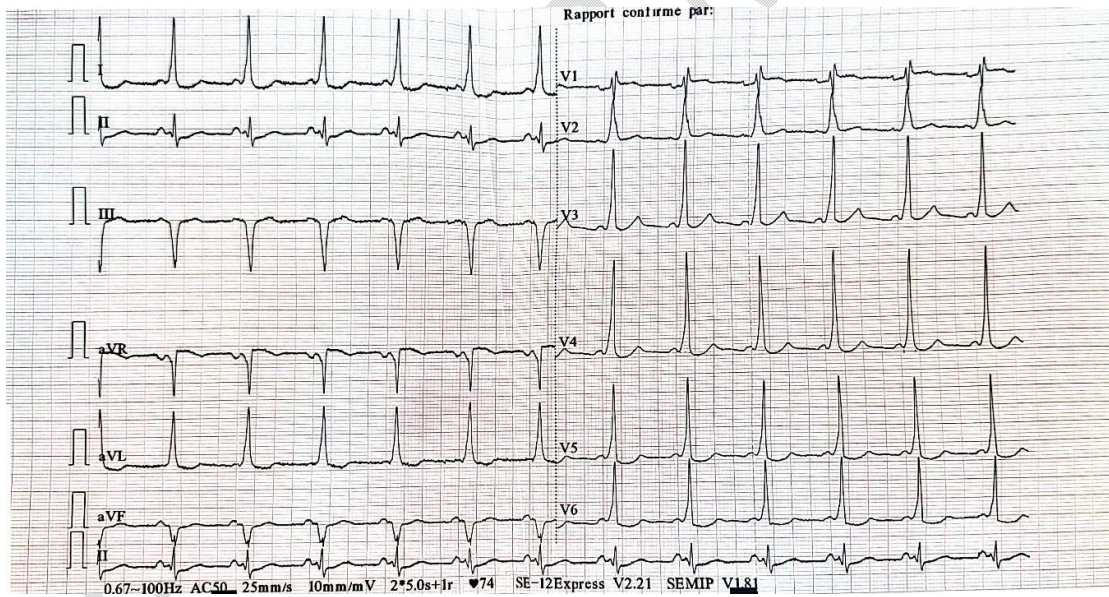
A 79-year-old male with a history of well-controlled hypertension was admitted to the emergency department with complaints of sudden-onset palpitations and dizziness. The patient denied any history of syncope or prior episodes of palpitations. Upon arrival, he was hemodynamically unstable, with a blood pressure of 85/55 mmHg and a heart rate of 200 beats per minute. The ECG revealed broad complex, irregular tachycardia, suggestive of pre-excited atrial fibrillation with varying QRS morphologies. (Figure 1) Urgent synchronized electrical cardioversion was performed at 150 joules, successfully restoring sinus rhythm. The post-cardioversion ECG showed a short PR interval and the presence of delta waves, characteristic of WPW syndrome (Figure 2). The patient was then stabilized with flecainide and beta-blockers.

Routine blood tests, including electrolytes and thyroid function tests, were within normal limits. Chest X-ray showed no cardiomegaly, and echocardiography revealed normal left ventricular function, moderate left atrial dilation, and no significant valvular abnormalities.

Although catheter ablation was recommended as the definitive treatment, the patient expressed a desire to postpone the procedure despite a clear explanation of the risks associated with sudden death and the necessity for ablation. Consequently, the patient was stabilized using flecainide and beta-blockers. This combination of treatments proved effective in maintaining sinus rhythm post-cardioversion and was well tolerated during follow-up.



**Figure 1 :** Initial electrocardiogram at emergency admission showing irregular tachycardia with a broad QRS complex related to atrial fibrillation with a rapid pre-excited ventricular response.



**Figure 2 :** The electrocardiogram after synchronized direct-current cardioversion showed sinus rhythm with a short PR interval of less than 120 ms and delta waves, suggesting Wolff-Parkinson-White (WPW) syndrome.

## Discussion

Wolff-Parkinson-White (WPW) syndrome is characterized by the presence of an accessory pathway that allows abnormal electrical conduction between the atria and ventricles, making it a rare but potentially serious cause of arrhythmias [1]. The association of WPW with atrial fibrillation (AF) is particularly concerning, as it can lead to a dangerously rapid ventricular response [2].

WPW syndrome is typically identified through distinct ECG changes that indicate ventricular pre-excitation, often referred to as the "WPW pattern." A typical ECG demonstrates a shortened PR interval (less than 120 ms), a widened QRS complex, and the distinctive appearance of a delta wave.

This condition is usually diagnosed in younger individuals, as they often present with classic symptoms such as palpitations or paroxysmal tachycardia, especially during physical or emotional stress [1]. However, as demonstrated by this case, it can also be discovered later in life. Elderly patients may remain asymptomatic until a triggering event, such as AF, reveals the condition. The subtle presentation in older adults may delay diagnosis, increasing the risk of serious complications. [3]

Several hypotheses explain why some patients remain asymptomatic until later in life. One possibility is intermittent pre-excitation, where the accessory pathway is only sporadically active, making it difficult to detect on a standard ECG. Additionally, age-related degenerative changes in cardiac tissue may reduce the functionality of the accessory pathway, which could account for the lack of earlier symptoms. [4]

In our case, even in the absence of a prior ECG confirming the lack of pre-excitation, the absence of prior palpitations or arrhythmias, along with the patient's advanced age and the delayed diagnosis, strongly indicates the presence of an intermittent form of pre-excitation. However, the onset of AF at an advanced age led to the incidental discovery of WPW after electrical cardioversion.

Atrial fibrillation in WPW patients is particularly dangerous. During AF, rapid atrial activity can be transmitted to the ventricles via the accessory pathway, bypassing the atrioventricular (AV) node [5]. This can result in an excessively fast ventricular response, increasing the risk of degeneration into ventricular fibrillation, a life-threatening arrhythmia if not treated promptly.

Managing AF in WPW patients requires careful consideration of pharmacological treatments. Current guidelines advise against the use of AV node-blocking agents, such as Adenosine, in stable cases of pre-excited AF, as they may inadvertently accelerate the arrhythmia. Instead, intravenous medications like Ibutilide or Procainamide are preferred (Class IIa, evidence level A), while Class IC drugs such as Flecainide or Propafenone are also recommended (Class IIb, evidence level B) [6]. If these drugs are unavailable, intravenous Amiodarone may be considered, though close monitoring is essential due to its effects on AV conduction [7]. For hemodynamically unstable patients, synchronized direct current (DC) cardioversion is the first-line treatment (Class I), as was the case with our patient. [6]

The choice of beta-blockers for the long-term treatment of our patient was based on their potential to enhance the efficacy of rhythm control when used in combination with flecainide. Although beta-blockers are generally avoided in patients with pre-excited atrial fibrillation due to the risk of ventricular fibrillation, their use can be considered in patients with an accessory pathway that has a short refractory period. Studies have shown that the concomitant administration of beta-blockers and class IC antiarrhythmics, such as flecainide, improves long-term efficacy and reduces the recurrence of arrhythmias. This therapeutic approach is particularly beneficial for patients in whom ablation cannot be performed. It allows for better rate control and improved symptom management while minimizing the risk of rapid ventricular responses. (8)

Catheter ablation is the definitive treatment for WPW syndrome, particularly in patients with recurrent episodes of pre-excited AF or symptomatic arrhythmias. Ablation eliminates the accessory pathway, effectively reducing the risk of future arrhythmias and improving quality of life. The procedure is generally well-tolerated, especially in younger patients. [9]

However, in elderly patients or those with significant comorbidities, the decision to proceed with ablation requires careful consideration. While the risks associated with the procedure are low, older patients may have a different risk profile, necessitating a thorough assessment of their overall health and preferences. For patients who opt to defer ablation, close monitoring and a well-structured medical management plan are essential to prevent complications.

## Conclusion

In summary, this case highlights a rare but serious presentation of pre-excited atrial fibrillation in an elderly patient. The complexity of diagnosing and managing arrhythmias in older adults necessitates an individualized approach that takes into account both the clinical findings and patient preferences. Continued follow-up and patient education will be critical for optimizing outcomes and ensuring appropriate management of this condition.

## Ethical Approval:

As per international standards or university standards written ethical approval has been collected and preserved by the author(s).

## Consent :

As per international standards or university standards, patient(s) written consent has been collected and preserved by the author(s).

## Disclaimer (Artificial intelligence)

Author(s) hereby declare that NO generative AI technologies such as Large Language Models (ChatGPT, COPILOT, etc.) and text-to-image generators have been used during the writing or editing of this manuscript.

## REFERENCES

1. Wolff L, Parkinson J, White PD. Bundle-branch block with short P-R interval in healthy young people prone to paroxysmal tachycardia. *Ann Noninvasive Electrocardiol.* 1930;11(4):340-53.
2. Fengler BT, Brady WJ, Plautz CU. Atrial fibrillation in the Wolff-Parkinson-White syndrome: ECG recognition and treatment in the ED. *Am J Emerg Med.* 2007;25:576-83.
3. Brebilla-Perrot B, Houriez P, Beurrier D, Louis P, Boursier M, Khalifé K. Atrial fibrillation with a very rapid ventricular response as the first clinical arrhythmia in a 76-year-old man. *Pacing Clin Electrophysiol.* 2003;26(8):1769-1770. doi:10.1046/j.1460-9592.2003.t01-1-00266.x.

4. Brembilla-Perrot B, Yangni N'da O, Huttin O, Chometon F, Groben L, Christophe C, Benzaghoul N, Luporsi JD, Tatar C, Bertrand J, Ammar S, Cedano G, Zhang N, Beurrier D. Wolff-Parkinson-White syndrome in the elderly: clinical and electrophysiological findings. *Arch Cardiovasc Dis.* 2008;101(1):18-22. doi:10.1016/s1875-2136(08)70250-x.
5. Centurión OA. Atrial fibrillation in the Wolff-Parkinson-White syndrome. *J Atrial Fibrillation.* 2011;4(1):899-915.
6. Brugada J, Katritsis DG, Arbelo E, et al. 2019 ESC guidelines for the management of patients with supraventricular tachycardia: The Task Force for the Management of Patients with Supraventricular Tachycardia of the European Society of Cardiology (ESC). *Eur Heart J.* 2020;41:655-720.
7. Ren J, Yang Y, Zhu J, Wu S, Wang J. The use of intravenous amiodarone in patients with atrial fibrillation and Wolff-Parkinson-White syndrome. *Pacing Clin Electrophysiol.* 2020;44:35-43.
8. Jae-Jin K, Doh JH, Lee SY. Effects of bisoprolol and flecainide in an elderly patient with paroxysmal supraventricular tachycardia and atrial fibrillation in Wolff-Parkinson-White syndrome. *Int J Clin Cardiol.* 2019;6:138. doi:10.23937/2378-2951/1410138.
9. Sherdia AF, Ali SAA, Abdelaal SA, et al. The success rate of radiofrequency catheter ablation in Wolff-Parkinson-White syndrome patients: A systematic review and meta-analysis. *Indian Heart J.* 2023;75:98-107.