

# Obstetric Frontal Head Trauma in a Newborn: Case Report and Literature Review"

## **Abstract**

Obstetrical cranial trauma can be responsible for extracranial hematomas, cranial fractures, and intracranial hematomas. It is diagnosed early, either after a normal vaginal or instrumental delivery, and rarely during Caesarean deliveries. It is most often located at the parietal level and very rarely at the frontal level. It results from the association between the force of uterine contractions, manual uterine trans-abdominal compression, presentation, and abrupt passage into the bony pelvis. It can affect all structures of the fetal head. In most cases, it resolves spontaneously. Neurosurgical treatment is rare. We present the clinical case of a 1-day-old girl, presenting with a significant depression of the left frontal bone with a very large central fracture, who was operated on with a good surgical outcome. Head trauma can occur at birth and can be described in normal childbirth. Resorption is generally spontaneous, but rare cases are surgical with a good prognosis.

**Keywords:** Obstetrical head trauma, Newborn

## **Introduction**

Obstetric cranial trauma refers to the traumatic lesions of the fetal head structures (scalp, skull, brain, and its ventricles) occurring during childbirth. During birth, the infant's head is exposed to contractions of the uterine muscles and intra-abdominal pressure, and must cross a bony pelvis. These mechanical influences cause transient physiological or enduring pathological changes to the skull. The skull deformities vary according to the size of the pelvic opening; thus, the modeling of the head allows a non-traumatic passage through the bony pelvis.(1) However, despite this modeling of the head, instrumental childbirth, the speed of descent of the baby in the pelvis, and abnormal cephalic presentations (cephalic, facial, breech) can cause cranial trauma during childbirth. These traumas can affect either extracranial structures, the skull, or intracranial structures (2).

**The mechanisms that can cause birth trauma are mechanical (compressive and traction forces) or hypoxic-ischemic. The most important risk factors for birth trauma include: instrumental delivery (e.g., forceps or vacuum extraction), primiparity, cephalopelvic disproportion, birth weight more than 4 kg or less than 2.5 kg, oligohydramnios, prolonged delivery, prolonged or unusually rapid labor, maternal pelvic anomalies, fetal malformations, abnormal presentations such as breech presentation, and prematurity. We present a clinical case of frontal embasure fracture after vaginal delivery in term pregnancy with normal birth weight**

## Case Presentation

BB X, 1 day old, was seen in consultation for a depression of the frontal cranial vault observed at birth without any history of a fall or trauma. She is the 3rd of 3 siblings, born vaginally in cephalic presentation from a full-term pregnancy of 39 weeks, well monitored with obstetric ultrasound (Fig. 1) showing no cranial anomaly. The mother reported that labor and delivery lasted approximately 5 hours, with manual abdominal pressure applied by the midwife at the last minute of expulsion. Apgar score was 10/10, birth weight 3250g. There was no mention of the color of the amniotic fluid or the position at delivery.

On physical examination, the child was conscious and tonic, with a left frontal depression and archaic reflexes. A cerebral CT scan (Fig. 2) with a bone window showed a depression of the left frontal bone with a continuity gap in its center, suggesting an obstetric traumatic pot-bearing fracture.

The child underwent surgery on Day 7 to remove the embasure, with an intraoperative incident marked by a wound in the frontal sagittal sinus, which was corrected. The post-operative course was good, with a small healing defect (Fig. 3). The follow-up CT scan showed good correction of the embasure fracture (Fig. 4).

The notion of obstetrical cranial trauma dates back to antiquity. [Hippocrates \(460-377 B.C.\)](#), [Shakespeare \(1564-1616\)](#), [Little \(1819-1894\)](#), and [Gowers \(1888\)](#) described that certain cerebral pathologies of infancy, such as epilepsy, infantile convulsions, cerebral palsy, and diplegia, were closely related to dystocia<sup>1</sup>. [Salomonsen \(1928\)](#) emphasized that even a normal delivery represents a trauma to the infant: "The traumatic effects of labor upon the brain give rise to demonstrable lesions in such a large proportion of cases that it attains the character of a physical law"<sup>12</sup>. It was not until the beginning of the 19th century that attention was drawn to the fact that there might be a connection between head injuries occurring during delivery and pathological conditions of infancy. No other complications observed as described in the literature.

## Discussion

Birth injury is defined as a condition that affects neonate's structure and function caused by an adverse event at birth. It is often used interchangeably with 'birth trauma'.(3), this birth trauma can involve several organs: the clavicle, humerus, skull, femur and ribs. The incidence of birth injury is known to be about 2% for, normal vaginal delivery and 1% for cesarean delivery. Since the head is the first part to enter the birth canal during delivery, it is one of the most vulnerable area to birth injury (2,4, 5). In the work of Andreas Rehm et al, it is the third most common obstetric trauma after that of the clavicle and humerus(6).

The mechanism of fractures: When the pregnancy reaches term, the foetus passes into the maternal pelvis in vertex presentation, the head is flexed with the chin resting on the chest, allowing for the smallest diameter under the occipito-bregma. As the foetal head descends into

the pelvic cavity, the shape of the head changes to facilitate the relationship between the size of the foetal head and the diameters of the pelvis. This shaping is achieved by overlapping the sutures, giving a trapezoidal shape that allows passage through the birth canal. No force is exerted on the sagittal sinus or cortical bridging veins, so in a normal delivery, the force of uterine contraction exerts pressure on the foetus as it passes through the bony pelvis without any trauma. Thus Skull of the newborn can be moulded during delivery and is resistant to fracture because it is separated into several, bones (2, 7). However, although it is rare, skull fracture could occur at birth if there are difficulties during delivery. The overall fracture incidence was 2-3.7 per 100000 live births (8,9). Some insist on that this data is underestimated because of undetected clinically silent simple linear fractures (2).

Difficulties leading to trauma may arise:

- In poor cephalic presentations occur when there is deviation of the foetal head, resulting in facial presentations (frontal, chin). The presentation is determined by the contractile force of the uterus, and this can lead to craniofacial trauma during delivery.
- In the powerful force of close contraction of the uterus, the effect of excessive moulding can cause the parietal bone to impact on the pelvis, resulting in trauma to this bone by sinking, the degree of sinking depending on the force of contraction of the uterine muscles. This depression may be accompanied by a fracture. The presence of the left frontal depression in our patient is due to poor presentation. Should deformation occur abruptly and be severe, intracranial bleeding may result from tearing of the falx cerebri and the tentorium cerebelli, or tearing of the bridging veins draining the cortical surface into the venous sinus (Figure 2). An excessive moulding effect may cause scalloping of the parietal bones, contributing to the traumatic mechanism to the fetal head. Infants with dolichocephaly suffer an especially severe configuration. In such cases, the changes in sutures and fontanelles are more distinct. It has been suggested that during breech delivery, occipitalosteodiasis, a separation of the squamous and lateral portions of the developing occipital bone, is caused by pressure from the pubic symphysis against the suboccipital region; however, this may also occur during forcible engagement of the head (2,8,10, 4,11).
- In cephalopelvic disproportion, the power of uterine contraction, as well as uterine Trans abdominal manual pressure manoeuvres can lead to rapid expulsion of the foetus with head trauma in cephalic presentation(1,3)

in short, the delivery process is a combination of compression, contraction and traction forces, when the size of the foetus, its presentation and neurological immaturity complicate the event. This can lead to tissue damage, edema and hemorrhage, or fractures in the newborn. The use of instruments can further amplify the effects of these forces, or can themselves cause trauma. In fact 46% of birth related skull fractures are associated with vacuum-assisted vaginal delivery in the work of (2,8).

Obstetric head trauma includes: extra cranial trauma constitutes the type of hematoma: caput succedaneum (bleeding between the skin and the galea), subgaleal hemorrhage (hematoma in the space between galea aponeurosis and periosteum) and cephalohematoma (accumulation of hematoma in the (1,2, 12.13)) .

Our patient had a depression of the left frontal cranial vault associated with a linear fracture in the center of the depression, no extracranial or intracranial lesions were associated.

Factors predisposing injury include: primigravida, cephalopelvic disproportion, small maternal stature, maternal pelvic anomalies, prolonged or rapid labor, transverse arrest of descent of the presenting part of the fetus, oligohydramnios, abnormal presentation, instrumental delivery, versions and extractions, very-low -birth-weight infant or extreme prematurity, fetal macrosomia, large fetal head, and other fetal anomalies, delivery during risk hours, parity Cesarean delivery was the only protective factor of BT (1, 14).

Our patient is the 3rd of a family of 3 born vaginally after a precipitous labor of 4 hours, with manual trans-abdominal uterine pressure on abnormal frontofacial presentation. The combination of these factors described above would be responsible for the sudden pressure of the left frontal region on the promontory of the pelvis leading to violent pressure of the frontal bone on the promontory, reflecting the frontal cranial depression associated with a central linear fracture, without associated extra or intracranial lesion.

Diagnostic :The diagnosis of traumatic cranial depression is made immediately after childbirth and sometimes a few days later, after returning home, it is often linked to instrumental deliveries such as forceps where parietal depressions are observed and are often described in the normal deliveries like the case of our patient(2).

Additional examinations include: imaging, biological examinations, and sometimes EEG.

Imaging: Depending on the doctor's experience, standard radiography is sufficient to make the diagnosis of fracture lines, anatomical sutures, after any day of observation of the baby, if it is normal, no other examination is useful for the diagnosis of fracture, Cella prevents subjecting the newborn to a lot of radiation (2, 13, 15). Extra cranial hematoma is dominated by cephalohematoma. It concerns 0.5 to 1.5% of all births (50% of obstetric trauma (16-16)), is sometimes associated with skull fracture, the association of fracture with intracranial hematoma is very rare, in cases of very significant depression associated with an abnormal examination of the baby, brain CT with 3D reconstruction is indicated in order to assess the fracture lines and intracranial lesions which may be associated (7) without increasing exposure to irradiation (17-17).The Computed tomography (CT) and magnetic resonance imaging (MRI) is useful for the evaluation of intracranial lesions, however, it should be performed in consideration of the patient's clinical conditions and necessities.

Transfontanellar ultrasound is the most easily performed examination in this context. Unfortunately it remains an unreliable test. The lesions encountered are most often extracerebral and located in the occipital region or in the posterior fossa, which increases the risk of false negatives (18).

In intraparenchymal hematoma, it is necessary to perform a coagulopathy (2)

Finally, the EEG shows focal abnormalities of the electrical trace which have a lesion localizing value and diffuse anomalies of the trace which are the translation of cerebral suffering (19)

In view of the importance of the depression, the head trauma in our patient being only bony, without extra or extra cranial lesion associated with a central fracture line. Although this was observed at birth, it was not a malformation given that the prenatal ultrasound showed a head without any deformation.

Treatment: The treatment of obstetric head trauma depends on the degree of the injury

In extracranial hematomas, Treatment is usually conservative observation until absorption. Aspiration and drain are generally ineffective for clotted blood and not recommended due to the potential risk of infection; Caput succedaneum absorbed within a few days and requires no treatment (2), the prognosis of Subgaleal hematoma is usually good, involves watchful observation and correction of hypovolemia and anemia. Surgical evacuation is performed when massive subgaleal hematomas produce neurological deteriorations with the evidence of increased intracranial pressure on images (1,2,20,21) Cephalhematoma, cephalhematoma resolves spontaneously within a few days, but in some cases, it may take several weeks(22). In those cases, calcification may also occur from collected blood. If disfiguration is severe, surgical treatment could be considered (2,23 ,24).

Rarely, cephalhematoma becomes infected even without laceration or abrasion (2,25) the major causative organism is Escherichia coli, It could be accompanied by osteomyelitis, meningitis, or sepsis. When infected cephalhematoma is suspected, diagnostic aspiration should be performed(2,26).

The Fracture SKULL traitement: the Linear fractures are of no clinical importance and therapy is indicated unless any of the above-mentioned associated lesions are present. Follow up is necessary when the skull fracture present with diastasis between its edges.

We must be cognizant of growing skull fractures. Even in the cases of depressed skull fracture, most of them can be resolved spontaneously; Spontaneous elevation has usually corrected the depressed bone by the three-month follow-up. Usually, there is no need for surgery or any other form of therapy. There have been reports of elevation by vacuum extractor, breast pump, and digital pressure. Surgical reduction could be considered depending on its severity. When neurosurgical expertise is available and digital compression or breast pumping has been

unsuccessful, operative elevation should be undertaken (1,2). Some authors recommend making a 1 cm incision to lift the emporment; in the case of our patient, the depression was significant, the 1 cm incision did not allow the emporment to be lifted, we had to enlarge the frontal incision to lift the emporment fracture. Intracranial hemorrhages treatment: with the obstetrical epidural hemorrhage, subdural hemorrhage, Intraventricular hemorrhage (IVH) and periventricular leukomalacia (PVL). The less invasive treatment is the most advisable, in the less abundant bleeding without mass effect, the monitoring and compliance is the therapeutic choice, the recourse to surgical treatment is indicated only in the hematomas exerting a mass effect on the cerebral structures, with an abnormal clinical examination, in the subarachnoid hemorrhage. the Complications of primary subarachnoid hemorrhage in the newborn are difficult to identify, except for hydrocephalus. Adhesions around the cisterna magna and the fourth ventricle may result in an obstruction to CSF circulation; the occurrence of hydrocephalus requires surgical treatment, the same is true for intraventricular hemorrhages where the only occurrence of hydrocephalus requires neurosurgical treatment. As for intracerebellar hemorrhage, cerebral contusion, monitoring and sequelae occurred such as epilepsy, delayed psychomotor development are taken care of medically or in rehabilitation, the surgical indication arises only in the very rare cases of occurrence of associated hydrocephalus. Severe neonatal head injuries are rare, and most neonatal head injuries have a favorable outcome (21, 27),

### Conclusion:

Obstetric head trauma, or birth trauma are diagnosed very early from birth, they are described in vaginal deliveries, with or without instruments, very rare cases have been described in cesarean deliveries they are rare and generally have a good prognosis. The injuries are mostly minor and resolve spontaneously, surgical treatment is exceptional and reserved for symptomatic cases and more severe cases.

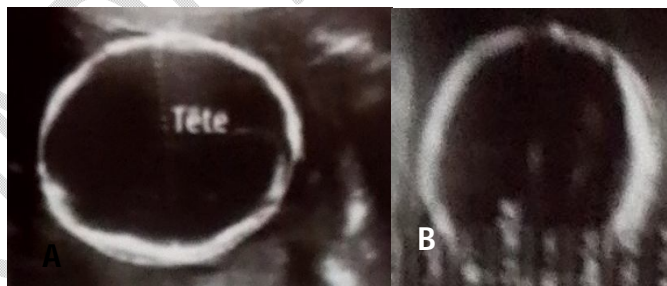
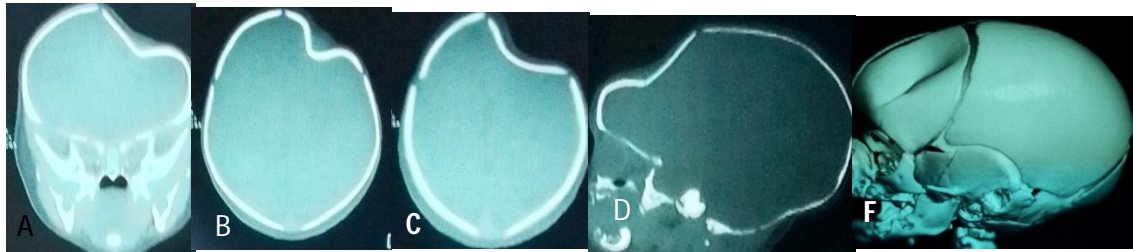
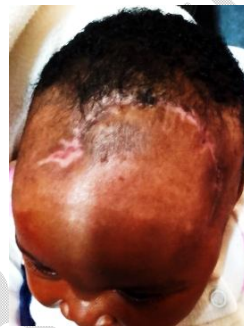

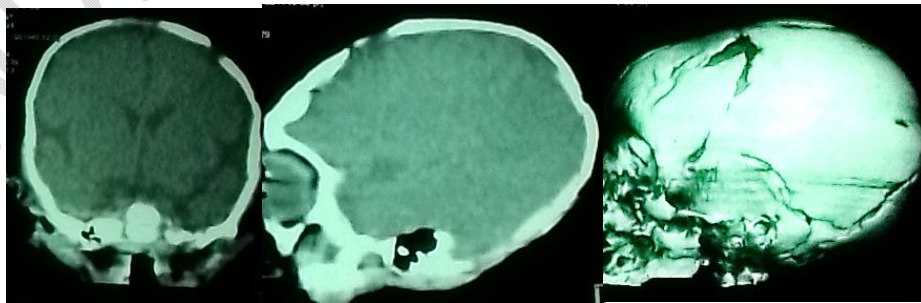
Fig 1 A et B : prenatal ultrasound



**FIG 2 :** Preoperative CT scan in bone window A coronal section, B and C axial section, D sagittal section, E reconstruction3D



• **FIG 3** Postoperative scar



**Fig 4 :** Postoperative control scanner : A coronal section, B axial section, C reconstruction

A

B

## References

- 1) Nicollas Nunes Rabelo, Hamilton Matushita, Daniel Dante Cardeal Nunes Rabelo, Hamilton Matushita, Daniel Dante Cardeal , Traumatic brain lesions in newborns. *ArqNeuropsiquiatr* 2017;75(3):180-188
- 2) Sangjoon Chong, Head Injury during Childbirth, Review Article, *J Korean Neurosurg Soc* 65 (3) : 342-347, 2022, <https://doi.org/10.3340/jkns.2022.0045> pISSN 2005-3711 eISSN 1598-7876
- 3) Moloy HC. Studies on head molding during labor. *Amer J Obstet Gynec.* 1942;44(5):762-82. [https://doi.org/10.1016/S0002-9378\(15\)30603-7](https://doi.org/10.1016/S0002-9378(15)30603-7)
- 4) Davis DJ : Neonatal subgaleal hemorrhage: diagnosis and management. *CMAJ* 164 : 1452-1453, 2001
- 5) Alexander JM, Leveno KJ, Hauth J, Landon MB, Thom E, Spong CY, et al. : Fetal injury associated with cesarean delivery. *ObstetGynecol* 90 :885-890, 2006
- 6) Andreas Rehm , Prakash Promod , Amanda Ogilvy-Stuart, Original Articles Neonatal birth fractures: a retrospective tertiary maternity hospital review, *J ObstetGynaecol.* mai2020 ; 40(4):485-490. DOI : 10.1080/01443615.2019.1631770. Epub 3 septembre 2019
- 7) Merhar SL, Kline-Fath BM, Nathan AT, Melton KR, Bierbrauer KS : Identification and management of neonatal skull fractures. *J Perinatol* 36 :640-642, 2016.
- 8) Högberg U, Fellman V, Thiblin I, Karlsson R, Wester K : Difficult birth is the main contributor to birth-related fracture and accidents to other neonatal fractures. *Acta Paediatr* 109 : 2040-2048, 2020
- 9) Dupuis O, Silveira R, Dupont C, Mottolese C, Kahn P, Dittmar A, et al. : Comparison of "instrument-associated" and "spontaneous" obstetric depressed skull fractures in a cohort of 68 neonates. *Am J ObstetGynecol* 192 : 165-170, 2005
- 10) Cieplinski JAM, Bhutani VK : Lactational and neonatal morbidities associated with operative vaginal deliveries. 1191. *Pediatric Research* 39 :201, 1996
- 11) Demissie K, Rhoads GG, Smulian JC, Balasubramanian BA, Gandhi K, Joseph KS, et al. : Operative vaginal delivery and neonatal and infant adverse outcomes: population based retrospective analysis. *BMJ* 329 :24-29, 2004
- 12) Zalatimo O, Ranasinghe M, Dias M, Iantosca M. Treatment of depressed skull fractures in neonates using percutaneous microscrew elevation. *J NeurosurgPediatr.* 2012;9(6):676-9. <https://doi.org/10.3171/2012.2.PEDS11304>
- 13) Weiner EJ, McIntosh MS, Joseph MM, Maraga N, Davis PG. Neonatal scalp abscess: is it a benign disease? *J Emerg Med.* 2011;40(5):e97-101. <https://doi.org/10.1016/j.jemermed.2009.08.019>

- 14) Nechama Linder,IdoLinder,ElenaFridman,FrankKouadio,DanielLubin,PaulMerlob Birth trauma – risk factors and short-term neonatal outcome Research article The Journal of Maternal-Fetal and Neonatal Medicine Issue 15,Volume 26, 2013 –
- 15) Martin A, Paddock M, Johns CS, Smith J, Raghavan A, Connolly DJA, et al. : Avoiding skull radiographs in infants with suspected inflicted injury who also undergo head CT: “a no-brainer?” EurRadiol30 : 1480- 1487, 2020
- 16) Mr. Zerah, obstetric head trauma, Extract from the Neurosurgery Campus  
<http://campus.neurochirurgie.fr/spip.php?article421>, January 2009.
- 17) Orman G, Wagner MW, Seeburg D, Zamora CA, Oshmyansky A, Tekes A, et al. : Pediatric skull fracture diagnosis: should 3D CT reconstructions be added as routine imaging? J NeurosurgPediatr16 : 426-431, 2015.
- 18) J S Wigglesworth, R P Husemeyer Intracranial birth trauma in vaginal breech delivery: the continued importance of injury to the occipital bone, Br J ObstetGynaecol. 1977 Sep;84(9):684-91. doi: 10.1111/j.1471-0528.1977.tb12681.x.
- 19) Comité éditorial pédagogique de l'UVMaF , Les traumatismes obstétricaux, Université Médicale Virtuelle Francophone2011-1012,
- 20) Amar AP, Aryan HE, Meltzer HS, Levy ML : Neonatal subgalealhematomacausing brain compression: report of two cases and review of the literature. Neurosurgery 4 : 1470-1474, 2003
- 21) NiccolòParri, Martina Giacalone, Marco Greco, Arianna Aceti, ErsiliaLucenteforte, IuriCorsini, Prise en charge des traumatismes crâniens néonataux : une étude de cohorte rétrospective le groupe de recherche sur la prévention des blessures au néon (NATIVE) Acta Paediatrica ;ORIGINAL ARTICLE, Acta Paediatrica , Première publication : 23 septembre 2024 <https://doi.org/10.1111/apa.17420>
- 22) Mangurten H, Puppala B: Birth injuries. Fanaroff and Martin's Neonatal Perinatal Medicine- Diseases of the Fetus and Newborn, ed 8. Philadelphia: Mosby Elsevier, 2006, pp.529-559.
- 23) Ulma RM, Sacks G, Rodoni BM, Duncan A, Buchman AT, Buchman BC,et al. : Management of calcified cephalohematoma of infancy: the University of Michigan 25-year experience. PlastReconstr Surg 148 :409-417, 2021
- 24) Wong CH, Foo CL, Seow WT: Calcified cephalohematoma: classification,indications for surgery and techniques. J Craniofac Surg 17 :970-979, 2006.
- 25) Chang HY, Chiu NC, Huang FY, Kao HA, Hsu CH, Hung HY: Infected cephalohematoma of newborns: experience in a medical center in Taiwan. Pediatr Int 47: 274-277, 2005
- 26) LeBlanc CM, Allen UD, VentureyraE : Cephalhematomas revisited. When should a diagnostic tap be performed? Clin Pediatr (Phila) 34 : 86-89, 1995.

27)Abdul Razak, Waseemoddin Patel, Naveed Ur Rehman Durrani,,corresponding author and Abdul Kareem Pullattayil, MIST

Interventions to Reduce Severe Brain Injury Risk in Preterm Neonates

A Systematic Review and Meta-analysis

UNDER PEER REVIEW