

Ameliorative Effects of Ascorbic Acid on *Bridelia micrantha* Induced Haematological, Histological and Carcass Characteristics Alterations in African Catfish *Clarias gariepinus*, Burchell(1822) Juvenile.

Abstract

Chronic exposure of ichthyotoxic plant *Bridelia micrantha* (BM) during fishing of African Catfish *Clarias gariepinus* juvenile causes alterations in haematological, histological and proximate composition of the carcass. The recovery of *C. gariepinus* from *Bridelia micrantha* (BM) was evaluated by exposing *C. gariepinus* to a 60-days depuration, by placing the fish on ascorbic acid (AA)-supplemented diet at concentrations of 0.00, 25, 50, 75, 100, 125 mg/l. After 60-days depuration some of the lesions in histological, haematological and proximate composition of the carcass attained different stages of recovery. Ascorbic acid administration at the highest concentration of 125 mg/l completely reversed the lesions in tissue, blood and nutrients composition as compared to the control. Histological alterations in *C. gariepinus* exposed to *Brandelia micrantha* after 60 days at highest concentration of 0.21 mg/l shows severe effect on the gill architecture with hypertrophy of the gill arch, gill filament degeneration and aggregate of inflammation (AI), the liver shows moderate to severe effect on the hepatic tissue with severe effect on the hepatic tissue with severe ground glass (GG) appearance of the cytoplasm and intra hepatic hemorrhage (IHH) while the kidney shows severe degeneration of the renal tissue with severe intra renal necrosis (TN) and inflammatory cell aggregate (IC) with tubular atrophy (TA) in some areas. Ascorbic Acid administration to *Bridelia micrantha* (BM) exposed fish at 125 mg/l partially and completely reversed the lesions, the gill shows normal gill architecture with well projected filament (PF), gill epithelium (GE) and cartilages (C), liver shows normal hepatic architecture with normal hepatocyte (H) and central vein (C) while the kidney shows normal renal architecture with active glomeruli (G) renal tubules (RT) and tubular cell (TC). The ameliorative effect of AA on *C. gariepinus* organs, blood and carcass increased with increase in concentration and exposure time. The 125 mg/l AA dietary supplementation have the potency to ameliorate the *Bridelia micrantha* (BM) induced pathological lesions in *C. Gariepinus* juvenile.

KEY WORD: - Ameliorative Effect, Ascorbic acid, *Bridelia micrantha*, Haematology, Histopathology, Proximate composition, Catfish *Clarias gariepinus*

Introduction

Fish poisons are widely used for cultural, commercial, and environmental reasons, the frequent use of Ichthyotoxic plants to catch fish is part of the traditional fishing method which is not 'environmentally friendly' to the aquatic ecosystem (Connell 1999, Ayotunde and Igbang 2023). Plant Ichthyotoxic are among the widely used fishing method which is biodegradable and less severe than Ichthyotoxic piscicides (OECD (1992, Onusiriuka and Ufodike, 1998, Ayotunde 2019). In Africa more than 325 fishing poison plant species are commonly used to catch fish (Neuwinger, 2004). The mechanism of action of ichthyotoxic plants varied from cytotoxicity (they act by causing cell death) to genotoxicity (they are able to produce their effect by altering gene expression) generally, toxicants produce their effects by interference with physiological or biochemical homeostatic (regulatory) mechanisms. Some of them can modify the regulation of cell division with harmful effects. Many toxic chemicals cause proliferative lesions on the skin of the organism. Plant-based ichthyotoxins are fish poisons derived from plants (Vimal and Das 2015) and active

ingredients commonly detected in such plants include alkaloids, tannins, saponins, flavonoids, resin and phenolics (Fafioye 2005, Gill, 1992).). The active ingredients in *Bridelia micrantha* are triterpenoid saponins and rotenoids with rotenone being the most widely used commercially. Some other poisons include sesquiterpenes, diterpenoids, including diterpenoid orthoesters, triterpenes, furanocoumarins, 2-hydroxy-5-methoxy-3-undecyl-1,4-benzoquinone, prenyl phenyl propanoids, and sterol acylglucosides (Cannon *et al.*2004. Osuagwu, and Ibeabuchi, 2010).The great variety of chemical structures presents many interesting questions regarding the relative toxicity, biochemical mechanisms, and environmental effects of fish poisons(Amoatey and Baawain 2019).

The use of haematological, histological and proximate composition of carcass as biomarker is one of the most effective methods of assessing pollutant-induced oxidative stress in aquatic organisms however information on fish recovery after ichthyotoxic exposure is obscured. Adhikari *et al.*,(2004) stated that an understanding of fish recovery time after toxicant exposure could help in the maintenance of fish health status and that of its consumers. Fish, like higher vertebrates, are generally endowed with an antioxidant system with which they eliminate free radicals generated by the reactive oxygen species ROS and recovered from oxidative stress. This system comprises enzymatic - superoxide dismutase and catalase and non-enzymatic - α tocopherol (vitamin E) and ascorbic acid (vitamin C) antioxidants. Vitamin C is a chain-breaking, least toxic, most effective and widely used antioxidant that react with free radicals (Bielski, 1982), and thus, protects animals against oxidative damage (El-Keredy *et al.*, 2017). As important as it is, not all fish species are capable of synthesizing vitamin C. They, therefore, depend on exogenous sources to meet their requirements. Several reports are available on dietary efficacy of vitamin C in ameliorating pollutants toxicity to fish (El-Keredy *et al.*, 2017). During laboratory studies, fish are usually returned to toxicant-free water after an exposure to initiate 'self' detoxification process sufficient to reverse any morphological, biochemical or physiological changes arising from such exposure. Earlier studies have shown that, after exposure, the normal physiology of fish could either be moderately restored (Ayotunde 2019, Adhikari *et al.*, 2004; Ramesh *et al.*, 2015) or fully restored (Maltez *et al.*, 2017) when relocated to water free of toxicant.

The African catfish *Clarias gariepinus* is a commercially important fish in Nigeria (Okechi 2004, Ayotunde and Ofem 2008, Suleiman *et al.*, 2015; Ayotunde and Igbang 2023), it is a large, eel-like fish, usually of dark gray or black colouration on the back, fading to a white belly. It has an adult length of 1-1.5 m and reaches a maximum total length of 1.7 m and can weigh up to 60 kg. *C. gariepinus* is one of the most important tropical catfish species for aquaculture in spite its commanding presence in the wild Abalaka (2013). It has long tolerance for drought. However, a dearth of information exists on Ichthyotoxins toxicity with respect to this commercially important species and the sub-lethal effects of *Bridelia micrantha* exposure, recovery responses and potential ameliorative effects of vitamin C are yet to be understood. This study, therefore, attempts to fill the information gap on the Haematology, histopathology, and plasma biochemistry of the *Clarias gariepinus* following exposure to *Bridelia micrantha*, recovery responses after exposure and ameliorative potentials of ascorbic acid (vitamin C).

Materials and Methods

Location of Study: This research was carried out at the Department of Fisheries and Aquatic Science, Wet Laboratory, University of Cross River State (Unicross), Obubra Campus.

Collection and preparation of *Bridelia micrantha*

Ichthyotoxic Plants (*Bridelia micrantha*) was sourced around the University communities at Obubra Campus where they are abundant. All the plant sample was collected in the early hours of the day

between 6:00 and 9:00 am. After collection, the samples were taken to the Herbarium unit of the Department of Forestry Obubra Campus, University of Cross River State, Nigeria for proper identification. The plant sampled was air dried in the laboratory, at room temperature for two weeks and then oven dried at 32 °C for 30 minutes. The leaf *Bridelia micrantha*, was pulverized using an electric blender. The powder of each plant sample was sieved through a 100µm sieve to obtain fine powder and transferred into air-tight sterile bottles, labelled, and stored at 4°C until further analyses.

Aqueous extraction of Ichthyotoxins

Ichthyotoxins from the plant samples were extracted by soaking 100 g of the powder from each sample in 1L of distilled water. The solutions were left for 72 hours to undergo fermentation and stirred once, morning and evening during this period. After the fermentation period, the solution of each sample was filtered through a Whatman (No.1) filter paper to obtain the aqueous extracts (Fafioye 2005). The stock solutions were serially diluted 1:100 (water content: toxicant) depending on required concentrations, for use in toxicity testing studies.

Toxicity Experiment

Test organism/ Acclimation

Clarias gariepinus was used as test organism in this study. A total number of apparent healthy 550 *C. gariepinus* juveniles (4-6 weeks old) was purchased from Amazon Fish Farms hatcheries Abakaliki, Ebonyi State with an average body weight (66.38±6.3g) and length (23.27±3.5cm) Table 1 and transported in oxygenated polythene bags, to the Fisheries wet Laboratory, Department of Fisheries and Aquatic Science, UNICROSS Obubra. The juveniles were acclimated separately for fourteen days in holding tanks, half filled with non-chlorinated rain water. They were fed with commercially prepared fish feed (Vital Fish Feed, Nigeria) at 3% body weight during this period and water in the tanks was changed once every other day to avoid pollution by fish metabolic wastes and food remnants. Feeding was discontinued 24 hours before the commencement of experiments.

Experimental Design

Following the result of the presumptive test, five nominal concentrations (0.00, 0.42, 0.084, 0.126, 0.168 and 0.21 ml/l of Ichthyotoxic Plants (*Bridelia micrantha*) was prepared through serial dilution in a static renewal bioassay for acute toxicity test using the Organization of Economic Cooperation and Development (OECD, 1992) guidelines. Thirty fish were randomly selected and subjected to a 60-day exposure regime in five measured sublethal concentrations of the toxicant (0.00, 0.42, 0.084, 0.126, 0.168 and 0.21 mg/l); equivalent to 1/10 each of the concentrations used for the acute assay, while the first treatment (0.00 mg/l) was the control as it was devoid of the toxicant. The experiment was set up in triplicates and fish were fed at 3% body weight two times daily. The aquaria containing fish were cleaned and toxicant was renewed every day to keep the toxicant concentration constant (FAO, 1986). After the 60-day exposure, fish from the different concentrations were transferred each into separate *Bridelia micrantha*-free aquarium (aquarium containing only water) for a 30-day depuration studies. After the 60-day exposure and depuration periods, five fish from each of the treatments and controls were dissected at 15 days interval to remove the Blood for haematological test, gills kidney skin, and liver for histological analyses, respectively.

Ameliorative experiment

Preparation of Vitamin C stock solution

Twenty (20 packets of Ascorbic acid tablets (100 mg/tablet), MedVit C1 (Dol-Med Laboratories Limited, Lagos, Nigeria) was obtained from a Pharmaceutical Store in Calabar. In the laboratory the Vitamin C tablets were ground and a stock solution was prepared by dissolving a known weight of

the powder in 900mls of distilled water. The volume was now made up to the 1 L mark using distilled water. The concentration of the solution was calculated from the formula: milligram of powder/ volume of distilled water. This was shaken until a homogeneous mixture is formed and all the Vitamin C granules have completely dissolved. This was labelled and preserved in screw capped container in a cool place in the laboratory (Ambaliet *et al.*, 2011).

Ameliorative effect of ascorbic acid (vitamin C) on *Bridelia micrantha* exposed fish was evaluated by placing the fish on ascorbic acid (AA)-supplemented diet. The diet was formulated with the following ingredients: maize corn (30%), soya bean (20%), groundnut cake (18%), fish meal (30%), bone meal (0.4%), vitamin C (0.2%), methionine (0.4%), lysine (0.4%), salt (0.2%), premix (0.2%) which formed 100% balanced diet mixed with already prepared AA. With a meat mincer through 3 mm die, these constituents were ground, crushed, weighed, mixed, pelleted, air dried and kept in moisture-free container prior use (DeSilva, 1991). Twenty one (21) (75cm x 45cm x 45cm) glass tanks of 121.5 litres capacity each were filled with 50 litres aerated unchlorinated rain water. Ten juveniles of the test organism were batch-weighted with a top-loading Mettler balance (Mettler Toledo (K)), and distributed randomly in triplicate per treatment. Five treatments and one control labelled were used for the ameliorative experiment. The concentrations of the ascorbic acid (vitamin C) used for the experiment were 0.00, 25, 50, 75, 100, and 1501 ml/l.

Haematological Examinations

Blood Sampling

Blood (1-2ml) was collected from the vertebral caudal blood vessel according to Svobodova *et al.*, (1991) Neuwinger (2004), using disposable 2ml syringe and needle. The blood will be emptied into the heparinized blood bottle treated with Ethyl Diamine Tetracetic Acid (EDTA). A blood sample will be centrifuged (1500 rpm for 7mins) to obtain the blood plasma. Plasma samples will be stored at (-20°C) for the electrochemical and biochemical analysis.

Method of Blood Analysis

Computerized method employing System KX-2INTM Automated Haematology Analyzer was used in blood analysis, the KX-2IN is an ideal haematology analyzer for a clinical satellite laboratory or research testing. Spectrophotometric method was used for biochemical analysis as described by Svobodova *et al.*, (2003). While the plasma electrolytes were determined using Corning 400 flame photometer. Other metals were determined using (a back) Model 200A flame of the Atomic Absorption Spectrophotometer (AAS). Blood indices, including mean corpuscular hemoglobin (MCH), mean corpuscular hemoglobin concentration (MCHC), and mean corpuscular volume (MCV), were assessed according to the method of Gupta (1977) and following formulas:

$$\text{MCH (pg/cell)} = 10 \times [\text{Hb (g/100 mL blood)}/\text{RBCs (10}^6/\text{mm}^3)]$$

$$\text{MCHC} = 100 \times [\text{Hb (g/100 mL blood)}/\text{hematocrit (\%)}]$$

$$\text{MCV (fL)} = 10 \times [\text{hematocrit (\%)}]/\text{RBCs (10}^6/\text{mm}^3]$$

Plasma Biochemical Analysis

Plasma Biochemical Analysis of the experimental fish was run to determine the Crude Protein (CP), crude Lipid (CL), Crude Fiber (CF), Moisture (M), Ash and Nitrogen Free Extract (NFE), using standard methods (AOAC, 1990). Nitrogen was determined by the micro-kjedahl method (Pearson, 1976) and the crude protein was taken as N% x 6.25 (constant factor) where N is equal to Nitrogen content per 100g sample. Total carbohydrate was determined using the phenol-sulphuric

acid method. The crude fibre was obtained by dry ashing of the sample at 550°C dissolved in 10% HCl(25ml) and 5% Lanthanum Chloride (2ml) boiled, filtered and made up to standard volume with distilled water.

Histological Examination of Test Organ

At the end of the experiment, one fish per treatment, that is, three fish per concentration was sampled after 96 hours of exposure for histological analysis, the test organism was sacrificed with a blow on the head, using a mallet and was dissected for the removal of vital organs (kidney, gill and liver). The organs were fixed in 10% formalin for three days after which the tissue was dehydrated in periodic acid Schiff's reagent (PAS) following the method of Hughes and Perry, (1976), in graded levels of 50%, 70%, 90% and 100% alcohol for 3 days, to allow paraffin wax to penetrate the tissue during embedding.

The organs were embedded in malted wax. The tissue was sectioned into thin sections (5-7µm), by means of a rotatory microtome and was dehydrated and stained with Harris haematoxylin-eosin (H&E) stain, Bancroft and Cook, (1994), using a microtome and each section was cleared by placing in warm water (38°C), where it was picked with clean slide and oven-dried at 58°C for 30 minutes to melt the wax.

The slide containing sectioned materials/tissue was cleared using xylene and graded levels of 50%, 70%, 90%, 95% and 100% alcohol for two minutes each. The section was stained in haematoxyline eosin for ten minutes. The stained slide was observed under a light microscope at varying X100 magnification, sections were examined and photographed using an Olympus BH2 microscope fitted with photographic attachment (Olympus C35 AD4), a camera (Olympus C40 AB-4) and an automatic light exposure unit (Olympus PM CS5P).

Statistical analysis

Values obtained as mean + SEM were analysed using SPSS (Statistical Package for Social Sciences) version 20.0. Data obtained from haematological and proximate composition of the carcasses were analysed using one-way analysis of variance (ANOVA) and where a significant difference ($p < 0.05$) exist, Duncan new multiple range tests were used to detect the source of the difference.

Results

The result of Length-weight relationship of *Clarias gariepinus* Juvenile exposed to ichthyotoxic plant *B. micranthana* and Ascorbic acid is presented in table 1 shows that the weight (g) varies from (55.18±6.1 - 81.25±8.3) – (55.83±5.4 - 79.22±8.3) and standard length (22.52±3.0 - 27.47±4.3) – (22.52±3.0 - 30.90±2.8) for *Bridellia michranta* and Ascorbic acid tests respectively, this result indicates that the experimental fish are in good conditions of health.

Table 1: Length and Weight relationship of Catfish *Clarias gariepinus* Juveniles used for the Experiments (Mean±SD).

Treatment	L/W	Control	1	2	3	4	5
Treated with <i>Bridellia micranthana</i>	Standard Length (cm)	21.62±3.0 ^a	20.60±2.8 ^a	16.82±7.9 ^a	27.47±4.3 ^a	18.24±6.6 ^a	23.27±3.5 ^a
	Weight (g)	81.25±8.3 ^b	55.18±6.1 ^{ab}	65.02±8.1 ^{ab}	70.83±5.4 ^a	68.73±9.4 ^{ab}	66.38±6.3 ^{ab}

Treated with Ascorbic Acid	Standard Length (cm)	22.52±3.0 ^a	30.90±2.8 ^a	27.82±7.9 ^a	25.47±4.3 ^a	26.24±6.6 ^a	23.27±3.5 ^a
	Weight (g)	79.22±8.3 ^b	61.18±6.1 ^{ab}	61.02±8.1 ^{ab}	55.83±5.4 ^a	74.73±9.4 ^{ab}	64.38±6.3 ^{ab}

Means with the same superscripts in the same column are not significantly different at P>0.05, while those with different superscripts in the same column are significantly different at same

Table 2 summarizes the range of the physicochemical parameters of control and treated fish observed during the experimental period. There was no significant difference among the different treatments in terms of physicochemical parameters measured. Alkalinity significantly increased throughout the experiment. The result of the physicochemical parameters of the experimental media indicated a significant difference (P<0.05) in the values obtained in the level of dissolved oxygen, content free carbon dioxide and alkalinity with the control. Nevertheless, there were no significant difference (P>0.05) between the values of temperature and pH of test media with the control. The abnormal behaviour observed in fish exposed to the extract included respiratory distress, loss of balance, gulping of air, settling at the bottom motionless, and erratic swimming.

Table 2: - Effect of *Bridellia micrantha* and Ascorbic acid on water quality during the experiment

Conc mg/l.	<i>Brandellia micrantha</i>				Conc. mg/l	Ascorbic Acid			
	Temp(O ^c)	DO ₂	Conductivity	pH		Temp(O ^c)	DO ₂	Conductivity	pH
0.00	25.50±0.6 ^a	4.42±0.7 ^a	42.00±4.1 ^{ab}	6.95±0.3 ^{ab}	0	25.50±0.6 ^a	4.42±0.7 ^a	42.00±4.1 ^{ab}	6.95±0.3 ^{ab}
0.042	25.00±0.6 ^a	3.42±0.2 ^a	41.00±4.1 ^{ab}	6.97±0.3 ^a	25	25.00±0.6 ^a	3.42±0.2 ^a	41.00±4.1 ^{ab}	6.97±0.3 ^a
0.084	25.17±1.0 ^a	4.80±0.6 ^a	36.50±11.3 ^a	6.01±1.6 ^b	50	25.17±1.0 ^a	3.80±0.6 ^a	36.50±11.3 ^a	6.01±1.6 ^b
0.126	25.00±0.6 ^a	4.15±1.1 ^a	33.33±13.4 ^{ab}	7.11±1.5 ^b	75	25.00±0.6 ^a	4.15±1.1 ^a	33.33±13.4 ^{ab}	8.11±1.5 ^b
0.168	26.00±1.7 ^a	3.18±0.7 ^a	47.33±5.5 ^{ab}	6.90±0.2 ^b	100	26.00±1.7 ^a	3.18±0.7 ^a	47.33±5.5 ^{ab}	6.90±0.2 ^b
0.21	25.83±1.2 ^a	3.66±0.8 ^a	38.80±8.3 ^{ab}	6.97±0.5 ^{ab}	125	25.83±1.2 ^a	3.66±0.8 ^a	38.80±8.3 ^{ab}	6.97±0.5 ^{ab}

Means with the same superscripts in the same column are not significantly different at P>0.05, while those with different superscripts in the same column are significantly different at same

Histological alterations in *Clarias gariepinus* exposed to *Brandellia micrantha*)

The results of histological alterations in the liver of *Clarias gariepinus* exposed to *Brandellia micrantha* is presented in Plate A Figure 1-24, at 15 days treatment 0.00mg/l control section of liver (X100)(H/E) shows normal hepatic architecture with normal hepatocyte (H) and central vein (C). at 30days treatment 0.042mg/l section of liver (X100)(H/E) shows mild effect on the hepatic tissue with mild aggregate of intra hepatic inflammation (IHI), at 45 days treatment 0.084 mg/l section of liver (X100)(H/E) shows moderate effect on the hepatic tissue with moderate pyknotic (P) hypatocyte and intra hepatic hemorrhage (IHH) . treatment 0.126 mg/l section of liver (X100)(H/E) shows mild to moderate effect on the hepatic tissue with moderate congestion of the central vein (CCV)and aggregate of inflammatory cell (AIC) within the congested area focal area, treatment 0.125 mg/l section of liver (X100)(H/E) shows sever effect on the hepatic tissue with sever focal area of ovum of parasite (OP) in the liver paraenchyma and fibrous strand (FS) . The overall feature are consistence with (Shistosomiasis of the liver) treatment 0.168mg/l section of liver (X100)(H/E) shows moderate to severe effect on the hepatic tissue with sever focal area of cirrhosis(C) and extravassated red blood cell (EVRBC) at 60 days treatment 0.21mg/l section

of liver (X100)(H/E) shows severe effect on the hepatic tissue with severe ground glass (GG) appearance of the cytoplasm and intra hepatic hemorrhage (IHH)

The results of histological alterations in the kidney of *Clarias gariepinus* exposed to *Brandelia micrantha* at 15 days intreatment 0.00mg/l control is presented in Figs 25, 30,37 and 43 these sections of the kidney (x400) (H/E) shows normal renal tissue arrangement. Treatment 0.042 figs 26, 32, 38, and 44 section of kidney (x400) (H/E) shows moderate degeneration of the renal tissue with moderate intra renal inflammation (IRI) and moderate tubular atrophy (TA). Treatment 27, 33,39, and 45 section of kidney (x400) (H/E) shows mild degeneration of the renal tissue (MDR) with mild intra renal hemorrhage (IRH) Treatment 0.084 Figs 27 and 33 section of kidney (x400) (H/E) shows moderate degeneration of the renal tissue T 39 and 45 with moderate necrotic (N) glomeruli. Photomicrograph of treatment 0.126 figs 28, 34, 40 and 46 section of kidney (x400) (H/E) shows moderate degeneration of the renal tissue with moderate intra renal fibrosis (IF) and inflammatory cell aggregate (IC) Treatment 0.168, Figs 29,35,41 and 47 section of kidney (x400) (H/E) shows moderate degeneration of the renal tissue with moderate infiltration of inflammatory cell (II). At 60 days treatment 0.21 figs. 30, 36, 42 and 48 section of kidney (x400) (H/E) shows severe degeneration of the renal tissue with severe intra renal necrosis (TN) and inflammatory cell aggregate (IC) with tubular atrophy (TA) in some areas.

The result of histological alterations in the gill of *Clarias gariepinus* exposed to *Brandelia micrantha* at 15 days in treatment 0.00 Figs 49, 55, 61 and 67 control section of gill (X150)(H/E) shows normal gill architecture with well projected filament (PF) , gill epithelium (GE) and cartilages (C). At 30 days in treatment 0.042 figs 50, 56, 62, and 68 section of gill (X150)(H/E) shows mild effect on the gill architecture with mild detachment (D) of the gill filament from the epithelia. treatment 0.084 Figs 51, 57, 63 and 69 section of gill (X150)(H/E) shows mild effect on the gill architecture with mild focal area of hemorrhage (H) and mild aggregate of inflammatory cell (AIC) at 45days treatment 0.126 figs 52, 58, 64 and 70 section of gill (X150)(H/E) shows mild to moderate effect on the gill architecture with mild focal area of hemorrhage (H) and moderate focal area of necrosis (N) Photomicrograph of T0.168 figs 53, 59 65 and 71 section of gill (X150)(H/E) shows moderate effect on the gill architecture with mild focal area of hemorrhage (H) and aggregate of inflammation (AI).The result at 60 days of Treatment 0.21 figs 54, 60, 66 and 72 section of gill (X150)(H/E) shows severe effect on the gill architecture with hypertrophy of the gill arch, gill filament degeneration and aggregate of inflammation (AI)

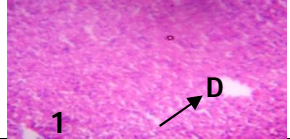
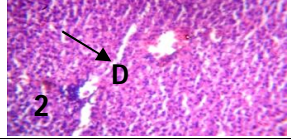
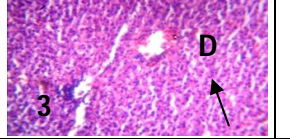
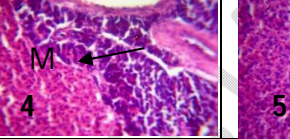
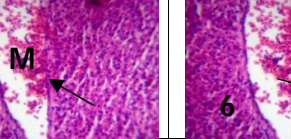
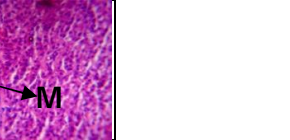
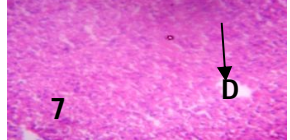
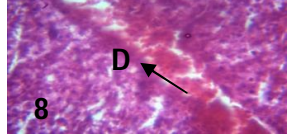
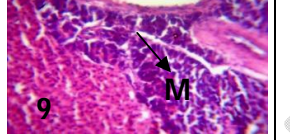
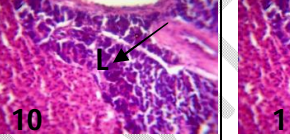
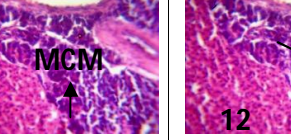

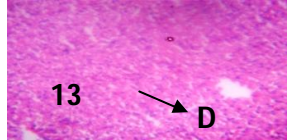
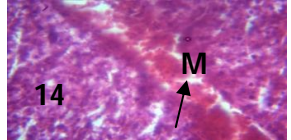
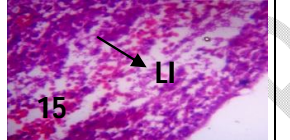

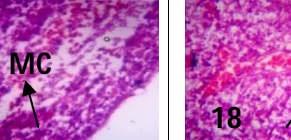
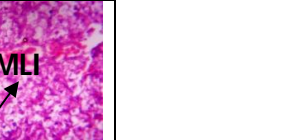
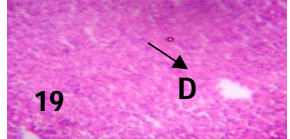
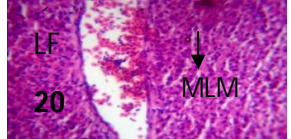

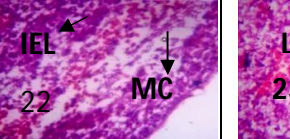
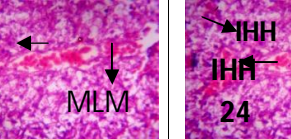
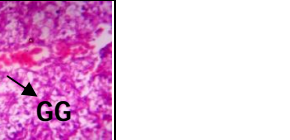
Exposure Period (Days)	Concentration (mg/l)					
	Control (0.00)	0.042	0.084	0.126	0.168	0.21
15						
30						
45						
60						

Plate A Figure 1:- 24 - Histological alterations in the liver of *Clarias gariepinus* exposed to *Brandelia micrantha* in treatment 0.00mg/l at 15 days control section of liver (X100)(H/E) shows normal hepatic architecture with normal hepatocyte (H) and central vein (C). In treatment 0.042mg/l section of liver (X100)(H/E) shows mild effect on the hepatic tissue with mild aggregate of intra hepatic inflammation (IHI). In treatment 0.084mg/l section of liver (X100)(H/E) shows moderate effect on the hepatic tissue with moderate pyknotic (P) hepatocyte and intra hepatic hemorrhage (IHH). In treatment 0.126 section of liver (X100)(H/E) shows mild to moderate effect on the hepatic tissue with moderate congestion of the central vein (CCV) and aggregate of inflammatory cell (AIC) within the congested area focal area, in treatment 0.168mg/l section of liver (X100)(H/E) shows severe effect on the hepatic tissue with severe focal area of ovum of parasite (OP) in the liver paraenchyma and fibrous strand (FS). The overall features are consistent with (Schistosomiasis of the liver) in treatment 0.168 mg/l section of liver (X100)(H/E) shows moderate to severe effect on the hepatic tissue with severe focal area of cirrhosis (C) and extravasated red blood cell (EVRBC) at highest concentration of 60 days in treatment 0.21 section of liver (X100)(H/E) shows severe effect on the hepatic tissue with severe ground glass (GG) appearance of the cytoplasm and intra hepatic hemorrhage (IHH).

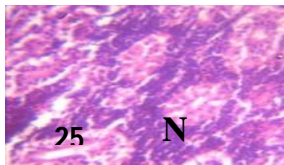
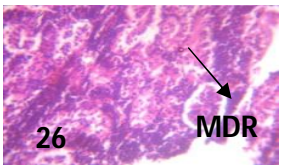
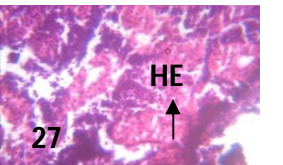
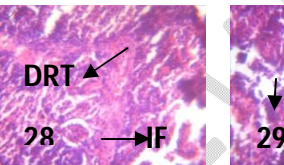
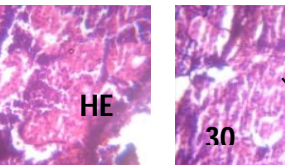

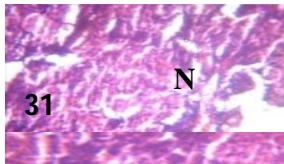
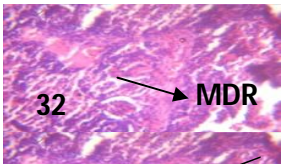
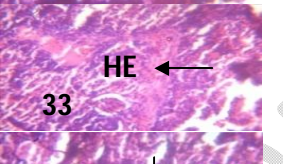
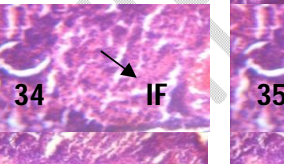
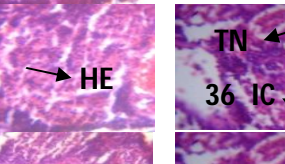

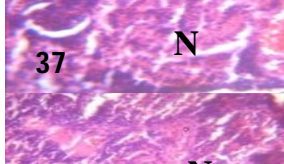

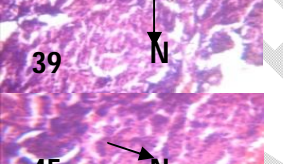
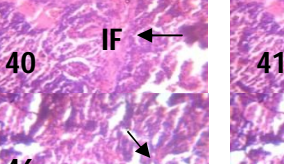
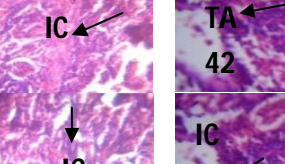

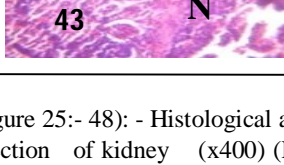
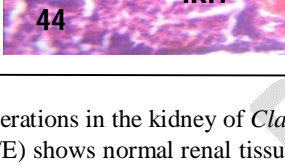
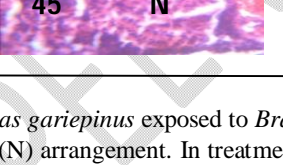
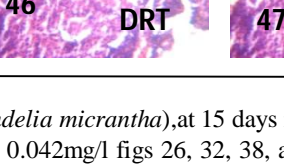
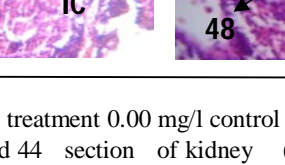

Exposure Period (Days)	Concentration (mg/l)					
	Control (0.00)	0.042	0.084	0.126	0.168	0.21
15						
30						
45						
60						

Plate B (Figure 25:- 48): - Histological alterations in the kidney of *Clarias gariepinus* exposed to *Brandelia micrantha*, at 15 days in treatment 0.00 mg/l control Fig 25, 30, 37 and 43 section of kidney (x400) (H/E) shows normal renal tissue (N) arrangement. In treatment 0.042 mg/l figs 26, 32, 38, and 44 section of kidney (x400) (H/E) shows moderate degeneration of the renal tissue with moderate intra renal inflammation (IRI) and moderate tubular atrophy (TA). Photomicrograph of Treatment 0.084 mg/l figures 27, 33 and 39 section of kidney (x400) (H/E) shows mild degeneration of the renal tissue (MDR) with mild intra renal hemorrhage (IRH). Photomicrograph of treatment 0.084 mg/l figure 45 section of kidney (x400) (H/E) shows moderate degeneration of the renal tissue figures 39 and 45 with moderate necrotic (N) glomeruli. Photomicrograph of Treatment 0.126 mg/l figs 28, 34, 40 and 46 section of kidney (x400) (H/E) shows moderate degeneration of the renal tissue with moderate intra renal fibrosis (IF) and inflammatory cell aggregate (IC). Photomicrograph of treatment 0.168 mg/l figures 29, 35, 41 and 47 section of kidney (x400) (H/E) shows moderate degeneration of the renal tissue with moderate infiltration of inflammatory cell (II). Photomicrograph of Treatment 0.21 mg/l figs 30, 36, 42 and 48 section of kidney (x400) (H/E) shows severe degeneration of the renal tissue with severe intra renal necrosis (TN) and inflammatory cell aggregate (IC) with tubular atrophy (TA) in some areas.

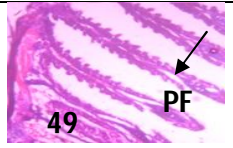

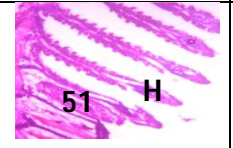
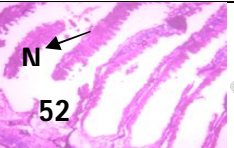
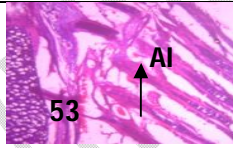
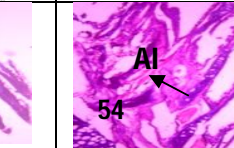
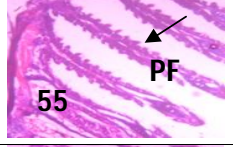

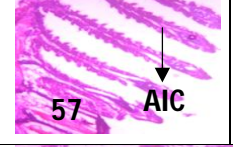
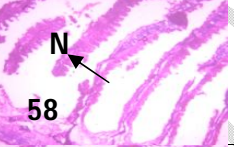
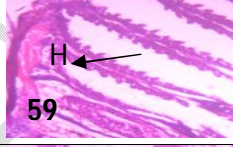
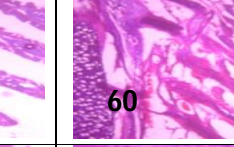




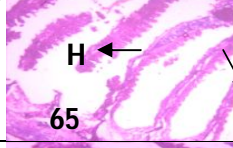



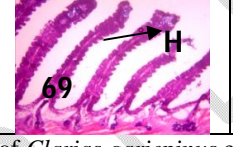
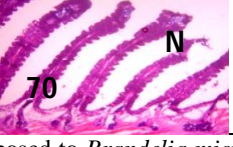


Exposure Period (Days)	Concentration (mg/l)					
	Control (0.00)	0.042	0.084	0.126	0.168	0.21
15	 49 PF	 50 D	 51 H	 52 N	 53 AI	 54 AI
30	 55 PF	 56 D	 57 AIC	 58 N	 59 H	 60 H
45	 61 GE	 62 D	 63 AIC	 64 H	 65 H	 66 DF
60	 67 C	 68 D	 69 H	 70 N	 71 AI	 72 GF

Plate C (Figure 49:- 72): - Histological alterations in the gill of *Clarias gariepinus* exposed to *Brandelia micrantha*, at 15 days group treatment 0.00mg/l Figures 49, 55, 61 and 67 control section of gill (X150)(H/E) shows normal gill architecture with well projected filament (PF) , gill epithelium (GE) and cartilages (C). Photomicrograph of at 30 days treatment 0.042 figures 50, 56, 62, and 68 section of gill (X150)(H/E) shows mild effect on the gill architecture with mild detachment (D) of the gill filament from the epithelia Photomicrograph of at treatment 0.084mg/l figures 51, 57, 63 and 69 section of gill (X150)(H/E) shows mild effect on the gill architecture with mild focal area of hemorrhage (H) and mild aggregate of inflammatory cell (AIC) Photomicrograph of at 45days treatment 0.126mg/l figs 52, 58, 64 and 70 section of gill (X150)(H/E) shows mild to moderate effect on the gill architecture with mild focal area of hemorrhage (H) and moderate focal area of necrosis (N) Photomicrograph of treatment 0.168 figs 53, 59 65 and 71 section of gill (X150)(H/E) shows moderate effect on the gill architecture with mild focal area of hemorrhage (H) and aggregate of inflammation (AI) Photomicrograph at 60 days of the highest treatment 0.21mg/l figures 54, 60, 66 and 72 section of gill (X150)(H/E) shows severe effect on the gill architecture with hypertrophy of the gill arch, gill filament degeneration and aggregate of inflammation (AI)

Ameliorative effects of Ascorbic Acid (vitamin C) on structural changes in the histology of African Sharptooth Catfish *Clarias gariepinus*

Ameliorative effects of ascorbic acid(AA) on structural changes in the gill of African Sharptooth Catfish *Clarias gariepinus* at 15 days treatment 0.00mg/l control figures 73 , 79, 85 and 91 control section of gill (X150)(H/E) shows normal gill architecture with well projected filament (PF) , gill epithelium (GE) and cartilages (C). at Treatment 25mg/l, figs 74, 80 and 86 section of gill (X150)(H/E) shows severe effect on the gill architecture with severe clumping (C) ,necrotic (N) filament and areas of hemorrhage (H) ; at treatment 50mg/l figures 75, 81, and 87, section of gill (X150)(H/E) shows severe effect on the gill architecture with severe areas necrotic filament (NF); at Treatment 75mg/l figures. 76, 82, and 88 section of gill (X150)(H/E) shows mild effect on the gill architecture with mild hypertrophied (H) filament; at treatment 100mg/l figures. 77, 83, and 89 section of gill (X150)(H/E) shows mild effect on the gill architecture with mild focal area of haemorrhage (H) otherwise normal; at treatment 125mg/l figures 78,84, and 90 section of gill (X150)(H/E) shows moderate effect on the gill architecture with moderate hypertrophy of the filament and moderate infiltration of inflammatory cells (IIC); treatments 25, 50, 75, 100 and 125mg/l at 60 days Fig 91, 92, 93, 94, 95 and 96 at 60 days (X150)(H/E) section of gill (X150)(H/E) shows normal gill architecture with well projected filament (PF) , gill epithelium (GE) and cartilages (C).

Ameliorative effects of vitamin C on structural changes in the liver of African Sharptooth Catfish *Clarias gariepinus* at treatment 0.00mg/l figures 97, 103, 109 and 115 control section of liver (X100)(H/E) at 15 days shows normal hepatic architecture with normal hepatocyte (H) and central vein. treatment 25mg/l figures 98, 104 and 110 at 15 to 45 days section of liver (X100)(H/E) shows severe effect on the hepatic tissue with ground glass (GG) appearance of the cytoplasm and moderate intra hepatic hemorrhage (IHH). Treatment 50mg/l, figures. 99, 105, and 111 section of liver (X100)(H/E) shows severe effect on the hepatic tissue with severe focal area of ovum of parasite (OP) in the liver parenchyma and fibrous strand (FS) . Treatment 75mg/l, Figures 100, 106, and 112 section of liver (X100)(H/E) shows moderate effect on the hepatic tissue with moderate focal area of haemorrhage (H). Treatments 75mg/l figures 101, 107, 113 section of liver (X100)(H/E) shows moderate effect on the hepatic tissue with moderate focal area of hemorrhage (H) , with mild aggregate of intra hepatic inflammation (IHI) and congestion of the central vein (CC) The hepatocyte are moderately active at treatment 100mg/l figures 102, 108, and 114 section of liver (X100)(H/E) shows mild effect on the hepatic tissue with mild aggregate of intra hepatic inflammation (IHI) and congestion of the central vein (CC). The hepatocyte are moderately active). At treatment 125mg/l figures 115, 116, 117, 118, 119 and 120 section of liver (X100)(H/E) at 60 days shows normal hepatic architecture with normal hepatocyte (H) and central vein (C).

Ameliorative effects of vitamin C on structural changes in the kidney of African Sharptooth Catfish *Clarias gariepinus* of Treatment 0.00mg/l, figures 121, 127, and 133 section of kidney (X150)(H/E) control section at 15 days shows renal renal tissue with severe aggregate of inflammation (AI) with eosinophilic (E) tubules at treatment 25mg/l figures 122, 128, 134 section of kidney (X150)(H/E) shows renal tissue with moderate aggregate of inflammation (AI), Photomicrograph of Treatment 50mg/l figures 124, 130, and 137 section of kidney (X150)(H/E) shows renal tissue with moderate to severe aggregate of inflammation (FAI) and areas of hemorrhage (H), at treatment 50mg/l figures 125, 131, 135 section of kidney (X150)(H/E) shows renal tissue with moderate aggregate of inflammation (AI) with eosinophilic (E) tubules. At 45 days treatment 100 mg/l figures 126, 132, and 138 of kidney (X150)(H/E) shows normal renal

architecture with active glomeruli (G) renal tubules (RT) and tubular cell (TC), at 125mg/l figures 139, 140, 141, 142, 143 and 144, section of kidney(X150)(H/E) at 60 days of the experiment with ascorbic acid shows normal renal architecture with active glomeruli (G) renal tubules (RT) and tubular cell (TC).

UNDER PEER REVIEW

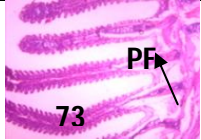

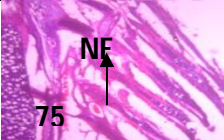
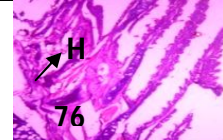
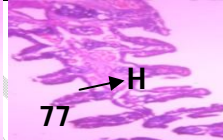

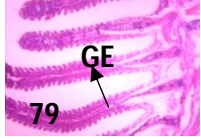

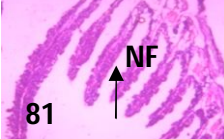
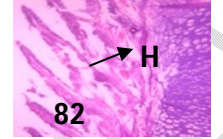
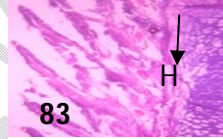
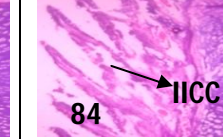
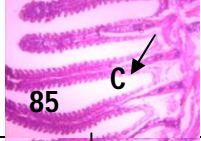
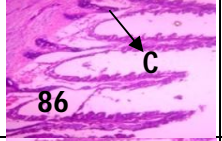
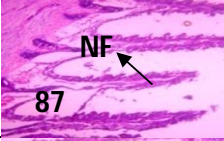
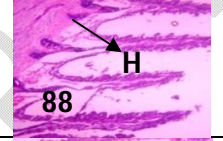
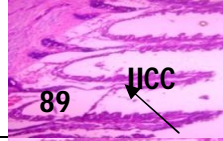
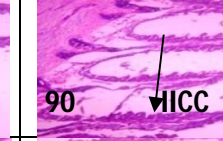





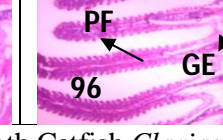
Exposure Period (Days)	Concentration (mg/l)					
	Control (0.00)	25	50	75	100	125
15	 73	 74	 75	 76	 77	 78
30	 79	 80	 81	 82	 83	 84
45	 85	 86	 87	 88	 89	 90
60	 91	 92	 93	 94	 95	 96

Plate D (Figure 73:- 96): Ameliorative effects of vitamin C on structural changes in the gill of the African Sharptooth Catfish *Clarias gariepinus* in treatment 0.00mg/l, figures 73 , 79, 85 and 91 control section of gill (X150)(H/E) at 15 minutes shows normal gill architecture with well projected filament (PF) , gill epithelium (GE) and cartilages (C). Photomicrograph of treatment 25mg/l figures 74, 80 and 86 section of gill (X150)(H/E) shows severe effect on the gill architecture with severe clumping (C) ,necrotic (N) filament and areas of hemorrhage (H) ; Photomicrograph of treatment 50mg/l figures 75, 81, and 87, section of gill (X150)(H/E) shows severe effect on the gill architecture with severe areas necrotic filament (NF); Photomicrograph of treatment 50mg/l figures 76, 82, and 88 section of gill (X150)(H/E) shows mild effect on the gill architecture with mild hypertrophied (H) filament; Photomicrograph of treatment 75mg/l figures. 77, 83, and 89 section of gill (X150)(H/E) shows mild effect on the gill architecture with mild focal area of haemorrhage (H) otherwise normal; Photomicrograph of treatment 100mg/l figures 78,84, and 90 section of gill (X150)(H/E) shows moderate effect on the gill architecture with moderate hypertrophy of the filament and moderate infiltration of inflammatory cells (IICC); Photomicrograph of treatment 125mg/l at 60 days Figures 91, 92, 93, 94, 95 and 96 section of gill (X150)(H/E) shows normal gill architecture with well projected filament (PF) , gill epithelium (GE) and cartilages (C).

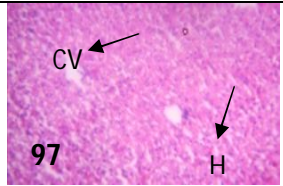
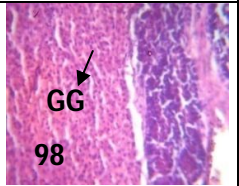
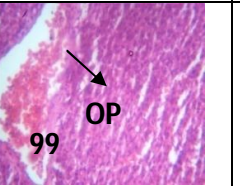
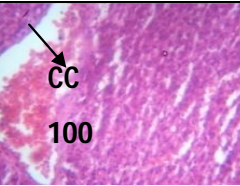
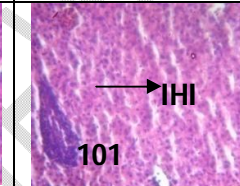
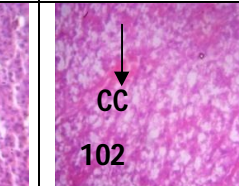
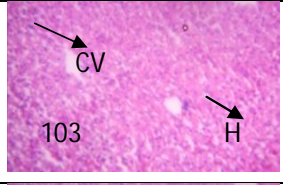
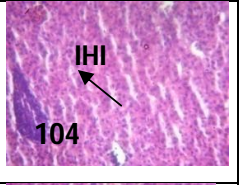
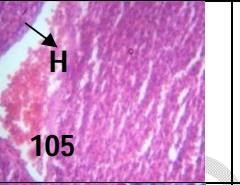
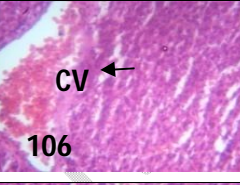
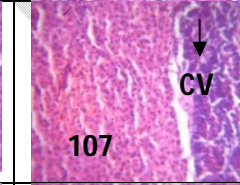
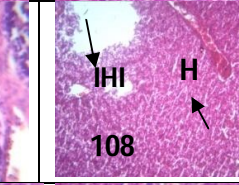
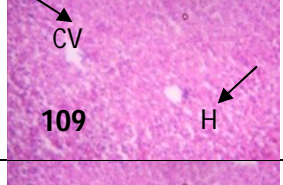
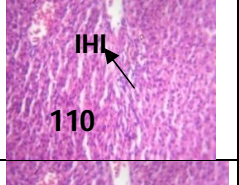
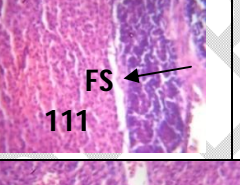
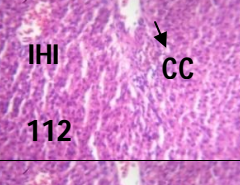
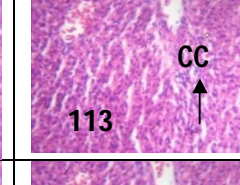
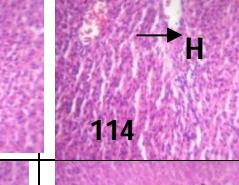
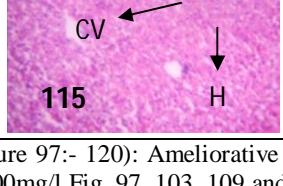
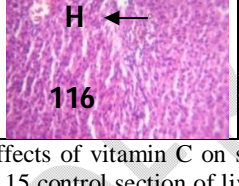
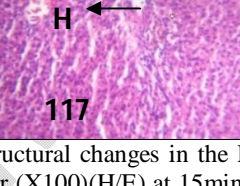
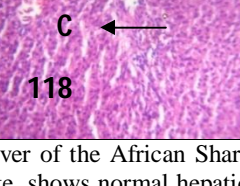
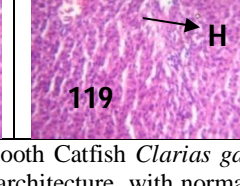

Exposure Period (Days)	Concentration (mg/l)					
	Control (0.00)	25	50	75	100	125
15						
30						
45						
60						

Plate E (Figure 97:- 120): Ameliorative effects of vitamin C on structural changes in the Liver of the African Sharptooth Catfish *Clarias gariepinus*. Photomicrograph of treatment 0.00mg/l Fig. 97, 103, 109 and 115 control section of liver (X100)(H/E) at 15 minutes shows normal hepatic architecture with normal hepatocyte (H) and central vein. Treatment 25mg/l figures 98, 104 and 110 at 15 minutes section of the liver (X100)(H/E) shows severe effect on the hepatic tissue with severe ground glass (GG) appearance of the cytoplasm and moderate intrahepatic hemorrhage (IHI). Treatment 50mg/l figures 99, 105, and 111 section of liver (X100)(H/E) shows severe effect on the hepatic tissue with severe focal area of ovum of parasite (OP) in the liver parenchyma and fibrous strand (FS). Treatment 75mg/l, figures 100, 106, and 112 section of liver (X100)(H/E) shows moderate effect on the hepatic tissue with moderate focal area of haemorrhage (H). Treatment 100mg/l Figures 101, 107, 113 section of liver (X100)(H/E) shows moderate effect on the hepatic tissue with moderate focal area of haemorrhage (H), with mild aggregate of intrahepatic inflammation (IHI) and congestion of the central vein (CC). The hepatocyte are moderately active. Treatment 125mg/l Figures 102, 108, 114 and 120 section of liver (X100)(H/E) at 60 days shows normal hepatic architecture with normal hepatocyte (H) and central vein (C).

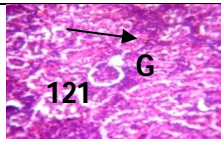
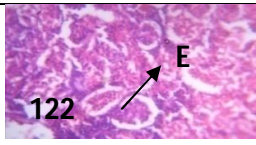
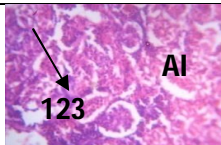
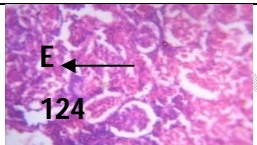
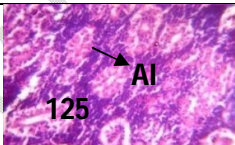
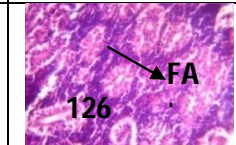
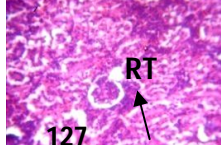
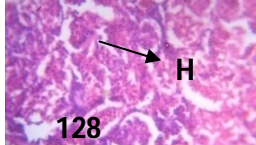
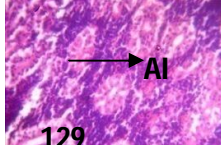
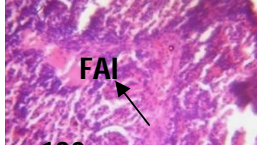
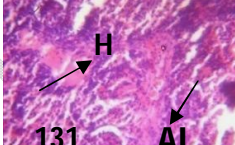
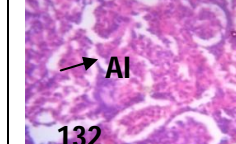
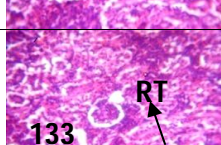
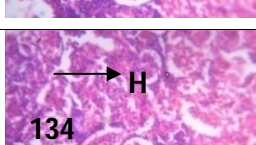
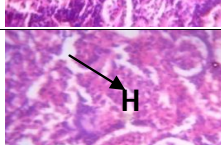
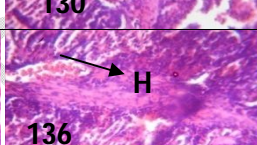
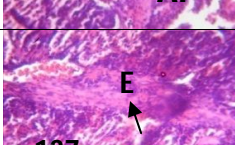
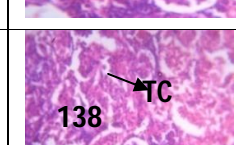
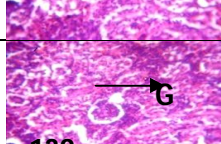
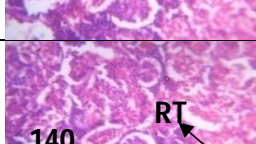
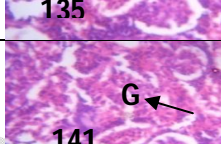
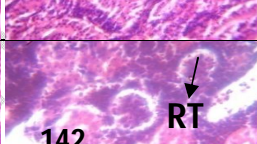
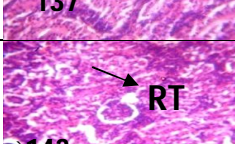
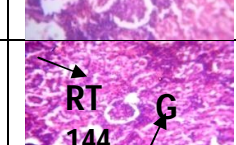
Exposure Period (Days)	Concentration (mg/l)					
	Control (0.00)	25	50	75	100	125
15						
30						
45						
60						

PLATE F: (Figures 121-144): Ameliorative effects of vitamin C on structural changes in the Kidney of the African Sharptooth Catfish *Clarias gariepinus*. In Treatment 0.00mg/l Figs 121, 127, 133 and 139 section of kidney(X150)(H/E) control section at 15 minutes shows renal renal tissue with normal aggregate of inflammation (AI) with eosinophilic (E) tubules. Photomicrograph of treatment 25mg/l figures 122, 128, 134 section of kidney(X150)(H/E) shows renal tissue with moderate aggregate of inflammation (A I), Photomicrograph of treatment 50mg/l figures 124, 130, and 137 section of kidney(X150)(H/E) shows renal tissue with moderate to severe aggregate of inflammation (FAI) and areas of hemorrhage (H), Photomicrograph of Treatment 75mg/l figures 125, 131, 135 section of kidney(X150)(H/E) shows renal tissue with moderate aggregate of inflammation (AI) with eosinophilic (E) tubules. Photomicrograph of treatment 100 mg/l figures 126, 132, and 138 of kidney(X150)(H/E) shows normal renal architecture with active glomeruli (G) renal tubules (RT) and tubular cell (TC). At treatment 125mg/l figures 140, 141, 142, 143 and 144, section of kidney(X150)(H/E) at 60 days of the experiment with ascorbic acid shows normal renal architecture with active glomeruli (G) renal tubules (RT) and tubular cell (TC).

The ameliorative effect of ascorbic acid on haematological parameters of *Clarias gariepinus* Juvenile

Haematological alterations in the *Clarias gariepinus* exposed to *Brandelia micrantha*, at 0.00mg/l during 15 days of exposure periods show an increase in white blood cell (ul), Red blood cell (ul) Haemoglobin (g/dl), Lymphocytes (ul), Mean cell volume (fl), Mean cell Haemoglobin concentration in the control section from $1.72 \times 10^2 \pm 12.5$, $2.63 \times 10^6 \pm 3.3$, 11.08 ± 2.3 , 96.78 ± 1.0 , 41.20 ± 4.6 , and 35.88 ± 4.2 to $2.55 \times 10^2 \pm 19.3$, 12.80 ± 2.2 , $3.26 \times 10^4 \pm 2.7$, 99.96 ± 4.6 , $1.98 \times 10^2 \pm 0.6$, and 45.54 ± 5.6 at 125mg/l in 60 days respectively, there was a decrease in the value of, Haematocrit (%), from 22.83 ± 2.5 to 10.36 ± 4.1 as presented in Table 3. Ameliorative effects of vitamin C on structural changes in the African Sharptooth Catfish *Clarias gariepinus*, presented in Table 4 at 0.00mg/l 15 days, the White blood cell (ul), Red blood cell (ul), Haemoglobin (g/dl), Haematocrit (%), Platelet (ul), Lymphocytes (ul), Mean Cell Volume (fl), Mean Cell Haemoglobin (pg), Mean Cell Haemoglobin Concentration normalizes with the control $1.61 \times 10^2 \pm 22.9$, $2.41 \times 10^6 \pm 7.5$, 6.53 ± 4.2 , 16.94 ± 8.7 , $2.83 \times 10^4 \pm 2.0$, 95.43 ± 1.0 , $2.11 \times 10^2 \pm 5.6$, 48.98 ± 9.5 and 46.07 ± 12.9 at 125mg/l at 60 days of exposure period as compared to control.

The ameliorative effect of ascorbic acid on proximate composition of the Carcass of *Clarias gariepinus* Juvenile

The alterations of the proximate composition of the Carcass in *Clarias gariepinus* exposed to *Brandelia micrantha* at 0.00mg/l at 15 days of exposure period is presented in table 5 there was a significant reduction in the value of proximate composition of the carcass after the exposure of *Clarias gariepinus* to *B. Micrantha* the Moisture (M), Crude Protein (CP) (Mg/l), Crude Lipid (CL), Ash, Nitrogen Free Extract (NFE), and Energy (kcal/100g) reduce from 66.24 ± 6.9 , 29.71 ± 2.3 , 3.49 ± 0.4 , 0.90 ± 0.0 , 0.38 ± 0.1 , and $1.37 \times 10^2 \pm 6.6$ to 64.57 ± 6.2 , 26.21 ± 1.3 , 3.31 ± 0.5 , 0.83 ± 0.1 , 0.25 ± 0.0 , and $1.31 \times 10^2 \pm 4.0$ respectively. The ameliorative effect of ascorbic acid on Carcass/Proximate composition of *Clarias gariepinus* juvenile is presented in table 6 at 125mg/l during 60 day exposure period the values of proximate composition of the carcass after exposure of *Clarias gariepinus* to Vitamin C Ascorbic acid (AA) increases from Crude Protein (CP), Crude Lipid (CL), Energy K(cal)/mg, Moisture (M), Ash, and Nitrogen Free Extract (NFE) were 26.25 ± 5.0 , 3.34 ± 0.6 , $1.36 \times 10^2 \pm 5.3$, 64.84 ± 3.3 , 0.92 ± 0.1 to 0.49 ± 0.21 to 27.87 ± 2.1 , 3.59 ± 0.6 , $1.38 \times 10^2 \pm 9.4$, 67.47 ± 5.0 , 1.05 ± 0.2 , and 0.56 ± 0.2 respectively, while the value of Crude Fiber (CF) 0.00 remains constant throughout.

Table 3: - The summary of alterations of aqueous extract of *Bridelia micrantha* on haematological parameters *Clarias gariepinus* Juvenile (mean±SD)

Conc. (mg/L)	White blood cell (ul)	Red blood cell (ul)	Haemoglobin (g/dl)	Haematocrit (%)	Platelet (ul)	Lymphocytes (ul)	Mean cell volume (fl)	Mean cell Haemoglobin (pg)	Mean cell Haemoglobin concentration.
0.00	1.72 x 10 ² ±12.5 ^c	2.63x10 ⁶ ±3.3 ^b	11.08 ±2.3 ^b	22.83 ± 2.5 ^b	3.22x10 ⁴ ±1.3 ^a	96.78±1.0 ^b	1.16x10 ² ± 2.3 ^b	41.20±4.6 ^a	35.88±4.2 ^a
0.042	1.62 x 10 ² ±10.5 ^c	2.13x10 ⁶ ±3.1 ^b	10.21 ±2.2 ^b	22.34 ± 2.2 ^c	3.21x10 ⁴ ±1.2 ^a	94.77±2.2 ^b	1.10x10 ² ±9.6 ^b	39.23±3.5 ^{ab}	43.33±1.3 ^a
0.084	1.83 x 10 ² ±14.7 ^c	3.25x10 ⁶ ±4.3 ^b	11.34 ± 3.6 ^b	22.85 ± 9.6 ^c	3.50x10 ⁴ ±2.2 ^a	93.93±7.9 ^b	1.13x10 ² ±1.4 ^b	41.71±8.1 ^a	58.45±6.5 ^a
0.126	1.91 x 10 ² ±4.9 ^c	3.05 x 10 ⁶ ±6.1 ^b	12.52 ± 3.9 ^b	14.96 ± 6.0 ^{abc}	3.30x10 ⁴ ±1.7 ^b	88.32±4.6 ^b	1.11x10 ² ± 7.7 ^b	46.52±5.6 ^a	52.80±5.1 ^{abc}
0.168	1.88 x 10 ² ±10.2 ^a	2.10 x 10 ⁶ ± 3.1 ^a	6.47 ± 0.9 ^a	17.13 ± 1.4 ^{bc}	2.73x10 ⁴ ±1.7 ^a	93.63±2.7 ^b	1.77x10 ² ±0.9 ^b	37.80±4.1 ^{ab}	35.21±3.5 ^a
0.21	2.55 x 10 ² ±19.3 ^b	2.85 x 10 ⁶ ± 2.1 ^b	12.80 ± 2.2 ^b	10.36 ± 4.1 ^{ab}	3.26x10 ⁴ ± 2.7 ^a	99.96±4.6 ^b	1.98x10 ² ±0.6 ^a	51.31±7.3 ^{ab}	45.54±5.6 ^b

Means with the same superscripts in the same column are not significantly different at P>0.05, while those with different superscripts in the same column are significantly different at same level.

Table 4: - Theameliorative effect of ascorbic acid on haematological parameters of *Clarias gariepinus* Juvenile (mean±SD)

Conc. (mg/L)	White Blood Cell (ul)	Red Blood Cell (ul)	Haemoglobin in (g/dl)	Haematocrit (%)	Platelet (ul)	Lymphocytes (ul)	Mean Cell Volume (fl)	Mean Cell Haemoglobin (pg)	Mean Cell Haemoglobin Concentration
0.00	1.65x10 ² ±21.9 ^b	2.37x10 ⁶ ±1.0 ^a	5.07±0.9 ^a	15.25±2.3 ^b	2.64x10 ⁴ ±1.5 ^a	95.60±1.1 ^b	1.16x10 ² ±2.3 ^{ab}	48.28±3.5 ^a	45.40±10.4 ^a
25	159x10 ² ±12.3 ^{ab}	1.93x10 ⁶ ±7.7 ^a	8.93±2.8 ^a	19.52±2.2 ^{ab}	3.49x10 ⁴ ±1.7 ^a	90.58±9.8 ^{ab}	1.06x10 ² ±10.8 ^{ab}	43.31±1.4 ^a	47.75±10.1 ^a
50	1.53x10 ² ±14.6 ^{ab}	2.12x10 ⁶ ±1.1 ^a	8.48±4.2 ^a	13.12±7.6 ^{ab}	3.84x10 ⁴ ±2.8 ^a	88.98±4.3 ^a	1.10x10 ² ±13.6 ^{ab}	54.95±1.9 ^a	62.85±11.6 ^b
75	1.42x10 ² ±12.5 ^{ab}	1.73x10 ⁶ ±4.9 ^a	9.37±3.7 ^a	11.37±8.7 ^a	2.23x10 ⁴ ±2.4 ^a	79.80±1.8 ^a	1.16x10 ² ±7.8 ^{ab}	50.60±6.4 ^a	46.10±10.5 ^a
100	1.53x10 ² ±41.2 ^{ab}	1.90x10 ⁶ ±5.1 ^a	6.30±0.9 ^b	16.53±1.1 ^{ab}	2.29x10 ⁴ ±1.2 ^a	92.93±4.6 ^b	2.78x10 ² ±3.8 ^{ab}	44.77±7.7 ^a	53.30±7.5 ^b
125	1.61x10 ² ±22.9 ^{ab}	2.41x10 ⁶ ±7.5 ^a	6.53±4.2 ^a	16.94±8.7 ^{ab}	2.83x10 ⁴ ±2.0 ^a	95.43±1.0 ^b	2.11x10 ² ±5.6 ^{ab}	48.98±9.5 ^a	46.07±12.9 ^b

Means with the same superscripts in the same column are not significantly different at P>0.05, while those with different superscripts in the same column are significantly different at same level.

Table 5: -The alterations of the proximate composition of the Carcass in *Clarias gariepinus* exposed to *Brandelia micrantha*)

Conc. (mg/L)	Moisture (M)	Crude Protein (CP) (Mg/l)	Crude Lipid (CL)	Crude Fiber (CF)	Ash	Nitrogen Free Extract (NFE)	Energy (kcal/100g)
0.00	66.24±6.9 ^a	29.71±2.3 ^b	3.49±0.4 ^c	0.00±0.0	0.90±0.0 ^b	0.38±0.1 ^a	1.37x10 ² ±6.6 ^a
0.042	67.30±5.5 ^a	28.66±2.2 ^b	3.51±0.3 ^c	0.00±0.0	0.65±0.3 ^a	0.40±0.2 ^b	1.32x10 ² ±6.2 ^a
0.084	63.31±8.7 ^a	29.23±5.5 ^b	3.3±0.4 ^c	0.00±0.0	0.69±0.3 ^{ab}	0.41±0.1 ^b	1.31x10 ² ±6.8 ^a
0.126	69.17±9.8 ^a	29.27±2.0 ^b	3.48±0.9 ^c	0.00±0.0	0.88±0.31 ^a	0.38±0.0 ^b	1.38x10 ² ±5.0 ^a
0.168	64.94±9.7 ^a	26.42±0.5 ^b	3.03±0.5 ^c	0.00±0.0	0.84±0.1 ^{ab}	0.42±0.1 ^b	1.36x10 ² ±3.4 ^a
0.21	64.57±6.2 ^a	26.21±1.3 ^b	3.31±0.5 ^c	0.00±0.0	0.83±0.1 ^b	0.25±0.0 ^b	1.31x10 ² ±4.0 ^a

Means with the same superscripts in the same column are not significantly different at P>0.05, while those with different superscripts in the same column are significantly different at same level.

Table 6: - The ameliorative effect of ascorbic acid on Carcass/Proximate composition of *Clarias gariepinus* Juvenile (Mean±SD)

Conc. (mg/L)	Crude Protein (CP) (Mg/l)	Crude Lipid (CL)	Energy K(cal)/mg	Crude Fiber (CF)	Moisture (M)	Ash	Nitrogen Free Extract (NFE)
0.00	26.25±5.0 ^a	3.34±0.6 ^a	1.36x10 ² ±5.3 ^a	0.00±0.0	64.84±3.3 ^{ab}	0.92±0.1 ^b	0.49±0.2 ^a
25	26.54±1.2 ^a	3.31±0.4 ^a	1.42x10 ² ±1.3 ^a	0.00±0.0	67.08±3.1 ^{abc}	0.67±0.3 ^a	0.48±0.1 ^{ab}
50	27.16±0.3 ^a	3.49±0.8 ^a	1.42x10 ² ±3.2 ^a	0.00±0.0	71.11±7.8 ^c	0.88±0.3 ^b	0.57±0.3 ^b
75	26.98±0.5 ^a	3.16±0.2 ^a	1.34x10 ² ±8.5 ^a	0.00±0.0	69.49±1.5 ^{bc}	0.91±0.1 ^b	0.29±0.1 ^b
100	27.10±1.8 ^a	3.47±0.7 ^a	1.33x10 ² ±3.4 ^a	0.00±0.0	63.73±5.4 ^a	1.27±0.7 ^b	0.52±0.1 ^{ab}
125	27.87±2.1 ^a	3.59±0.6 ^a	1.38x10 ² ±9.4 ^a	0.00±0.0	67.47±5.0 ^a	1.05±0.2 ^b	0.56±0.2 ^b

Means with the same superscripts in the same column are not significantly different at P>0.05, while those with different superscripts in the same column are significantly different at same level.

Discussion

Aquatic environments are generally known to be altered from their pristine state due to anthropogenic activities carried out in nearby areas; destruction of aquatic environment due to chemical pollution can be implicated for fish production decline in developing countries, particularly Nigeria. Among the emerging chemical pollutants with the potential of decimating the aquatic ecosystems are the plant Ichthyotoxins (Owolabi and Abdulkareem (2021). The *Bridelia micrantha* (Hochst.) (Phyllanthaceae) is an ichthyotoxic plant used in catching fish in Nigeria, the 96hrs LC_{50} of *Bridelia micrantha* to Catfish *Clarias gariepinus* was 0.21mg/l (Ayotunde and Igbang 2023) the active ingredient in *Bridelia micrantha* are triterpenoid saponins and rotenoids with rotenone being the most widely used commercially. Some other poisons include sesquiterpenes, diterpenoids, including diterpenoid orthoesters, triterpenes, furanocoumarins, 2-hydroxy-5-methoxy-3-undecyl-1,4-benzoquinone, prenyl phenyl propanoids, and sterol acylglucosides. The great variety of chemical structures presents many interesting questions regarding the relative toxicity, biochemical mechanisms, and environmental effects of fish poisons.

The result of Length-weight relationship of *Clarias gariepinus* juvenile exposed to ichthyotoxic plant *B. micrantha* and ameliorative activity of ascorbic acid as presented in table 1 shows that the experimental fish are in good conditions of health. The physicochemical parameters of fish culture water were all within acceptable limit for the growth and survival of *C. gariepinus* as earlier reported by Viveen *et al.* (1985) and Bruton (1988). Table 2 summarizes the range of the physicochemical parameters of control and treated fish observed during the experimental period. There was no significant difference among the different treatments in terms of physicochemical parameters measured. Table 2 summarizes the range of the physicochemical parameters of control and treated fish observed during the experimental period. There was no significant difference among the different treatments in terms of physicochemical parameters measured. Alkalinity significantly increased throughout the experiment. The result of the physicochemical parameters of the experimental media indicated a significant difference ($P < 0.05$) in the values obtained in the level of dissolved oxygen, content free carbon dioxide and alkalinity with the control. Nevertheless, there were no significant difference ($P > 0.05$) between the values of temperature and pH of test media with the control. The abnormal behaviour observed in fish exposed to the extract included respiratory distress, loss of balance, gulping of air, settling at the bottom motionless, and erratic swimming. Deborah *et al.*, (2023) carried out an Experiment to determine the effects of ascorbic acid water quality parameters of *Clarias gariepinus* subjected to road transportation. Group I (AAF) was administered ascorbic acid daily for one month and on the day of transportation while group II (NAF) was not administered. The dissolved oxygen content of group I was however higher ($P < 0.05$) in group I compared to group II. It was therefore concluded that ascorbic acid modulated some haematological and water quality parameters of *Clarias gariepinus* and may be beneficial to the fish in ameliorating the stress of transportation.

Owolabi and Abdulkareem (2021) reported that during laboratory studies, fish are usually returned to toxicant-free water after an exposure to initiate 'self' detoxification process sufficient to reverse any morphological, biochemical or physiological changes arising from such exposure. Earlier studies have shown that, after exposure, the normal physiology of fish could either be moderately restored (Adhikari *et al.*, 2004; Ramesh *et al.*, 2015) or fully restored (Maltez *et al.*, 2017) when relocated to water free of toxicant. However, information on fish recovery after ichthyotoxic exposure is obscured. Adhikari *et al.* (2004) stated that an understanding of fish recovery time after toxicant exposure could help in the maintenance of fish health status and that of its consumers. Fish, like

higher vertebrates, are generally endowed with an antioxidant system with which they eliminate free radicals generated by the ROS and recovered from oxidative stress. This system comprises enzymatic (e.g., superoxide dismutase and catalase) and non-enzymatic (e.g., α tocopherol (vitamin E) and ascorbic acid (vitamin C) antioxidants. Vitamin C is a chain-breaking, least toxic, most effective and widely used antioxidant that react with free radicals (Bielski, 1982), and thus, protects animals against oxidative damage (El-Keredy *et al.*, 2017). As important as it is, not all fish species are capable of synthesizing vitamin C. They, therefore, depend on exogenous sources to meet their requirements. Several reports are available on dietary efficacy of vitamin C in ameliorating pollutants toxicity to fish (Ambaliet *al.*, 2011, El-Keredy *et al.*, 2017).

Al-Agidi *et al.*, (2019) reported the results of Ameliorative Effect of Ascorbic Acid on hematological Parameters of *Cyprinus carpio* due to cadmium toxicity and showed significant differences at $P \leq 0.05$ between treatments with cadmium and control, ascorbic acid only and ascorbic acid with cadmium on haematological parameters. The results also showed the effect of Vitamin C (ascorbic acid) to reduce cadmium toxicity after 7 to 14 days after chronic exposure to CdCl₂ increased white blood cells number, mean corpuscular volume, Mean Corpuscular Haemoglobin and decreased RBC, Hb content, PCV and the mean corpuscular hemoglobin concentration as compared to control were found. The exposure of cadmium with ascorbic acid the WBC, RBC decreased and Hb contents, RBC, the packed cell volume PCV increase values of these parameters as that in control groups when compared with cadmium exposure groups. This work is similar to the result of the present in table 3 study on haematological alterations in the *Clarias gariepinus* exposed to *Brandelia micrantha*, the White blood cell (ul), Red blood cell (ul) Haemoglobin (g/dl), Lymphocytes (ul), Mean cell volume (fl), Mean cell Haemoglobin concentration increases from $1.72 \times 10^2 \pm 12.5$, $2.63 \times 10^6 \pm 3.3$, 11.08 ± 2.3 , 96.78 ± 1.0 , 41.20 ± 4.6 , and 35.88 ± 4.2 to $2.55 \times 10^2 \pm 19.3$, 12.80 ± 2.2 , $3.26 \times 10^4 \pm 2.7$, 99.96 ± 4.6 , $1.98 \times 10^2 \pm 0.6$, and 45.54 ± 5.6 respectively there was a decrease in the value of, Haematocrit (%), from 22.83 ± 2.5 to 10.36 ± 4.1 as presented in Table 3. Ameliorative effects of vitamin C on structural changes in the African Sharptooth Catfish *Clarias gariepinus*, Table 4 the White blood cell (ul), Red blood cell (ul), Haemoglobin (g/dl), Haematocrit (%), Platelet (ul), Lymphocytes (ul), Mean Cell Volume (fl), Mean Cell Haemoglobin (pg), Mean Cell Haemoglobin Concentration normalizes with the control $1.61 \times 10^2 \pm 22.9$, $2.41 \times 10^6 \pm 7.5$, 6.53 ± 4.2 , 16.94 ± 8.7 , $2.83 \times 10^4 \pm 2.0$, 95.43 ± 1.0 , $2.11 \times 10^2 \pm 5.6$, 48.98 ± 9.5 and 46.07 ± 12.9 as compare to control.

Deborah *et al.*, (2023) reported the ameliorative effects of ascorbic acid on hematological and water quality parameters following a 100 km transportation of adult *Clarias gariepinus* using two group of fish, they stated that erythrocyte counts, packed cell volume was significantly higher in group I ($P < 0.05$). Total leucocyte count, neutrophil count, and neutrophil/lymphocyte ratio of group I were significantly lower ($P < 0.05$) in group I compared to group II. The concentrations of nitrite, nitrate, and ammonia were significantly higher ($P < 0.05$) in group II compared to group I post-transportation. This work is similar to the work of Abdallah (2022) who reported significantly decrease in RBCs, hemoglobin content, hematocrit, total protein, albumin levels, and acetylcholinesterase activity activities compared to the control. Meanwhile, ABM significantly increased white blood cells, glucose, total lipids, cholesterol, and alanine and aspartate aminotransferase activities. Liver and kidney levels of lipid peroxidation was significantly increased, while hepato-renal antioxidant biomarkers (reduced glutathione, super oxide dismutase, catalase, and total antioxidant capacity) were significantly decreased upon Abamectin (ABM) exposure, during ameliorative effect of quercetin against abamectin-Induced Hemato-Biochemical Alterations and Hepatorenal Oxidative Damage in Nile Tilapia, *Oreochromis niloticus*. On the other hand, quercetin dietary supplementation improved the hemato-biochemical alterations and alleviated oxidative stress induced by Abamectin (ABM) exposure. Fish supplemented with quercetin at a level of 800 mg/kg diet showed better alleviating effects against ABM compared to 400 mg/kg diet. Based on these

study findings, we suggest that quercetin dietary supplementation (800 mg/kg) offered direct protection against ABM-induced physiological disturbance and oxidative stress in Nile tilapia (Abdallah 2022).

Abdallah (2022) also reported the effects of exposure to sublethal levels of ABM on several health and stress indicators of Nile tilapia, *Oreochromis niloticus*, and the potential protective effect of quercetin. Which show that the Abamectin(ABM) exposure significantly decreased total protein, albumin, globulin, and significantly increased total lipids, cholesterol, and glucose content in fish serum compared to the control. Dietary supplementation of quercetin significantly increased total protein and globulin, but total lipids, cholesterol, and glucose were not significantly affected by dietary quercetin compared to the control. The co-supplementation of dietary quercetin to ABM-exposed fish restored the levels of different examined biochemical parameters, especially in groups supplemented with 800 mg quercetin/kg diet, is similar to the present work on the alterations of the proximate composition of the Carcass in *Clarias gariepinus* exposed to *Brandelia micrantha*) is presented in table 5. The was a significant reduction in the value of proximate composition of the carcass after the exposure of *Clarias gariepinus* to *B. Micranthan* the Moisture (M), Crude Protein (CP) (Mg/l), Crude Lipid (CL), Ash, Nitrogen Free Extract (NFE), and Energy (kcal/100g) reduce from 66.24±6.9, 29.71±2.3, 3.49±0.4, 0.90±0.0, 0.38±0.1, and 1.37x10²±6.6 to 64.57±6.2, 26.21±1.3, 3.31±0.5, 0.83±0.1, 0.25±0.0, and 1.31x10²±4.0 respectively. The ameliorative effect of ascorbic acidon Carcass/Proximate composition of *Clarias gariepinus* juvenile is presented in table 6 at 125mg/l during 60day exposure period the values of proximate composition of the carcass after exposure of *Clarias garipinus* to Vitmin C Ascobic acid (AA) increases from Crude Protein (CP), Crude Lipid (CL), Energy K(cal)/mg, Moisture (M), Ash, and Nitrogen Free Extract (NFE) were 26.25±5.0, 3.34±0.6, 1.36x10²±5.3, 64.84±3.3, 0.92±0.1 to 0.49±0.21 to 27.87±2.1, 3.59±0.6, 1.38x10²±9.4, 67.47±5.0, 1.05±0.2, and 0.56±0.2 respectively, while the value of Crude Fiber (CF) 0.00 remains constant throughout.

The results of histological alterations in *Clarias gariepinus* exposed to *Brandelia micrantha*) is presented in Plate A Figure 1 - 24, at 15 days treatment 0.00mg/l control section of liver (X100)(H/E) shows normal hepatic architecture with normal hepatocyte (H) and central vein (C). at 60 days treatment 0.21mg/l section of liver (X100)(H/E) shows severe effect on the hepatic tissue with severe ground glass (GG) appearance of the cytoplasm and intra hepatic hemorrhage (IHH).The liver of fish from the control exhibited normal hepatocytes relative to those of ZnO-NPS-treated fish Pathological disorders observed were nuclear alteration, melanomacrophage centre, blood congestion or sinusoids, nuclear vacuolation, fibrosis, necrosis, cellular-, fatty and cytoplasmic degenerations. These disorders either occurred slightly or moderately within the first 15 d exposure irrespective of the concentration except necrosis that became severe at 12.00 mg/l (Table 3). Within 30 and 45 d exposure, nuclear alteration, melanomacrophage centre, blood congestion, nuclear vacuolation, necrosis and fibrosis were either slightly or moderately shown in all the treated groups, while fatty and cytoplasmic degenerations were observed as either slightly or moderately damaged between 6.0 and 10.0 mg/l but became severe at 12.0 mg/l ZnO-NPs concentration. At 60 d exposure, nuclear alteration, melanomacrophage centre, vacuolation, necrosis, fatty and cytoplasmic degenerations exhibited slight to moderate disorder in fish liver from 6-10mg/l ZnO-NPs treatments but became severe at 12.0 mg/l. However, blood congestion appeared as slight disorder at 10.0 mg/l and became severe at 12.0 mg/l, while fibrosis occurred as slight and moderate disorder in all the treated groups (Owolabi and Abdulkareem(2021).

The results of histological alterations in the kidney of *Clarias gariepinus* exposed to *Brandelia micrantha* at 15 days in treatment 0.00mg/l control is presented in Figs 25, 30,37 and 43 these sections of the kidney (x400) (H/E) shows normal renal tissue arrangement. At 60 days treatment 0.21 mg/l Figs. 30, 36, 42 and 48 section of kidney (x400) (H/E) shows severe degeneration of the renal tissue with severe intra renal necrosis (TN) and inflammatory cell aggregate (IC) with tubular atrophy (TA) in some areas. The result of histological alterations in the gill of *Clarias gariepinus* exposed to *Brandelia micrantha* at 15 days in treatment 0.00 mg/l Figs 49, 55, 61 and 67 control section of gill (X150)(H/E) shows normal gill architecture with well projected filament (PF), gill epithelium (GE) and cartilages (C). The result at 60 days of Treatment 0.21 mg/l Figs 54, 60, 66 and 72 section of gill (X150)(H/E) shows severe effect on the gill architecture with hypertrophy of the gill arch, gill filament degeneration and aggregate of inflammation (AI). This is similar to the work Owolabi and Abdulkareem(2021), stated that the higher the concentration and duration of ZnO-NPs exposure increased with the increase in concentration and exposure time, the severity of gill damage increased. While hyperplasia slightly occurred in all treatments between 15 and 45 d exposure and became severe at the highest concentration (12 mg/l) after 60 d, epithelial lifting and curling of lamellae were not observed until 45 d exposure at 12 mg/l concentration and 60 d exposure at 8 mg/l concentration respectively. Lamellar fusion occurred moderately in all the treated groups between 15 and 45 d exposure. Lamellar disorganisation occurred moderately at 12 mg/l within the first 15 d exposure and subsequently

Ameliorative effects of vitamin C on structural changes in the African Sharptooth Catfish *Clarias gariepinus* at 15 days treatments 10, Figs 74, 80 and 86 section of gill (X150)(H/E) shows severe effect on the gill architecture with severe clumping (C) necrotic (N) filament and areas of hemorrhage (H); at treatment 15 Figs 75, 81, and 87, section of gill (X150)(H/E) shows severe effect on the gill architecture with severe areas necrotic filament (NF); at Treatment 20 Figs. 76, 82, and 88 section of gill (X150)(H/E) shows mild effect on the gill architecture with mild hypertrophied (H) filament. treatments 10, 15, 20, 25 and 30 at 60 days Fig 91, 92, 93, 94, 95 and 96 at 60 days (X150)(H/E) section of gill (X150)(H/E) shows normal gill architecture with well projected filament (PF), gill epithelium (GE) and cartilages (C). treatment 10mg/l Fig 98, 104 and 110 at 15 to 45 days section of liver (X100)(H/E) shows severe effect on the hepatic tissue with severe ground glass (GG) appearance of the cytoplasm and moderate intra hepatic hemorrhage (IHH). treatment 10mg/l Fig 98, 104 and 110 at 15 to 45 days section of liver (X100)(H/E) shows severe effect on the hepatic tissue with severe ground glass (GG) appearance of the cytoplasm and moderate intra hepatic hemorrhage (IHH). Trt 15 Figs. 99, 105, and 111 section of liver (X100)(H/E) shows severe effect on the hepatic tissue with severe focal area of ovum of parasite (OP) in the liver parenchyma and fibrous strand (FS). Fig. 115, 116, 117, 118, 119 and 120 section of liver (X100)(H/E) at 60 days shows normal hepatic architecture with normal hepatocyte (H) and central vein (C).

Ameliorative effects of vitamin C on structural changes in the African Sharptooth Catfish *Clarias gariepinus* of Treatment 0.00 mg/l Figs 121, 127, and 133 section of kidney(X150)(H/E) control section at 15 minute shows normal renal tissue with severe aggregate of inflammation (AI) with eosinophilic (E) tubules. At 60 days treatment 30 mg/l figures 126, 132, and 138 of kidney(X150)(H/E) shows normal renal architecture with active glomeruli (G) renal tubules (RT) and tubular cell (TC)., Fig. 139, 140, 141, 142, 143 and 144, section of kidney(X150)(H/E) at 60 days of the experiment with ascorbic acid shows normal renal architecture with active glomeruli (G) renal tubules (RT) and tubular cell (TC). In a similar work after 15 days depuration, the

quantitative evaluation of recovery responses in fish treated with 6, 8 and 10 mg/l concentrations of ZnO-NPs revealed similar gill damage compared to those observed when the fish were subjected to same concentrations for 60 d; as their DTC fell within 21 and 50 categorised as moderate damage, indicating no recovery. The lesions in 12 mg/l treated group after 15 d recovery were also not reversed from being severe as their DTC value was 52.70 compared to the DTC obtained (78.50 ± 1.15) during 60-day exposure. At the end of 30 d, however, there was a gradual recovery from moderately damaged to normal organ at 6 mg/l (DTC 5.20 ± 0.05), moderately damaged to slightly damaged at 8 mg/l (DTC 14.30 ± 0.03), and severely damaged to moderately damaged at 10 (DTC 28.20 ± 0.30) and 12 mg/l (31.50 ± 0.06), respectively. After 15 d, the DTC in fish liver from 6, 8 and 10 mg/l recovery groups ($27.00 \pm 0.00 - 49.20 \pm 0.05$) compared to those observed from the same groups during the 60 d exposure ($36.20 \pm 0.17 - 68.50 \pm 0.64$) indicated recovery from severely damaged organ to moderate, while DTC in the liver of fish in 12.0 mg/l group (62.60 ± 9.56) showed no recovery. At the end of 30 d recovery, the DTC in the liver of fish in 6 mg/l treated group showed slight damage (13.10 ± 0.00), while those in other groups ($21.00 \pm 0.00 - 36.00 \pm 0.12$) exhibited moderate damage (Owolabi and Abdulkareem, 2021)

Conclusion

Ameliorative effects of ascorbic acid on ichthyotoxic plant *Bridelia micrantha* induced haematological, histological and plasma biochemical alterations in African Catfish *Clarias gariepinus* juvenile shows partial and full recovery at 125mg/l of ascorbic acid after 60 days exposure period. Chronic exposure during fishing of African catfish *Clarias gariepinus* to ichthyotoxic plant *Bridelia micrantha* (BM) causes increased haematological, histological and plasma biochemical alterations. The results of histological alterations in *Clarias gariepinus* exposed to *Brandelia micrantha* at 60 days of treatment shows severe effect on the gill architecture with hypertrophy of the gill arch, gill filament degeneration and aggregate of inflammation (AI), the liver shows moderate to severe effect on the hepatic tissue with severe effect on the hepatic tissue with severe ground glass (GG) appearance of the cytoplasm and intra hepatic hemorrhage (IHH) while the kidney shows severe degeneration of the renal tissue with severe intra renal necrosis (TN) and inflammatory cell aggregate (IC) with tubular atrophy (TA) in some areas.

The mean level tissue change in both organs of *B. micrantha* (BM) exposed fish gradually increased with increase in *Bridelia micrantha* (BM)-concentration and exposure period. The recovery of fish from *Bridelia micrantha* (BM) was evaluated by exposing fish to a 60-days depuration. Ascorbic acid (AA) ameliorative potential against *Bridelia micrantha* (BM) toxicity was assessed by placing the fish on ascorbic acid (AA)-supplemented diet at 0.00, 25, 50, 75, 100, and 125mg/l levels. After 60-day depuration, some of the lesions in tested organs attained partial and full recovery. Ascorbic Acid administration to *Bridelia micrantha* (BM)-exposed fish at 125mg/l indicated partially and completely reversed the lesions, the gill shows normal gill architecture with well projected filament (PF), gill epithelium (GE) and cartilages (C), liver shows normal hepatic architecture with normal hepatocyte (H) and central vein (C) while the kidney with ascorbic acid shows normal renal architecture with active glomeruli (G) renal tubules (RT) and tubular cell (TC) after 60-days depuration, some of the lesions in both haematological and proximate composition of the carcass attained recovery. Ascorbic acid administration to *Brandelia micrantha* exposed fish at 125 mg/l completely reversed the lesions in both blood and nutrient composition compared to the in the control.

References

- Abalaka S E (2013) Evaluation of the haematology and biochemistry of *Clarias gariepinus* as biomarkers of environmental pollution in Tiga dam, Nigeria. *Braz Arch BiolTechnol* 56: 1-7.
- Abdallah Tageldein Mansour, Heba H. Mahboub, Rehab M. Amen, Marwa A. El-Betagy, Amany Ramah, Abdefattah M. Abdelfattah, Hossam S El-Beltagi, Tarek A Shalaby, Hesham S Ghazzawy, Khaled M, A. Ramadam, Adnan H M. Alhaji and Heba S Hamed (2022) Ameliorative Effect of Quercetin against Abamectin-Induced Hemato-Biochemical Alterations and Hepatorenal Oxidative Damage in Nile Tilapia, *Oreochromis niloticus*, *Animals* (Basel 2022 Dec; 12(23): 3429. Published online 2022 Dec 5. doi: 10.3390/ani12233429.
- Abdulkareem, S.I. (2017). Toxicity of zinc oxide nanoparticles on some biological parameters of *Heterobranchus longifilis* and ameliorative potentials of ascorbic acid. Ph.D. Thesis, Department of Zoology, University of Ilorin, Nigeria. 258 pp.
- Ambali Suleiman F, Joseph O Ayo, Samuel A Ojo and King AN Esievo (2011) Ameliorative effect of vitamin C on chronic chlorpyrifos-induced erythrocyte osmotic fragility in Wistar rats. DOI: 10.1177/09603271110368415 *Human and Experimental Toxicology* 30(1) 19–24
- Amoatey P and Baawain M S (2019) Effects of pollution on freshwater aquatic organisms. *Water Environment Research*. 91: 1272-1287.
- Adhikari, S.; Sarkar, B.; Chatterjee, A.; Mahapatra, C.T. and Ayyapan, S. (2004). Effects of cypermethrin and carbofuran on certain haematological parameters and prediction of their recovery in a freshwater teleost, *Labeorohita* (Hamilton). *Ecotoxicol. Environ. Saf.*, 58 (2): 220-226. Doi: 10.1016/j.ecoenv.2003.12.003.
- Ayotunde EO, and Ofem BO. (2008) Acute and chronic toxicity of pawpaw to adult Nile tilapia (*Oreochromis niloticus* Linne 1757) fingerlings. *African Journal of Biotechnology*. 7(13):2265–2274.
- Ayotunde, Ezekiel Olatunji (2019) Fish Habitat Health and Integrity: The Key to Sustainable Fisheries and Protein Malnutrition, the 3rd Inaugural Lecture series, Cross River University of Technology (CRUTECH) Calabar on 31st October 2019. Pp134.
- Ayotunde, E. Olatunji, Igbang Sunday K. (2023). Effect of Aqueous Extract of Ichthyotoxic Plant *Bridelia micrantha* (Hochst) (Baill) on Haematology, Histopathology and Carcass Characteristics of African Catfish (*Clarias gariepinus*) (BURCHELL, 1822) Juvenile. *J Mari Scie Res Ocean*, 6(3), 106-122.
- Al-Agidi, Al-Agidi Hamza G., Kadhim O.M. AL-Humairi and Sadeq M. Al-Haider (2019) Ameliorative Effect of Ascorbic Acid on Hematological Parameters Due to Cadmium Toxicity in *Cyprinus carpio*. *Indian Journal of Ecology* 46 Special Issue (8): 36-39
- AOAC. (1990) Official Methods of Analysis, 15th edn. Washington, DC USA: Association of Official Analytical Chemists, pp. 69 – 88.

- Bielski, B.H. (1982). Chemistry of ascorbic acid radicals, ascorbic acid: chemistry, metabolism and uses. *Advanced Chemistry, Series*, 200: 81-100.
- Bancroft, J. D., Cook, H. C., & Stirling, R. W. (1994). Manual of histological techniques and their diagnostic application. In *Manual of histological techniques and their diagnostic application* (pp. 457-457).
- Cannon Ak, J. G., Burton, R. A., Wood, S. H. and Owen, N. L (2004). "Naturally occurring fish poisons from plants". *Journal of Chemical Education* 81(10):1457-1461.
- Connell, D., P. Lam, B. Richardson and R. Wu. (1999) *Introduction to Ecotoxicology*, Oxford, England, Blackwell Science.
- Deborah Adah Arimie, Adah Sylvanus Adakole, Nwonuma Charlse Obiora, Olaosebikan Boluwaji, and Oyekunle Taiwo (2023) Ameliorative effects of ascorbic acid on hematological and water quality parameters following a 100 km transportation of adult *Clarias gariepinus*. *Media Kedokteran Hewan* 34(1):13-26, DOI:10.20473/mkh.v34i1.2023.13-26.
- DeSilva, S.S. (1991). *Fish Nutrition Research in Asia. Proceedings of the Fourth Asian Fish Nutrition Workshop*. 217 pp.
- El-Keredy, M.S.; Abeer, M-S.; Amany, M.D.; Gehan, I.E.A. and Walid, S.K. (2017). Effect of dietary vitamin C and β -Glucan to alleviate the toxic effect of copper sulphate in *Tilapia* fish. *Alex. J. Vet. Sci.*, 55 (2): 36-49. Doi:10.5455/ajvs.276295.
- Fafioye O (2005). Plants with piscicidal activities in south western Nigeria. *Turkish Journal of Fisheries and Aquatic Science*. 5: 91-97.
- Gill, L.S. (1992). *Ethnomedical uses of Plants in Nigeria*. University of Benin Press. Benin, Nigeria. P.276.
- Gupta P.K. (1977) *Haematological Techniques*. 4th ed. Syndicate; London, UK: p. 231.
- Maltez, L.C.; Stringhetta, G.R.; Enamorado, A.D.; Okamoto, M.H.; Romano, L.A.; Monserrat, J.M.; Sampaio, L.A. and Garcia, L. (2017). Ammonia exposure and subsequent recovery trigger oxidative stress responses in juveniles of Brazilian flounder *Paralichthys orbignyanus*. *Fish Physiol. Biochem.*, 43 (6): 1747-1759. <https://doi.org/10.1007/s10695-017-0406-8>
- Neuwing HD (2004) Plants used for poison fishing in tropical Africa. *Toxicon* 44(4):417-430.
- Ramesh, M.; Narmadha, S. and Poopal, R.S. (2015). Toxicity of furadan (carbofuran 3% g) in *Cyprinus carpio*: Haematological, biochemical and enzymological alterations and recovery response. *Beni-Suef Uni. J. Basic Appl. Sci.*, 4: 314-326.
- OECD (1992). Organisation for Economic Cooperation and Development. *Guidelines for testing of chemicals. Guideline no. 203*, 10. Fish, acute toxicity test.
- Okechi JK (2004) Profitability assessment: A case study of African catfish (*Clarias gariepinus*) in the Lake Victoria basin, Kenya. *Fisheries Training Programme, The United Nations University, Iceland*. Pp: 17-22.

- Osuagwu, G.G.E. and Ibeabuchi, I.C. (2010). The influence of aqueous leaf and stem extracts of *Adenialobata* (Jacq) on the flowering and fruiting of okra (*Abelmoschus esculenta*) and groundnut (*Arachis hypogea*) *African Journal of Biotechnology* 9: 3260-3263.
- Owolabi, Olufemi D. and Abdulkareem, Saratu I. (2021) Effects of vitamin C on structural changes in the tissues of the giant African catfish, *Heterobranchus longifilis* exposed to Zinc Oxide nanoparticles *Egyptian Journal of Aquatic Biology & Fisheries Zoology Department, Faculty of Science, Ain Shams University, Cairo, Egypt. ISSN 1110 – 6131 Vol. 25(5): 103 – 129* www.ejabf.journals.ekb.eg.
- Onusiriuka, B. C, & Ufodike E. B. C. (1998)., Effect of sub lethal concentration of Akee Apple – *Blighia sapida* and sausage plant, *Kigelia Africana* on tissue chemistry of African catfish, *Clarias gariepinus* (L). *AJOL J. Aqua. Sci.* Vol. 15.
- Vimal J B and Das S M (2015). Toxicity of *Euphorbia antiquorum* latex extracts to freshwater fish *Poeciliareticulata*. *International Journal of Fisheries and Aquatic Studies*. 2: 214-216.
- Viveen, W.J.A.R., Rither, C.J.J., van Oordt, P.G.J., Janssen, J.A.L., Huisman, E.A., (1985). Practical Manual for the Culture of the African catfish (*Clarias gariepinus*). Directorate General for International Technical Cooperation, The Hague, Netherlands, p. 93.
- Suleiman, B.; Maruff, L. and Oniye, S.J. (2015). Radiographic studies on morphological anomalies in artificially spawned *Heterobranchus longifilis* Valenciennes, 1840 F1 generation. *Sokoto J. Vet. Sci.*, 13 (1): 9-16.
- Svobodova D. Ravds, J. & Palackova, (1991): Unified method of Haematological examination of fish. Research Inst. of Fish Culture and Hydrobiology. Vonnony Czechoslovakia.