

## Case report

# Complete Atrioventricular Block Reveals Rare Transthyretin Cardiac Amyloidosis: Case Report

### ABSTRACT

**Introduction:** Atrioventricular block in the context of cardiac amyloidosis is often the result of amyloid infiltration of the conduction pathways. This degenerative process disrupts the transmission of electrical impulses along conduction fibers, resulting in symptoms such as bradycardia, syncope and even cardiac arrest.

**Case Report:** This is a case report of transthyretin cardiac amyloidosis in an 81-year-old patient who was admitted to hospital for an episode of syncope with an electrocardiogram showing complete atrioventricular block. Transthoracic echocardiography demonstrated biventricular infiltrative cardiomyopathy and Cardiac MRI confirmed the presence of amyloid deposits on late enhancement sequences after Gadolinium injection.

**Conclusion:** Early diagnosis of cardiac amyloidosis is crucial to improving patient prognosis, and this requires particular attention to the presence of conduction disorders such as AVB. Management includes pacemaker implantation, combined with specific treatment depending on the type of amyloidosis, such as specific transthyretin stabilizers in ATTR cardiac amyloidosis.

**Keywords:** Transthyretin Cardiac Amyloidosis, Atrioventricular Block, case report

## 1. INTRODUCTION

Amyloidosis is the manifestation of several systemic diseases whose common feature is an extracellular accumulation of insoluble fibrillar proteins that are deposited and progressively invade tissues, preventing them from functioning properly.

Cardiac amyloid (CA) infiltration is responsible for thickening of the myocardium, creating an aspect of false 'hypertrophy' which is complicated by heart failure and conduction disorders (1).

"Dozens of amyloidogenic proteins have been identified, but the most commonly encountered forms in clinical practice are systemic immunoglobulin light chain and transthyretin amyloidosis (ATTR). ATTR cardiac amyloidosis (ATTR-CA) is further subdivided into wild-type (wtATTR) and hereditary (hATTR) types, depending on the absence or presence of mutation in the precursor protein gene". (2).

Cardiac impulse conduction disorders and atrial arrhythmias are more frequent in ATTR than in the AL form, and this seems to reflect the longer survival of patients affected by ATTR, given that the AL form manifests with high mortality up to 6 months from diagnosis, because conduction system disease appears to be a later manifestation. (3)

We describe a case of complete AV block secondary to ATTR cardiac amyloidosis.

## 2. Case Presentation

An 81-year-old man presented to the emergency department after a brief episode of syncope without prodrome. The patient was alert and oriented after the episode, and witnesses reported no convulsive activity. He had no previous history of syncope. His blood pressure was 190/80 mm Hg and his heart rate was 35 to 40 beats/min. His temperature, oxygen saturation and respiratory rate were normal, as were the rest of his physical examination.

An electrocardiogram (ECG) revealed complete atrioventricular block (AVB). No previous ECG was available. [17]

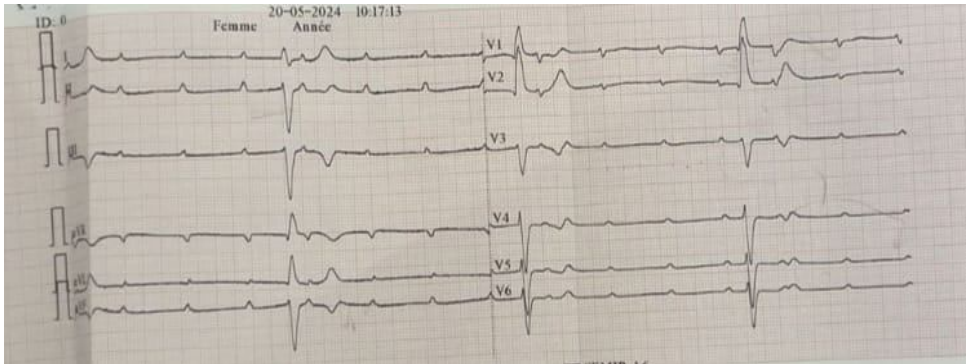


Fig. 1. The electrocardiogram (ECG) shows complete atrioventricular block (AVB).

The patient had a complete blood count, electrolytes, renal function, liver enzymes and normal thyroid-stimulating hormone levels which ruled out electrolyte abnormalities and thyroid disease as causes of heart block. Ultrasensitive troponin T assays were slightly elevated (17, 54 and 73 [reference values 0-14] ng/L). We admitted the patient to hospital for further investigations, including analysis of C-reactive protein levels, immunoglobulins, vasculitis panel and blood cultures, all of which were negative. Thus, you considered it unlikely that heart block was caused by infectious or autoimmune diseases.

After hospitalization, the patient experienced multiple episodes of dizziness and symptoms approaching syncope, with a heart rate dropping into the 20s. We inserted an emergency temporary venous pacemaker.

Transthoracic echocardiogram (TEE) revealed infiltrative cardiomyopathy with significant concentric left ventricular hypertrophy, right ventricular hypertrophy, left atrial hypertrophy and thickened non-stenotic valves, moderate tricuspid regurgitation estimating a pulmonary artery systolic pressure of 36 mmHg, preserved left ventricular ejection fraction and minimal pericardial effusion opposite the right cavities. Left ventricular global longitudinal strain (GLS) was reduced with an apical sparing pattern suggesting cardiac amyloidosis. The coronary angiography showed atheromatous overload without significant lesions. Cardiac MRI (CMRI) showed amyloid deposits visualized by late enhancement after Gadolinium injection in T1 sequence with cancellation of the healthy myocardial signal.

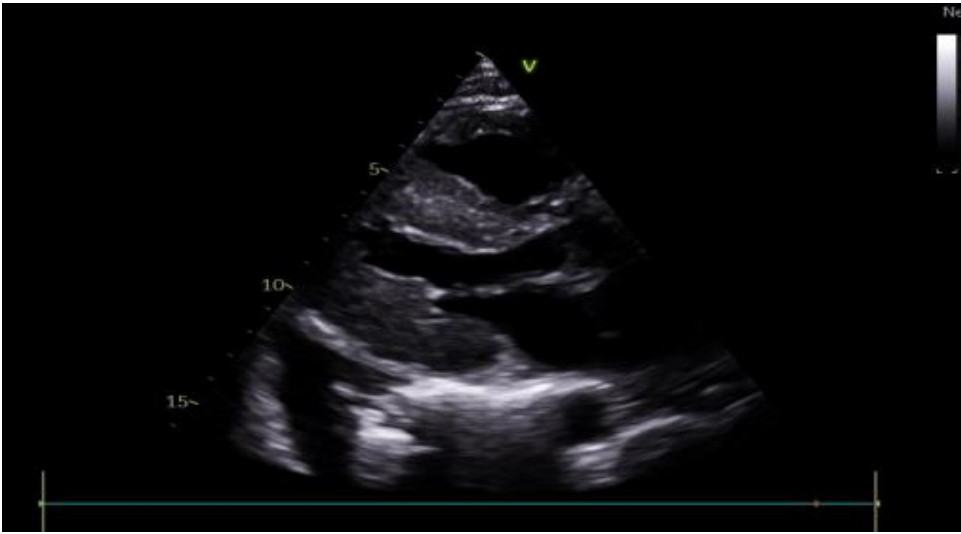

Fig. 2. Parasternal long-axis view on echocardiography demonstrates diffuse concentric left ventricular hypertrophy

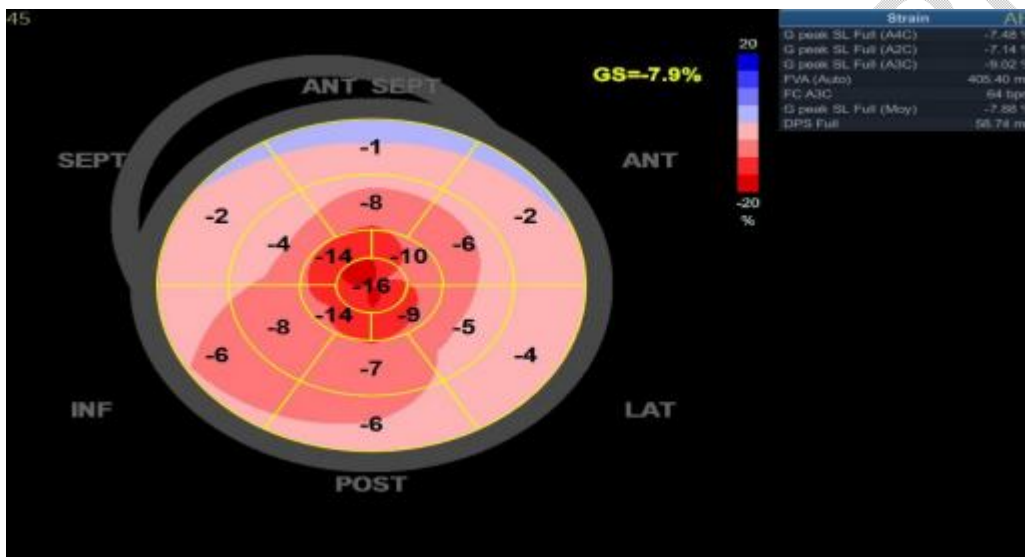


Fig. 3. Apical sparing pattern of left ventricular (LV) longitudinal strain

Consequently, the patient underwent diagnostic testing for amyloid cardiomyopathy. AL amyloidosis was excluded by electrophoresis and immunofixation of serum and urine proteins. Biopsy of accessory salivary glands reveals abundant amyloid deposits. Genetic testing showed no mutations in the transthyretin gene. The diagnosis retained is therefore senile amyloidosis with cardiac involvement.

We inserted a permanent venous pacemaker and specific treatment with a transthyretin tetramer stabilizer was started.

### 3. Discussion:

“Cardiac amyloidosis is frequently associated with cardiac electrical abnormalities, that can lead to conduction or rhythm disorders. Moreover, these abnormalities, which may occur several years before the specific diagnosis of cardiac amyloidosis, may require the implantation of cardiac prostheses such as pacemakers or defibrillators” (3).

“Conduction system disease from amyloid infiltration commonly manifests as atrioventricular nodal disease, often preceding the diagnosis of CA and resulting in pacemaker implantation in about 10% of ATTR patients” (2).

"The prevalence of pacemaker implantation is reported to be highest in patients with wtATTR, potentially attributed to old age and chronic amyloid deposition over the course of many years"(2,9).

"The pathogenesis of conduction system disease in cardiac amyloidosis is multifactorial including amyloid deposition causing a disruption of the transmission of electrical impulses along of the conduction fibers and the cytotoxicity of amyloid precursor proteins" (4,8).

"The diagnostic evaluation in suspected cardiac amyloidosis includes electrocardiography, echocardiography, and CMR and in certain cases requires a myocardial biopsy"(5).

"In amyloidosis, high-grade auriculoventricular blocks are common, also responsible for significant morbimortality, and sometimes a sudden onset with no warning conductive disorders on previous electrocardiograms" (10). "Preventive strategies of bradyarrhythmia's and symptomatic bradycardias suggest the use prophylactic pacemaker implantation in patients with ATTR cardiac amyloidosis who present conduction disorders in the ECG, such as fascicular blocks (right bundle branch block, left bundle branch block, left anterior hemiblock, and left posterior hemiblock), first-degree AV block (PR interval  $\geq 200$  ms), or Wenckebach anterograde point  $\leq 100$  b.p.m" (14,15). "Some therefore recommend a systematic electrophysiological exploration at the time of diagnosis, to be repeated in case of changes in the surface electrocardiogram" (10,11).

"Pacemakers are commonly required in patients with CA. Analysis of 145,900 hospitalizations across the United States demonstrated that 3.9% of those with CA and documented arrhythmias had pacemakers" (11). "In a 10-year retrospective review of 262 patients with ATTR-CA, a pacemaker was inserted in 45% of cases" (12).

"Furthermore, a high burden of right ventricular pacing is associated with deleterious consequences. In a retrospective observational cohort study of 78 patients with ATTR-CA and cardiac implantable electronic devices, a pacing burden  $>40\%$  was shown to result in adverse structural and clinical consequences, including worsening NYHA functional class, left ventricular ejection fraction (LVEF), and an increased severity of mitral regurgitation" (13).

"Patients with CA appear to be particularly vulnerable to the interventricular and intraventricular desynchrony brought about by RV pacing, given their restrictive physiology. As a corollary, biventricular pacing has been associated with improvements in NYHA functional class, LVEF, and mitral regurgitation severity" (13). Summarizing this evidence, biventricular pacing should be considered when an indication for pacing emerges, because single-chamber pacing can result in a high RV pacing burden and eventual clinical deterioration.

"ATTR-CA is a disease whose diagnosis and prognosis have changed significantly in the last 4 years with the arrival of Tafamidis. The ATTR-ACT showed that Tafamidis was associated with a reduction in all-cause mortality, decrease in cardiovascular (CV)-related hospitalizations, and reductions in the decline of functional capacity and quality of life" (16).

"The management of arrhythmias and conduction disorders in cardiac amyloidosis is a multifaceted challenge. Advancements in understanding their pathophysiology and epidemiology have been made, but the complex interplay of various factors demands ongoing research to refine therapeutic strategies. The evolving landscape of medical therapies and the increasing longevity of patients with cardiac amyloidosis underscore the necessity for a comprehensive and personalized approach to arrhythmia management in this unique population" [17].

#### 4. CONCLUSION

Atrioventricular block can be a telltale sign of underlying cardiac amyloidosis, particularly when it occurs without any other identifiable cause. Amyloid infiltration into the cardiac conduction system causes a plethora of electrophysiological dysfunction, most commonly atrial fibrillation. There is also increasing recognition of other important sequelae, including AV nodal disease and ventricular arrhythmias. The current evidence base for both electrophysiological interventions and the effect of new disease-modifying therapies on cardiac amyloidosis-related arrhythmias is sparse.

## DISCLAIMER (ARTIFICIAL INTELLIGENCE)

AUTHOR(S) HEREBY DECLARE THAT NO GENERATIVE AI TECHNOLOGIES SUCH AS LARGE LANGUAGE MODELS (CHATGPT, COPILOT, ETC) AND TEXT-TO-IMAGE GENERATORS HAVE BEEN USED DURING WRITING OR EDITING OF MANUSCRIPTS.

## CONSENT

WRITTEN INFORMED CONSENT WAS OBTAINED FROM THE PATIENTS FOR PUBLICATION OF THIS CASE REPORT AND ANY ACCOMPANYING IMAGES.

## ETHICAL APPROVAL

AS PER INTERNATIONAL STANDARDS OR UNIVERSITY STANDARDS WRITTEN ETHICAL APPROVAL HAS BEEN COLLECTED AND PRESERVED BY THE AUTHOR(S).

## AVAILABILITY OF DATA AND MATERIAL

ALL DATA GENERATED OR ANALYSED DURING THIS STUDY ARE INCLUDED IN THIS PUBLISHED ARTICLE.

## COMPETING INTEREST

THE AUTHORS DECLARE THAT THEY HAVE NO COMPETING INTERESTS

## REFERENCES

1. Nienhuis HL, Bijzet J, Hazenberg BP. The Prevalence and Management of Systemic Amyloidosis in Western Countries. *Kidney Dis (Basel)*. 2016 Apr;2(1):10-9.
2. Bukhari S. Cardiac amyloidosis: state-of-the-art review. *Journal of Geriatric Cardiology*, 2023, 20(5): 361-375. doi.org/10.26599/1671-5411.2023.05.006
3. Ruberg F.L., Grogan M., Hanna M., Kelly J.W., Maurer M.S. "Transthyretin amyloid cardiomyopathy: JACC state-of-the-art review". *J Am Coll Cardiol* 2019;73:2872-2891.
4. Grogan M., Scott C.G., Kyle R.A., et al. "Natural History of Wild-Type Transthyretin Cardiac Amyloidosis and Risk Stratification Using a Novel Staging System". *J Am Coll Cardiol* 2016;68:1014-1020
5. Kittleson M.M., Maurer M.S., Ambardekar A.V., et al. "Cardiac amyloidosis: evolving diagnosis and management: a scientific statement from the American Heart Association". *Circulation* 2020;142:e7e22.
6. Jacobson D.R., Alexander A.A., Tagoe C., Buxbaum J.N. "Prevalence of the amyloidogenic transthyretin (TTR) V122I allele in 14 333 African-Americans". *Amyloid* 2015;22:171-174.
7. Pan J.A., Kerwin M.J., Salerno M. "Native T1 mapping, extracellular volume mapping, and late gadolinium enhancement in cardiac amyloidosis: a meta-analysis". *J Am Coll Cardiol* 2020;13:1299-1310.
8. Jack H, Wael J, Matthew M, Brett S, Mazen H, Patrick C, et al. Electrophysiological manifestations of cardiac amyloidosis. *JACC Cardio Oncol*. (2021) 3:506–15. doi: 10.1016/j.jacc.2021.07.010
9. López-Sainz Á, de Haro-Del Moral FJ, Dominguez F, et al. Prevalence of cardiac amyloidosis among elderly patients with systolic heart failure or conduction disorders. *Amyloid* 2019;26:156–63.
10. Kristen, A.V., Dengler, T.J., Hegenbart U., Schonland, S.O. Prophylactic implantation of cardioverter-defibrillator in patients with severe cardiac amyloidosis and high risk for sudden cardiac death. *Heart Rhythm*, 5(2), 235-240
11. Isath A., Correa A., Siroky G.P., et al. "Trends, burden, and impact of arrhythmia on cardiac amyloid patients: a 16-year nationwide study from 1999 to 2014". *J Arrhythmia* 2020;36:727-734.
12. Algalarrondo V., Dinanian S., Juin C., et al. "Prophylactic pacemaker implantation in familial amyloid polyneuropathy". *Heart Rhythm* 2012;9:1069-1075.
13. Donnellan E., Wazni O.M., Saliba W.I., et al. "Cardiac devices in patients with transthyretin amyloidosis: impact on functional class, left ventricular function, mitral regurgitation, and mortality". *J Cardiovasc Electrophysiol* 2019;30:2427-2432

14. Eoin Donnellan, MD, Oussama M. Wazni, MD, Walid I. Saliba et al "Prevalence, Incidence, and Impact on Mortality of Conduction System Disease in Transthyretin Cardiac Amyloidosis" 0002-9149/© 2020 Elsevier Inc
15. Briasoulis A, Kourek CH, Papamichail A, Loritis, Bampatsias D et al " Arrhythmias in Patients with Cardiac Amyloidosis: A Comprehensive Review on Clinical Management and Devices" *J. Cardiovasc. Dev. Dis.* **2023**, *10*(8), 337; <https://doi.org/10.3390/jcdd10080337>
16. Shah SJ, Fine N, Garcia-Pavia P, et al. Effect of Tafamidis on Cardiac Function in Patients With Transthyretin Amyloid Cardiomyopathy: A Post Hoc Analysis of the ATTR-ACT Randomized Clinical Trial. *JAMA Cardiol* **2023**;Nov 15
17. Hartnett J, Jaber W, Maurer M, Sperry B, Hanna M, Collier P, Patel DR, Wazni OM, Donnellan E. Electrophysiological manifestations of cardiac amyloidosis: JACC: CardioOncology state-of-the-art review. *Cardio Oncology*. 2021 Oct 1;3(4):506-15.

UNDER PEER REVIEW