

Case report

Osteoid osteoma treated with Computed tomography-guided percutaneous microwave Thermo-ablation: A Case report

Abstract:

Background: Osteoid osteomas are one of the most common bone tumors. Although benign, they can cause significant pain and distress to the afflicted patient. The main goal of treatment is to relieve pain. More recently, microwave ablation has gained popularity.

The aim is to report a case and the place of computed tomography (CT) guided percutaneous microwave thermo-ablation in osteoid osteoma management.

Case report: A case of osteoid osteoma of the iliac bone managed by CT-guided percutaneous microwave thermo-ablation with good results.

Conclusion: treating osteoid osteomas with percutaneous microwave thermo-ablation is a safe and effective technique. The disappearance of pain is the first parameter used to define whether the treatment is effective.

Keywords: Iliac bone; Interventional radiology; Microwave ablation; Osteoid osteoma; Thermoablation.

Introduction: “Osteoid osteomas (OO) are benign bone-forming tumors that typically occur in children (particularly adolescents). They have a characteristic lucent nidus <1.5 or 2 cm and a surrounding osteosclerotic reaction, which classically causes night pain that is relieved by the use of aspirin and nonsteroidal anti-inflammatory medications (NSAIDs)” [1,2].

Recently, several treatment methods less invasive than surgery have been proposed as alternative treatments for OO. Computed tomography (CT)-guided microwave thermo-ablation (MWA) is a method that is less invasive than surgery, ambulatory, and therefore represents a substantial saving with promising outcomes [3-5,10].

A case of OO treated with CT-guided percutaneous MWA is reported.

Case report: A 28-year-old man presented with seven months of fessialgia. This pain is exacerbated at night and was rebellious to routine antalgic. Spinal examination showed no radicular sign, and the cox-femoral joints were free. There was no sign of sacroiliac inflammation joints. Neurological and osteoarticular examinations were unremarkable. Locally, no dermatological lesions were noted. The clinical examination showed no abnormalities. Routine blood test was normal. A plain X-ray was normal. A pelvic CT scan showed, on bone view, a typical OO. The conservative management was done over 5 months but failed to manage the pain. The OO was treated with CT-guided percutaneous MWA (Figure 1). The pain was controlled with good follow-up and the patient was satisfied. With 10 months of follow-up, no recurrence was noted.

Discussion: “OO is a benign bone tumor, accounting for 12% of all benign bone tumors. They are most frequently found in the cortex of long bones and predominate in males in their second decade of life (with a male-to-female ratio of 4:1). The solitary tumor is small (<1.5 cm) and composed of sclerotic bone with a central vascular nidus surrounded by osteoblasts” [2,4,6].

The OO frequently affects the bones of the femur and tibia. Unlike most bone tumors, osteoid osteoma does not have a predilection site along the long bone. It is epiphyseal, metaphyseal, and diaphyseal and can be ossified at the level of the cortex or the cancellous bone. So, the OO can be found at the level of a joint surface, which will cause a significant synovial reaction.

“Microscopically, the central nidus is comprised of highly vascularized bone and intertwined osteoid. Remodeling of the bone occurs through osteoblastic activity. In the periphery of the nidus, an area of lucency is visible due to the resorption of bone from osteoclastic activity. New bone formation occurs around the nidus and appears to be sclerotic” [6-9].

“An OO typically presents with a nidus of vascular osteoid with surrounding sclerotic bone. OO do not exceed a diameter of 2 cm and are classified into cortical, cancellous, and subperiosteal subtypes. When the lesion is intracapsular, the presentation is more atypical and more likely to mimic inflammatory arthropathy or synovitis. Joint effusion is often present” [5,7,8].

Clinically, patients present with intermittent, localized pain exacerbated at night and relieved by aspirin or nonsteroidal anti-inflammatory medications. This is the most common complaint of a patient suffering from an osteoid osteoma. Swelling is the next most common symptom and is thought to be due to the increased vascular supply to the tumor from prostaglandin

release within the nidus. Other symptoms include bone deformity, muscle atrophy, and gait disturbances. If the tumor is located intra-articular or close to a joint, synovitis effusion, arthritic changes, and contractures may be present. When in the spine, they are a classic cause of painful scoliosis, concave on the side of the lesion. This typical presentation is seen in over 75% of cases.

“Plain x-ray radiograph may be normal or may show a solid periosteal reaction with cortical thickening. CT is excellent at characterizing the lesion and is the modality of choice. It typically shows a focally lucent nidus within the surrounding sclerotic-reactive bone. A central sclerotic dot may also be seen. Although MRI is sensitive, it is non-specific and is often unable to identify the nidus. The hyperemia and resultant bone marrow edema pattern may result in the scans being misinterpreted as representing aggressive pathology” [6,7]. “The signal intensity of the nidus is variable in all sequences, as is the degree of contrast enhancement. In patients without a history of lower limb overuse, the identification of the half-moon sign is highly specific and sensitive for the detection of femoral neck OO. In these cases, the detection of a half-moon sign on fluid-sensitive MRI sequences should prompt further CT examination to detect a nidus. In cases of overuse (e.g., marathon runners, armed forces members), the half-moon sign may indicate a stress reaction or fracture” [6,9].

The principal differential diagnoses of an OO include chondroblastoma, bone infarction, Brodie's abscess, stress fracture, chronic osteomyelitis, focal cortical bone abscess, sclerosing osteitis, and an early stage of Ewing sarcoma.

“The management of OO includes observation, symptom management with NSAIDs, Radiofrequency ablation, MWA, MR-guided high-frequency ultrasound, and intralesional resection” [2,4].

The role of the radiologist in the management of this pathology has now evolved significantly from the simple diagnosis of OO to its treatment. A radiologist with experience in interventional radiology, particularly bone biopsies, can carry out this type of procedure. Indeed, certain OO whose nature and size localization are difficult to treat require special considerations and good operator experience.

Minimally invasive techniques such as image-guided thermal ablation are now widely used in the treatment of tumors. MWA is one of the newer modalities of thermal ablation and has proven its safety and efficacy in the management of tumors amenable for ablation for primary

and metastatic diseases. The main goal of treatment is to relieve pain. More recently, microwave ablation has gained popularity.

MWA is a form of electrosurgery in which a high-frequency alternating current passes from the electrode tip into adjacent tissues and dissipates its energy as heat. A microwave generator forms an electrical current that passes from the generator through the electrode into the patient and returns to the generator through the electrode. The resistance of biological structures creates vibrational ions. This ionic agitation results in friction around the tip of the electrode due to a multitude of changes in the direction of its ions due to a ting current. The maximum size of the treated area should be calculated according to the following criteria: 1-The long axis of the treated area: twice the length of the heated tip of the needle. 2- Transverse diameter: two-thirds of the long axis. The method could be summarized as a six-step procedure:

1-Localization: Using a mark on the skin surface (**Figure 1A**), the coaxial needle, the anatomical point of entry can sometimes be opposite the lesions, making it possible to avoid noble structure, to avoid crossing a joint, and avoid creatin-destructive lesions along the path of the biopsy. 2- Drilling and milling: Depending on the needle used, a simple drilling movement can be applied to the needle and thus cross the bone cortex, making it possible to reach the lesion with any other movement than turning the needle on itself. 3- Biopsy: A biopsy is not always obligatory; it is always carried out to allow histological confirmation of the diagnosis of OO and to exclude another underlying pathology or a diagnostic error from the images. 4- Placement of the MTA needle: After the biopsy, the path to the center of the nidus is free of any obstacle and allows easy placement of the MT. 6- A CT scan makes it possible to verify the optimal position of the heated distal end of the needle in the center of the lesion, which must be treated(**Figure 1B, C**). 6- Connection and adjustment and finally thermo-ablation procedure.

Pain may be variable after a thermoablation procedure. So, the patients may experience pain disappearing within a few hours, while others may experience residual pain for one to two days after the procedure. However, this pain disappears quickly, and very rarely, any oral analgesia is necessary [1-3].

A clinical examination is carried out before reloading, and the patient can immediately (4 to 5 hours after the procedure) return to normal activities. The patient can return home the evening of the procedure or the following morning.

There are several identified complications, although they are rare. These include cellulitis, thrombophlebitis, nerve skin burns, and reflex sympathetic dystrophy. To reduce the risk of

neurovascular damage or damage to the skin, it is recommended that radiofrequency ablation be reserved for lesions greater than 1.5 cm from a neurovascular bundle and greater than 1.0 cm from the surface of the skin.

A clinical check-up is carried out on all patients every two weeks. If the pain persists and the histological diagnosis of OO is confirmed, a second procedure can be performed. The disappearance of pain is the first parameter used to define whether the treatment has been effective. Radiographically, sclerosis of the nidus is expected within two to twenty-seven hours following the procedure, although in one radiological third of cases, no changes appear [2].

Conclusion: Osteoid osteoma is a benign lesion that affects young patients and can cause significant pain and loss of complete function of the affected limb. Microwave thermoablation treatment under CT scan control has now proven its effectiveness and is accepted as a safe, minimally invasive, and economically favorable method in the treatment of osteoid osteomas.

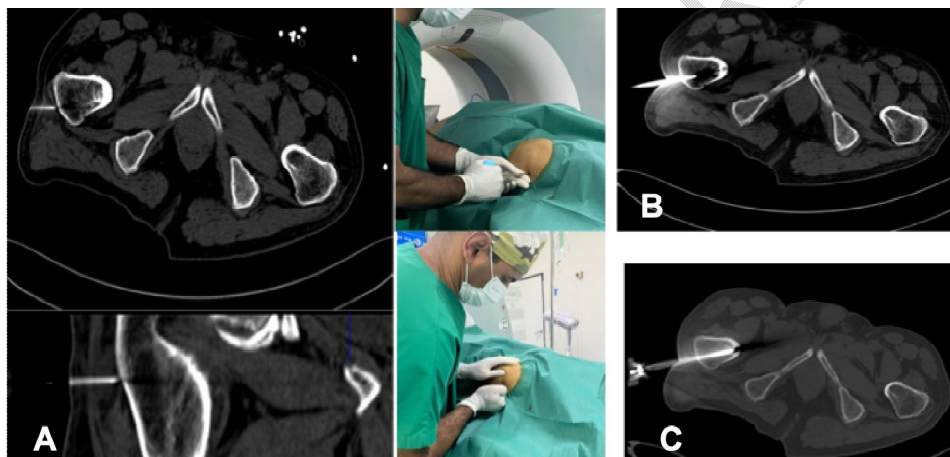


Figure 1: (A) Skin marking of the puncture zone. (B) Computed Tomography bone, on axial view showing needle progression of the guide needle toward the lesion with simple drilling maneuvers (B), penetration of sclerosis. (C) Insertion through the medullary pathway of the microwave thermoablation antenna and verification of the position. Computed Tomography-guided percutaneous microwave thermo-ablation of iliac bone osteoid osteoma in a 28-year-old man.

Ethical Approval:

As per international standards or university standards written ethical approval has been collected and preserved by the author(s).

Consent

As per international standards or university standards, patient(s) written consent has been collected and preserved by the author(s).

References:

- 1- Westlake B, Mazzi J, Tedesco N. Osteoid Osteoma Treatment with Microwave Ablation: A Report of Two Cases. *Medicina (Kaunas)*. 2021; 11;57(5):470.
- 2- T, Cingoz E, Kilickesmez O. Percutaneous CT-Guided Microwave Ablation for the Treatment of Osteoid Osteomas: A Single Center Experience. *AcadRadiol*. 2024;14: S1076-6332(24)00095-3.
- 3- Daher M, Roukoz S, Pearl A, Saleh K. Osteoid osteoma of the wrist: Recent advances. *Hand Surg Rehabil*. 2023;42(5):386-391.
- 4- Yildirim G, Karakas HM, Yilmaz B. Uncooled microwave ablation of osteoid osteoma: New approaches to an old problem. *North Clin Istanbul*. 2022 ; 27;9(5):524-529.
- 5- Le Corroller T, Vives T, Mattei JC, Pauly V, Guenoun D, Rochwerger A, Champsaur P. Osteoid Osteoma: Percutaneous CT-guided Cryoablation Is a Safe, Effective, and Durable Treatment Option in Adults. *Radiology*. 2022;302(2):392-399.
- 6- Tan JR, Yan YY, Sheikh A, Ouellette H, Mallinson P, Munk PL. Cementoplasty to cryoablation: review and current status. *BJR Open*. 2024; 29;6(1): tzae007.
- 7- Knežević I, Bojanić I. Comparison of arthroscopy versus percutaneous radiofrequency thermal ablation for the management of intra- and juxta-articular elbow osteoid osteoma: case series and a literature review. *BMC MusculoskeletDisord*. 2022; 25;23(1):287.
- 8- Gaillard F, Walizai T, Niknejad M, et al. Osteoid osteoma. *Radiopaedia.org* (Accessed on 14 Aug 2024) <https://doi.org/10.53347/rID-1802>.
- 9- Benyass, Y., Chafry, B., Koufagued, K. et al. Osteoid osteoma of the acetabular roof: a case report. *J Med Case Reports*. 2016; 10, 232.

10. Shinozaki T, Sato J, Watanabe H, Takagishi K, Aoki J, Koyama Y, Takahashi A. Osteoid osteoma treated with computed tomography—guided percutaneous radiofrequency ablation: a case series. *Journal of Orthopaedic Surgery*. 2005 Dec;13(3):317-22.

UNDER PEER REVIEW