

Angioleiomyoma of left proximal arm region- mimic as soft tissue sarcoma

ABSTRACT:

The angioleiomyomas are rare soft tissue tumors mainly arising from smooth muscle cell layer. These vascular origin tumors often present at extremities. The exact underlying cause is unknown for these tumors. Due to nonspecific presentations and inconclusive radiological findings, it is very difficult to diagnose preoperatively. The exact management line of these rare soft tissue tumors may be delayed or vary, due to misdiagnosis. To expand the awareness of the pathology of this condition, more publications are needed. We are presenting a rare case of angioleiomyoma of left arm mimicking as soft tissue tumor, which implements the list of differential diagnosis of peripheral extremity soft tissue tumors.

Keywords: leiomyoma, angioleiomyoma, musculoskeletal tumors, soft tissue tumors, Magnetic resonance imaging.

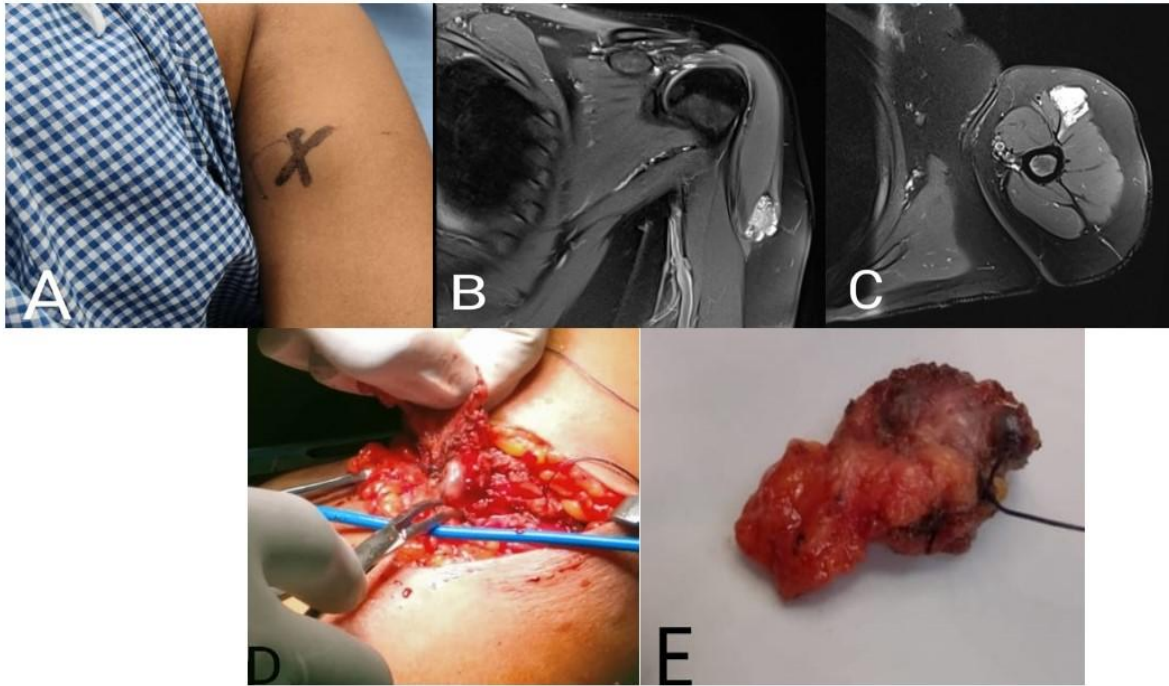
INTRODUCTION:

“Angioleiomyoma is benign soft tissue vascular tumor present at peripheral extremity”[1]. “It includes around up to 5% of all soft tissue tumors. These are well circumscribed tumors usually round or oval in shape, sometimes presenting as painless mass. They are slow-growing masses that can be asymptomatic but often present with pain, discomfort, nerve entrapment or causing patient concerns with footwear or cosmesis. These tumors mainly present in lower extremity, but very rare in upper limb”[4]. “Angioleiomyomas typically present as a firm, rounded mobile nodule arising from deep layers of dermis/subcutaneous tissues. On Ultrasound it appears as well circumscribed mass with homogenous echo texture and occasionally hypoechoic protuberances and on MRI (Magnetic resonance imaging), it shows signal intensity similar to muscle on T1 weight images and hyperintense on T2 weight image and with hypointense peripheral rim on T2 weighted images. According to World health organization(WHO), these tumors classified as perivascular tumors”[2]. On microscope these lesions will be having abundant amount of vessels surrounded by smooth muscle cells[3]. We are presenting one case of angioleiomyoma of upper limb(arm) mimicking as soft tissue sarcoma on preoperative diagnosis, turned out to be an angioleiomyoma, after excision.

CASE REPORT:

A 40-year-old female came to our hospital with complaining of swelling of the left upper arm. The swelling was insidious onset and gradually increased in size and now associated with slight pain. The swelling is causing some difficulty in activities since last 1 month. On bed side clinical examination, the swelling was approximately 4x2 cm in size, located on the antero-lateral side of upper arm. The swelling was firm to hard in consistency, partially mobile, well defined. After history and examination, patient underwent required blood and imaging studies. Routine blood investigations were normal. The patient was investigated with X-ray, ultrasound and MRI. The plain radiograph of the limb showed no bony involvement. Ultrasound (USG) of left arm swelling showed an hypoechoic lesion with vascular pattern. MRI (Magnetic resonance imaging) revealed an irregular, well circumscribed, hyperintense lesion (Proton Density sequence) involving the left deltoid muscle on its distal aspect, measuring 3.3x1.3x1.7cm. The lesion is noted within the superior aspect (subcutaneous plane) of deltoid muscle and shows contrast enhancement, mass showing similar intensity of deltoid muscle on T1 weighted image, which suggestive of soft tissue neoplasm. Preoperative FNAC (Fine needle aspiration cytology), showed blood mixed tissue with soft tissue tumor pattern. We have preferred guided FNAC in view of small size tumor, and in view of prominent vascularity in the mass.

With this preoperative pathological diagnosis, we have planned for surgical excision. Under regional anesthesia wide local excision with 2 cm margin was performed by an elliptical incision incorporating the biopsy site. Patient was discharged on post operative day-3 and followed up in the OPD. The post operative follow-up was uneventful. The post operative histopathological examination showed fibro-adipose and skeletal muscle tissue with a delineated benign tumor composed of thick walled blood vessels of variable size, with smooth muscle cells emanating from the wall of the blood vessels and blending with intervascular smooth muscle fibers. No signs of atypia were present. These histopathological aspects were suggestive of angioleiomyoma.



From right to left: (A) Per operative image showing lesion over left shoulder,(B) & (C) PDFS sequence of MRI of left shoulder showing contrast enhancement (D) & (E) Intra operative image of lesion and post excision of swelling from

Fig .1 pictures from pre operative to post operative from right to left with above mentioned titles

UNDER PEER

DISCUSSION:

Angioleiomyoma is one of the three different forms of leiomyomas, which is also known as vascular leiomyoma. The typical lesion is a small, slowly growing, firm, and mobile nodule. Pain has been known as the most striking clinical feature of angioleiomyoma reported in 58% of patients in the series by Hachisuga et al[5] and in 62% of patients from a study at the Mayo Clinic[6]. Most common presentation is lower extremity and middle age women.

The underlying causes are largely unknown but factors such as trauma, infection, hormones and arterio-venous malformations have been associated with this condition.

Sometimes these tumors present like soft tissue sarcoma of extremity and it is very difficult to differentiate preoperatively. As in our case, it presented over left arm, which is a rare anatomical localization site and pre-operative cyto-pathological examination revealed a blood mixed tissue.

“On histopathological examination these tumors appears like, well-circumscribed dermal nodule surrounded by a compressed connective tissue and separated from it by clefts. Various sized veins with muscular walls are present within the nodule, and smooth muscle bundles extend tangentially from the periphery of the vessels”[7].

“The differential diagnoses can include lipoma, fibroma, ganglions, schwannoma, cutaneous angiolipoma, glomus tumor”.[8].

“In a relatively large number of cases it present asymptomatic and pain is not always detectable, but if present, can be of varied character like pressure pain, sharpness or pinching type and is affected by temperature”[9].

Radiological investigations like ultrasound Doppler and MRI (magnetic resonance imaging) are useful in preoperative investigations[10]. In our index case ultrasound showed, irregular well defined ovoid hypoechoic lesion present between the intermuscular plane above the anterior fibers of lower part of deltoid muscle and MRI scan reported an irregular, well circumscribed, hyperintense lesion with contrast homogeneous enhancement with peripheral heterogeneity.

As we mentioned above, the imaging studies like USG(Ultrasound) and MRI scan findings can suggest a diagnosis of probable soft tissue tumor. The confirmed diagnosis will be established only after excision and histopathological examination. Usually angioleiomyomas have a peripheral low-intensity signal rim corresponding to a fibrous pseudo-capsule with adjacent vascular structures with hypo or isointense to muscle on T1 images and heterogeneous and hyperintense to muscle on T2 images[11], substantially different from what we saw in our case.

The best treatment for angioleiomyomas is simple in toto excision[12]. "Sometimes the decision may change according to the size of lesion and severity of symptoms. The complications as secondary calcification, myxoid degeneration, hyalinization and malignant transformation, were reported in some cases"[13]. In case of recurrence, it has been discussed that the new lesion must be removed and treated like other low-grade malignancies

In our case, we have done wide local excision of the lesion and closed the wound in layers. Patient was discharged on postoperative day-3 and followed up in the OPD(out patient department) basis.

CONCLUSION:

Angioleiomyoma is a relatively uncommon benign subcutaneous soft tissue tumor which most often occurs in the extremities but uncommon in upper limb proximity. Proper preoperative evaluation (clinical as well as radiological) and histopathological examination should be done in doubtful scenarios, before planning surgery to avoid recurrence. Sometimes, as in our case, angioleiomyoma can it can mimic a soft tissue tumor and should be considered in differential diagnoses. Post-operative histological examination represents the only method of definitive diagnosis.

Consent:

Written informed consent was obtained from the husband of the patient for publication of this case report and any accompanying images.

References:

1. Yoo HJ, Choi AJ, Chung JH, Oh JH, Lee GK, Choi JY, et al. Angioleiomyoma in soft tissue of extremities: MRI findings. *Am J Roentgenol* 2009;2009:W291-4.
2. Matsuyama A. *Lyon, IARC Press*. 2020. Angioleiomyoma. World Health Organization Classification of Tumours: Soft Tissue and Bone Tumours. p. pp. 186.
3. Matsuyama A, Hisaoka M, Hashimoto H. Angioleiomyoma: a clinicopathologic and immunohistochemical reappraisal with special reference to the correlation with myopericytoma. *Hum Pathol*. 2007;38(4):645-651. doi: 10.1016/j.humpath.2006.10.012.
4. Hanft JR, Carbonell JA, Hao DQ. Angioleiomyoma of the lower extremity. *JAPMA* 1997;87:388-91.
5. Hachisuga T, Hashimoto H, Enjoji M. Angioleiomyoma. A clinicopathologic reappraisal of 562 cases. *Cancer*. 1984 Jul 1;54(1):126-30. doi: 10.1002/1097-0142(19840701)54:1.

6. Freedman AM, Meland NB. Angioleiomyomas of the extremities: report of a case and review of the Mayo Clinic experience. *Plast Reconstr Surg* 1989; 83:328 -331
7. Edo H, Matsunaga A, Matsukuma S, Mikoshi A, Susa M, Horiuchi K, Shinmoto H. Angioleiomyoma of the extremities: correlation of magnetic resonance imaging with histopathological findings in 25 cases. *Skeletal Radiol*. 2022;51(4):837-848. doi: 10.1007/s00256-021-03888-4.
8. Dominguez-Cherit J, Brandariz A. Distal digital angioleiomyoma: a case report and review of the literature. *Int Soc Dermatology* 2003;42:141-3.
9. Hasegawa T, Seiki K, Yang P, Hirose T, Hizawa K. Mechanism of pain and cytoskeletal properties in angioleiomyomas: an immunohistochemical study. *Pathol Int* 1994; 44:66-72
10. FKang BS, Shim HS, Kim JH, Kim YM, Bang M, Lim S, Park GM, Lee TY, Ha ND, Kwon WJ. Angioleiomyoma of the extremities: Findings on ultrasonography and magnetic resonance imaging. *J Ultrasound Med*. 2019;38(5):1201-1208. doi: 10.1002/jum.14798
11. Kinoshita T, Ishii K, Abe Y, Naganuma H. Angiomyoma of the lower extremity: MR findings. *Skeletal Radiol* 1997; 26:443 -445.
12. Woo KS, Kim SH, Kim HS, Cho PD. Clinical experience with treatment of angioleiomyoma. *Arch Plast Surg* 2014;41:374-8.
13. Gajanthodi S, Rai R, Chaudhry RK. Vascular leiomyoma of foot. *J Clin Diagn Res* 2013;7:571-2.