

## Case report

### **Angioleiomyoma of left proximal arm region- mimic as soft tissue sarcoma.**

#### **ABSTRACT:**

The angioleiomyomas are rare soft tissue tumors mainly arising from smooth muscle cell layer. These vascular origin tumors often present at extremities. The exact underlying cause is unknown for these tumors. Due to nonspecific presentations and inconclusive radiological findings, it is very difficult to diagnose preoperatively. The exact management line of these rare soft tissue tumors may be delayed or vary due to misdiagnosis. To expand the awareness of the pathology of this condition, differential diagnosis of peripheral extremity soft tissue tumors, more publications are needed. We are presenting such a rare case of angioleiomyoma of left arm mimicking as soft tissue tumor.

**Keywords:** leiomyoma, angioleiomyoma, musculoskeletal tumors, soft tissue tumors, Magnetic resonance, imaging.

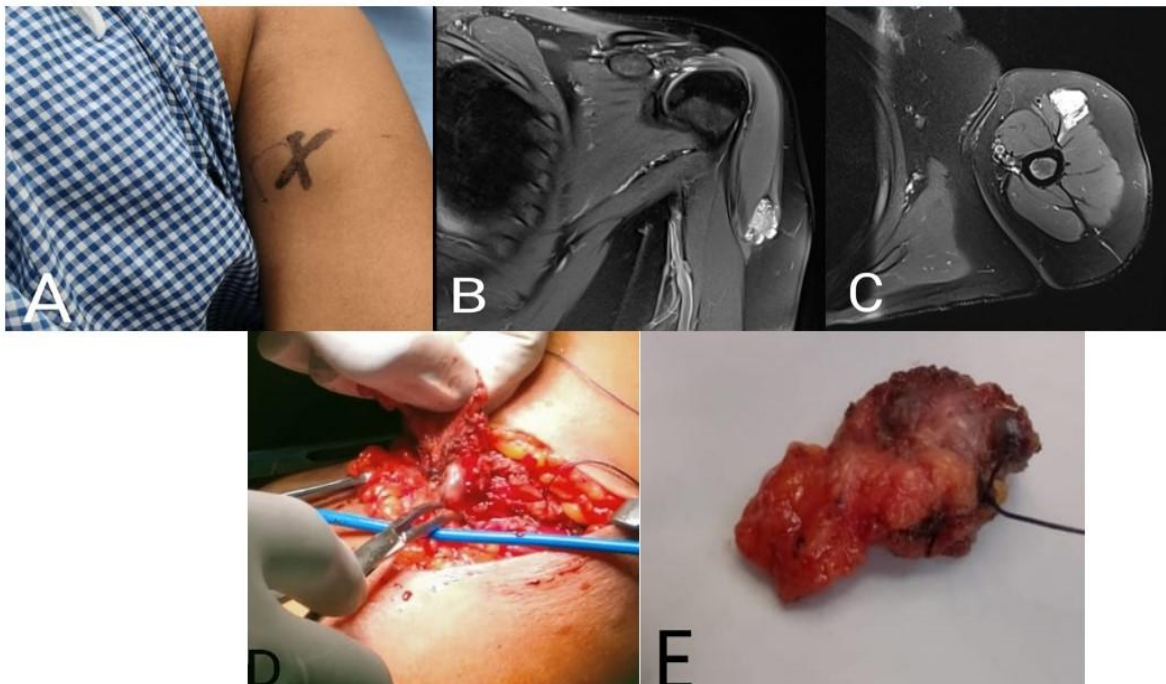
#### **INTRODUCTION:**

Angioleiomyoma is benign soft tissue vascular tumor present at peripheral extremity[1]. It includes around up to 5% of all soft tissue tumors. These are well circumscribed tumors usually round or oval in shape commonly presenting as painless mass. According to World Health Organization (WHO), these tumors are classified as perivascular tumors[2]. On microscope these lesions will be having abundant amount of vessels surrounded by smooth muscle cells[3]. Angioleiomyomas typically present as a firm, rounded mobile nodule arising from deep layers of dermis/subcutaneous tissues. They are slow-growing masses that can be asymptomatic but often present with pain, discomfort, nerve entrapment or causing patient concerns with footwear or cosmesis. These tumors mainly present in lower extremity, but very rare in upper limb[4]. We are presenting one case of angioleiomyoma of upper limb (arm) mimicking as soft tissue sarcoma on preoperative diagnosis and later it turned out to be angioleiomyoma after excision.

#### **CASE REPORT:**

A 40-year-old female came to our hospital with complaining of swelling of the left upper arm. The swelling was insidious onset and gradually increased in size and now associated with slight pain. The swelling is causing some difficulty in activities since last 1 month. On bedside clinical examination, the swelling was approximately 4x2 cm in size, located antero-lateral side of upper arm. The swelling was firm to hard in consistency partially mobile well defined. After history and examination, patient underwent required blood and imaging studies. Routine blood investigations were normal. The patient was investigated with X-ray, ultrasound and MRI. The plain radiograph of the limb showed no bony involvement. Ultrasound (USG) of left arm swelling showed hypoechoic lesion with vascularity in within it. MRI (Magnetic resonance imaging) revealed an irregular a well circumscribed hyperintense lesion is noted involving the left deltoid muscle in its distal aspect measuring 3.3x1.3x1.7 cm. the lesion is noted within the superior aspect (subcutaneous plane) with of deltoid muscle and shows diffusion restriction suggestive of soft tissue neoplasm. Preoperative FNAC (Fine needle aspiration cytology) showed 1. blood mixed tissue 2. soft tissue tumor.

With this preoperative pathological diagnosis, we have planned for surgical excision. Under regional anesthesia wide local excision with 2 cm margin was performed with by an elliptical incision incorporating the biopsy site into it. The Post operative course of the patient was uneventful. On post operative histopathological examination, it showed fibro adipose and skeletal muscle tissue with a delineated benign tumor composed of thick walled blood vessels of variable size with smooth muscle cells emanating from the wall of these blood vessels and blending with intervascular smooth muscle fibers. Atypia is absent. Finally it was suggestive of angeliomyoma. Patient was discharged on post operative day-3 and followed up in the OPD



From right to left: (A) Per operative image showing lesion over left shoulder, (B) & (C) PDFS sequence of MRI of left shoulder showing contrast enhancement (D) & (E) Intra operative image of lesion and post excision of swelling from

Fig .1 showing pictures from pre operative to post operative from right to left with above mentioned titles

#### **DISCUSSION:**

Angioleiomyoma is one of the three different forms of leiomyomas, which is also known as vascular leiomyoma. The typical lesion is a small, slowly growing, firm, and mobile nodule. Pain has been known as the most striking clinical feature of angioleiomyoma reported in 58% of patients in the series by Hachisuga et al[5] and in 62% of patients from a study at the Mayo Clinic[6]. Most common presentation is lower extremity and middle age women.

The underlying causes are largely unknown but factors such as trauma, infection, hormones and arterio venous malformations have been associated with this condition.

Some times these tumors present like soft tissue sarcoma of extremity and it is very difficult to differentiate pre operatively. As in our case, it presented over left arm, which is again rare site to present and pre-operative histopathological examination revealed it blood mixture.

On histopathological examination these tumors appears like, well-circumscribed dermal nodule surrounded by a compressed connective tissue and separated from it by clefts. Various sized

veins with muscular walls are present within the nodule, and smooth muscle bundles extend tangentially from the periphery of the vessels[7].

The differential diagnoses can include lipoma, fibroma, ganglions, schwannoma, cutaneous angiolipoma, glomus tumor, etc[8].

Many of time, It present asymptomatic and Pain is not always present, but if present, can be of varied character like pressure pain, sharpness or pinching type and is affected by temperature[9].

Radiological investigations like ultrasound Doppler and MRI (magnetic resonance imaging) are useful in preoperative investigations[10]. In our index case ultrasound showed, irregular well defined ovoid hypoechoic lesion present between the intermuscular plane above the anterior fibers of lower part of deltoid muscle and MRI scan which reported an indeterminate swelling suggestive of a possible soft tissue neoplasm.

As we mentioned above, the imaging studies like USG(Ultrasound) and MRI scan findings can suggest a different diagnosis of soft tissue tumor only. The confirmed diagnosis will be established after excision and histopathological examination only. Usually, angioleiomyomas have a peripheral low-intensity signal rim corresponding to a fibrous pseudo capsule with adjacent vascular structures with hypointense to muscle on T1 images and heterogeneous and hyperintense to muscle on T2 images[11].

The best treatment for angioleiomyomas is simple in toto excision[12]. But some time, the decision may change according to the size of lesion and severity of symptoms. The complications like, secondary calcification, myxoid degeneration, hyalinization and malignant transformation, were reported in some cases[13]. In case of recurrence, it has been discussed that the new lesion must be removed and treated like other low-grade malignancies

In our case,we have done wide local excision of the lesion and closed the wound in layers. So, angioleiomyoma can present over upper extremity and mimics as soft tissue sarcoma.

## **CONCLUSION:**

Angioleiomyoma is a relatively uncommon benign subcutaneous soft tissue mass which most often occurs in the extremities but uncommon in upper limb proximity. Proper preoperative evaluation (clinical as well as radiological) and histopathological examination should be done in doubtful scenarios, before planning surgery to avoid recurrence.

## **References:**

1. Yoo HJ, Choi AJ, Chung JH, Oh JH, Lee GK, Choi JY, et al. Angioleiomyoma in soft tissue of extremities: MRI findings. *Am J Roentgenol* 2009;2009:W291-4.
2. Matsuyama A. *Lyon, IARC Press*. 2020. Angioleiomyoma. World Health Organization Classification of Tumours: Soft Tissue and Bone Tumours. p. pp. 186.
3. Matsuyama A, Hisaoka M, Hashimoto H. Angioleiomyoma: a clinicopathologic and immunohistochemical reappraisal with special reference to the correlation with myopericytoma. *Hum Pathos*. 2007;38(4):645-651. doi: 10.1016/j.humpath.2006.10.012.
4. Hanft JR, Carbonell JA, Hao DQ. Angioleiomyoma of the lower extremity. *JAPMA* 1997;87:388-91.
5. Hachisuga T, Hashimoto H, Enjoji M. Angioleiomyoma. A clinicopathologic reappraisal of 562 cases. *Cancer*. 1984 Jul 1;54(1):126-30. doi: 10.1002/1097-0142(19840701)54:1.
6. Freedman AM, Meland NB. Angioleiomyomas of the extremities: report of a case and review of the Mayo Clinic experience. *Plast Reconstr Surg* 1989; 83:328 -331
7. Edo H, Matsunaga A, Matsukuma S, Mikoshi A, Susa M, Horiuchi K, Shinmoto H. Angioleiomyoma of the extremities: correlation of magnetic resonance imaging with histopathological findings in 25 cases. *Skeletal Radiol*. 2022;51(4):837-848. doi: 10.1007/s00256-021-03888-4.
8. Dominguez-Cherit J, Brandariz A. Distal digital angioleiomyoma: a case report and review of the literature. *Int Soc Dermatology* 2003;42:141-3.
9. Hasegawa T, Seiki K, Yang P, Hirose T, Hizawa K. Mechanism of pain and cytoskeletal properties in angioleiomyomas: an immunohistochemical study. *Pathol Int* 1994; 44:66-72
10. FKang BS, Shim HS, Kim JH, Kim YM, Bang M, Lim S, Park GM, Lee TY, Ha ND, Kwon WJ. Angioleiomyoma of the extremities: Findings on ultrasonography and magnetic resonance imaging. *J Ultrasound Med*. 2019;38(5):1201-1208. doi: 10.1002/jum.14798
11. Kinoshita T, Ishii K, Abe Y, Naganuma H. Angiomyoma of the lower extremity: MR findings. *Skeletal Radiol* 1997; 26:443 -445.
12. Woo KS, Kim SH, Kim HS, Cho PD. Clinical experience with treatment of angioleiomyoma. *Arch Plast Surg* 2014;41:374-8.
13. Gajanthodi S, Rai R, Chaudhry RK. Vascular leiomyoma of foot. *J Clin Diagn Res* 2013;7:571-2.

Ethics approval and consent to participate:

Not applicable.

Consent for publication:

Written informed consent was obtained from the husband of the patient for publication of this case report and any accompanying images.

UNDER PEER REVIEW