

Original Research Article

GROSS ANATOMICAL STUDIES ON FACIAL BONES OF THE SKULL OF INDIAN MONGOOSE (*Herpestes javanicus*)

ABSTRACT: The maxillae were the principal bones of the upper jaw and carry the upper cheek teeth. The lateral surface of the body just above the upper 3rd or 4th cheek tooth infra orbital foramen is present; the alveolar socket for the canine tooth is located at the junction of the alveolar border of the maxilla and premaxilla. The palatine surface bears an anterior palatine foramen. The alveolar sockets for the last molar tooth were opened into the temporal fossa. Incisive bones showed three alveolar sockets for the upper incisors. The Palatine process was a thin plate that forms the rostral part of the hard palate. Nasal bones do not make any articulation with the maxilla bone. The frontal extremities of the nasal bones are blunt, and two bones together fit into the groove formed by the two frontal bones. The rostral extremities of two bones were free for muscular attachment. Lacrimal bones were articulated dorsally with the orbital plate of the frontal bones, ventrally with the palatine process of the maxilla, rostrally with the caudal border of the maxilla, and caudally with the perpendicular part of the palatine bones. The facial surface extends very little, or not at all, beyond the orbital margin. The orbital surface was small and quadrilateral in outline. Lacrimal Bulla was absent. Zygomatic bones were placed between the lacrimal and maxilla rostrally. The temporal process was long, strongly curved, and forms the bulk of the bone. Between the horizontal and vertical parts of the palatine bones forms the posterior 3/4th of the nasal cavity. The rostral extremity of the pterygoid bones were articulated with the palatine bones, and the posterior extremities were free and carried by the by the hamulus. The rostral extremity of the vomer bone has almost reached the body of the incisive bone. The ventral turbinate is larger than the dorsal one. Two halves of the mandibles were not fused completely. The body presents three alveoli for the lower incisors and one alveolus for the canine tooth. It has six alveoli for the lower cheek teeth. The 5th alveolus was larger than the remaining ones and carries a carnassial tooth.

Keywords: Facial bones of the skull, gross anatomy, Indian mongoose (*Herpestes javanicus*)

INTRODUCTION

The genus *Herpestes* contains 10 species (Nowak, 1999) and is considered the oldest genus within the order Carnivora, dating back approximately 30 million years (Hinton & Dunn, 1967). The native distribution of the small Indian mongoose [*Herpestes auropunctatus* (Hodgson 1836)] stretches from Iraq in the west to Myanmar in the east, and from northern Pakistan southwards throughout the Indian subcontinent (Ahmad and Omar, 2023). It is a small predatory mammal capable of surviving in a variety of habitats, including deserts, forests, agricultural areas, and urban areas. The small Indian mongoose is listed under CITES Appendix III in India (as *Herpestes javanicus auropunctatus*) (Wozencraft, 2005). Mongoose are poached in India for their hairs, which are used for making paint and shaving brushes. Due to poaching,

mongooses have been reclassified from Schedule IV to Schedule II of the Wildlife Protection Act in India (Sahajpal *et al.* 2009). So, there is no information available on the anatomical features of the skeletal system of the Indian mongoose. Hence, the present study was undertaken to elucidate the anatomical features of the facial bones of the skull of the Indian mongoose.

MATERIALS AND METHODS

The present study was conducted on four Indian mongoose skulls. The six dead mongooses were collected and macerated in fresh water at the College of Veterinary Science, Proddatur, Andhra Pradesh. After maceration, the skulls were cleaned, and the gross anatomical features of the facial bones were recorded.

RESULTS AND DISCUSSION

Maxilla: Maxillae were the principal bones of the upper jaw and carry the upper cheek teeth. The body was very wide and made up of two tables. The facial surface of the body is concave. The lateral surface of the body just above the upper 3rd or 4th cheek tooth infra orbital foramen is present; this was the external opening of the infra orbital canal (Fig.1), which was similar to the findings of Monfared (2013) and Getty (2012) in dogs. The infraorbital foramen is wide, as reported by Yilmaz *et al.* (2000) in Otter. The medial surface of the body forms the lateral boundary of the nasal cavity. This surface also gives attachment to the ventral turbinate crest. The maxillary sinus was situated between the external and internal tables of bone. The dorsal border of the body is serrated and attached to the rostral border of the frontal bone. The rostral border was irregular and attached to the caudal border of the nasal process of the incisive bone. Caudal border attached to the lacrimal bone and continued on the dorsal border of the zygomatic process. The ventral/alveolar border consisted of an alveolar socket for the first three upper cheek teeth. The alveolar socket for the canine tooth was located at the junction of the alveolar border of the maxilla and premaxilla (Fig.1), which was similar to the findings of Getty (2012) in dogs and Joshi *et al.* (2005) in tigers.

The Palatine process was wide comparatively and forms the hard palate. It was wide anteriorly and has narrowed towards the caudal. The palatine surface bears the anterior palatine foramen. The zygomatic process was very wide. It was attached medially to the palatine and lacrimal bones. The alveolar sockets for the last molar tooth are opened into the temporal fossa. Internal openings of the infraorbital canal are located at the root of the zygomatic process of the maxilla (Fig.2). However, Joshi *et al.* (2005) stated that the zygomatic process was short and thick in tigers and carries alveolar sockets for molars.

Incisive bones (Premaxilla): This is a paired bone that forms the rostral part of the upper jaw and carries the upper incisors. It also articulates with the maxilla, frontal, and nasal bones. The body was thick and carries three alveolar sockets for the upper incisors (Fig.1). These findings were in accordance with Konig and Liebich (2009) in dogs, Yilmaz (2000) in otters, and Getty (2012) in dogs and pigs. However, Farag *et al.* (2012) and Salih (2013) mentioned that two alveolar sockets are present in the upper jaw of rabbits. The lingual surface was convex, attached to the upper lip, and the palatine surface was concave. The nasal process projects caudo dorsally from the body, as observed by Farag *et al.* (2012) in rabbits and Konig and Liebich (2009) in dogs. The lateral surface was smooth, and the internal surface formed the anterolateral

wall of the nasal cavity. The medial border articulates with the lateral border of the nasal bones, and the lateral border articulates with the dorsal border of the maxilla. The upper parts of the nasal process are pointed and fixed between the junction of the maxilla, frontal, and nasal bones. The palatine process was a thin plate that formed the rostral part of the hard palate (Fig.2). The nasal surface of two adjacent processes forms a groove for the dorsal border of the septal cartilage. The lateral border was separated from the nasal process by the palatine fissure. The caudal extremity fits in between the palatine processes of the maxilla. Similar results were encountered in dogs by Getty (2012).

Palatine bones: It was a very long and narrow bone and forms the caudal half of the hard palate (Fig.2), which was similar to the findings of Farag *et al.* (2012) in rabbits and Getty (2012) in pigs. Each articulates with the bone on the opposite side; the palatine process of the maxilla ventro laterally. Posteriorly, articulates with the lateral surface of the pterygoid bone, body, and subsphenoidal process of the presphenoid bone. Dorsally, it articulates with the orbital plate of the frontal and vomer bones and anteriorly with the lacrimal bone. The caudal half of the horizontal part was very large and formed the hard palate. Numerous minute foramina were present on this plate (Fig.2). Farag *et al.* (2012) stated that each horizontal palatine presents the rostral palatine foramen on the level of the 3rd premolar teeth, the rostral orifice of the palatine canal in rabbits. Ozkan (2007) stated that the foramen palatinum majus and foramina palatine minora were absent on the lamina horizontalis of the os palatinum, and a significant crest lying sagittally and two longitudinal grooves on the ventral face of the os palatinum were present in the mole rat. Getty (2012) mentioned that the minor palatine foramen and major palatine foramen were present in pigs. The vertical part was smaller than the horizontal part, which was similar to the report of Yilmaz *et al.* (2000) in otter. Anteriorly, it was pierced by posterior palatine foramens. Between the horizontal and vertical parts, the posterior 3/4th of the nasal cavity is present, which was also connected to the maxillary sinus.

Nasal Bones: Paired nasal bones were located rostral to the frontal bones. Two nasal bones articulated with each other at their medial borders, the frontal and incisive bones laterally. The external surface was smooth and flat (Fig.1), as observed by Getty (2012) in pigs. However, Yilmaz *et al.* (2000) in otter, Ozkan (2007) in mole rat, and Farag *et al.* (2012) in rabbit stated that the external surface is slightly convex from side to side, whereas in dogs it was variably concave (Getty, 2012; Konig and Liebich, 2009). The lateral lip of the internal surface, along with the medial border of the maxilla, gives attachment to the dorsal nasal turbinate. The internal lips of two bones together form a crest, which gives attachment to the dorsal border of the perpendicular plate of the ethmoid bone. The frontal extremity of each bone was blunt, and two bones together fit into the groove formed by the two frontal bones. The rostral extremities of two bones were free for muscular attachment (Fig.1). Similar findings were observed by Farag *et al.* (2012) in rabbits. Whereas Getty (2012) observed that the caudal extremity fit into a notch formed by the frontal bones in dogs.

Lacrimal bones: Lacrimal bones were very small and situated rostral to the orbit. They articulated dorsally with the orbital plate of the frontal bones, ventrally with the palatine process of the maxilla, rostrally with the caudal border of the maxilla, and caudally with the perpendicular part of the palatine bones. The facial

surface extends very little or does not cross beyond the orbital margin. The orbital surface was small and quadrilateral in outline (Fig.1). Similar results were also observed by Getty (2012) in dogs. The orbital part forms the medial and rostral walls of the orbit. Near the orbital margin, it presents a fossa, which was the entrance of the lacrimal canal. This was similar to the reports of Farag *et al.* (2012) in rabbits and Getty (2012) in dogs. The nasal surface faces the frontal and maxillary sinuses. Lacrimal Bulla was absent.

Zygomatic bones: These bones were located between the lacrimal and maxilla rostrally, the palatine process of the maxilla ventrally, and the zygomatic process of the temporal bone caudally. The temporal process was long, strongly curved, and formed the bulk of the bone. The lateral surface was smooth and convex, and the and the medial surface was smooth and concave. The dorsal border was concave and free rostrally, where it forms the ventral margin of the orbit. At the middle frontal process is present, it gives attachment to the orbital ligament. The posterior half of the temporal process articulates with the zygomatic process of the temporal bone and completes the zygomatic arch (Fig.1). However, Joshi *et al.* (2005) stated that the frontal process was short and blunt and did not articulate with the zygomatic process of the frontal bone, hence the caudal boundary of the orbit was free in tigers. Rostral half of the ventral border articulates with the zygomatic process of the maxilla is similar to the finding of Farag *et al.* (2012) in rabbits, whereas the caudal part was free. However, Ozka (2007) mentioned that the zygomatic arch was formed by three bones, namely the temporal process of the zygomatic bone, the zygomatic process of the temporal bone, and the third bone (jugal), which was not fused with the other two processes in the mole rat. Yilmaz (2000) stated that the zygomatic bone was narrow and the zygomatic arch was well developed in the otter. The anterior extremity was considered to be the body. The lacrimal process fitted in between the lacrimal bone and maxilla is similar to the finding of Joshi *et al.* (2005) in tigers.

Pterygoid bones: These were wide and short. They form the lateral boundaries of the caudal nares (Fig.2). Dorsally they articulated with the body of the post sphenoid was similar to the finding of Farag *et al.* (2012) in rabbits. Ventral borders were free and faced towards the caudal nares and lateral surface of the palatine bone. The rostral extremity articulated with the palatine bones and posterior extremities were free and carried hamulus, which was similar to the results of Getty (2012) in dogs and Joshi *et al.*, (2005) in tigers.

Vomer: The vomer was a median bone located in the floor of the nasal cavity, which assists in the formation of the ventral part of the nasal septum (Fig.2). It is grooved dorsally and lodges the ventral border of the nasal septum. Its rostral extremity has almost reached the body of the incisive bone, and its caudal extremity is pointed and concealed by the wings of the pre sphenoid bone. The caudal 3/4th was free of articulation with the floor of the nasal cavity and does not divide the posterior nares into two complete halves. The middle 1/3 was wide, and the ventro laterally met the perpendicular plates of the palatine bones. Throughout its length, it is distinctly grooved on its dorsal surface to receive the cartilage of the nasal septum rostrally and the osseous perpendicular lamina of the ethmoid bone caudally. Similar characters were also observed in the skulls of pigs and dogs by Getty (2012). Whereas in rabbit skulls, the caudal 1/3 of the vomer bone is narrow, and the rostral 1/3 has two laterally projected wings fused with the basal

lamina of the ethmoid bone. It results in the elongated nasopharyngeal meatus remaining between the ethmoid bone and horizontal parts of the palatine bone (Farag *et al.*, 2012).

Turbinates: Each half of the nasal cavity was comprised of dorsal and ventral turbinate bones. The ventral turbinate was larger and more extensive than the dorsal one. Dorsal turbinate was attached to the turbinate crest on the internal surface of the nasal bone. It is pointed rostrally, widens caudally, and extends in between the ethmoturbinates. The basal lamina of ventral turbinates was attached to the nasal surface of the body of the maxilla bone. This lamina was divided into three secondary laminae, viz., dorsal, middle, and ventral, which were scrolled ventrally. Among the three laminae, the middle one was the largest, and the remaining two were of equal size. The ventral nasal meatus was wide and continued into the nasal cavity proper. Farag *et al.* (2012) in rabbits mentioned that the dorsal turbinate was smaller than the ventral one. Similar findings were also reported by Getty (2012) in dogs.

Mandible: The mandible, or lower jaw bone, was the largest bone in the face. Two halves of the mandible were not fused completely, so there was no permanent symphysis (Fig.3). Similar findings were reported by Ozkan (2007) in mole rats and Getty (2012) in dogs. The body presents three alveoli for the lower incisors and one alveolus for the canine tooth. The alveolus for the canine tooth was large and deep. The horizontal ramus extends caudally from the body and diverges to enclose the mandibular space. It has six alveoli for the lower cheek teeth. The 5th alveolus was larger than the remaining ones and carried a carnassial tooth. The lateral surface was smooth and convex. Two mental foramens were present: the anterior one was smaller and located at the junction of the body, and the caudal one was larger and located behind the anterior one on the lateral surface of the ramus. However, Yilmaz *et al.* (2000) observed 5 mental foramina in the mandible of an otter, Ozkan (2007) in mole rats reported only one small mental foramina, and Getty (2012) reported 2-3 mental foramens in dogs. The medial surface was convex and presented a shallow groove.

The vertical ramus was wide and short. Its lateral surface presents a deep masseteric fossa, which encroaches the coronoid process as well. Similar findings were reported by Yilmaz *et al.* (2000) in otter and Getty (2012) in dogs and pigs, whereas Ozkan (2007) in mole rats observed a shallow masseteric fossa, and Jurgelėnas *et al.* (2007) reported that the masseteric fossa in red fox occupies nearly the entire surface of the ramus. The medial surface presents the mandibular foramen (Fig.3). Farag *et al.* (2012) observed mandibular foramen on the medial surface caudoventral to the last molar tooth in rabbits. Behind the foramen, near the junction of vertical and horizontal rami, an angular process was present (Fig.3). Farag *et al.* (2012) reported similar findings in rabbits; however, Jurgelėnas *et al.* (2007) reported that the end of the angular process in raccoon dogs is blunt and in red foxes is pointed; and Hidaka *et al.* (1997) observed that the angular process was curved in raccoon dogs and linear in badgers. The condyloid process was transversely elongated. Similar findings were reported by Getty (2012) in dogs. However, Yilmaz *et al.* (2000) reported that the condyloid process was convex in the mandible of the otter, and Hidaka *et al.*, (1997) reported that the condyloid process was wide in badgers. The condyloid process is separated from the coronoid process by a shallow mandibular notch. The coronoid process was blunt and wide; it was

placed in the temporal fossa. Similar findings were reported by Yilmaz *et al.* (2000) in otter. However, Olude and Olopade (2010) reported a thin coronoid process that was curved caudally in the African giant rat, and Getty (2012) in dogs reported that the coronoid process was very extensive and bent slightly lateral and caudal, and in pigs the coronoid process was small and thin-edged.

CONCLUSION

The maxillae were the principal bones of the upper jaw and carried the upper cheek teeth. It presents an infraorbital foramen above the level of the upper 3rd or 4th cheek tooth. Incisive bones showed three alveolar sockets for the upper incisors, and the palatine process forms the rostral part of the hard palate. Nasal bones do not make any articulation with the maxilla bone. The frontal extremities of the nasal bones together fit into the groove formed by the two frontal bones, and the rostral extremities give muscular attachment. Lacrimal bones were articulated with the frontal, maxilla, palatine bones. The temporal processes of zygomatic bones were long, strongly curved, and formed the bulk of the bone. Between the horizontal and vertical parts of the palatine bones, posterior 3/4th of the nasal cavity was present. The pterygoid bones were articulated with the palatine bones rostrally, and the posterior extremities carried the hamulus. The rostral extremity of the vomer bone has almost reached the body of the incisive bone. The ventral turbinate is larger than the dorsal one. Two halves of the mandibles were not fused completely. It has six alveoli for the lower cheek teeth. The 5th alveolus is larger than the remaining ones and carries a carnassial tooth.

REFERENCES

1. Ahmad E, Aidek, Omar F. Al-Sheikhly. First record of the Small Indian Mongoose *Urva auropunctatus* (Hodgson 1836) from Syria. *Mammalia*. 2023; 87(5). <https://doi.org/10.1515/mammalia-2022-0117>.
2. Farag FM, Daghash SM, Mohamed EF, Hussein MM, Hagrass SMJ. Anatomical Studies on the Skull of the Domestic Rabbit (*Oryctolagus cuniculus*) With Special Reference to the Hyoid Apparatus. *Vet. Anat*. 2012; 5(2): 49 – 70
3. Getty R. *Sisson and Grossman's the Anatomy of the Domestic Animals*. Vol.2. W.B. Saunders Comp. Philadelphia. 2012; 1427-1482.
4. Hidaka S, Matsumoto M, Hiji H, Ohsako S, Nishinakagawa H. Morphology and Morphometry of Skulls of Raccoon Dogs, *Nyctereutes procyonoides* and Badgers, *Meles meles*. *J. Vet. Med. Sci*. 1998; 60(2): 161–167.
5. Hinton HE, Dunn AMS. *Mongoose Their Natural History and Behavior*. Published by University of California Press, Berkeley CA, 1967.
6. Joshi H, Deora KS, Thanvi P, Menaka R. Radiographic anatomy of skull of tiger (*Panthera tigris*). *Indian J. vet. Anat*. 2005;17 (1): 68-70.
7. Jurgelėnas E, Linas Daugnora, Monastyreckienė E, Linas Balciauskas. On the skull morphology of raccoon dog (*Nyctereutes procyonoides*) and red fox (*Vulpes vulpes*). *Acta Zoologica Lituanica*. 2007; 17(1):41-46.

8. König HE, Liebich HG. Text book and color Atlas of Veterinary Anatomy of Domestic Mammals. Schattauer Publisher, Stuttgart, Newyork. 2009; 129-217.
9. Monfared AL. Anatomical study of the skull of the adult dogs and its clinical value during regional anesthesia. Glob. Veterinaria. 2013; 10(4):459-463. DOI: 10.5829/idosi.gv.2013.10.4.7295
10. Nowak RM. Walker's Mammals of the World (Volume 1). 6th Edition, Johns Hopkins University Press, Baltimore, 1999; 1166-1170.
11. Özkan ZE. Macro-anatomical investigations on the skeletons of mole-rat (*Spalax leucodon* Nordmann) III. Skeleton axiale, Veterinarskii arhiv. 2007;77 (3): 281-289.
12. Salih KM. Gross anatomical and morphometrical studies to the skull bones of the local rabbit (*Oryctohguscuniculus*), Bas. J. Vet. Res. 2013; 12 (2) : 267-277.
13. Vivek Sahajpal, Goyal SP, Raza R, Jayapal R. Identification of Mongoose (Genus: *Herpestes*) species from hair through band pattern studies using Discriminate Functional Analysis (DFA) and microscopic examination. Sci. Justice.2009; 49(3):205-9. DOI: 10.1016/j.scijus.2008.09.002
14. Wozencraft WC. Order carnivora. In Wison, D.E. & Reeder. D.M (eds). Mammal Species of the World, 3rd edition. The John Hopkins University Press, Baltimore. 2005; 532-628.
15. Yilmaz S, Gürsel Dinç, Toprak B. Macro-anatomical investigations on skeletons of otter (*Lutra lutra*). III. Skeleton axiale. Veterinarski Arhiv. 2000; 70 (4):191-198.

FIGURES

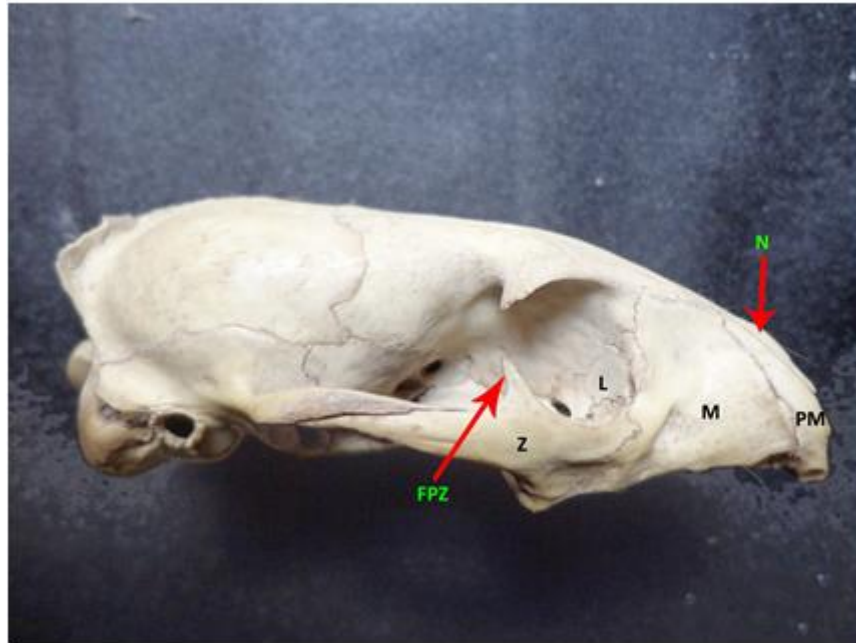


Fig. 1. The Photograph of skull of Indian mongoose showing Nasal (N), Pre maxilla (PM), Maxilla (M), Lacrimal (L) Zygomatic (Z) bones and Frontal process of zygomatic bone (Z).

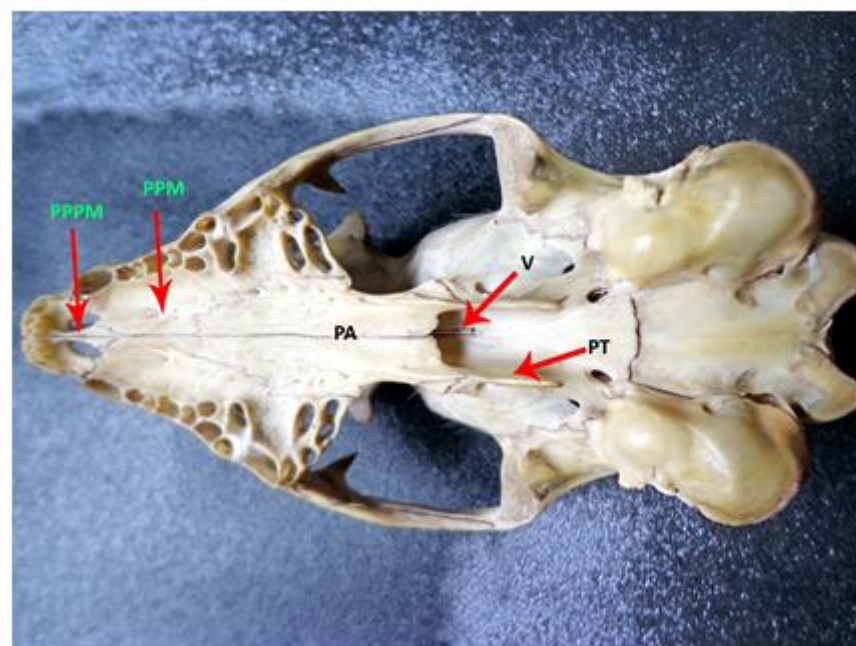


Fig. 2. The Photograph of skull of Indian mongoose showing Pterygoid (PT), Palatine (PA), Vomer (V) bones, Palatine process of Maxilla (PPM) and Palatine process of pre maxilla (PPPM).

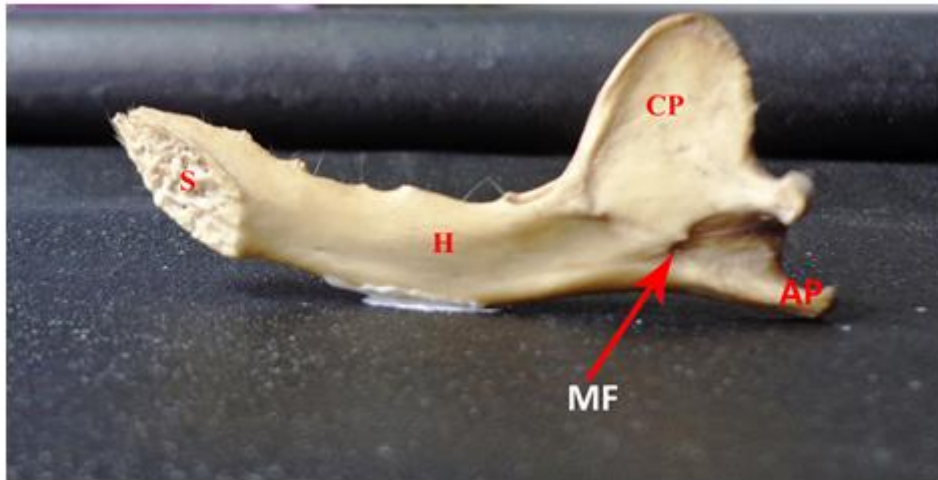


Fig. 3. The Photograph of mandible of Indian mongoose showing Symphysis (S), Horizontal Ramus (H), Coronoid process (CP), Mandibular foramen(MF) and Angular process (AP).

UNDER PEER REVIEW