

Case study

Endoscopic Extraction of Foreign Bodies from The Upper Digestive Tract in Adults – A Case Study

ABSTRACT

Ingestion of foreign bodies is the 2nd most common indication for emergency endoscopy. The nature and location of the foreign body determine the indication and the time required for its extraction.

The aim of our work was to report on the experience of our department in the endoscopic management of foreign bodies in the upper digestive tract.

Our study was retrospective and descriptive over a period of 7 years, and included all patients who required endoscopic management of an ingested foreign body.

During this period, 62 oeso-gastro-duodenal fibroscopies were performed.

Ingestion was accidental in 74.2% of patients. Food impactions were the most frequent (48.4%).

Ingestion of multiple foreign bodies was observed in 8 patients.

In half the cases, the foreign body was found in the oesophagus, in 29% of cases in the stomach and in 3.2% of cases in the duodenum. Foreign body was not found in 17.7% of cases.

According to our series, the success rate of emergency endoscopic extraction of foreign bodies was satisfactory at around 70%, with a low complication rate of around 6.4%.

Keywords: Foreign body, Upper digestive tract, Endoscopic extraction, Endoscopic emergency.

1. INTRODUCTION

Ingestion of foreign bodies (FB) represents 1 to 4% of endoscopic emergencies, ranking second after digestive bleeding (1).

The majority of FBs progress spontaneously along the digestive tract, only 10 to 20% remain impacted, requiring endoscopic intervention and in 1% of cases surgical intervention (2).

The recommended initial assessment is based on detailed questioning, a meticulous clinical examination and simple radiological tests to determine the indication and timing of extraction.

The aim of our study is to report the experience of our Gastro-Enterology Department in the endoscopic management of FBs of the upper digestive tract, by evaluating the indications, the extraction methods used and the success rate.

2. MATERIAL AND METHODS

This is a retrospective and descriptive study, carried out at the Hepato-Gastro-Enterology department of the Ibn Rochd University Hospital in Casablanca, spread over a period of 7 years from January 2015 to January 2023.

We included all patients over 15 years old, who consulted the emergency department for an ingestion of FB located in the upper digestive tract, without signs of complications and who underwent an oeso-gastro-duodenal endoscopy.

Data was collected using a pre-established data collection form, emergency admission registers and endoscopy reports.

3. RESULTS AND DISCUSSION

RESULTS

During the study period, 62 oeso-gastro-duodenal fibroscopies were performed.

The mean age of our patients was 43 years (+/- 17.3 years) with a M/F sex ratio of 2.2.

15 were edentulous (24.1%), 11 were prisoners (17.7%) and 5 had a psychiatric history (8%).

A recurrence of impaction was found in 6.4% of patients.

Ingestion was accidental in 74.2% of cases.

Concerning the characteristics of the FBs, 104 were found in our patients, they were single in 88% of patients and multiple in 12% of cases, with extremes of 2 to 20 FBs per patient.

Food impactions were the most frequently ingested FBs (48.4%) (with bone: 9.7%, without bone: 38.7%), followed by sharp/pointed objects (29%) then foam objects (22.6%).

The consultation delay after ingestion of the FB ranged from 2 hours to 3 months, with an average of 8 days.

Symptoms on admission varied, 25.8% of our patients were completely asymptomatic. Among those who were symptomatic, 16 patients (25.8%) presented with dysphagia, 15 (24.1%) with total aphagia, odynophagia was noted in 7 patients (11.2%) and hypersialorrhoea in 6 patients (9.6%).

As part of the radiological assessment, standard X-rays were taken in 36 of our patients. These revealed radio-opaque FBs in 28 of them.

The radiological detection rate of FBs was 77.7%.

The frontal chest X-ray revealed radio-opaque FBs projecting into the oesophagus in 9 patients (Figure 1, 2).

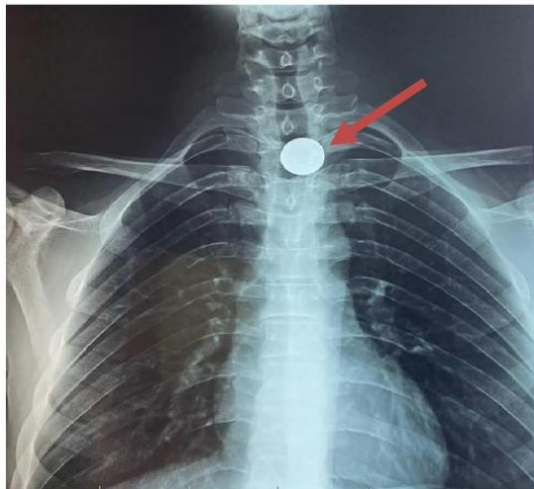


Figure 1: Frontal chest x-ray showing the presence of a coin in the upper third of the esophagus.

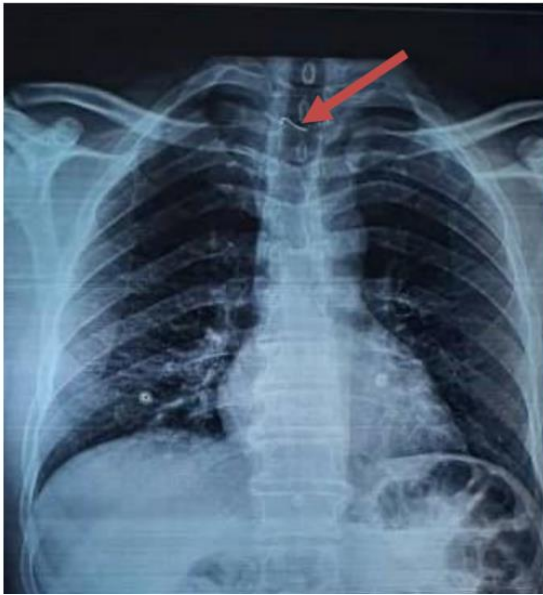

Figure 2: Frontal chest x-ray showing the presence of dentures with metal wire at the upper third of the esophagus.

The unprepared abdominal X-ray showed radio-opaque FBs in 19 patients with variable projections (Figure 3).

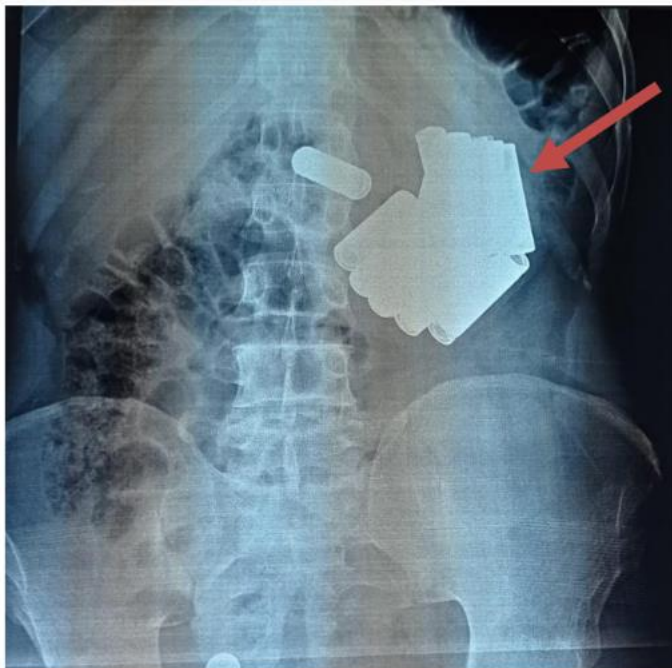


Figure 3: Unprepared abdominal X-ray showing the presence of several piles at the gastric level.

A thoraco-abdomino-pelvic CT scan was performed in 7 patients who had ingested multiple FBs (Figure 4).

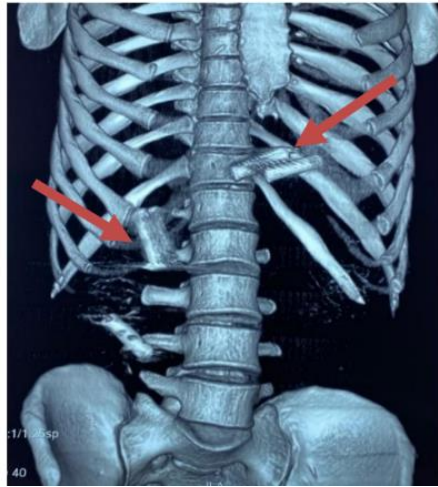


Figure 4: Scanographic reconstruction image objectifying the presence of multiple piles at the gastric and intestinal level.

The average time between the consultation and the oeso-gastro-duodenal fibroscopy was 16 hours [5-72 hours]. It was performed under sedation in the majority of our patients (83%).

FB was found at the esophageal level in 31 patients (50%):

- 18 (29%) at the middle 1/3 level.
- 10 (16.2%) at the lower 1/3 level.
- 3 (4.8%) at the upper 1/3 level.

In 18 patients (29%), it was found in the gastric region, and in 2 patients (3.2%) in the duodenal region.

It was not found in 11 patients (17.7%).

In our series, extractions were mainly performed using the Dormia loop, the polypectomy loop, the mesh loop and the tripod forceps.

It was performed in 44 patients (70.9%) and failed in 7 patients (11.2%), necessitating surgical extraction in 3 patients, while the other patients were able to eliminate the FB spontaneously.

The outcome was favourable in 93.6% of patients.

Complications were present in 6.4% of cases, linked to minor lacerations in the esophagus observed in 3 patients who were placed on PPI with good progress. An esophageal perforation was noted in a single patient, occurring after the extraction of a chicken bone impacted in the esophageal mucosa, treated with clips and antibiotic therapy with good progress.

DISCUSSION

The incidence of FB ingestion is not well known because it can go unnoticed (3).

Food impactions are largely predominant, with an estimated annual incidence of 13/100,000 people (4).

Certain population subgroups are at greater risk of obstruction by FB (5), notably children, patients with a history of upper digestive tract stenosis (peptic, caustic, tumour, etc.), hiatal hernia or motor disorders of the oesophagus (eosinophilic oesophagitis, achalasia, etc.) (6) and prisoners.

In adults, the average age of ingestion of FB is 60.2 years for dietary FB and 53.9 years for non-food FB (3).

Thus, in the Taiwanese study by Chung-Ying (7), which included 280 adult patients who had undergone endoscopic treatment for FB ingestion, the mean age of the patients was 56 years.

This contrasts with the Sahota study (8) and our study, in which the mean age was 32 and 43 years respectively.

Male predominance was reported by several authors, notably in a study conducted by Shrestha et al (9), including 119 patients, 61.3% of whom were male.

The same observation was also noted in the study of Sahota (8) and Chih-chien Yao (10), with 60% and 61% of male patients respectively.

These results are consistent with those of our study.

The ingestion of FB in adulthood frequently occurs in patients with a particular background.

Compared with our series, in which psychiatric disorders were present in 8% of patients, the rate in Selivanov's series (11) was 10%.

Prisoners accounted for 20% of patients in Selivanov's series (11) and 17.7% in our series.

An anatomical or functional oesophageal anomaly is present in 40% of cases (2) and can reach up to 75% in cases of oesophageal food impaction (12).

In Shen's study of 1088 patients admitted for FB ingestion, oesogastric tract abnormalities were found in 8% of patients and included oesophageal cancer (33%), oesophageal stenosis (23.9%), oesophageal diverticulum (15.9%), gastrectomy (11.4%), hiatal hernia (10.2%) and achalasia (5.7%) (13).

In our series, 6 patients (9.6%) had abnormalities which could lead to food blockage: two caustic strictures (3.2%), a diaphragm of the oesophagus (1.6%), oesophageal cancer (1.6%), duodenal stricture in Crohn's disease (1.6%) and oesophageal diverticula (1.6%).

Ingestion of FB is most often accidental (97%) (14).

In Sahota's series (8), it was accidental in 96% of patients.

Our results are in line with those reported in the literature, since accidental ingestion represented 74.2% of cases.

Ingested FBs were most often single in 97% of cases, but may also be multiple. A record of 2533 FBs found in the stomach of a single patient was reported (15).

Similarly, the FB was single in 88% of patients in our series and multiple in 12%.

In the series by Shrestha (9) and Chih-Chien Yao (10), the majority of ingested FBs were food-related.

These results match those of our series, in which food impactions were reported in 48.4% of patients, sharp and pointed objects were found in 29% of patients, with a clear predominance of dentures and foam FBs in 22.6%.

Symptoms depend on the patient's age, history, size and location of the FB (16).

In the series by Chih-Chien Yao (10), odynophagia was the most common symptom reported by patients (36.5%), followed by dysphagia and sensation of FB in 27% of cases, chest pain in 4.2% of cases and nausea in 3.1% of cases. However, 17.7% of patients were asymptomatic.

In our series, 25.8% of symptomatic patients had dysphagia, and a quarter of patients were asymptomatic.

Standard X-rays are only recommended in the case of radio-opaque FB, bone foods, objects of unknown type, or when a complication is suspected (2,5), to determine the location, type and number of FB ingested (2,5).

In some cases, a thoraco-abdomino-pelvic CT scan with injection of contrast product may be useful, particularly if complications are suspected (perforation, occlusion, etc.), or if surgery is being considered (2,5). In the Chung-Ying study (7), the detection rate of FBs by standard radiography was 53% (122/230), and was significantly higher in the stomach and duodenum than in the pharynx and oesophagus (73.9% versus 50.7%; $p < 0.05$).

Chih-Chien Yao et al (10) reported a detection rate of 33.3% (44/131) by standard radiography.

In contrast to our series, the rate of detection of FB by standard radiography was higher (77.7%).

The decision to perform a digestive endoscopy and the time required to perform it depend on several factors (3), in particular the anatomical location of the object, whether or not it is obstructive, its contours (pointed, sharp or not), its nature (button cell, magnet) and its size (possibility or not of passing through the cardia and pylorus).

According to European recommendations, endoscopy should be performed :

- Within 2 to 6 hours, for stenosing oesophageal FBs, batteries or intra-oesophageal sharp or pointed objects.
- Within 24 hours for non-stenosing oesophageal FBs, sharp or pointed intragastric objects, magnets, batteries and long (>6cm) or wide (>2.5cm) objects.
- Within 72 hours for medium-sized foam intragastric objects (17).

On the other hand, the ESGE recommends simple monitoring without endoscopic procedures for asymptomatic patients who have ingested intragastric foam FBs smaller than those mentioned above, with the exception of batteries and magnets (17).

However, patients should be vigilant for warning signs and monitor their stools. In this case, weekly monitoring by means of an unprepared abdominal X-ray is sufficient to document the progression of FB. At four weeks, if the object is still intragastric, endoscopic extraction should be performed. (12)

In the study by Chung-Ying (7), the average time taken to perform oeso-gastro-duodenal fibroscopy was 5.9 hours (± 5.2).

As for our study, this delay was 16 hours [5-72 hours].

33.7% of patients underwent the procedure early, in less than 6 hours.

Extraction of a FB should be performed under general anaesthetic, ideally after orotracheal intubation to prevent the risk of inhalation (3).

In contrast to our series, the majority of patients underwent endoscopic exploration and extraction under

sedation (83%).

The most commonly described sites of blockage are ENT, the three zones of physiological narrowing of the oesophagus and the pylorus (14).

In the study by Chih-Chien Yao (10), the sites of impaction were distributed as follows: oesophagus (75.6%), stomach (12.5%), pharynx (8.3%), anastomoses (2.4%) and duodenum (1.2%).

The oesophagus was also the main site of impaction of ingested FBs (77.9%) in the Chung-Ying series (7), with the other sites of impaction being the stomach (12.3%), pharynx (8.8%) and duodenum (1.1%).

Our results are in line with those reported in the literature: the oesophagus was also the predilection site for FB (50%), followed by the stomach (29%) and the duodenum (3.2%).

Regarding the means of extraction, it is recommended to choose the endoscopic extraction equipment according to the type of object and the habits of the endoscopist (3).

In the Chih-Chien Yao cohort (10), the most frequently used equipment was: biopsy forceps (67.1%), baskets (14%) and polypectomy loops (11.7%).

Shrestha et al report that the extraction of FBs was most often performed using the Dormia basket (84.1%).

In our series, they were most frequently extracted using the Dormia loop, the polypectomy loop and the tripod forceps.

In the study by Shrestha et al, the "push" technique was used for alimentary impactions after air insufflation (9). This technique was also the most commonly used in our series. In cases where food bowls were difficult to dislodge, biopsy forceps were used for fragmentation, followed by piecemeal extraction.

The success rate of endoscopic management of FB ingestions varies from 90 to 95% according to the latest studies (14).

In the study by Shrestha et al (9), the success rate was 93.5%.

An excellent success rate for endoscopic extraction (93.4%) was also reported in the series by Chih-Chien Yao (10).

In our series, this rate was 70%.

The complication rate of endoscopic extraction of impacted FBs in the upper gastrointestinal tract is estimated to be less than 5% (14).

In the series by Chung-Ying (7), this rate was 4.9%, with 3.1% of patients having lacerations of the oesophageal mucosa, and the remainder presenting with oesophageal microperforation with pneumomediastinum, mediastinitis or abscess.

Our results are similar to those reported in the literature, with a rate of 6.4% in which lacerations of the oesophageal mucosa were observed in 3 patients and only one patient had oesophageal perforation.

4. CONCLUSION

Ingestion of a foreign body is a frequent occurrence during endoscopic emergencies, mostly secondary to food impactions requiring in this case the systematic search for a pre-existing oesophageal disease.

Management should be multidisciplinary, involving emergency physicians, radiologists, gastroenterologists, surgeons and psychiatrists.

Foreign bodies require endoscopic extraction in 10 to 20% of cases and surgical intervention in less than 1% of cases, although they pass spontaneously through the digestive tract in more than 80 to 90% of cases without complications.

The indication and time for performing endoscopy depend on several factors, including the location and type of the foreign body ingested.

The success rate of endoscopic treatment of ingestion of foreign bodies varies from 90% to 95% with a complication rate of this treatment of less than 5%.

Management also involves prevention work with education of populations at risk and those around them.

REFERENCES

1. Mosca S, Manes G, Martino R, et al. Endoscopic management of foreign bodies in the upper gastrointestinal tract: report on a series of 414 adult patients.. Endoscopy 2001.
2. Fraga.M et al, Risks and benefits of an interventional approach to digestive foreign bodies, Rev Med Switzerland 2015.

3. Britschu O, Caron B, Berdugo Y, Gronier O. Management of foreign bodies in the digestive tract. Hepato-Gastro and Digestive Oncology 2021.
4. Longstreth GF, Longstreth KJ et Yao JF. Esophageal food impaction: epidemiology and therapy. A retrospective, observational study. Gastrointest Endosc 2001.
5. Webb WA. Management of foreign bodies of the upper gastrointestinal tract: update. Gastrointest Endosc 1995 ; 41(1) : 39-51.
6. Libânio D, Garrido M, Jácome F, et al. Foreign body ingestion and food impaction in adults: better to scope than to wait. United European Gastroenterol J 2018 ; 6 (7) : 974-980.
7. Chung-Ying.L et al, Retrospective analysis of endoscopic management of foreign bodies in the upper gastrointestinal tract of adults, Journal of the Chinese Medical Association 82(2): p 105-109, February 2019.
- 8.Sahota A, Shandil R, Barmaki A. R, Salama P, Simpson NI. Foreign body ingestions : Characteristics and outcomes in a lower socioeconomic population. Gastrointestinal endoscopy 2006.
9. Ramila Shrestha,et al, Successful Endoscopic Management of Suspected Foreign Bodies in Upper Gastrointestinal Tract among Patients Undergoing Upper Gastrointestinal Endoscopy in a Tertiary Care Hospital: A Descriptive Cross-sectional Study, JNMA J Nepal Med Assoc. 2021 Jul.
10. Chih-Chien Yao et al, Endoscopic Management of Foreign Bodies in the Upper Gastrointestinal Tract of Adults Biomed Res Int. 2015 jul 15.
- 11.Selivanov V, Sheldon G. F, Cello J. P, Crass R. A. Management of foreign body ingestion. Annales Surgery 1984; 199, 2 :187-91.
12. Vincent QUENTIN Foreign bodies of the upper digestive tract in adults, POSTU 2020
13. Zhao-Shen L, Zhen-Xing S, Duo-Wu Z, Guo-Ming X, Ren-Pei W. Endoscopic management of foreign bodies in the upper-GI tract: experience with 1088 cases in China. Gastrointestinal endoscopy 2006.
14. Quentin.V Foreign bodies of the upper and lower digestive tract, Hepato-Gastro and Digestive Oncology / Volume 29; Number 2 ; February 2022.
15. Monat S, Barouk J, Le Rhun M. Management of foreign bodies of the upper digestive tract. Hepato-gastroenterology 2001.
16. Lazartigues J, Lamarque D, Campeotto F. Ingestion of foreign bodies: when and what to see? Hepato Gastro 2018.
17. Birk M, Bauerfeind P, Deprez PH, et al. Removal of foreign bodies in the upper gastrointestinal tract in adults: European Society of Gastrointestinal Endoscopy (ESGE) Clinical Guideline. Endoscopy 2016.