

Original Research Article

**ASSESSING THE IMPACT OF ONION JUICE ON THE LEVELS OF
LEUTINIZING
HORMONE AND FOLLICLE STIMULATING HORMONE IN FEMALE
MICE EXPOSED
TO TRANSFLUTHRIN SMOKE.**

ABSTRACT

Aim: Transfluthrin is a fast-acting insecticide used in household mainly against mosquito. Its uses have not been without health risk to humans. The study aims at evaluating the effect of onion juice on follicle stimulating hormone and leutinizing hormone levels in mice exposed to transfluthrin smoke.

Study Design: This is an animal study conducted in the Animal House, College of Medical Science in Rivers State University.

Material and Methods: Thirty (30) female mice were used in this study. They were divided into six groups of five mice each; Group 1(negative control, exposed to normal environmental air), Group 2(exposed to 6g of transfluthrin coated insecticide paper smoke and given 0.2ml of onion juice), Group 3(exposed to 6g of transfluthrin coated insecticide paper smoke only), Group 4(exposed to 12g of transfluthrin coated insecticide paper smoke and given 0.2ml of onion juice), Group 5(exposed to 12g of transfluthrin coated insecticide paper smoke only), Group 6(given 0.2ml of onion juice only) through the oral gavage method daily. The smoke inhalation lasted for 15 minutes daily for 28 days.

Results: There was a significant difference in the mean values of Follicle Stimulating Hormone in groups 2, 3, 4, 5 & 6 when compared to group 1 ($P=0.004$). There was no significant difference observed in the mean values of Leutinizing Hormone in the various groups ($P=0.068$). The ovaries in groups 2, 3, 4, 5 & 6 showed several distortion and fluid congestion.

Conclusion: This study shows that the exposure significantly altered the hormonal levels and the ovarian cyto architecture of the mice. It also reveals that exposure to transfluthrin is detrimental to the reproductive functions of female mice however, the Onion juice administered to the mice in this study showed no ameliorative effect on the ovarian distortion, hence not improving the reproductive status of the mice.

KEYWORDS: *Transfluthrinsmoke, LH, FSH, OnionJuice, fertility, reproductive health.*

1. INTRODUCTION

Lifestyle factors, which include the practices we adopt in our daily life, have a significant role in shaping our overall health. Several factors have been claimed to affect women's fertility; lifestyle-related factors, in particular, have received great attention in the last decade. Transfluthrin is a commonly used synthetic pyrethroid insecticide that is widely utilized for its insecticidal properties in various household products [1]. Transfluthrin is very active in controlling malaria by killing mosquitos via inhalation or contact with the substance (World Health Organization [2, 3]). Its usage has become a daily lifestyle practice for most homes. However, concerns have been raised regarding its potential adverse effects on endocrine function, particularly in female mammals [4]. Luteinizing hormone (LH) and follicle-stimulating hormone (FSH) play critical roles in regulating the reproductive system. Any disruption in the normal secretion or balance of these hormones can have profound implications for female fertility and reproductive health [5,

6, 7]. Onion (*Allium cepa*) is a well-known vegetable with a rich composition of bio active compounds, including flavonoids and sulfur-containing compounds. Previous studies have suggested that onion possesses antioxidant and anti-inflammatory properties, and it may also exert modulatory effects on hormone levels. Specifically, onion has been reported to influence the endocrine system by altering hormone secretion or activity, making it a potential agent or intervention for mitigating the adverse effects of endocrine disruptors. It is also prominent for its reproductive health boosting properties [8]. It is estimated that at least 51 synthetic chemicals are ubiquitous in our environment, all of which are suspected reproductive toxicants [9]. As a result of this, pyrethroids, where Transfluthrin belongs are able to bind to mammalian steroid receptors and disrupt the steroid signaling pathways [10], thereby adversely affecting reproduction and sexual development [11]. This transfluthrin exposure might cause poor oocyte maturation and competency, meiotic maturation of oocytes, embryonic defects and poor IVF outcomes in animal studies [12]. Therefore, the essence of evaluating the effect of onion juice on LH and FSH levels in female mice exposed to transfluthrin smoke.

2. MATERIALS AND METHODS

2.1 Animals

Thirty (30) female mice were obtained from Animal care unit at Rivers State University, NkpoluOroworukwo, Port Harcourt, Nigeria. They were housed in semi-transparent plastic cages under standard laboratory conditions with a 12 hours daylight cycle and have access to feed and water ad libitum. They were acclimatized to laboratory conditions for 2 weeks before grouping for the experiments. Animal laboratory conditions room temperature, 40 to 50% humidity and proper ventilation. Experimental procedures involving the animals and their care were conducted in conformity with International, National and Institutional guidelines for the care of laboratory animals in Biomedical Research [13].

2.2 Animal Feed

Pelletised Vital Feed (ultima) was obtained from a store in Rumuokoro market, River State, Nigeria and used to feed the mice during the experiment.

2.3 Transfluthrin Coated Insecticide Paper (TCIP)

The Transfluthrin insecticide paper (Rambo® Bayer Crop science, Gongoni Company Limited) was purchased from a retail store in Mile One Market, Port Harcourt, Rivers state Nigeria. This insecticide paper weighed 6 g and contained 0.45% of transfluthrin, 2.5% of Essential Oil and 97.05% of inert ingredients.

2.4 Transfluthrin Smoke Exposure

6grams and 12 grams of Transfluthrin coated insecticide papers respectively were burnt and the experimental mice were exposed to the transfluthrin smoke. The papers were placed inside a transparent plexiglass box (0.6x0.5x0.1 m³) with flow ports which acted as an inhalation chamber to perform the smoking process using a modified smoking machine. After placing the mice inside the inhalation chamber, a vacuum pump withdrew smoke from burned repellent papers inside the chamber to produce a smoky environment. The smoking procedure lasted for 15 minutes' duration daily for 28 days. Onion juice was administered once daily for period of 28days after they are exposed to the smoke. After the experimental period, the mice were sacrificed under chloroform euthanasia on the 29th day, blood samples were collected for the biochemical analysis of follicle stimulating hormone and Leutinizinghormone. The ovaries were harvested and placed into a sample container containing formaline then followed by histological examination.

2.5 Onion Juice Preparation

Onion bulb was obtained from mile one market, River State, Nigeria. The fresh onion bulbs were washed, cut into small pieces and rubbed against a grater. It was squeezed and filtered through a fine cloth to obtain the juice. 0.2mls of the onion juice was administered to the mice with the aid of a flexible oral gavage tube for a period of 28 days. Fresh onion juice was prepared daily in the morning for the experimental purpose.

2.6 Experimental Groups/ Design

Group 1 (Negative Control) was given feed and distilled water and exposed to normal environmental air for 28 days.

Group 2 (6g of TCIP smoke plus onion juice) mice were exposed to (6g) transfluthrin coated insecticide paper smoke for 15 minutes daily for 28 days, then administered 0.2mls of fresh onion juice daily using the oral gavage method.

Group 3 (6g of TCIP smoke without onion juice) mice were exposed to low concentration (6g) of transfluthrin coated insecticide paper smoke for 15 minutes daily without administration of onion juice (0.2ml).

Group 4 (12g of TCIP smoke with onion juice) mice were exposed to high concentration of transfluthrin coated insecticide paper smoke for 15 minutes daily (12g) and also administered 0.2ml of fresh onion juice daily using the oral gavage method.

Group 5 (12g of TCIP smoke without onion juice) mice were exposed to high concentration of transfluthrin coated insecticide paper smoke (12g) without the administration of fresh onion juice

Group 6 (only Onion juice) mice were orally administered fresh onion juice (0.2ml) using the oral gavage method daily without exposure to the transfluthrin smoke for 28 days.

2.7 Blood collection

3mls of blood sample was collected through cardiac puncture into plain sterilized centrifuge bottles and allowed to clot. The serum was separated by centrifugal force at 3000rpm for 15 minutes and collected in sample bottles for determination of FSH AND LH levels.

2.8 Hormone Analysis

LH and FSH levels were quantified using enzyme-linked immunosorbent assay (ELISA) kits from Fortress diagnostics Ltd (Antrim, UK)

2.9 Histological Examination

The ovary was immersed in 10% formal saline solution in tissue sample bottle. The paraffin-embedded samples were sectioned at 5 mm thickness. The samples passed through each stage of tissue processing. They were grossed, and placed in labeled tissue cassettes and introduced into ascending grades of alcohol, (70%, 90%, Absolute 1 and 2) for dehydration and further introduced into two changes of xylene for clearing. The tissues were infiltrated and embedded with molten paraffin wax and solidified with cold ice packs. The prepared tissues were sectioned using a rotary microtome and the selected ribbons was picked in clean grease free slides. They were heat fixed on a hot plate and dewaxed in xylene, hydrated in descending grades of alcohol and taken to water bath before proceeding with the staining procedure. Haematoxylin and Eosin staining technique was used to stain the tissues. finally, the slides containing the tissue sample was covered with a cover slip after the application of DPX for mounting and then observed under the light microscope. Photomicrographs of the sections were obtained.

2.10 Statistical Analysis

GraphPad Prism version 9.0.4 of Apple Macintosh HD Big Sur (version 11.0) statistical package was used for data analysis. ANOVA was used to compare means between the various groups for inferential evaluation. Tukey's multiple comparison test was used to compare mean values in groups that were significantly different. The probability (p) value less than 0.05 was considered statistically significant.

3.RESULTS

Table 1: Mean \pm SD of Follicle Stimulating Hormone and Leutinizing Hormone levels in Mice with different treatment requirement for two weeks.

Group/Treatment Design	Follicle Stimulating Hormone ng/ml	Leutinizing Hormone ng/ml
Group 1(Negative control)	0.967 \pm 0.355 ^a	1.40 \pm 0.515
Group 2(low dose from TCIP smoke + onion)	0.590 \pm 0.370 ^b	0.85 \pm 0.530
Group 3(low dose from TCIP smoke)	0.580 \pm 0.130 ^c	0.81 \pm 0.175
Group 4(high dose from TCIP smoke + onion)	0.643 \pm 0.1007 ^d	0.92 \pm 0.140
Group 5(high dose from TCIP smoke)	1.083 \pm 0.205 ^e	1.547 \pm 0.295
Group 6(positive control) onion only	1.453 \pm 0.095 ^f	1.673 \pm 0.467
F value	6.412	3.944
P value	0.004	0.068
Remark	Significant	Not significant

N=5, values with different super scripts are significantly different from each other ($P=0.05$)

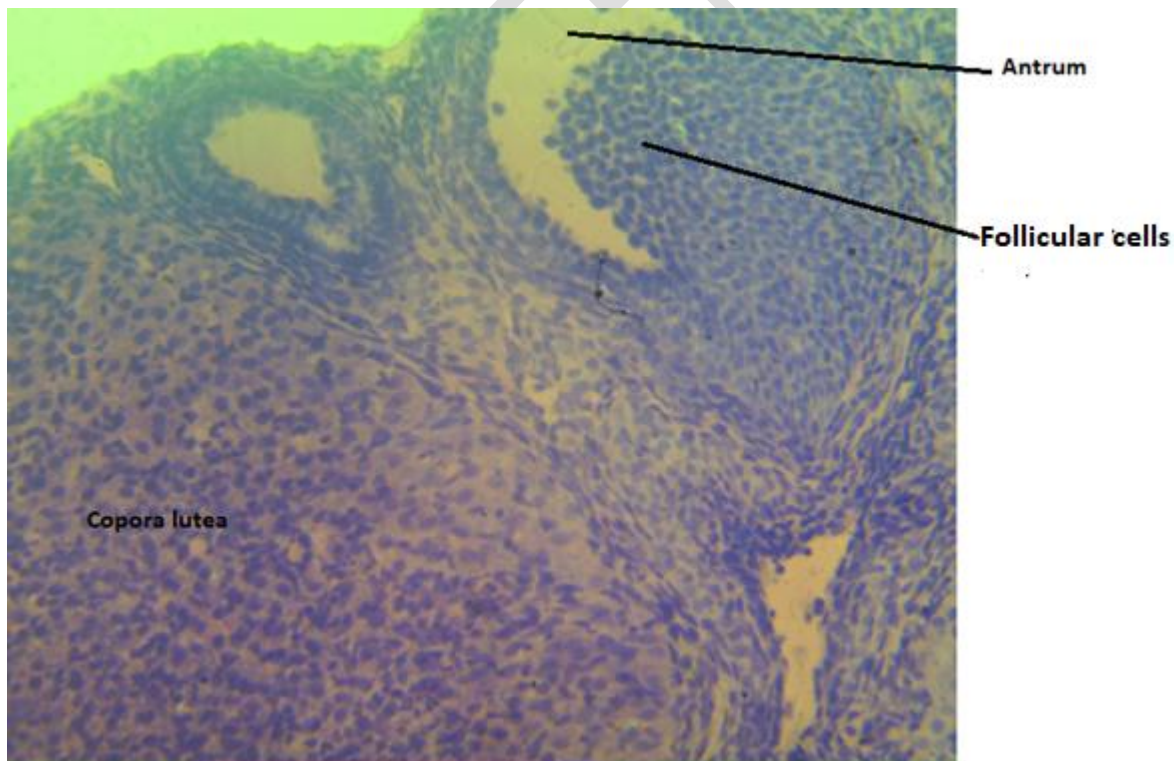


Plate 1: (Group 1) Photomicrograph of the ovary tissue showing primary follicles with developing antrum, Well delineated corpora lutea observed. Normal tissue observed at higher magnification. H & E, X400.

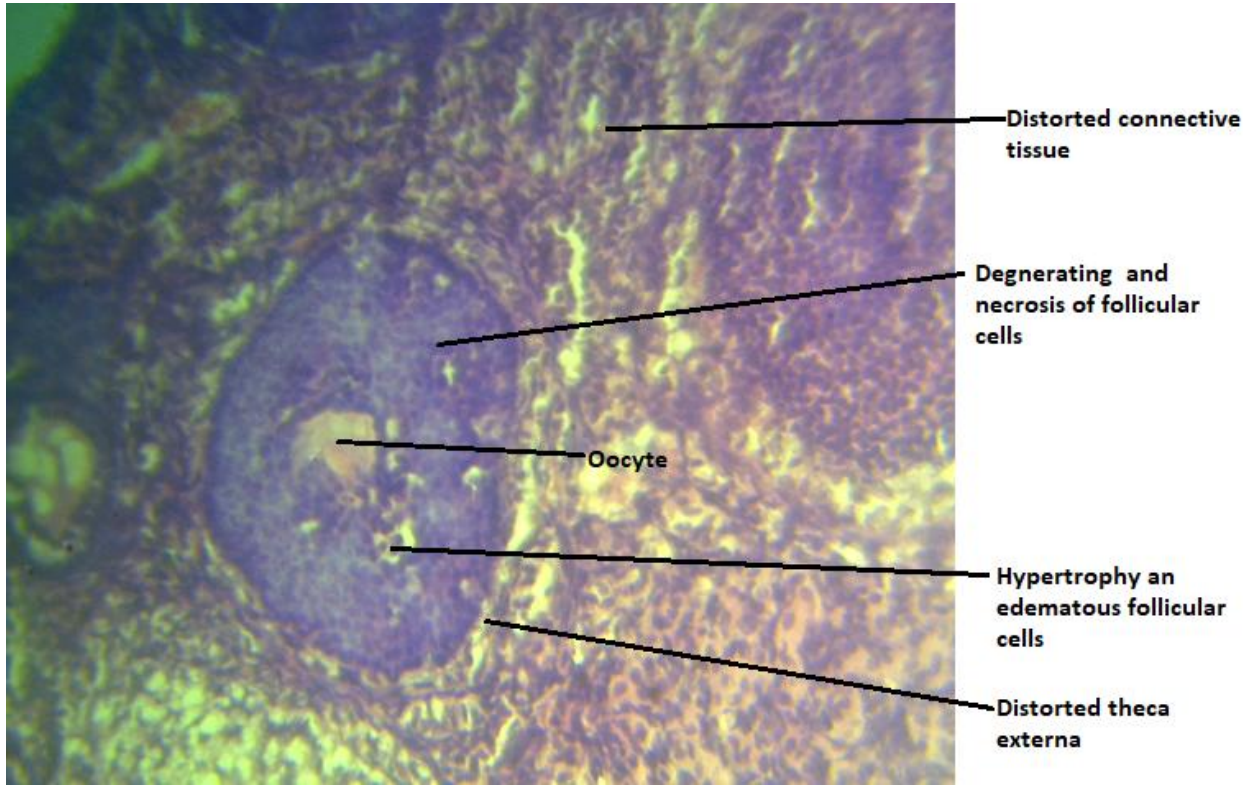


Plate 2: (Group 2) Photomicrograph of the ovary tissue showing degenerating, necrosis and hypertrophy of follicular cells, large oocyte. The theca externa shows distortion. The connective tissue also shows distortion. Tissue shows distortion of cytoarchitecture. H & E, X400.

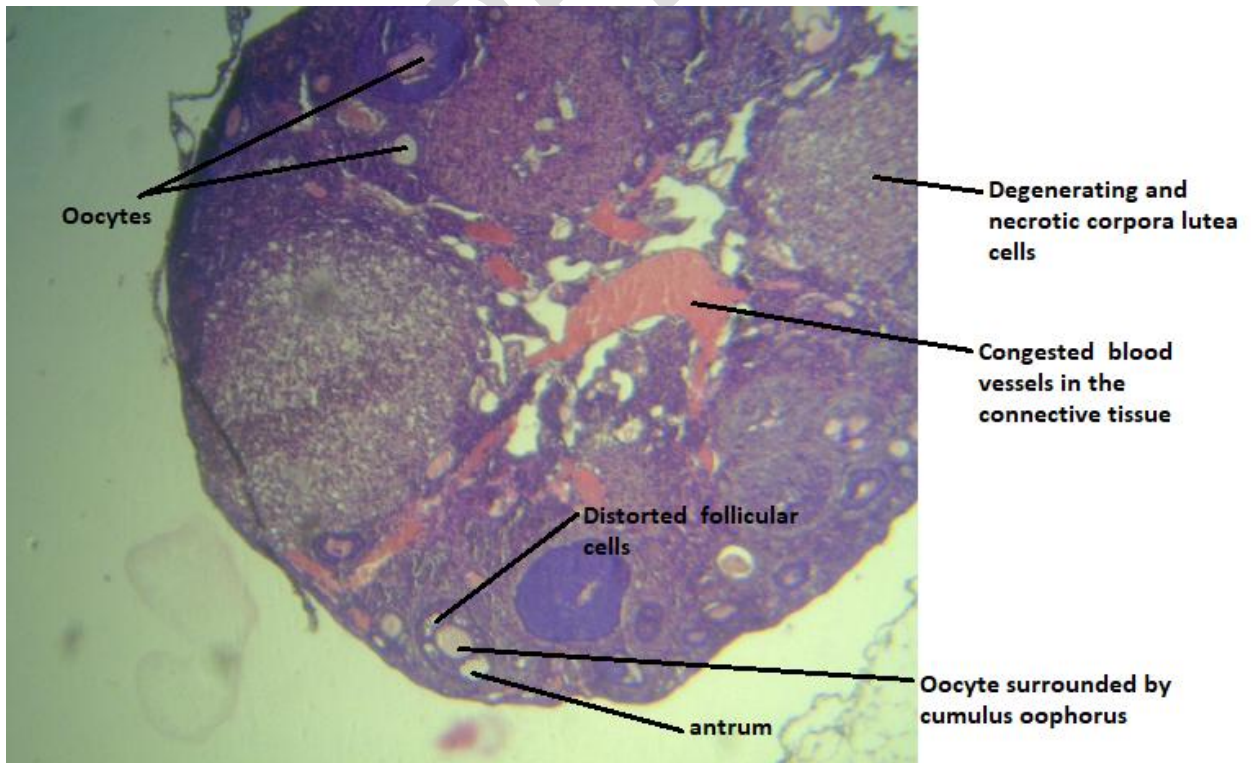


Plate 3: (Group 3) Photomicrograph of tissue showing severe congestion of blood in the connective tissue space, distorted follicular cells of a secondary follicle and degeneration/necrosis of corpora lutea cells. Several primordial and primary follicles are observed. Severe tissue distortion. H & E, X100.

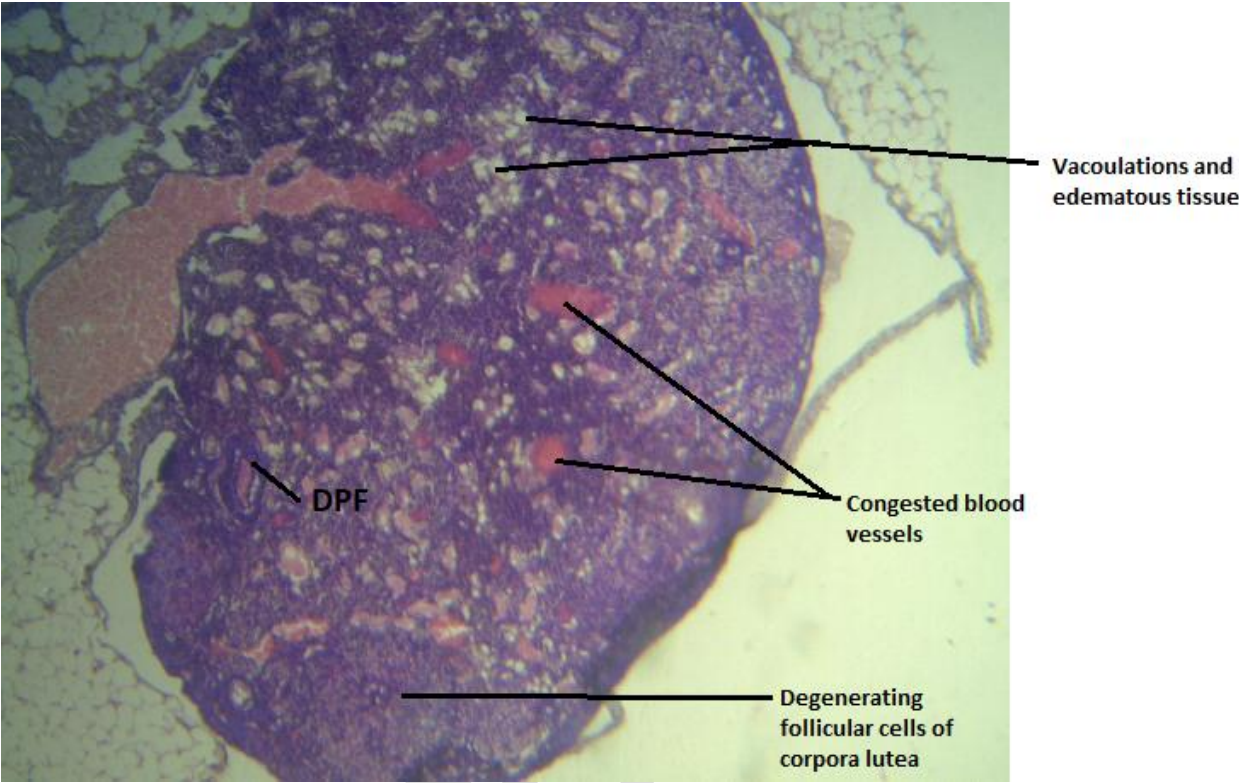
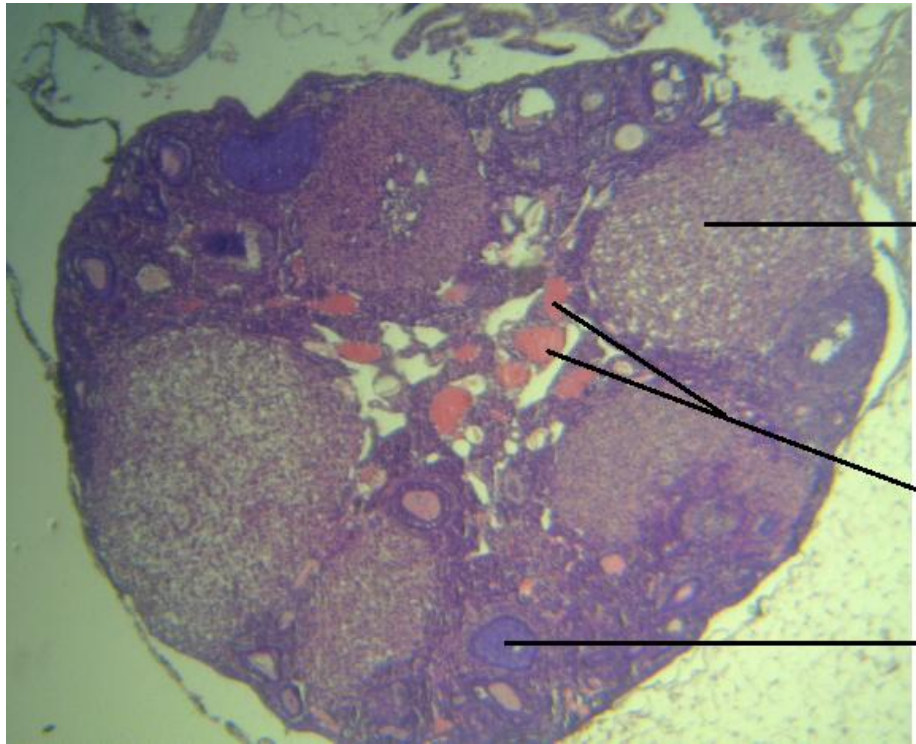


Plate 4: (Group 4) Photomicrograph of ovary tissue showing severe distortion of connective tissue cytoarchitecture, diffused vacuolation and distortion of primary follicle (DPF) and congested blood vessels and fluid filled tissue. Severe distortion of ovary tissue. H & E, X100.

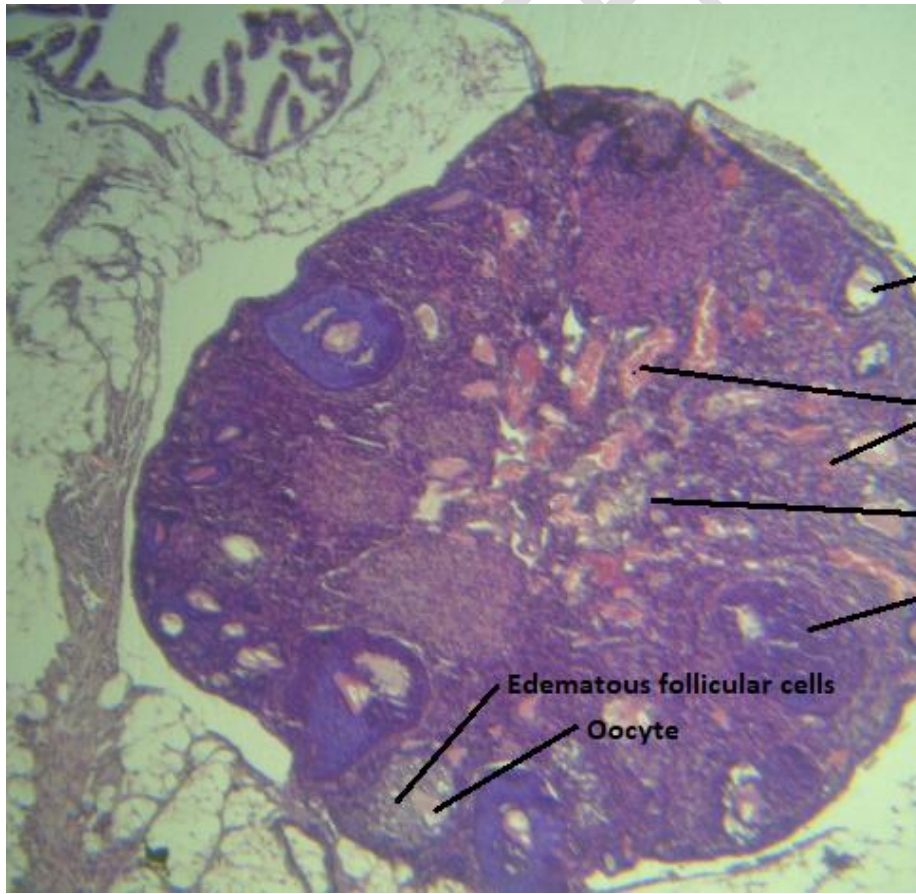


Degenerating and necrotic cell in corpora lutea with several vacuoles

Congested blood vessels in connective tissue

Degenerating primordial follicle

Plate 5: (Group 5) Photomicrograph of ovary showing degenerating and necrotic cells in corpora lutea, and congested blood vessels in the connective tissue. The follicular cells in primary follicle indicate degeneration. Distortion of tissue cytoarchitecture is indicated. H & E, X100.



Fluid filled antrum

Blood congestion in vessels

Connective tissue distortion

Follicular cells distortion

Edematous follicular cells

Oocyte

Plate 6: (Group 6) Photomicrograph showing pockets of edematous follicular cells in primary follicle. There is also mild distortion of the connective tissue. The corpora lutea show distinct appearance. Mild distortion of tissue indicated. H & E, X100.

4. DISCUSSION

The function of the female reproductive system depends upon hormone concentrations and their balance. Endocrine disruption may result in disturbances in the reproductive system, such as modulation of hormone concentrations, ovarian cycle irregularities, and impaired fertility [14].

The result showed a significant difference in the mean values of follicle stimulating hormone levels in the various groups as showed in Table 1. From the result, there was a significant increase in Group 6 the positive control group (FSH-1.453±0.095) which was not exposed to the TCIP smoke but was administered with onion juice when compared with Group 1, the negative control group (FSH-0.967±0.355). The result showed that the onion juice had an effect on follicle stimulating hormone with no effect in LH. This is at variance with the study by Khaki *et al* [15] where the levels of LH significantly increased only in the group that received the high dose of fresh onion juice ($P < 0.004$), however the level of FSH did not differ between the experimental and control groups. This observation might have been attributed to the specific compounds present in the onion juice that could have had a direct impact on the regulation of FSH levels. Onion contains phytochemicals and antioxidants that have been shown to affect hormone levels and improve reproductive health [16]. These compounds might have interacted with the hypothalamic-pituitary-gonadal axis, which is responsible for regulating the production and release of FSH and LH. It is also possible that the compounds in onion juice stimulated the production of FSH, leading to an increase in its levels, while not affecting the production of LH as in a study by Narges *et al* [17]. However, a study by Neda & Mehrdad [18] showed no significant changes in FSH and LH levels when onion juice were used to check effects on reproductive hormones.

The photomicrograph of Group 3 (Plate 3) exposed to low dose of TCIP smoke only, showed severe congestion of blood in the connective tissue space, distorted follicular cells of a secondary follicle and degeneration/necrosis of corpora lutea cells. Several primordial and primary follicles were observed with severe tissue distortion. The photomicrograph of Group 5 (Plate 5) which was exposed to high dose of TCIP smoke only, showed degenerating and necrotic cells in corpora lutea and congested blood vessels in the connective tissue. The follicular cells in primary follicles indicate degeneration while there was distortion of tissues in the cytoarchitecture. From these observations, it is indicative that the result was consistent with the report by Marettova *et al* [19] which showed the effect of pyrethroids on female genital system as, resulting in atresia of follicles, decrease in the number of follicular cells, oocytes, corpora lutea and also induced vesicular atrophy of the endometrial glands. Whereas, the photomicrograph of the ovaries of Group 2 (Plate 2) mice exposed to low dose (6g) of TCIP smoke and administered onion juice showed degenerating necrosis and hypertrophy of follicular cells, large oocyte with the theca externa showing distortion hence no ameliorating effect seen by the onion juice administered. Likewise the same observation was noticed in the Plate 4 (Group 4) mice exposed to high dose (12g) of the TCIP smoke with the administration of the onion juice. There was a severe distortion of connective tissue cytoarchitecture, diffused vacuolation, distortion of primary follicle (DPF), congested blood vessels and fluid filled tissue with severe distortion of ovarian tissues. This result is not in agreement with a similar study by Jeje *et al* [20] who evaluated the protective role of *Allium cepa* Linn (onion) juice on maternal dexamethasone induced alterations in reproductive functions of female offspring of Wistar rats with the results suggesting that *Allium cepa* ameliorated deleterious reproductive alterations and ovarian oxidative stress in offspring of lactating Wistar rats treated with dexamethasone.

Onion juice has been shown to have antioxidant properties and potential protective effects in various studies [20]. However, the ameliorating effect of the onion juice on toxicity induced ovarian damage was not clearly observed in this study. The reason could have been the bio availability of the phytochemicals or bioactive compounds, dosage or the duration of exposure of the experiment which lasted for 4 weeks as compared to the study of Khaki *et al* [21] which lasted for a period of 2 months with resultant significant effect of *Onion* juice on the increases in the number of Leydig cells.

The results observed in this study also suggests that the transfluthrin smoke are detrimental to the ovaries hence inflicting a negative impact which might lead to infertility. The photomicrograph of group 6

mice (Plate 6) treated with onion juice without exposure to transfluthrin insecticide smoke showed enlarged oocyte surrounded by coronary radiata cells, pockets of distortion of follicular cells in primary follicle, well distinct corpora lutea and mild distortion of follicles. This shows certain developmental or structural changes in the ovaries which is suggestive that the transfluthrin affects the ovaries despite the administration of onion juice [22]. However, from the result obtained there were discrepancies between the biochemical and histology report which could be as a result of autoregulatory mechanisms leading to biochemical derangement, these mechanisms can lead to variations in biochemical markers, making it difficult to accurately reflect the underlying histological changes [23]. Another reason could be random selection of histology slides which can lead to inconsistency with biochemical reports [24]. This is because variations in slide staining and scanning procedures, such as dye batch, slice thickness, and whole slide scanner used, can compromise feature stability [25]. Therefore, random selection of histology slides without considering feature stability can result in inconsistencies between histomorphometric features and biochemical reports [26].

5. CONCLUSION

The onion juice was able to cause an increase in the Follicle stimulating hormone with no effect on the Leutinizing hormone and there were damages in the ovaries due to the toxicity of the Rambo paper smoke and co-administration with the onion juice did not ameliorate the effect caused by the exposure. Use of transfluthrin coated insecticide paper damages the ovary and can lead to infertility.

REFERENCES

1. Chrustek A, Holyńska-Iwan I, Dziembowska I, Bogusiewicz J, Wróblewski M, Cwynar A, Olszewska-Słonina D. Current Research on the Safety of Pyrethroids Used as Insecticides. *Medicina (Kaunas)*. 2018; 54(4): 61. doi: 10.3390/medicina54040061. PMID: 30344292; PMCID: PMC6174339.
2. Masalu JP, Finda M, Killeen GF. *et al.* Creating mosquito-free outdoor spaces using transfluthrin-treated chairs and ribbons. *Malaria Journal*. 2020; 19: 109. <https://doi.org/10.1186/s12936-020-03180-1>
3. Masalu JP, Finda M, Okumu FO. Efficacy and user acceptability of transfluthrin-treated sisal and hessian decorations for protecting against mosquito bites in outdoor bars. *Parasites Vectors*. 2017; 10: 197. <https://doi.org/10.1186/s13071-017-2132-6>
4. Oyeniran DA, Ojewale AO, Jewo PI, Ashamu EA, Adeniyi OO, Adelokun SA. Infertility: A product of smoke emanating from Transfluthrin coated insecticide paper (TCIP). *Toxicology Research and Application*. 2021; 5. doi: [10.1177/23978473211025467](https://doi.org/10.1177/23978473211025467)
4. Bosch E, Alviggi C, Lispi M, Conforti A, Hanyaloglu AC, Chuderland D, Simoni M, Raine-Fenning N, Crépieux P, Kol S, Rochira V, D'Hooghe T, Humaidan P. Reduced FSH and LH action: implications for medically assisted reproduction. *Human Reproduction*. 2021 ;36(6): 1469-1480. doi: 10.1093/humrep/deab065. PMID: 33792685; PMCID: PMC8129594.
5. Oduwole OO, Huhtaniemi IT, Misrahi M. The Roles of Luteinizing Hormone, Follicle-Stimulating Hormone and Testosterone in Spermatogenesis and Folliculogenesis Revisited. *Int J Mol Sci*. 2021; 22(23): 12735. doi: 10.3390/ijms222312735. PMID: 34884539; PMCID: PMC8658012.

6. Raju GA, Chavan R, Deenadayal M, Gunasheela D, Gutgutia R, Haripriya G, Govindarajan M, Patel NH, Patki AS. Luteinizing hormone and follicle stimulating hormone synergy: A review of role in controlled ovarian hyper-stimulation. *Journal of Human Reproductive Sciences*. 2013; 6(4): 227-34. doi: 10.4103/0974-1208.126285. PMID: 24672160; PMCID: PMC3963304.
7. Griffiths G, Trueman L, Crowther T, Thomas B, Smith B. (). Onions—A global benefit to health. *Phytotherapy Research*. 2002; 16(7): 603–615.
8. Connors TA. Steering committee on identification of toxic and potentially toxic chemicals for consideration by the national toxicology program toxicity testing—strategies to determine needs and priorities. *National Academy Press, Washington*, 1984:382.
9. Ye X, Liu J. Effects of pyrethroid insecticides on hypothalamic-pituitary-gonadal axis: a reproductive health perspective. *Environmental Pollution*. 2019; 245: 590-599.
10. Saillenfait AM, Ndiaye D, Sabaté JP. Pyrethroids: exposure and health effects—an update. *International Journal of Hygiene and Environmental Health*. 2015; 218(3): 281-292.
11. Liu Y, Wang YL, Chen MH, Zhang Z, Xu BH, Liu R, Xu L, He SW, Li FP, Qi ZQ. Methoxychlor exposure induces oxidative stress and affects mouse oocyte meiotic maturation. *Molecular Reproduction and Development*. 2016; 83: 768–779.
13. Mandal J, Parija SC. Ethics of involving animals in research. *Trop Parasitol*. 2013; 3(1): 4-6. doi: 10.4103/2229-5070.113884. PMID: 23961435; PMCID: PMC3745669.
14. Nicolopoulou-Stamati P, Pitsos MA. The impact of endocrine disrupters on the female reproductive system. *Human Reproduction Update*. 2001; 7: 323-330.
15. Khaki A, Fathiazad F, Nouri M, Khaki AA, Khamenehi HJ, Hamadeh M. (2009). Evaluation of androgenic activity of *Allium cepa* on spermatogenesis in the rat. *Folia Morphologica*. 2009; 68(1): 45-51.
16. Zhao XX, Lin FJ, Li H, Li HB, Wu DT, Geng F, Ma W, Wang Y, Miao BH, Gan RY. Recent Advances in Bioactive Compounds, Health Functions, and Safety Concerns of Onion (*Allium cepa* L.). *Frontiers in Nutrition*. 2021; 8: 669805. doi: 10.3389/fnut.2021.669805. PMID: 34368207; PMCID: PMC8339303.
17. Narges M, Vahideh G, Farzaneh S, Marzie B, Farzaneh K, Ramin R, Mohammad HB. (2021) A review of anti-inflammatory, antioxidant, and immunomodulatory effects of *Allium cepa* and its main constituents, *Pharmaceutical Biology*. 2021; 59(1): 285-300, DOI: [10.1080/13880209.2021.1874028](https://doi.org/10.1080/13880209.2021.1874028)
18. Neda M, Mehrdad M. (2020). The Effect of Red Onion Extract on Reproductive Hormones in Female Mice. *The Pharmaceutical and Chemical Journal*. 2020; 7(2): 132-137.
19. Marettova E, Marett M, Legáth J. Effect of pyrethroids on the female genital system. *Animal Reproduction Science*. 2017; 184: 132-138.
20. Jeje SO, Akpan EE, Kunle-Alabi OT, Akindele OO, Raji Y. (2021). Protective role of *Allium cepa* Linn (onion) juice on maternal dexamethasone-induced alterations in reproductive functions of female offspring of Wistar rats. *Current Research in Physiology*. 2021; 4: 145-154.
21. Khaki A, Khaki AA, Hajhosseini L, Golzar FS, Ainehchi N. The anti-oxidant effects of ginger and cinnamon on spermatogenesis dysfunction of diabetes rats. *African Journal of Traditional, Complementary, and Alternative Medicines*. 2017; 14: 214-223.
22. Patel S, Zhou C, Rattan S, Flaws JA. Effects of Endocrine-Disrupting Chemicals on the Ovary. *Biol Reprod*. 2015; 93(1): 20. doi: 10.1095/biolreprod.115.130336. Epub 2015 Jun 10. PMID: 26063868; PMCID: PMC6366440.

23. Tian Qj, Zhao Xy, Wang Y. Histologic pattern is better correlated with clinical outcomes than biochemical classification in patients with drug-induced liver injury. *Mod Pathol*.2019;32: 1795–1805. <https://doi.org/10.1038/s41379-019-0314-9>
24. Gavrielides MA, Ronnett BM, Vang R, Sheikhzadeh F, Seidman JD. Selection of Representative Histologic Slides in Interobserver Reproducibility Studies: Insights from Expert Review for Ovarian Carcinoma Subtype Classification. *J Pathol Inform*. 2021; 12: 15. doi: 10.4103/jpi.jpi_56_20. PMID: 34012719; PMCID: PMC8112350.
25. Patrick L, George L, Natalie NC, Shih RE, Michael D, Anant M. Evaluating stability of histomorphometric features across scanner and staining variations: prostate cancer diagnosis from whole slide images. *Journal of Medical Imaging*. 2016; 3(4): 047502. doi: 10.1117/1.JMI.3.4.047502.
26. Ugljesa D, Gelareh, Z, Kenneth, A, Phedias D. Precision histology: How deep learning is poised to revitalize histomorphology for personalized cancer care. *Lancet*. 2017; 3(2): 1691-1698

UNDER PEER REVIEW