

A Complex Case of Coronary Artery Disease and the Rare Behçet's Disease: When the Eye Saves the Heart

ABSTRACT

Coronary artery disease (CAD) is a common medical condition that is associated with significant morbidity and mortality, especially in individuals with multiple cardiovascular risk factors. This case report focuses on a 61-year-old man with established coronary artery disease, a history of NSTEMI, and subsequent revascularization. The unique clinical course reveals a complex interplay between cardiovascular and ocular manifestations, revealing an unrecognized Behçet's disease.

Keywords: [Coronary artery disease - Behçet's disease - Uveitis]

1. INTRODUCTION

Behçet's disease is a multisystem inflammatory vasculitis of unknown aetiology, probably multifactorial. It is characterized by recurrent acute inflammatory attacks. Diagnosis is based on a clinical score according to the international criteria for MB, including oral and genital aphthosis, neurologic, ophthalmologic, and vascular involvement. Cardiac involvement during the course of Behçet's disease is a rare complication (1 to 6%), which can sometimes be inaugural (33%), it can involve the three tunics and of variable expression, it can occur in the form of intracardiac thrombus, endocarditis, myocarditis, pericarditis, coronary arteritis, valvular disease or myocardial infarction. Myocardial infarction is considered rare, if not exceptional. It has a poor prognosis. It can be life-threatening, with an estimated mortality of 20%, mainly due to cardiovascular complications.

2. CASE PRESENTATION

We report the case of a 61-year-old man with no cardiovascular risk factors other than his age and male sex.

The patient had a history of non-ST-elevation acute coronary syndrome (NSTEMI) 15 days ago, with coronary angiography showing a significant lesion of the middle IVA, which was revascularized with placement of an active stent and a tight circumflex stenosis, for which he was referred for additional angioplasty.

In the meantime, the patient presented to the emergency department with typical chest pain similar to angina pectoris. The electrocardiogram (ECG) showed an electrical LVH (with no changes compared to the initial ECG 2 weeks before). (**Figure 1**).

Biologic work-up revealed elevated troponin U to 11,068 ng/L (upper limit of normal 15 ng/L). Cardiovascular risk factors were assessed. Triglycerides were 2.7 g/L, HDL 0.40 g/L, LDL 0.90 g/L, and HbA1c 5.9%.

Echocardiography showed hypokinesia of the IL and AL walls with a preserved LVEF of 55% with no valvular regurgitation and good LV function, and no pericardial effusion or signs of pulmonary hypertension.

Medical management for high-risk NSTEMI included dual antiplatelet therapy (clopidogrel and acetylsalicylic acid), statins, beta-blockers, ACE inhibitors, and enoxaparin. In addition, coronary angiography performed within 24 hours revealed a recent occlusion of the middle AVI at the site of the active stent implantation with successful recanalization of this artery (**Figure 2**). A tight stenosis of the circumflex artery was also observed (**Figure 3**).

During hospitalization, the patient presented with decreased visual acuity associated with anterior and posterior uveitis. Ocular ultrasound revealed a retinal detachment with papillary attachment in the left eye (**Figure 4,5**).

Given the clinical picture and the discovery of uveitis, a work-up for Behçet's disease was requested, which was positive, demonstrating the association between coronary artery disease and Behçet's disease according to the international criteria for the diagnosis of MB.

The patient received conventional treatment for his ischemic heart disease with stenting, oral BASIC therapy (beta-blockers, antiplatelet agents, statins and converting enzyme inhibitors, and anticoagulation), combined with treatment for Behçet's disease consisting of corticosteroid therapy (methylprednisolone) infused at a dose of 1 g/d for 3 days. An azathioprine-based immunosuppressant at a dose of 150 mg/d was also administered.

Progression was good with stability of the vasculitis. The patient remained asymptomatic regarding cardiac function after treatment. As a first attack of Behçet's disease, we maintained the diagnosis of coronary artery disease associated with Behçet's disease

DISCUSSION

Identifying Behçet's disease associated with coronary artery disease presents a rare and challenging clinical scenario. The limited existing literature underscores the need for increased awareness among clinicians to recognize atypical presentations and facilitate early diagnosis and management.

Cardiac involvement in Behçet's disease is one of the rarest, accounting for about 6% of cases in various series; it can affect all three tunics, dominated by pericarditis, and rarely myocardial infarction, the latter being a rare and fatal complication of Behçet's disease [1]. On average, about thirty cases are reported in the literature [2].

Pathophysiologically, Behçet's disease differs from other vasculitides in that arteries and veins of different calibers are involved. Arteries are affected by perivascular pathways accompanied by an endovascular inflammatory process. This leads to stenosis, thrombotic occlusion, hemorrhage, and aneurysms. Cardiac damage is mainly manifested by coronary arteritis, myocardial infarction and aortic insufficiency. [3] On the other hand, fibrous intimal thickening can cause acute myocardial infarction despite angiographically normal coronary arteries. And some data in the literature suggest that such alterations in microvascular function are responsible for coronary events in these patients. [4]

Atherosclerosis is the major cause of myocardial infarction. However, Behçet's disease remains one of the etiologies classified as a non-atheromatous cause [5].

In our patient, the possible role of Behçet's disease in the genesis of the coronary lesions responsible for ischemia is suggested by the absence of atheromatous lesions, both coronary and extracoronary. The therapeutic management of coronary artery lesions remains uniquely problematic. It presents the clinician with a dual challenge with two essential facets that are inseparable and complementary: To ensure adequate and rapid protection and aggressive treatment in the acute phase of the coronary syndrome, and to propose a fundamental pathophysiological approach to the treatment of the disease in question, the only guarantee of effective prevention of recurrence. [6]

In practice, the EULAR 2018 recommendations have clearly established the systematic need for the first-line use of immunosuppressive agents in combination with glucocorticoids in severe arterial disease secondary to Behçet's disease in order to limit the progression of coronary inflammatory involvement. This should be combined with dual antiplatelet therapy based on acetylsalicylic acid and clopidogrel, which should be maintained as long as possible in coronary patients [7-8].

Regarding prognosis, arterial and cardiac damage are undeniably poor prognostic factors associated with an increased risk of mortality [9].

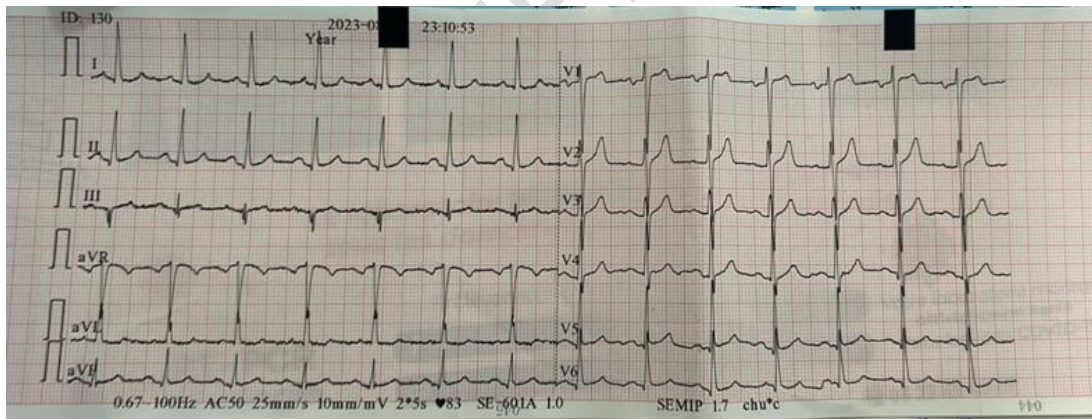


Fig. 1. Electrical appearance of LVH with secondary repolarization disorders and lateral ST segment steepening

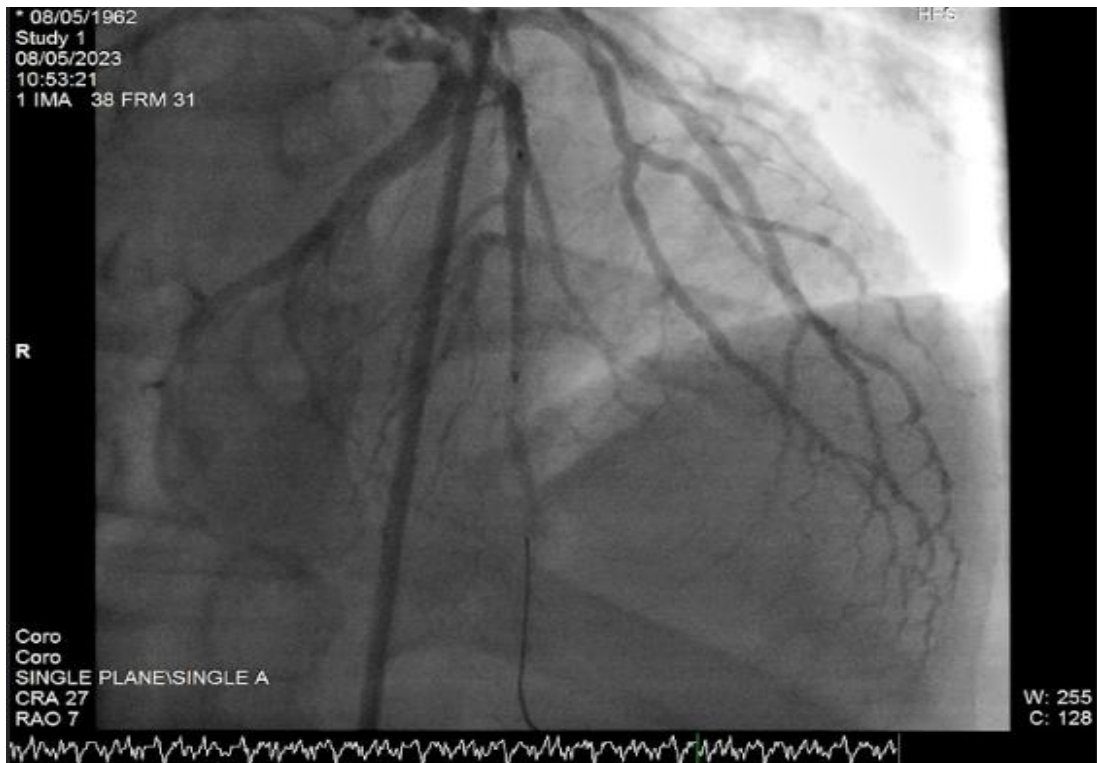

Fig.2. Pre-dilation with a balloon at the level of the middle IVA at the site of stent implantation

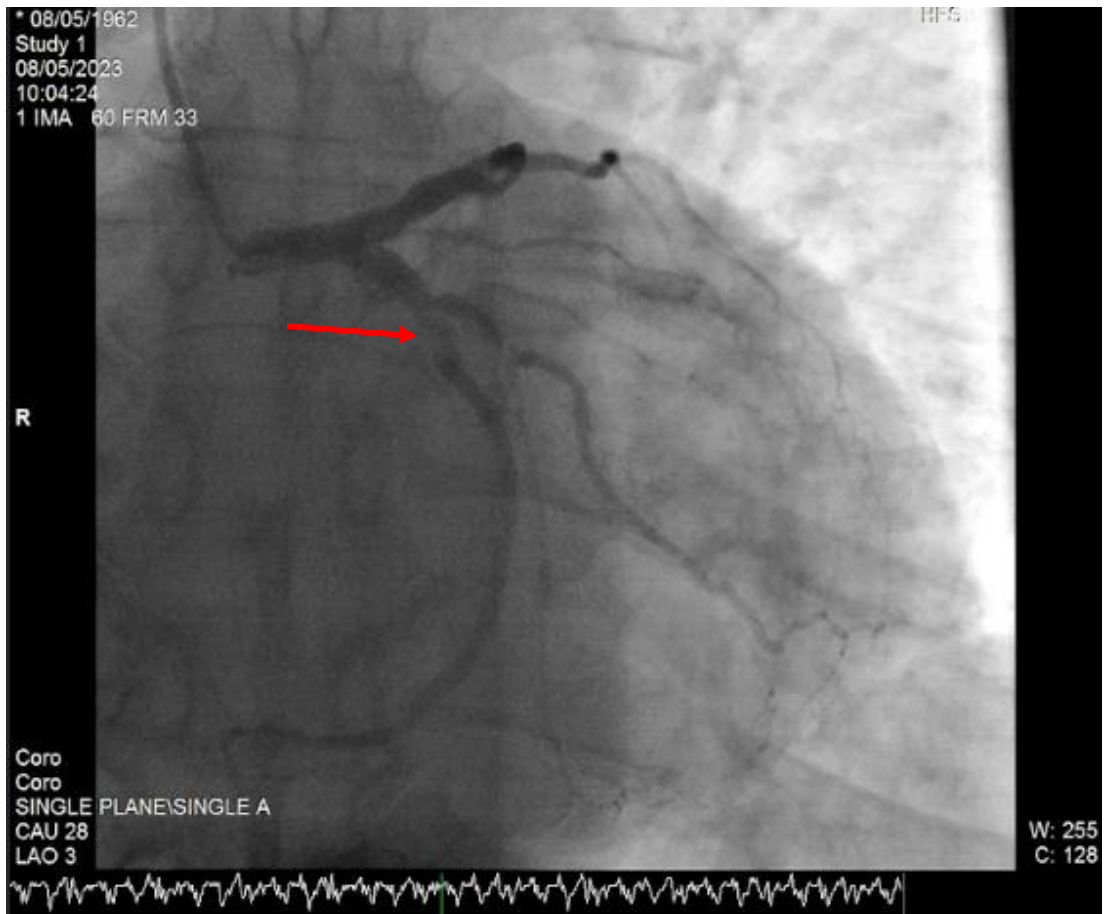


Fig.3. Bifurcation lesion with tight stenosis of proximal circumflex and ostium of first marginalis

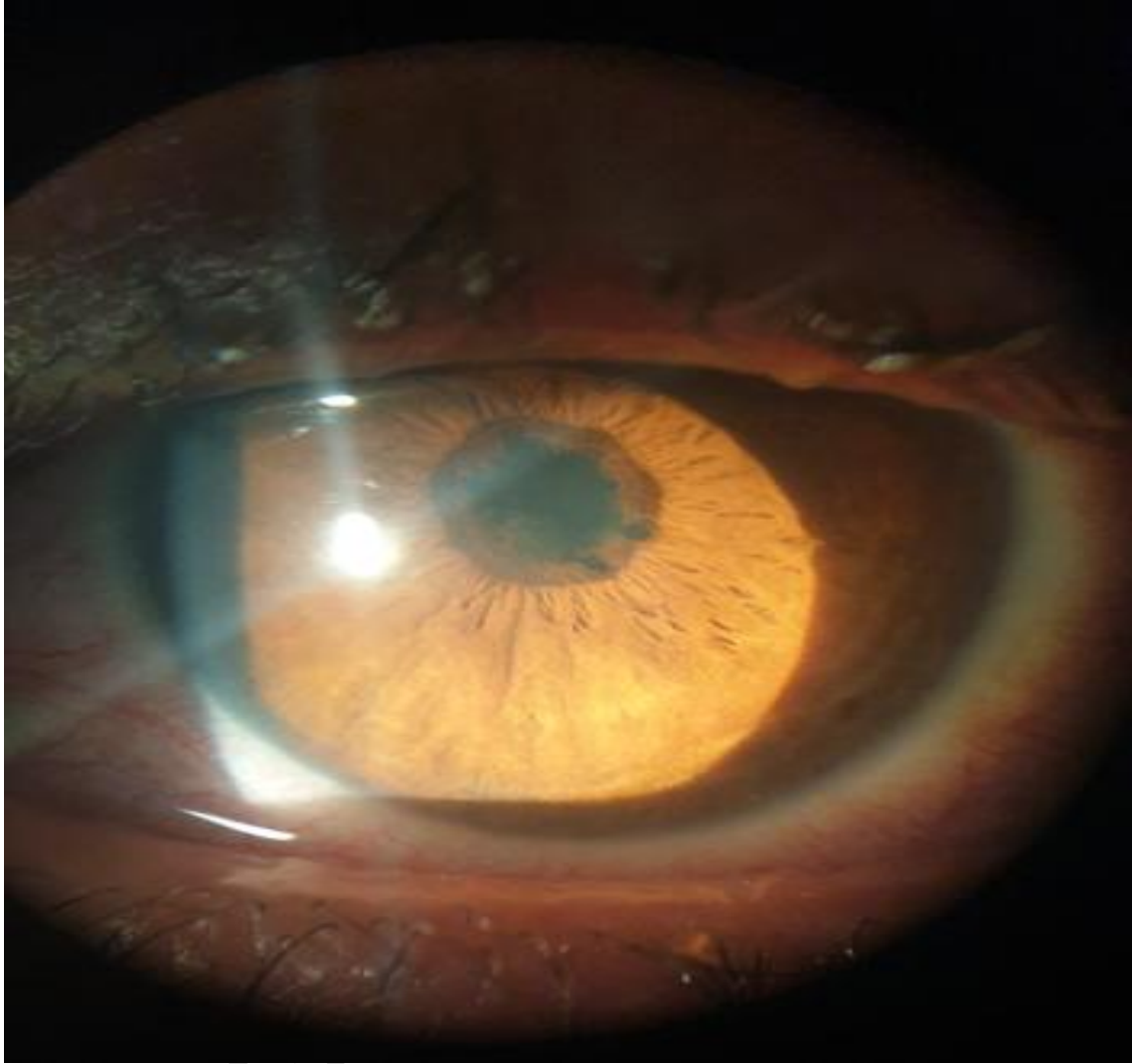


Fig.4. Iridocrystalline synechiae secondary to anterior uveitis.

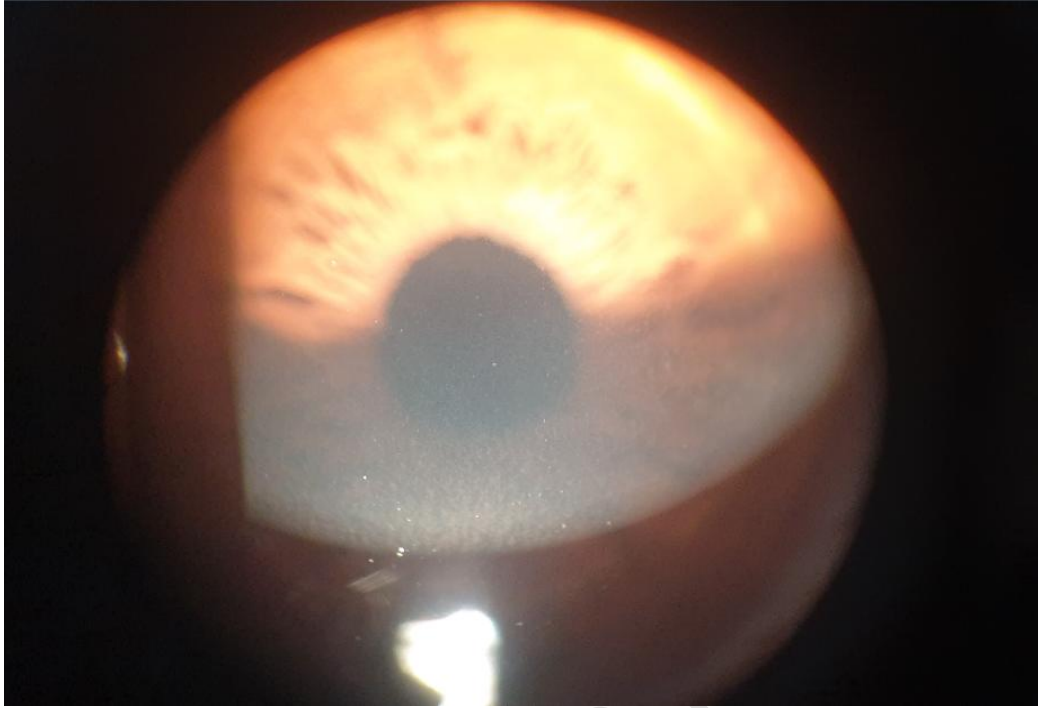


Fig. 5. This image shows an active anterior uveitis with the presence of Tyndall's in the anterior chamber

4. CONCLUSION

In this complex clinical case, the novel association between coronary artery disease and Behçet's disease was revealed, underscoring the importance of clinicians' heightened awareness of atypical presentations. The rarity of this association requires multidisciplinary management and poses therapeutic challenges, highlighting the importance of a personalized approach. This case encourages a continued search for an underlying etiology of coronary involvement, especially in the absence of risk factors, to improve understanding of mechanisms and guide more effective treatment strategies.

REFERENCES

1. AC Desbois, B Wechsler, P Cluzel. (2014) Cardiovasculareffects of Behçet'sdisease. 12:2.
2. Sarica, et al. (2006) Vascular involvement in Behçet's disease: a retrospective analysis of 2319 cases. *Int J Dermatol.* 45(8): 919-921.
3. Unsal Vural, Mehmet Kizilay, and Ahmet Arif Aglar. (2019) Coronary Involvement in Behçet's Disease: what are its Risks and Prognosis? (*Rare Cases and LiteratureReview*). 34(6): 749-758.
4. Chen H, Zhang Y, Li C, Wu W, Liu J, et al. (2019) Coronary involvement in patients with Behçet's disease. *Clin Rheumatol.* 38(10): 2835-2841.

5. FA Benaich, A Ben, El Mekki, H Benjelloun, Z Lakhal. (2015) Infarctus Du Myocarde Revelant La Maladie De Behçet. A Propos D'un Cas, Journal Marocain des Sciences Médicales Tome XX) N.
6. Hatemi G, Christensen R, Bang D, Bodaghi B, Celik AF, et al. (2018) update of the EULAR recommendations for the management of Behçet's syndrome. *Ann Rheum Dis.* 77(6): 808-818.
7. SelamiDemirelli. (2015) HusnuDegirmenci Sinan Inci and Arif Arisoy:Cardiac manifestations in Behcet'sdisease. 4(2): 70-75.
8. F Othmani. (2009) Behçet's disease: new therapeutics. *The journal of internal medicine.* 30: 243-252.
9. Saadoun D, Wechsler B, Desseaux K, Le Thi Huong D, Amoura Z, et al. (2010) Mortality in Behcet'sdisease. *ArthritisRheum.* 62: 2806-2812.

ABBREVIATIONS

CAD: Coronary artery disease

NSTEMI: non-ST-elevation acute coronary syndrome

ECG: electrocardiogram

LVH: left ventricular hypertrophy

IVA :intraventricular artery