

# PHYLLODESTUMOR OF THE BREAST: A CASE SERIES

## ABSTRACT

**Background:** Phyllodes tumor is a rare fibroepithelial tumor of the breast comprising less than 1% of all breast tumors. Most of these tumors are benign but some have malignant potential. The aim of the study was to evaluate the clinical characteristics, treatment and post operative complications in patients with phyllodes tumor.

**Methods:** This retrospective study was conducted in a tertiary care centre (Assam Medical College and Hospital, Dibrugarh, Assam) for a duration of 1 year from May 2022 to April 2023. A total of 12 histologically confirmed cases of phyllodes tumor were included in the study from hospital records of the institution.

**Result:** The median age of diagnosis at the time of admission was 36 years with a range from 13 to 49 years. 11 out of 12 cases were benign, whereas 1 was found to be of borderline malignancy. All patients underwent operative interventions - excision of the tumor in 8 patients, simple mastectomy in 3 patients and MRM in one patient. No postoperative complications or recurrence were observed during the period of follow-up.

**Conclusion:** Local excision of the tumor is adequate in all the benign phyllodes tumors, whereas borderline phyllodes and malignant tumors were best treated by simple mastectomy.

*Keywords: Phyllodes, Mastectomy, Breast*

## 1. INTRODUCTION

Phyllodes tumor is a rare tumor of the breast in comparison to other histologic subtypes, however itself is not a rare tumor, accounting for <1% of all breast malignancies<sup>(1,2)</sup>, and has an incidence of about 2.1 per million. Most of these tumors are benign, but some have a malignant potential. These tumors commonly occur in females during the 4th or 5th decade of life. They can grow rapidly and the associated symptoms can mimic other types of breast carcinoma, particularly if the mass ulcerates and bleeds. Phyllodes tumor usually compresses the surrounding tissue from which it is usually well demarcated. The bulk of this tumor is connective tissue with mixed gelatinous cystic and solid areas<sup>(3)</sup>, the number of mitoses may help in the diagnosis of the malignant subtype<sup>(4-6)</sup>. The only treatment option for these tumors is surgical removal<sup>(3)</sup>. Phyllodes tumors often present a diagnostic and treatment dilemma. The phyllodes tumors are classified into benign, borderline, and malignant categories based on the degree of stromal cellular atypia, mitotic activity, degree of stromal overgrowth, tumor necrosis, and margin appearance. Borderline tumors have the greatest tendency for local recurrence<sup>(6,7)</sup>. All forms of phyllodes tumors have malignant potential<sup>(5)</sup>. A five-year survival rate was observed in almost 100% of patients with benign tumors, 98% with borderline, and about 88% with malignant<sup>(8)</sup>. Depending on malignant potential, bulky tumor, recurrence, and status of resection margins, the treatment may vary between wide local excision with 1cm breast tissue or radiotherapy<sup>(10)</sup>. Revision surgery may be required for a high percentage of tumors with inadequate margin removal, and radiotherapy after breast surgery may significantly reduce the local recurrence rate for borderline and malignant tumors.<sup>(9,11)</sup>

## 2. METHODS

A total of 12 cases were evaluated retrospectively from hospital register of Assam Medical College & Hospital, Dibrugarh, Assam who were clinico-pathologically diagnosed as phyllodes tumors. The duration of study was 1 year, from May 2022 to April 2023. One of the 12 cases had axillary lymphadenopathy whereas others presented with breast lump only. Ultrasonography and chest x-ray radiography were performed in all the cases prior to surgery. Abdominal computed tomography (CT) scan was performed post-operatively for the borderline lesion to rule out any metastatic disease. Appropriate surgical plans were formulated depending on the findings. Treatment modalities were excision of the tumor, simple mastectomy and modified radical mastectomy (MRM) on the basis of tumor size and lymphadenopathy. No postoperative complications or recurrences were observed in the follow-up notes of the patients.

## 3. RESULTS

Sl.	Age	Clinical	Side	HPE No.	Size (in cm <sup>3</sup> )	Operative	Anaesthesia	Histopatho	complication
-----	-----	----------	------	---------	----------------------------	-----------	-------------	------------	--------------

No.	(in years)	presentation				procedure		logical inference	
1.	31	Lump with axillary lymphadenopathy	Left	2441/22	14x13x10	MRM	GA	Benign	None
2.	18	Lump	Left	2762/22	5x4x3	Excision	GA	Benign	None
3.	35	Lump	Right	3604/22	15x14.5x11	Excision	GA	Benign	None
4.	45	Rapidly progressing lump	Right	4363/22	12x11x8	Simple mastectomy	GA	Benign	None
5.	23	Lump	Bilateral	747/23	L=2x1.5x1.5 R=2.5x2x2	Excision	GA	Benign	None
6.	49	Lump	Right	1895/23	9x7.5x4	Excision	GA	Benign	None
7.	16	Lump	Right	2341/23	6x4x3	Excision	GA	Benign	None
8.	13	Lump with Pain	Left	2371/23	13x12x6	Simple Mastectomy	GA	Borderline	None
9.	39	Lump	Right	2495/23	6x4x4	Excision	GA	Benign	None
10.	37	Lump	Left	2511/23	10x10x8	Excision	GA	Benign	None
11.	28	Rapidly progressing lump	Left	3151/23	16x16x8	Simple mastectomy	GA	Benign	None
12.	31	Lump	Left	3702/23	3x1.5x1.5	Excision	GA	Benign	None

Table 1 shows the number of cases with phyllodes tumor

**TABLE 1**

Table 2 shows the common presenting complaints with which patient presented to our patient department (OPD).

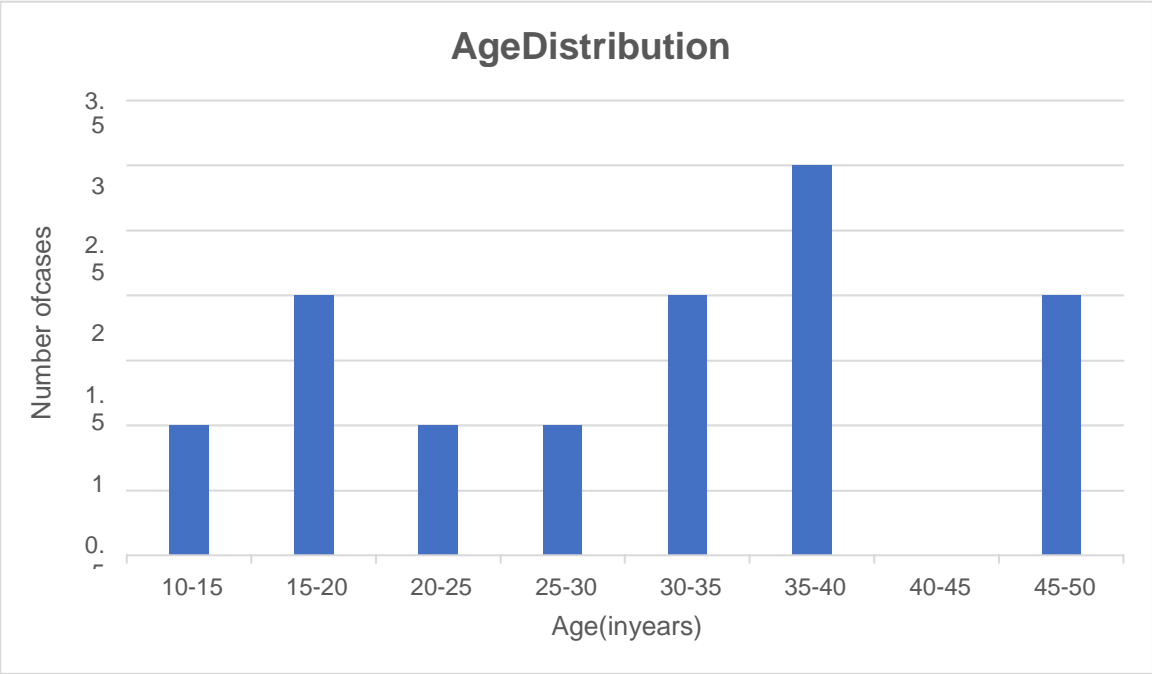
**TABLE 2**

Sl.No.	Presenting symptom	Number of cases	Percentage
1.	Slowly progressing swelling	9	75%
2.	Rapidly progressing swelling	2	17%
3.	Pain	1	8%
4.	Skin changes	0	0

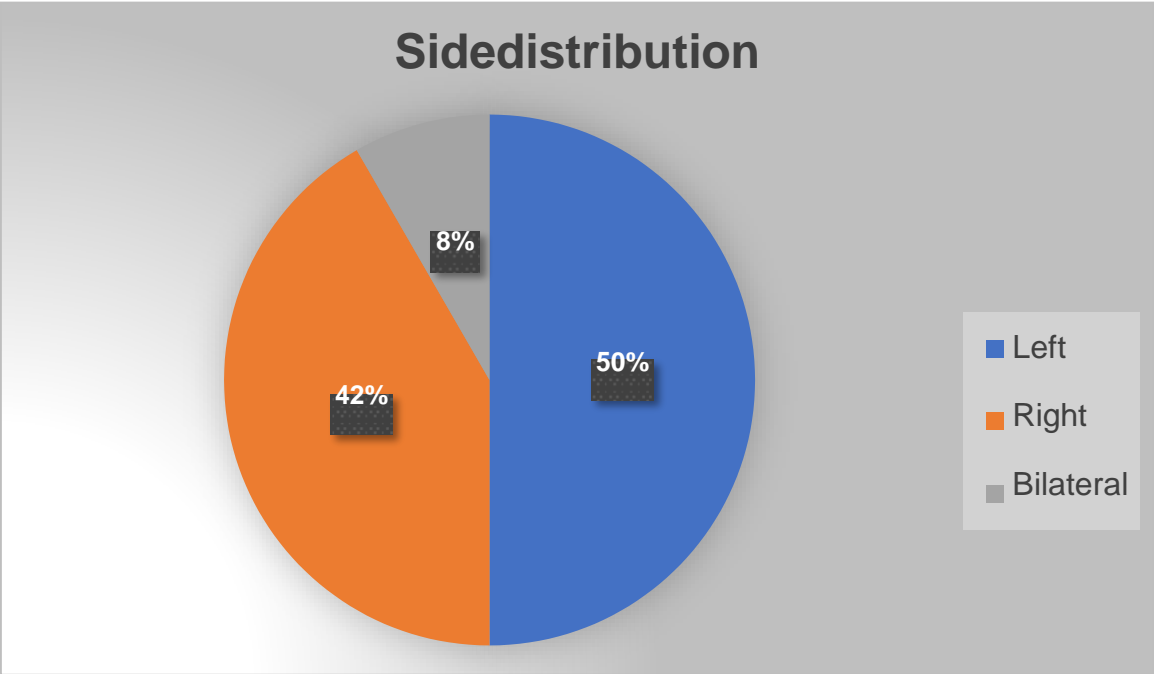
The median age at diagnosis was 36 years (range 13-49 years). 11 (92%) out of 12 tumors were benign and 1 (8%) was borderline. In 6 (50%) of the cases, the tumor was on the left side, 5 (42%) on the right side and 1 (8%) was bilateral. All the cases the patient presented with a breast lump of which only 1 (8%) presented with pain over the lump. Rapid growth of the breast lump was noted in 2 (17%) of the cases. Excision of the breast lump was the treatment of choice in 8 (67%) of the cases where as simple mastectomy was performed in 3 (25%) of the cases presenting with rapid

growth of the breast lump. In 1 (8%) case modified radical mastectomy (MRM) was performed. All interventions (100%) were done under general anesthesia. No post-operative complications were documented in the records.

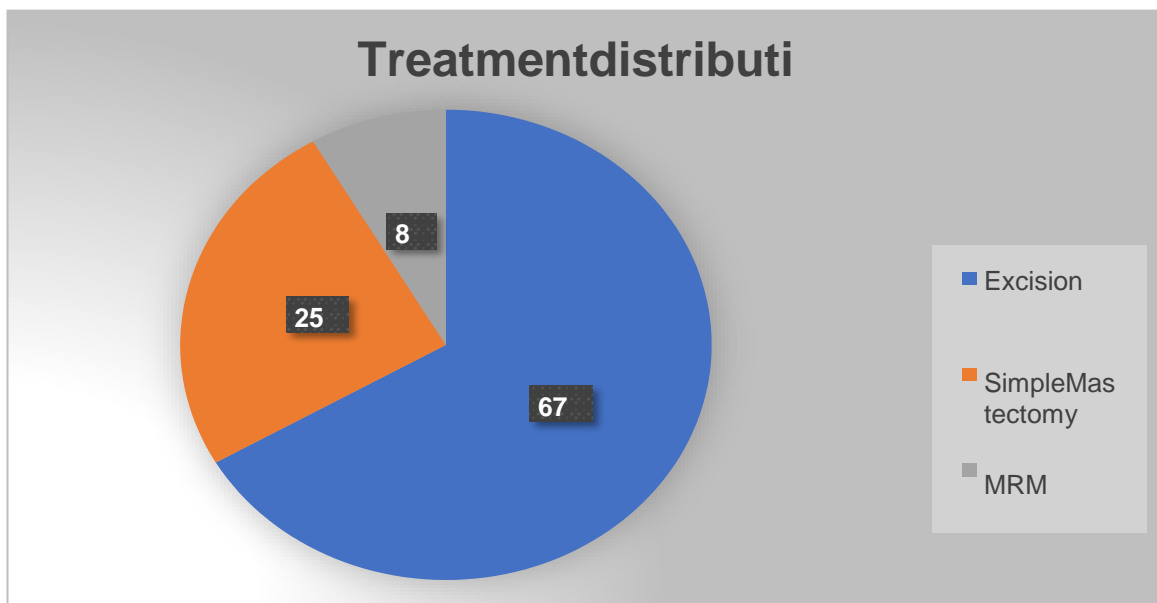
**FIGURE 1**



**FIGURE 2**



**FIGURE3**



#### 4. DISCUSSION

Phyllodes tumors are rare, representing only 0.3% to 0.9% of all breast tumors<sup>(12,13)</sup>. Phyllodes tumors occur at any age, from 10 to 90 years<sup>(13,14,15)</sup>, with a peak incidence between 30 and 40 years (a decade later than the average presentation of fibroadenoma). In our study also the peak incidence was found to be between 30 to 40 years of age which is similar to most of the studies given in the reference. It is common for a "fibroadenoma" to be reclassified as a phyllodes tumor after excision of the mass. In the study by Hassouna et al<sup>(46)</sup>, 106 patients with phyllodes tumor were reviewed, retrospectively of which 37% of the patients with phyllodes tumor had the history of fibroadenoma<sup>(47)</sup>. In our study out of 12 cases, 8 (67%) were preoperatively diagnosed as fibroadenoma and only 4 (33%) cases were labelled as phyllodes tumor which includes the borderline phyllodes and axillary lymphadenopathy case.

The diagnosis of phyllodes tumor is difficult as phyllodes tumor often mimics fibroadenoma at mammography<sup>(48,49)</sup>. In our study a majority of the cases were diagnosed post-operatively on histopathological examination.

In the literature, the tumor size varies between 5 and 270 mm, with a mean size between 50 and 72 mm<sup>(14,19-21)</sup>. Tumors with a size reaching up to 450 mm have been described by Rajan PB et al and Matar N et al<sup>(17,22)</sup>. In our study also the tumor size varied within this range (15 and 160 mm).

In a study conducted by Badar E et al, Ball AB et al and Vorherr H et al on phyllodes tumors, they reported that 96% of the patients had a unilateral presentation with very few cases of bilaterality<sup>(23-25)</sup>. A few cases of phyllodes tumor arising within ectopic mammary tissue have been reported in the axilla and vulva<sup>(26-28)</sup>. In our study, only 1 case of bilateral phyllodes tumor was found.

In 1996, Liberman et al<sup>(29)</sup> concluded in their study of 51 phyllodes tumors, that a tumor with a mammographic diameter of 30 mm or greater appears to be associated with a higher likelihood of malignancy. On the other hand, Jorge Blanco et al<sup>(30)</sup> found in their series of 154 cases that the mean size on mammography was 41 mm and 90 mm in malignant and benign phyllodes tumor, respectively.

Surgery is the mainstay of treatment for phyllodes tumors, but the extent of surgery remains controversial, particularly for borderline and malignant phyllodes tumor. Regardless of their histology, all phyllodes tumors recur, although the risk of local recurrence is low in benign forms, ranging from 4.7% to 30%, and notably higher in borderline and malignant forms (30%–65%)<sup>(31,32)</sup>. In the literature, most authors agree that the correct procedure for benign phyllodes tumor is a wide local excision allowing a 1 to 2 cm margin in all directions<sup>(32,33)</sup>. On the contrary, Zurrida et al<sup>(34)</sup>, in their largest series, concluded that when benign phyllodes tumor is encountered unexpectedly, a wait-and-see policy is justified because of the low local recurrence rate of benign phyllodes tumor and the rarity of preoperative diagnosis<sup>(35,36)</sup>. In the past, the treatment of choice for borderline and malignant phyllodes tumor was simple mastectomy or radical mastectomy. Currently, most authors favor conservative surgery because local recurrences do not appear to be related to the systemic spread of the disease<sup>(37)</sup>. Conversely, Barth RJ Jr.<sup>(32)</sup> in a large review of the literature found that the recurrence rate was as high as 46% and 65% after local excision for borderline and malignant phyllodes tumor, and these rates remained high even after wide local excision (29% and 36%). In contrast, Asoglu O et al<sup>(38)</sup> found no significant difference in terms of local control when wide local excision or mastectomy was performed for benign and malignant forms.

Many authors consider that axillary lymph node dissection is not useful, whereas others prefer to use it only in cases of clinically suspect adenopathy or invasive carcinoma within phyllodes tumor. Matar N et al<sup>(18)</sup> in 1995 observed 3 cases of lymph node involvement among 9 lymph node clearances, whereas Kapiris I et al<sup>(39)</sup> in 2001 showed no lymph node invasion among 21 patients with malignant phyllodes tumor undergoing lymph node dissection. According to Rowell MD et al, Cohn-Cedermark G et al and Norris HJ et al<sup>(13,40,41)</sup>, of 10% to 15% of patients presenting with clinical axillary adenopathy, less than 1% had pathological nodes. In our series, 1 case had breast mass with axillary lymphadenopathy, for which she was operated by modified radical mastectomy. However, the histopathological examination showed phyllodes tumor with reactionary lymphadenitis of the axillary lymph nodes.

The frequency of local recurrences varies between 0% and 60% according to various series in the literature<sup>(21,33,37,38,42,43)</sup>. According to some authors, malignant phyllodes tumor recur in 24% to 58% of cases, whereas benign phyllodes tumor recur only in 4.3% to 27% of cases<sup>(14,20,33,38)</sup>. Other factors are identified to be risk factors for local recurrences such as surgical margins, nuclear atypia, and stromal overgrowth<sup>(33,37)</sup>. Recurrence histotypes are generally identical to the primary tumor. However, sarcomatous transformation can occur during recurrence after resection of benign or borderline phyllodes tumor<sup>(44)</sup>. Reinfuss M et al<sup>(33)</sup> explains this transformation by the existence of malignant foci that might have been missed on pathologic examination.

53 The distant metastases rate varies considerably, from 6.6% to 70%, and most of them occur in lung (84.5%) and bone (39%)<sup>(33,39)</sup>.  
54 Moffat CJ et al<sup>(37)</sup> report that patients with local recurrence do not develop distant metastases. On the contrary, Kapisirli  
55 et al<sup>(39)</sup>, Hajdu SI et al<sup>(44)</sup>, and West TL et al<sup>(45)</sup> showed that among patients having metastases, 60% to 85% had already developed local recurrences.

57 The 5-year disease-free and overall survival varies, according to other series, ranging from 60% to 92%<sup>(32,39)</sup>.

58 In our series, no proper inference can be drawn due to short follow-up period of the cases. However we have also not detected  
59 any recurrences during our period of study.

## 60 5. CONCLUSION

61 Phyllodes tumor represents a heterogeneous group of tumors sharing the same macroscopic features with that of a  
62 fibroadenoma. The data concerning the prognostic factors of phyllodes tumor are conflicting, and further studies are  
63 warranted. Surgery remains the cornerstone of treatment. All histologically confirmed phyllodes tumor need proper follow up  
64 for early detection and proper management of recurrence.

## 66 6. LIMITATIONS OF THE STUDY

67 The main limitation of this study are inclusion of small number of cases and short duration of follow up.

## 69 7. ETHICAL CLEARANCE

70 Taken from institutional ethics committee.

## 71 8. CONFLICT OF INTEREST

72 None

## 73 9. REFERENCES

- 75 1. Yohe S, Yeh IT. "Missed" diagnosis of Phyllodes tumor on breast biopsy: pathological clues to its  
76 recognition. *Int J Surg Pathol* 2008;16(2):137–42. doi:10.1177/1066896907311378.
- 77 2. Farias-Eisner GT, Small K, Swistel A, Ozerdem U, Talmor M. Immediate Implant  
78 Breast Reconstruction with Acellular Dermal Matrix for Treatment of a Large Recurrent  
79 Malignant Phyllodes Tumor. *Aesthetic Plast Surg*. 2014;38(2):373–8. doi: 10.1007/s00266-  
80 014-0283-9.
- 81 3. Lannin DR, Geibel J. *Cystosarcoma Phyllodes*'s. 2014.
- 82 4. Kumar T, Patel MD, Bhargavan R, Kumar P, Patel MH, Kothari K, et al. Largest Phyllodes  
83 Tumor-Case Report and Brief Review Article. *Indian J Surg Oncol*. 2011;2(2):141–4. doi:  
84 10.1007/s13193-011-0077-3.
- 85 5. Moffat CJ, Pinder SE, Dixon AR, Elston CW, Blamey RW, Ellis IO. Phyllodes tumour of the breast: a cl  
86 inic pathological review of the thirty-two cases. *Histopathology*. 1995;27(3):205–18.  
87 doi:10.1111/j.1365-2559.1995.tb00212.x
- 88 6. Rowell MD, Perry RR, Jeng-Gwang H, Barranco SC. Phyllodes tumors. *Am J Surg*.  
89 1993;165:376–9. doi: 10.1016/S0002-9610(05)80849-9.
- 90 7. Khan SA, Badve S. Phyllodes tumors of breast. *Curr Treat Options Oncol*. 2001;2:139–  
91 47. doi: 10.1007/s11864-001-0056-y.
- 92 8. Ye John Shangming Seven Lakes High School, Katy, TX. Statistical analysis on the behavior and re  
93 currence of breast phyllodes tumors. *J Clin Oncol*. 2016;34(suppl3).
- 94
- 95 9. Tan PH1, Thike AA, Tan WJ, Thu MM, Busmanis I, Li H, et al. Predicting clinical behaviour  
96 of breast phyllodes tumours: an omogram based on histological criteria and surgical margins. *J Clin  
97 Path*. 2012;65(1):69–76. doi:10.1136/jclinpath-2011-200368.
- 98 10. Liang MI, Ramaswamy B, Patterson CC, McKelvey MT, Cordillo G, Nuovo GJ, et al. Giant  
99 breast tumors: surgical management of phyllodes tumors, potential for reconstructive surgery and r  
100 eview of literature. *World J Surg Oncol*. 2008;6:117. doi:10.1186/1477-7819-6-117.

- 101 11. Barth RJ, Jr, Wells WA, Mitchell SE, Cole BF. A prospective, multi-institutional study of  
102 adjuvant radiotherapy after resection of malignant phyllodes tumors. *Ann Surg Oncol*.  
103 2009;16(8):2288–94. doi: 10.1245/s10434-009-0489-2.
- 104 12. Azzopardi JG. *Sarcoma of the Breast*. Philadelphia: WBSaunders Co; 1979:355–9.
- 105 13. Rowell MD, Perry RR, Hsiu JG, Barranco SC. Phyllodes tumors. *Am J Surg* 1993;165:376–9.
- 106 14. Tan PH, Jayabaskar R, Chuah KL, et al. Phyllodes tumor of the breast: the role of pathologic param-  
107 eters. *Am J Clin Pathol* 2005;123: 1–12.
- 108 15. Eroglu E, Irkkan C, Ozsoy M, Eroglu F. Phyllodes tumor of the breast: case series of 40 patients. *Eur J*  
109 *Gynaecol Oncol* 2004;25:123–5.
- 110 16. Pandey M, Mathew A, Kattoor J, et al. Malignant phyllodes tumor. *Breast J* 2001;7:411–6.
- 111 17. Rajan PB, Cranor ML, Rosen PP. Cystosarcoma phyllodes in adolescent girls and young women: a  
112 study of 45 patients. *Am J Surg Pathol* 1998;22:64–9.
- 113 18. Matar N, Soumani A, Noun M, et al. [Phyllodes tumor of the breast. Forty-one cases.] *J Gynecol Obst*  
114 *et Biol Reprod (Paris)* 1997;26: 32–6.
- 115 19. Isotalo PA, George RL, Walker R, Sengupta SK. Malignant phyllodes tumor with liposarcomatous d-  
116 ifferentiation. *Arch Pathol Lab Med* 2005;129:421–2.
- 117 20. Hernanz F, Alvarez A, Ortega E, Garijo F. Malignant cystosarcoma phyllodes of the breast treated wi-  
118 thoncoplastic conservative surgery. *Breast J* 2005;11:146.
- 119 21. Mokbel K, Price RK, Mostafa A, et al. Phyllodes tumor of the breast: a retrospective analysis of 30 ca-  
120 ses. *Breast* 1999;8:278–81.
- 121 22. Hines JR, Geurkink RE. Giant breast tumor in the adolescent. *Am J Surg* 1965;109:810–3.
- 122 23. Bader E, Isaacson C. Bilateral malignant cystosarcoma phyllodes. *J Surg Res* 1961;48:519–21.
- 123 24. Ball AB, Fisher C. Bilateral malignant phyllodes tumors. *J Surg Oncol* 1991;46:67–9.
- 124 25. Vorherr H, Vorherr UF, Kutvirt DM, Key CR. Cystosarcoma phyllodes:  
125 epidemiology, pathohistology, pathobiology, diagnosis, therapy, and survival. *Arch Gynecol* 1985  
126 ;236:173–81.
- 127 26. Chulia MT, Paya A, Niveiro M, et al. Phyllodes tumor in ectopic breast tissue of the vulva. *Int J Surg*  
128 *Pathol* 2001;9:81–3.
- 129 27. Oshida K, Miyauchi M, Yamamoto  
130 N, et al. Phyllodes tumor arising in ectopic breast tissue of the axilla. *Breast Cancer* 2003;10:82–4.  
131
- 132 28. Tbakhi A, Cowan DF, Kumar D, Kyle D. Recurring phyllodes tumor in aberrant breast tissue of the vul-  
133 va. *Am J Surg Pathol* 1993;17: 946–50.
- 134 29. Liberman L, Bonaccio E, Hamele-  
135 Bena D, et al. Benign and malignant phyllodes tumors: mammographic and sonographic  
136 findings. *Radiology* 1996;198:121–4.
- 137 30. Jorge Blanco A, Vargas Serrano B, Rodriguez Romero R, Martinez Cendejas E. Phyllodes tumor so-  
138 f the breast. *Eur Radiol* 1999;9: 356–60.
- 139 31. Bartoli C, Zurrada S, Veronesi P, et al. Small sized phyllodes tumor of the breast. *Eur J*  
140 *Surg Oncol* 1990;16:215–9.
- 141 32. Barth RJ Jr. Histologic features predict local recurrence after breast conserving therapy of phyllode-  
142 stumors. *Breast Cancer Res Treat* 1999;57:291–5.
- 143 33. Reinfuss M, Mitus J, Duda K, et al. The treatment and prognosis of patients with phyllodes tumor of the

- 144 ebreast: an analysis of 170 cases. *Cancer* 1996;77:910–6.
- 145 34. Zurrida S, Bartoli C, Galimberti V, et al. Which therapy for an unexpected phyllodes tumor of the breast?  
146 *Eur J Cancer* 1992;28:654–7.
- 147 35. Cosmacini P, Zurrida S, Veronesi P, et al. Phyllodes tumor of the breast: mammographic experience in  
148 99 cases. *Eur J Radiol* 1992;15: 11–4.
- 149 36. Jayaram G, Sthaneshwar P. Fine-  
150 needle aspiration cytology of phyllodes tumors. *Diagn Cytopathol* 2002;26:222–7.
- 151 37. Moffat CJ, Pinder SE, Dixon AR, et al. Phyllodes tumours of the breast: a clinicopathological review of  
152 thirty-two cases. *Histopathology* 1995;27:205–18.
- 153 38. Asoglu O, Ugurlu MM, Blanchard K, et al. Risk factors for recurrence and death after primary surgical  
154 treatment of malignant phyllodes tumors. *Ann Surg Oncol* 2004;11:1011–7.
- 155 39. Kapiris I, Nasiri N, A'Hern R, et al. Outcome and predictive factors of local recurrence and distant met-  
156 astases following primary surgical treatment of high-grade malignant phyllodes tumours of  
157 the breast. *Eur J Surg Oncol* 2001;27:723–30.
- 158 40. Cohn-  
159 Cedermark G, Rutqvist LE, Rosendahl I, Silfversward C. Prognostic factors in cystosarcoma phyllo-  
160 des. A clinicopathologic study of 77 patients. *Cancer* 1991;68:2017–22.
- 161 41. Norris HJ, Taylor HB. Relationship of histologic features to behavior of cystosarcoma phyllodes. An  
162 alysis of ninety-four cases. *Cancer* 1967;20:2090–9.
- 163 42. Carter BA, Page DL. Phyllodes tumor of the breast: local recurrence versus metastatic capacity. *Hu-  
164 m Pathol* 2004;35:1051–2.
- 165 43. Halverson JD, Hori-Rubaina JM. Cystosarcoma phyllodes of the breast. *Am Surg* 1974;40:295–  
166 301.
- 167 44. Hajdu SI, Espinosa MH, Robbins GF. Recurrent cystosarcoma phyllodes: a clinicopathologic stud-  
168 y of 32 cases. *Cancer* 1976;38:1402–6.
- 169 45. West TL, Weiland LH, Clagett OT. Cystosarcoma phyllodes. *Ann Surg* 1971;173:520–  
170 8. Ben Hassouna J, Damak T, Gamoudi A, et al. Phyllodes tumor of the breast: a case series of 106 pa-  
171 tients. *Am J Surg* 2006;192: 141–147.
- 172 46. Barrio AV, Clark BD, Goldberg J, et al. Clinicopathologic features and long-  
173 term outcomes of 293 phyllodes tumors of the breast. *Ann Surg Oncol* 2007; 14:2961–2970.
- 174 47. Foxcroft LM, Evans EB, Porter AJ. Difficulties in the pre-  
175 operative diagnosis of phyllodes tumor of the breast: a study of 84 cases. *Breast* 2007; 16: 27–37.
- 176 48. Jacklin RK, Ridgway PF, Ziprin P, Healy V, Hadjiminias D, Darzi A. Optimising pre-  
177 operative diagnosis in phyllodes tumor of the breast. *J Clin Pathol* 2006;59:454–459.