

Case report

BASAL IMPLANT AS AN ALTERNATIVE TREATMENT IN ATROPHIC POSTERIOR RIDGE

Abstract:

Need for study and background: Since basal implant usage is on a rise, this case report will show the usage of basal implants in posteriorly atrophied ridge. Basal implantology works on the concept that the jaw bone comprises of two parts one is tooth bearing alveolus or crestal part and the basal bone, the basal bone is heavily corticated and is rarely subject to infections and resorption and hence it offers excellent support to the implants as it is densely corticated and at the same time the load bearing capacity of the basal bone is many times higher than that offered by the spongy crestal bone. A 50 years old female patient reported to the department of implantology with chief complaint of missing teeth in lower left back region of jaw since 5 years and wanted treatment for same. After taking thorough history she gave history of traumatic extraction from the same region. Past medical history was non-contributory. **Aim:** This case report aims at suitable rehabilitation of atrophied posterior ridge of mandible with basal implant. **Methodology:** The surgical procedure began by locating the drilling point for 35 and to start the drilling, the only used was 2.0 * 17 mm drill at the speed of 4000 rpm under copious irrigation and was stopped when lingual perforation with the drill was felt. The implant was taken with the help of regular driver and tightened in the site prepared. At last provisional restoration was provided to check for occlusion, phonetics and esthetic implications. Since enough bone was present in fourth quadrant, conventional implant was considered in that arch and rehabilitation was done in accordance to that.

Conclusion: Basal implant have various advantages over conventional implants as it decreases patient's discomfort due to the flapless procedures which often doesn't require sutures for flap approximation. Basal implantology cases should be meticulously planned and through knowledge of anatomical structure and bone morphology should be known to operator for its success.

Keywords: tooth bearing alveolus, atrophied edentulous, Rehabilitation, bicortical implants, **Basal Implants and Atrophic Posterior Ridge**

INTRODUCTION

Basal implantology or bicortical implantology or just cortical implantology is a modern implantology system that makes use of basal cortical portion for retention of the dental implants. The basal bone serves as a quality cortical bone for retaining these uniquely and highly advanced implants. Since basal implantology includes the application of the rules of orthopedic surgery, the basal implants are also called as "orthopedic implant" [6-10]. First single-piece implant was developed and used by Dr. Jean-Marc Julliet in 1972. Basal bone being highly dense bone remains even after regression of alveolar bone and is less prone to resorption and infection. Implants taking support from basal bone offer an excellent and long-lasting solution for bone loss. ^[1]

Better masticatory force distribution, less evidence of peri-implantitis are some of the major advantages of basal implantology and it offers better results in patient with diabetes and chronic periodontitis^[2]. With conventional implants there should be sufficient amount of bone (at least 13-15mm length and 5-7 mm width) that should be present, to overcome these hurdles basal implants were developed. BOI (Basal Osseo Integrated) and BCS (Basal Cortical Screw) are two groups of basal implants specifically designed to utilize dense cortical jaw bones. Screwable basal implants (type of BCS) have been evolved with up to 12 mm thread diameter which can be inserted immediately in the socket after extraction^[3].

Basal bones are flapless and work on the concept of “osseoadaptation”, this stems from the fact that the bone with continuous functional loads remodels and adapts over the implant surface^[4].

Here is a case report of a 50 years old female patient who had atrophied edentulous span in posterior mandible. This case was done at ITS-CDSR Ghaziabad, UP, India.

Case Presentation

A 50 years old female patient reported to the department of implantology with chief complaint of missing teeth in lower left back region of jaw since 5 years and wanted treatment for same. After taking thorough history she gave history of traumatic extraction from the same region. Past medical history was non-contributory.

On intra-oral examination, partial edentulous span in relation to 35 and 36 was observed (figure 1) and diagnosis for mandibular arch was found to be Kennedy’s class III with remaining teeth present. The patient was educated and motivated to go for fixed rehabilitation. Therefore CBCT evaluation for bone quality and quantity assessment for implant placement was advised.

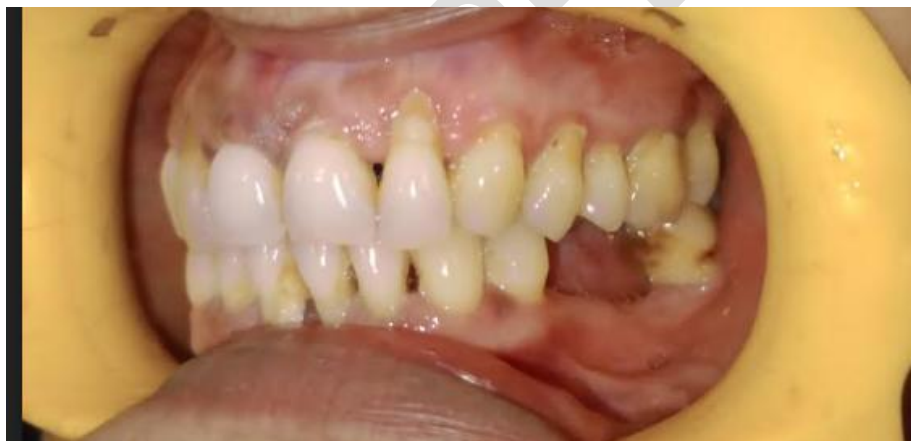

FIGURE 1: MISSING 35 AND 36

After CBCT evaluation and bone mapping an edentulous region was noted with no evidence of any remaining root fragment was noted, the alveolar bone revealed few bony trabeculae with large marrow spaces and intact cortical outlines along with Misch D2-D3 bone density. A dense sclerotic bony island was noted in the cervical-mid thirds of the ridge in relation to #36 region (figure 2).

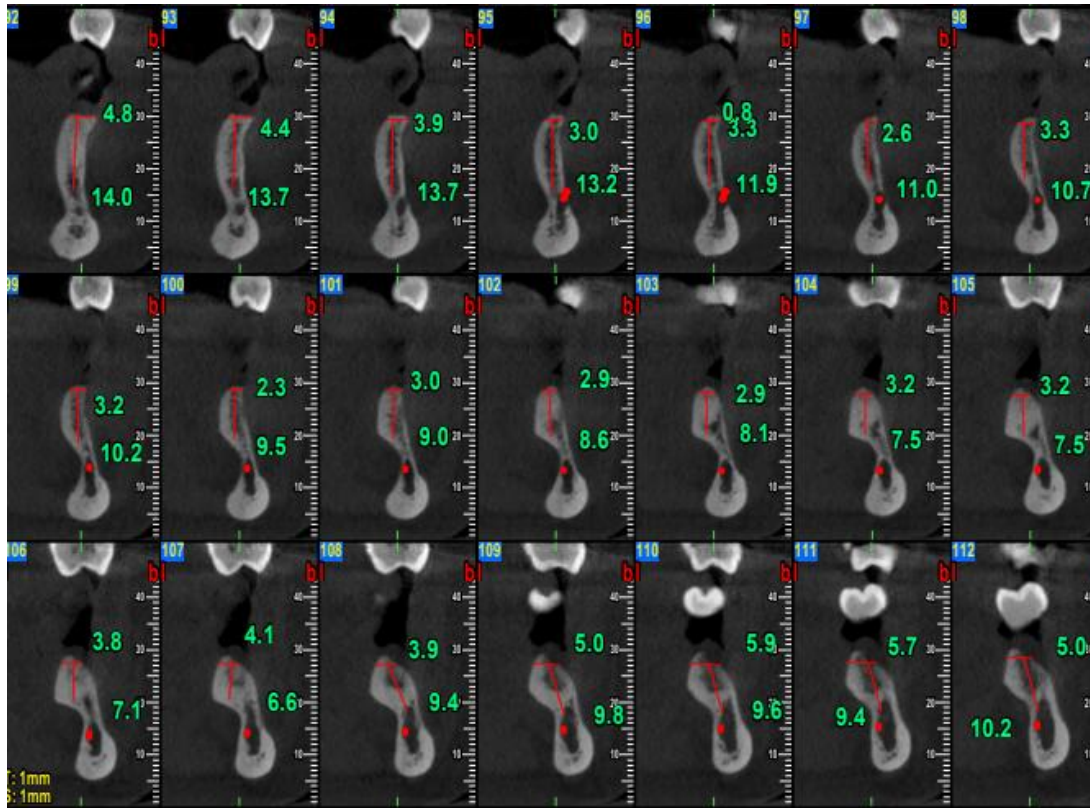


FIGURE 2: CBCT REPRESENTATION OF THE EDENTULOUS RIDGE

Since the amount of bone available was inadequate for the placement of conventional implantology, basal implants were planned for this patient. Before implant placement Root Canal Treatment was done with respect to 34 so as to involve a fixed prosthesis spanning from 34 to 36. The implant size that was chosen was MONOIMPLANT, SWITZERLAND having dimension of 2.7*17mm (smooth surface).

The inferior alveolar nerve was at its normal anatomical position.

Methodology

After taking the informed consent of the patient, surgical procedure was carried out under local anesthesia, 1:100,000 lignocaine solution was used to give Inferior alveolar, lingual and long buccal nerve block in order to completely anesthetize the region, firstly tooth preparation for 34 was done and post that the surgical procedure was initiated. Mylohyoid ridge was identified to avoid any nerve damage as slight lingual perforation had to be done in this case.

The surgical procedure began by locating the drilling point for 35 and to start the drilling, the only used was 2.0 *17 mm drill at the speed of 4000 rpm under copious irrigation and was stopped when lingual perforation with the drill was felt. In order to check the accuracy, the osteotomy site was radiographically evaluated by placing the drill in the osteotomy site. The implant was taken with the help of regular driver and tightened in the site prepared. Once the lingual perforation was felt the bone was brazed and the implant that was tilted was made straight. The same procedure was repeated for 36 as well and then the radiographic evaluation for the correct placement. Since IOPA was readily available, it was used to access osteotomy at all the times, although a 2-D modality but during the surgical procedure it is most reliable

and clinical correlation can also be done in accordance to that. The entire surgical procedure was 20minutes long.

At last provisional restoration was provided to check for occlusion, phonetics and esthetic implications which was found satisfactory and then got replaced by permanent prosthesis in later stages with porcelain fused to metal (figure 3 to 5 : shows procedure). Only Intra-oral Periapical radiograph was taken post operatively since the patient was not ready to undergo another Cone beam computed tomography.

Since enough bone was present in fourth quadrant, conventional implant was considered in that arch and rehabilitation with Zirconia crown was done after 3days.

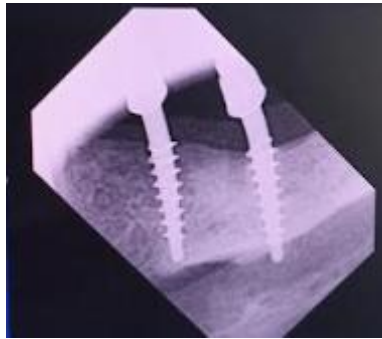


Figure 3: Post Implant IOPA

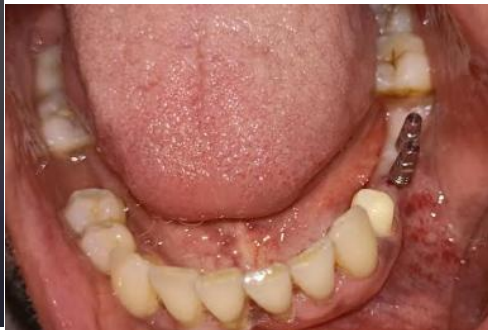

Figure 4: Intraoral picture of implants

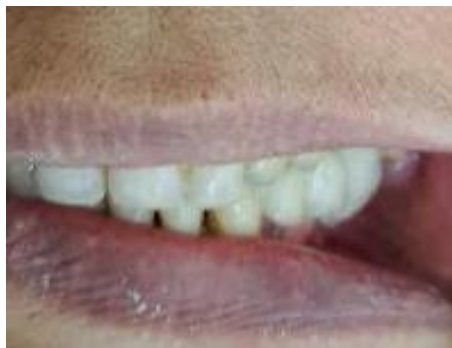

Figure 5: Final rehabilitation

Discussion

Since conventional implants demands for extensive surgical procedures which are not only expensive, but involves extensive surgery and great amount of postoperative discomfort and cannot be effectively used in all the bone types, so an alternative was needed for the same which was provided by basal implants^[3].

The modern basal implant is sophisticated has simple design, surgical protocol, and is a prosthetic friendly system as well due to these advantages basal implants are widely adopted by practitioner. Restoration of atrophied ridge always poses to be challenging for the practitioner^[5]. The restoration of

atrophied ridge requires extensive surgical planning and in some cases even ridge augmentation, basal implant in such cases can be used in any case either alone or in combination with conventional implantology^[2].

Immediate loading of basal implants can be done, when they are placed in the dense cortical bone, as they attain high primary stability there. Therefore, they are more predictable than before, though there are high chances of crestal bone loss. Since the remodeling of the bone starts within 72 h and weakens the peri-implant bone structures, rigid splinting of the metal framework should be done as early as possible^[4].

Immediate loading, single section implants, basal cortical bone support, minimal invasive, atrophied ridge, distribution of masticatory forces are some of the major advantages of basal implantology. Apart from surgical and prosthetic part of treatment planning this technique also requires a thorough fundamental knowledge in the fields of biomechanics and bone physiology. Proper training is must to avoid any complications^[1,4].

In our case there was atrophied ridge of the posterior mandible, the conventional implants would have caused more harm than good. Hence the basal implant was opted.

Conclusion

Basal implants is the treatment choice for patients with severe atrophic ridges in which conventional implants cannot be placed or extensive and expensive bone grafting and augmentation procedure might be required. It also give the option to get fixed functional prosthesis as compared to removable prosthesis which might have limitations in retention, stability and support due to compromised residual ridge height in severely resorbed ridges.

Basal implantology cases should be meticulously planned and through knowledge of anatomical structure and bone morphology should be known to operator for its success.

In our case it proved to be a better option that resulted in functional as well as esthetic rehabilitation and more patient satisfaction.

Ethical Approval:

As per international standards or university standards written ethical approval has been collected and preserved by the author(s).

Consent

As per international standards or university standards, patient(s) written consent has been collected and preserved by the author(s).

References

- 1) Ghalaut P, Shekhawat H, Meena B. Full-mouth rehabilitation with immediate loading basal implants: A case report. *National journal of maxillofacial surgery*. 2019 Jan 1;10(1):91-4.
- 2) Mustilwar R, Fatima N, Ahmed CZ, Bagde H, Johnson L, Khan FA. Basal Implantology-A Review. *NeuroQuantology*. 2022;20(11):1425.
- 3) Patel K, Madan S, Mehta D, Shah SP, Trivedi V, Seta H. Basal implants: An asset for rehabilitation of atrophied resorbed maxillary and mandibular jaw—A prospective study. *Annals of Maxillofacial Surgery*. 2021 Jan 1;11(1):64-9.
- 4) Anuradha M, Babaji HV, Hiremath NV, Usha VA, Kumar A, Nandkeoliar T, Verma S. Assessment of basal implants in compromised ridges. *Journal of Family Medicine and Primary Care*. 2020 Apr 1;9(4):2067-70.
- 5) Gupta AD, Verma A, Dubey T, Thakur S. Basal osseointegrated implants: classification and review. *Int J Contemp Med Res*. 2017;4(11):2329-35.
- 6) Rathee M, Malik S, Jain P, Kaushik S. Basal implants: an alternative treatment modality for geriatric patients-A case report. *J West Bengal Univ Health Sci*. 2020;1(1):85-9.
- 7) Ghalaut P, Shekhawat H, Meena B. Full-mouth rehabilitation with immediate loading basal implants: A case report. *National journal of maxillofacial surgery*. 2019 Jan 1;10(1):91-4.
- 8) Prasad S, Pandey A, Bagchi G. Basal implants: an alternative treatment modality to conventional dental implants. *InIDA 2018 (Vol. 34, No. 1, pp. 12-17)*.
- 9) Ali SM, Othman KS, Samad AA, Mahmud PK. Comparison between basal and conventional implants as a treatment modality in atrophied ridges. *Journal of Dental Implant Research*. 2019 Sep 30;38(2):48-54.
- 10) Shaikh TA, Bhanotia D, Pacharne AP. Bicortical Implants: An Alternative Treatment Modality for the Hopeless: A Case Report. *Journal of Advanced Medical and Dental Sciences Research*. 2022 Nov 1;10(11):23-7.