

Case report

BASAL IMPLANT: TREATMENT OPTION IN POSTERIRLY ATROPHIED RIDGE

Abstract:

We report a case of a 50 years old female patient who had atrophied edentulous span in posterior mandible. Basal implantology works on the concept that the jaw bone comprises of two parts one is tooth bearing alveolus or crestal part and the basal bone, the basal bone is heavily corticated and is rarely subject to infections and resorption and hence it offers excellent support to the implants as it is densely corticated and at the same time the load bearing capacity of the basal bone is many times higher than that offered by the spongy crestal bone. A 50 years old female patient reported to the department of implantology with chief complaint of missing teeth in lower left back region of jaw since 5 years and wanted treatment for same. After taking thorough history she gave history of traumatic extraction from the same region. Past medical history was non-contributory. Basal implant have various advantages over conventional implants as it decreases patient's discomfort due to the flapless procedures which often doesn't require sutures for flap approximation. Basal implantology cases should be meticulously planned and through knowledge of anatomical structure and bone morphology should be known to operator for its success.

Keywords: tooth bearing alveolus, atrophied edentulous, Rehabilitation, biocortical implants

INTRODUCTION

Basal implantology is a unique system that engages the basal cortical portion of the jaw bones for retention. They are also regarded as cortical, or biocortical implants. In basal implantology there is multicortical support that results in absolute primary implant stability in dense living native bone¹.

Rehabilitation of an edentulous maxillary and mandibular ridge with dental implants have become a routine practice but for it to be successful sufficient bone should be available (at least 13-15mm length and 5-7 mm width)². In case there is lack of adequate bone dimensions, the implant placement becomes difficult³. To overcome this, there have been innovations in implant dentistry in regards to implant designs and protocols which are Mini Dental Implants and Basal Implants.

Basal implantology works on the concept that the jaw bone comprises of two parts one is tooth bearing alveolus or crestal part and the basal bone, the basal bone is heavily corticated and is rarely subject to infections and resorption and hence it offers excellent support to the implants as it is densely corticated and at the same time the load bearing capacity of the basal bone is many times higher than that offered by the spongy crestal bone^{4,5,6,7}.

For conventional implant the term used is "Osseointegration" but as far as basal implant is concerned "Osseoadaptation"¹ is the right term because bone with continuous functional loads remodels and finally adapts over the surface of the implant. According to the philosophy of basal implantology the

process of Osseoadaptation is carried out by a “Bone Multicellular Unit” (BMU). Basal implants employ the same principles of peri-implant healing and bone densification, so they are also termed as “orthopedic implants”⁵

The crestal bone is less dense in nature and is exposed to infections from tooth borne pathologies, injuries or iatrogenic factors and is therefore subject to higher rate of resorption whereas the basal bone is heavily corticated and is rarely subject to infections and resorption. It is this, i.e.; the basal bone that can offer excellent support to the implants because of its densely corticated nature, at the same time the load bearing capacity of the basal bone is many times higher than that offered by the spongy crestal bone. This rationale stems from Orthopedic surgery and from the experience that cortical areas are essential, since, they are resistant to resorption, as a result basal implants are also called as “Orthopedic Implants”^[8,9,10]

Rehabilitating an atrophied ridge is a challenging task for any clinician. Restoration of such cases involves extensive planning including the option of pre-prosthetic surgery; basal implantology negates any need for extensive surgeries. Unlike conventional implantology where ridge augmentation is indicated to enable placement of implant with appropriate dimensions, basal implants can be used in any size and in combination with any implant^{11,12}.

There are four basic types of basal implants available

I Screw Form.

II Disk Form.

III Plate Form.

IV Other Forms^[1]

The surface can be rough surface as well as smooth surface but since according to various studies, smooth surfaces are less prone to inflammation, smooth surface implants are considered nowadays^[1]

Here is a case report of a 50 years old female patient who had atrophied edentulous span in posterior mandible.

Case Presentation

A 50 years old female patient reported to the department of implantology with chief complaint of missing teeth in lower left back region of jaw since 5 years and wanted treatment for same. After taking thorough history she gave history of traumatic extraction from the same region. Past medical history was non-contributory.

On intra-oral examination, partial edentulous span irt 35 and 36 was observed (figure 1) and diagnosis for mandibular arch was found to be Kennedy’s class III with remaining teeth present. The patient was educated and motivated to go for fixed rehabilitation. Therefore CBCT evaluation for bone quality and quantity assessment for implant placement was advised.

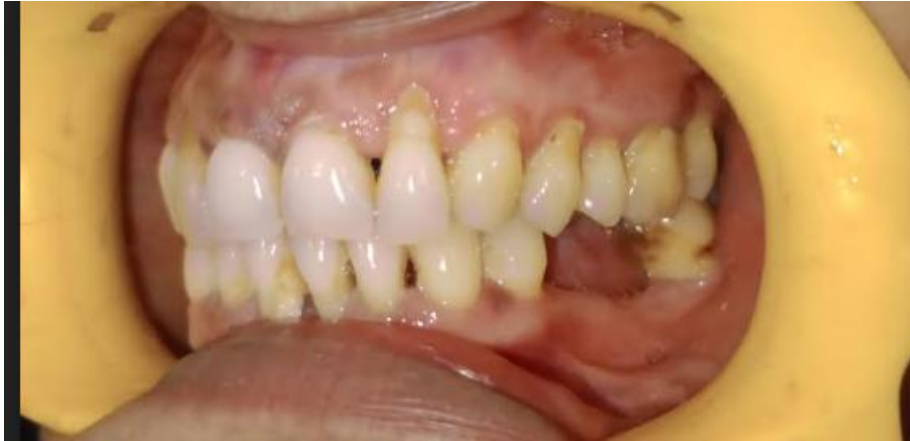

FIGURE 1: MISSING 35 AND 36

After CBCT evaluation and bone mapping an edentulous region was noted with no evidence of any remaining root fragment was noted, the alveolar bone revealed few bony trabeculae with large marrow spaces and intact cortical outlines along with Misch D2-D3 bone density. A dense sclerotic bony island was noted in the cervical-mid thirds of the alveolus wrt #36 region (figure 2).

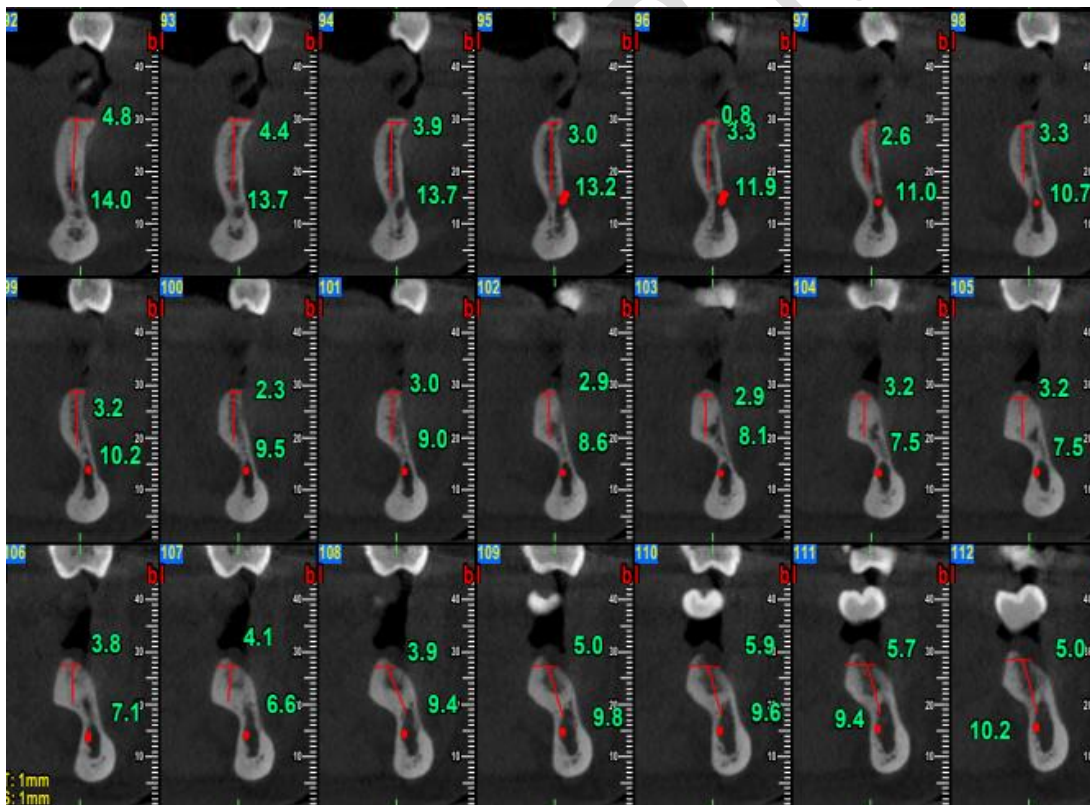


FIGURE 2: CBCT REPRESENTATION

Since the amount of bone available was inadequate for the placement of conventional implantology, basal implants were planned for this patient. Before implant placement RCT was done with respect to 34 so as to involve a fixed prosthesis spanning from 34 to 36. The implant size that was chosen was MONOIMPLANT, SWITZERLAND having dimension of 2.7*17mm (smooth surface).

The inferior alveolar nerve was at its normal anatomical position.

Surgical Procedure

The procedure was carried out under local anesthesia, 1:100,000 lignocaine solution was used to give Inferior alveolar, lingual and long buccal nerve block in order to completely anesthetize the region, firstly tooth preparation for 34 was done and post that the surgical procedure was initiated. Mylohyoid ridge was identified to avoid any nerve damage as slight lingual perforation had to be done in this case.

The surgical procedure began by locating the drilling point for 35 and to start the drilling, the only used was 2.0 *17 mm drill at the speed of 4000 rpm under copious irrigation and was stopped when lingual perforation with the drill was felt. In order to check the accuracy, the osteotomy site was radiographically evaluated by placing the drill in the osteotomy site. The implant was taken with the help of regular driver and tightened in the site prepared. Once the lingual perforation was felt the bone was brazed and the implant that was tilted was made straight. The same procedure was repeated for 36 as well and then the radiographic evaluation for the correct placement. Since IOPA was readily available, it was used to access osteotomy at all the times, although a 2-D modality but during the surgical procedure it is most reliable and clinical correlation can also be done in accordance to that.

At last provisional restoration was provided to check for occlusion, phonetics and esthetic implications which was found satisfactory and then got replaced by permanent prosthesis in later stages with porcelain fused to metal (figure 3 to 5 : shows procedure).

Since enough bone was present in fourth quadrant, conventional implant was considered in that arch and rehabilitation was done in accordance to that.

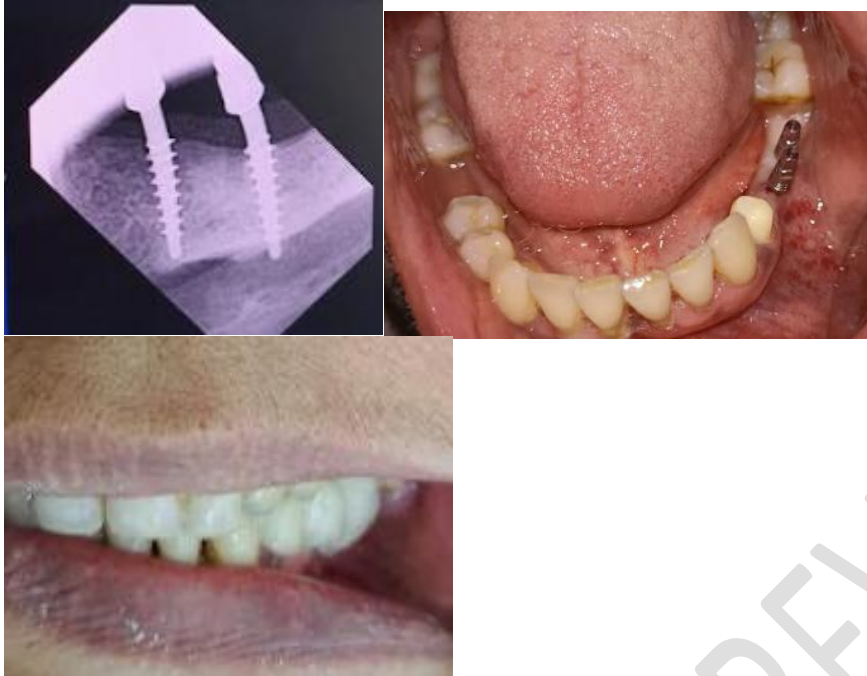


Figure 3 to 5: Showing the final rehabilitation

Discussion

Since basal implants are placed in the dense cortical bone they attain good primary stability and it is for this reason that immediate loading of these implants can be done. Since the remodeling of the bone starts within 72 h and weakens the peri-implant bone structures, rigid splinting of the metal framework should be done as early as possible. The splinting distributes the masticatory forces from the bone around the implants to other cortical areas as well. This procedure and its principles are known in traumatology. Two implants were placed flaplessly in the mandibular jaw engaging the lingual cortical bone, using handgrip instruments. About 100% success rate can be achieved if BCS implants are used along with an appropriate immediate load protocol. The BCS implants are smooth surface implants which have aggressive threads and can be placed in already infected sockets. We can achieve excellent primary stability along the vertical surfaces of BCS implants with no need for corticalization¹⁰.

Basal implant have various advantages over conventional implants as it decreases patient's discomfort due to the flapless procedures which often doesn't require sutures for flap approximation. It reduces cost and saves time of the patient specifically in atrophied ridges as bone grafting procedures and the normal Osseointegration time of conventional implants are time taking.^[11]

Hence, they can be used for both immediate placement and immediate loading.

Conclusion

Basal implants is the treatment choice for patients with severe atrophic ridges in which conventional implants cannot be placed or extensive and expensive bone grafting and augmentation procedure might

be required. It also give the option to get fixed functional prosthesis as compared to removable prosthesis which might have limitations in retention, stability and support due to compromised residual ridge height in severely resorbed ridges.

Basal implantology cases should be meticulously planned and through knowledge of anatomical structure and bone morphology should be known to operator for its success.

References

1. Gupta AD, Verma A, Dubey T. Saloni Thakur Basal Osseointegrated Implants: Classification and Review International Journal of. Contemp Med Res. 2017;4(11):2329–35.
2. Ihde S. Restoration of the Atrophied Mandible Using Basal Osseointegrated Implants and Fixed Prosthetic Superstructures. *Implant Dent*. 2001;10(1):41–5.
3. Sharma R, P J, Dhruv A, Hasti A. Basal Implants- An Alternate Treatment Modality for Atrophied Ridges. *IJRID*. 2016;6:60–72.
4. Sharma Rahul, Prakash Jai, Anand Dhruv, Hasti Anurag. Basal Implants- An Alternate Treatment Modality for Atrophied Ridges. *IJRID* 2016;6:60-72.
5. Ihde Stefan. Principles of BOI- Clinical, Scientific, and Practical Guidelines to 4-D Dental Implantology. Springer, Heidelberg; Germany, 2005.
6. NiswadeGrishmi, Mishra Mitul. Basal Implants- A Remedy for Resorbed Ridges. *WJPLS* 2017;3:565-572.
7. Yeshwante Babita, Choudhary Neha. Baig Nazish, Tated Gaurav, Kadam Pranit. Basal Osseointegrated Implants. *IJAHS* 2016;3:1-8.
8. Sharma Rahul, Prakash Jai, Anand Dhruv, Hasti Anurag. Basal Implants- An Alternate Treatment Modality for Atrophied Ridges. *IJRID* 2016;6:60-72.
9. Ihde Stefan. Principles of BOI- Clinical, Scientific, and Practical Guidelines to 4-D Dental Implantology. Springer, Heidelberg; Germany, 2005.
10. NiswadeGrishmi, Mishra Mitul. Basal Implants- A Remedy for Resorbed Ridges. *WJPLS* 2017;3:565-572.
11. Yadav R. S, Sangur R, Mahajan T, Rajanikant A. V, Singh N, Singh R. An Alternative to Conventional Dental Implants: Basal Implants. *Rama Univ J Dent Sci*, 2015;2:22-28.
12. Misch, Carl E. Contemporary Implant Dentistry. St. Louis: Mosby, 1993.
13. Ghalaut P, Shekhawat H, Meena B. Full-mouth rehabilitation with immediate loading basal implants: A case report. *National journal of maxillofacial surgery*. 2019 Jan;10(1):91.
14. Kumar K, Kumar S, Singh R, Vaibhav V, Kedia NB, Singh AK. Basal implants-A new era of prosthodontic dentistry. *IP Ann Prosthodontics Restor Dent*. 2020;6:1-3.