

Continuous epidural catheter for postoperative analgesia in children [A case report].

ABSTRACT

The management of postoperative pain in children and infants has now become a significant concern. Continuous epidural anesthesia is a proven method for controlling acute pain after surgery.

We present the case of thoracic epidural analgesia used for the repair of an extensive burn involving the back and trunk, assisted by a skin graft, in a 6-year-old girl. Department of Pediatric Intensive Care Unit, Children's Hospital of Rabat.

In pediatric surgery, postoperative pain awareness is crucial for medical and paramedical teams. Continuous epidural anesthesia, utilizing suitable equipment, is feasible for young children. Its advantages during long procedures are manifold: it eliminates the need for central analgesics, ensuring stable cardiovascular function and a calm awakening post-surgery. Moreover, it provides high-quality analgesia in the postoperative phase, decreasing morbidity and easing care for children. With safe analgesics and advances in locoregional anesthesia, managing postoperative pain in pediatrics has markedly improved.

Keywords: Continuous epidural catheter ; analgesia ; children ; postoperative

1. INTRODUCTION

Postoperative pain management in children and infants has become a major concern nowadays. Continuous epidural anesthesia is a well-established procedure for postoperative pain relief, allowing for the control of acute pain following surgery.

2. CASE PRESENTATION

We report successful outcomes of thoracic epidural analgesia used for the repair of an extensive burn involving the back and trunk with skin grafting in a 6-year-old girl without any comorbidities. The surgery was performed under light general anesthesia combined with a single epidural injection of 0.25% bupivacaine (0.5 ml.kg⁻¹) through an epidural catheter inserted via the sacral route. The catheter was easily placed and secured. Over the following two days, the catheter remained in place, and a continuous epidural infusion was utilized (0.2 ml.kg⁻¹.h⁻¹ of 0.125% bupivacaine), providing safe and effective analgesia to facilitate the child's management. Preoperative and postoperative analgesia were adequate, with the latter assessed using the Children's Hospital of Eastern Ontario Pain Scale (CHEOPS). In our patient, the score was 6/13, indicating no need for adjunctive analgesic therapy (Table 1).

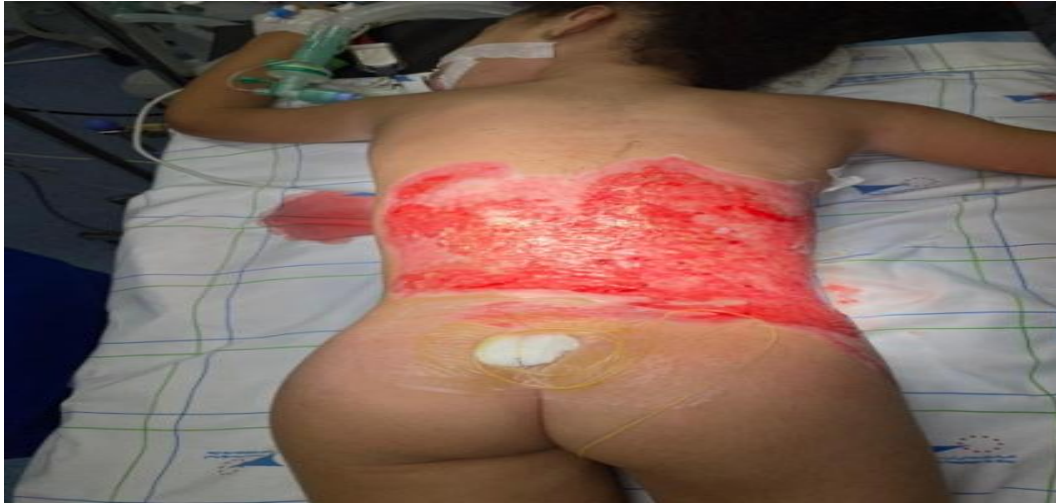

Fig. 1: An extensive burn involving the back and trunk in a 6-year-old girl.

Settings		Score
cries – tears	Not crying" - No tears	1
	Mourning or crying	2
	Piercing screams or howls	3
Expression of face	Smile	0
	Calm, neutral face	1
	Grimace	2
Verbal complaints	Talks about various things without complaining	0
	Doesn't talk or complains, but not about pain	1
	Complains about pain	2
Body posture	Body (torso) calm, at rest	1
	Changes position or fidgets, or body arched or rigid or trembling, or body straightened vertically, or body restrained	2
	A child standing up from his bed	2
Desire to touch the wound.	No	1
	yes	2
Legs	Relaxed or gentle movements	1
	Twisting, writhing, or kicking, or legs straightened or lifted onto the body,	2
	stands up or squats or kneels, or legs restrained	2

Table 1: CHEOPSscale Children's Hospital of Eastern Ontario Postoperative scale Assessment of postoperative pain in children aged 1 to 5 years"

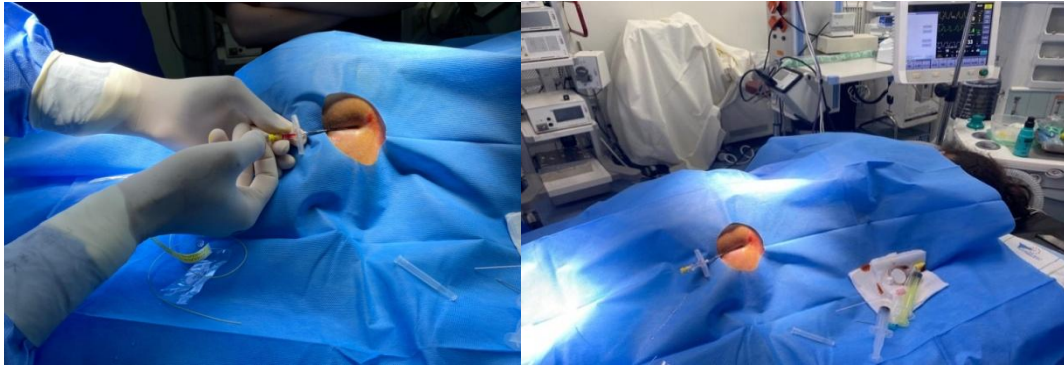


Fig 2 : Cathéter péridurale continue par ponction caudale chez un enfant de six ans

3. RESULTS AND DISCUSSION

Extradural space puncture is easy and safe in young children provided a rigorous technique and suitable equipment are used. The extradural space is reached within less than 2 cm after piercing the skin [1]. The resistance offered by the yellow ligament is not as significant as in adults, and the space itself is occupied by fatty lobules much less tightly interwoven than in adults. Therefore, it is preferable to use short Tuohy needles with a short bevel and a low-capacity syringe-mandrel (3 to 5 ml) for this puncture. The smallest volume should be injected for extradural space identification to avoid diluting the injected local anesthetic (LA) too much. The "hanging drop" technique, as used by RUSTON[2-3], is employed to locate the epidural space.

Catheter insertion is straightforward. Polyurethane, used in this study, represents a particularly suitable material for this technique. Its characteristics are close to the ideal material defined by BROMAGE [4]. It is indeed non-toxic, flexible, yet particularly resistant. The diameter used allows for mandrel usage. However, due to the catheter's small internal diameter, LA injection is slow. This catheter has a single distal exit orifice and a rounded tip; it is graduated to enable precise catheter length identification.

Extradural anesthesia has always been performed under general anesthesia [5]. Cooperation from the child at this age is impossible to obtain. Furthermore, strict immobility of the child is necessary due to the short distance between the skin and the epidural space. Finally, the length of the surgical procedure itself is an indication for combining light general anesthesia with locoregional anesthesia. During the operative period, the obtained analgesia was satisfactory, avoiding the use of central analgesics and allowing for a rapid awakening at the end of the surgical procedure.

No failure of L5-S1 root blocks was reported. In adults, the failure rate is 17.5% [6], linked to the size of the lower lumbar and sacral nerve roots. The smaller diameter of these roots in children, as well as the low myelination of the fibers, likely accounts for this difference in effectiveness. Additionally, no asymmetry was observed in the preoperative analgesia level.

Cardiovascular stability was remarkable both after epidural anesthesia and during the operative period. The absence of hemodynamic repercussions has been noted by several authors during caudal epidural anesthesia in children[7, 8], unlike what is observed in adults [9]. One of the most frequently accepted explanations is the existence of a high baseline sympathetic tone in children, which would quickly compensate for the slight drop in blood pressure.

The local anesthetic used in this study is 0.25% BPV. These are interventions requiring long-lasting analgesia without complete motor block, due to the necessity of general anesthesia. The initial dose is lower than the maximum recommended doses in adults ($2 \text{ mg} \cdot \text{kg}^{-1}$) [10].

The volume of LA used was sufficient ($0.5 \text{ ml} \cdot \text{kg}^{-1}$), but the level of analgesia could not be precisely evaluated at the end of the procedure. It does not seem to have exceeded D6 at most. In any case, no clinical impairment of respiratory muscles was observed.

No study has yet been conducted to specify the LA requirements in young children. These volumes are lower than those required for a caudal anesthesia to achieve a low dorsal block[11, 12].

In the postoperative period, assessing the quality of analgesia is very difficult in young children. The reasons for reinjection were agitation, unexplained crying, or a painful impression noted by parents, the doctor, or the nurse. Additionally, the quality of sleep on the first postoperative night was excellent in this child without requiring reinjection.

4. CONCLUSION

In pediatric surgery, recognition of postoperative pain should be a constant concern for medical and paramedical staff. Continuous epidural anesthesia can be performed in young children using well-adapted equipment. The benefits of this technique for lengthy procedures are twofold. During the operative period, it avoids the need for central analgesics while ensuring excellent cardiovascular stability and a rapid, calm awakening at the end of the procedure. In the postoperative period, it allows for excellent quality analgesia, reducing postoperative morbidity and facilitating care for young children. Indeed, the availability of safe and effective analgesics, along with the advancement of locoregional anesthesia in pediatrics, now enables better management of postoperative pain.

COMPETING INTERESTS

Authors have declared that no competing interests exist.

CONSENT

It is not applicable

ETHICAL APPROVAL

It is not applicable.

REFERENCES

1. SCHULTE-STEINBERG O. Neural blockade. In : Clinical anesthesia and pain management, vol. 21. M.J. Cousins and P.O. Bridenbaugh eds. Lippincott, Philadelphia, 1980.
2. RUSTON F.G. Epidural anaesthesia in infants and children. *Can. Anesth. Soc. J.*, 1 : 37-44, 1954.
3. RUSTON F.G. Epidural anesthesia in pediatric surgery: present status in the Hamilton General Hospital. *Can. Anaesth. Soc. J.*, 11: 12-34, 1964.
4. BROMAGE P_R. Epidural analgesia. Saunders, Philadelphia, 1978.
5. Continuous epidural anaesthesia for children less than two years old M.M. DELLEUR, I. MURAT, C. ESTI~VE, P. RAYNAUD, O. GAUDICHE, C. SAINT-MAURICE
6. GALINDO A,, HERNANDEZ J., BENAVIDES O., ORTEGON DE MUNOZ S., BONICA J.J. Quality of spinal extradural anaesthesia : the influence of spinal nerve root diameter. *Br. J. Anaesth.*, 47: 41-47, 1975.
7. FORTUNA A. Caudal analgesia : a simple and safe technique in pediatric surgery. *Br. J. Anaesth.*, 39 : 165-170, 1967
8. MELMAN E., PENNELAS J., MARUEFO J. Regional anesthesia in children. *Anesth. Analg. (Cleve.)*, 54: 387-392, 1975.
9. BONICA J.J., BERGES P_U., MORIKAWA K. Circulatory effects of peridural block. *Anesthesiology*, 33" 619-626, 1970.
10. COUSINS M.J., MATHER L.E. Clinical pharmacology of local anesthetics. *Anesth. Intensive Care*, 8: 257-277, 1980
11. MC Grath PJ, Johnson G, Goodman JT, Schillinger J. Dunn J, Chapman J. The CHEOPS: a behavioral scale to measure postoperative pain in children. In: Fields HL. Dubner R. Cervero F e&. *Advances in pain research and therapy*. New York: Raven Press; 1985. p 395-402 (niveau 4)
12. TAKASAKI M. Blood concentrations of lidocaine, mepivacaine and bupivacaine during caudal analgesia in children. *Acta AnesthesiolScand.*, 28: 211-214, 1984

