

## Case report

### **Rare case of right ventricular perforation during pericardiocentesis: Case report**

#### **abstract**

Iatrogenic cardiac injuries are potential complications arising from diagnostic and therapeutic procedures in cardiology, including interventions like cardiac catheterization, coronary angioplasty, and pacemaker implantation(1)(2). Pericardial tamponade can occur, with a prevalence of 0.12%, often requiring urgent intervention such as pericardiocentesis.

Patients with chronic pericardial effusion and signs of tamponade may adapt to gradual fluid accumulation, but vigilance for iatrogenic injuries remains crucial. Transthoracic echocardiography aids in rapid diagnosis and guides timely interventions (3). Therefore, the right ventricular perforation seems to be one of these complications, and it may occur during pericardiocentesis.

Surgical approaches for acute tamponades vary, with median sternotomy enabling comprehensive exploration (4). Echocardiographic monitoring can signal clinical deterioration, necessitating prompt fluid management and early intervention to optimize outcomes. Although, the therapies in right ventricular perforation are variable. In our case, we emphasize about the conservative approach.

#### **Introduction:**

Cardiac trauma necessitating immediate surgical intervention stands as a pivotal clinical concern within cardiac surgery, with delayed intervention being a leading cause of both iatrogenic and non-iatrogenic cardiac injuries. Iatrogenic incidents are predominantly observed in healthcare settings, notably during pericardiocentesis procedures which inherently bear the risk of cardiac injury. Among these injuries, right ventricular trauma emerges as a common occurrence during pericardiocentesis. Decisive early surgical

intervention is guided significantly by frequent transaortic echocardiography assessments in urgent tamponade scenarios. Particularly in emergency diagnoses, timely transport and expedited surgical exploration serve as life-saving measures for these patients."

### **Case presentation:**

55-year-old male patient, without modifiable cardiovascular risk. The patient presented to the emergency department for acute dyspnea stage IV (New York heart association). He underwent pericardiocentesis once before due to pericardial effusion, presenting with recurrent fluid formation came in the emergency department.

Patient was monitored via, chest x-ray, echocardiography, one central venous catheter, and urinary catheter and followed.

Patient vital values were Blood Pressure: 88/41 mmHg, HR: 128 beats/min. Patient's echocardiography showed cardiac tamponade. Chest x-ray had massive pericardial effusion. The ECG showed a sinus tachycardia at 128bpm, inverted T waves in the anterior territory and low QRS voltage.

Pericardiocentesis, under low sedation, was performed with the evacuation of 300cc of pericardial non clotting fluid.

At the end the patient moved brutally causing an injury by the 6F catheter.

The echocardiography showed right ventricular (RV) perforation with formation of a blood clot at the apex of the right ventricle. 'FIGURE 1'

A day later the patient became unstable, so due to the evidence of a cardiac tamponade, the deterioration of the hemodynamic state, he was presented an informed consent and was moved to the emergency operating room.

The surgery went under median sternotomy and 1500cc of hemorrhagic liquid was drained with the removal of the local hematoma and the perforation on sharp edge of the side facing the bottom of the right ventricle was controlled by pressing fingers. The post operative followings were simple.

Post op followings were simple.

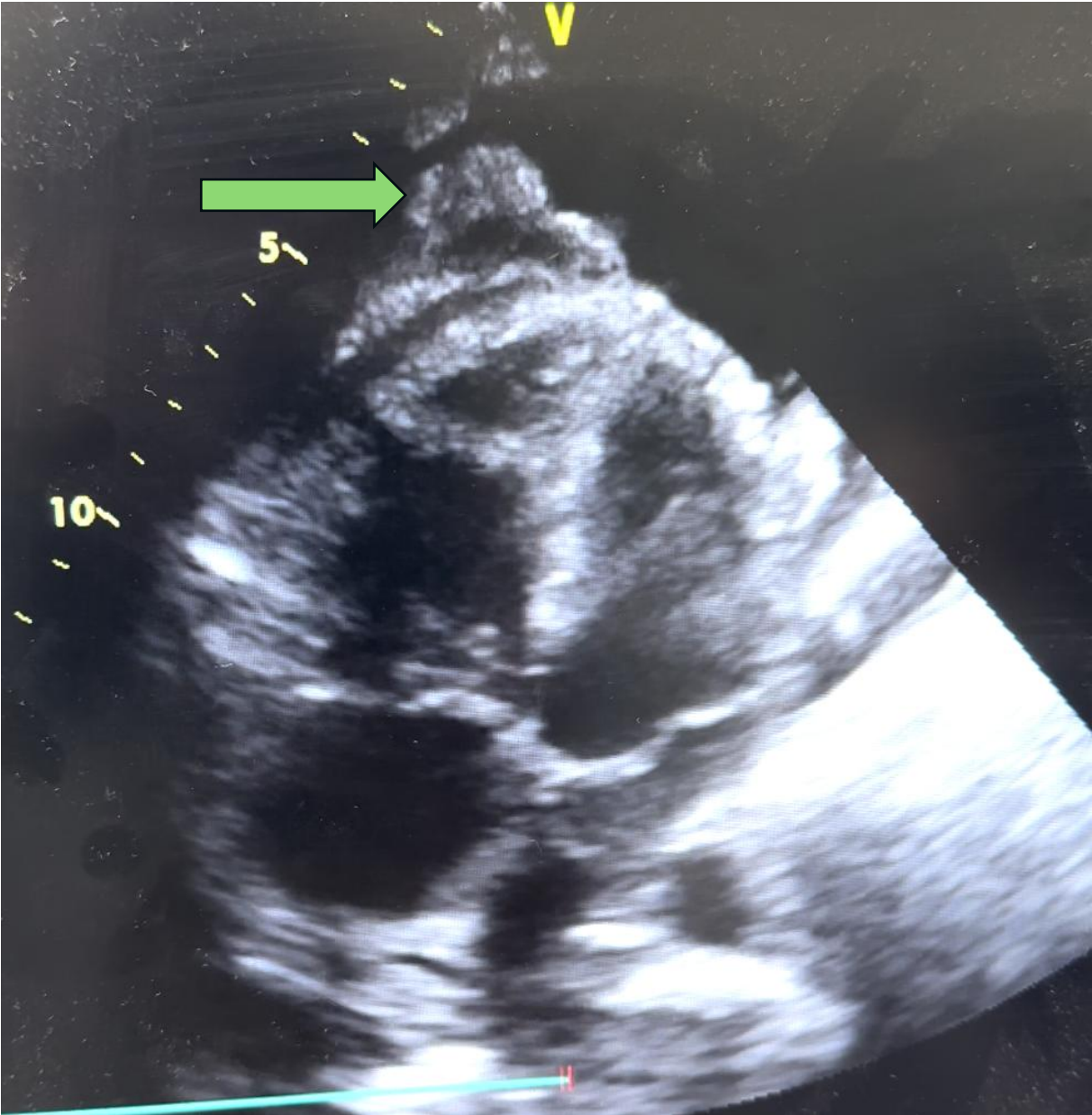


Figure 1 Echocardiography showed the formation of a blood clot at the apex of the right ventricle.

**Discussion:**

Iatrogenic cardiac injuries can arise from diagnostic and therapeutic procedures in cardiology. These injuries can occur during various interventions such as cardiac catheterization, coronary angioplasty, stent placement, pacemaker implantation, balloon valvuloplasty, or during cardiopulmonary resuscitation, leading to sternum and rib fractures. Moreover, cardiac damage can be precipitated during new surgical procedures due to factors like pericardial adhesions causing infections, previous radiotherapy, or prior surgical interventions (5).

Pericardiocentesis is a commonly utilized intervention for the diagnosis and treatment of substantial pericardial effusion, proving to be a vital life-saving measure, especially in cases of cardiac tamponade (6) (7). The overall major complication rate associated with pericardiocentesis is 3%, with iatrogenic ventricular rupture occurring in 1% of instances. Surgical exploration and primary repair are typically favored as the initial approach for managing these significant complications (8).

In a distinct investigation focusing on iatrogenic cardiac injury, a cohort of over 25,000 patients was scrutinized. The prevalence of pericardial tamponade was determined to be 0.12%. Among these occurrences, 17 cases were identified during procedures in the catheterization laboratory, with an additional 14 cases detected after a 4-hour interval (9).

The iatrogenic perforation rate during pericardiocentesis or interventional procedures involving the right ventricle varies from 0.3% to 5%. Approximately half of these incidents have been linked to the onset of tamponade or circulatory collapse. In contrast, the iatrogenic perforation rate for procedures involving the left ventricle ranges between 0.1% and 3.3% (10).

Patients presenting with chronic pericardial effusion and signs of tamponade can undergo a gradual progression, enabling adaptation to the pace of pericardial fluid accumulation and parietal pericardium stretching. However, we stress the critical importance of remaining vigilant regarding iatrogenic injuries. The severity of clinical outcomes hinges on the size of the perforation. Implementing repetitive transthoracic echocardiography at frequent intervals within the intensive care unit setting plays a pivotal role in preserving lives, as illustrated in this case. Echocardiography is adept at detecting swift escalations in pericardial

fluid, signaling the imperative for immediate intervention sans the delay for further diagnostic measures.

The approach to managing rapidly developing tamponades resulting from cardiac injury lacks universal standardization. Nonetheless, median sternotomy is frequently favored due to its ability to facilitate comprehensive exploration of all cardiac regions (11).

In the iatrogenic injury case described herein, the swift escalation of pericardial fluid in the right heart, as detected by echocardiography, coupled with a rapid increase in central venous pressure, underscored the patient's swift clinical deterioration. At this juncture, swift fluid resuscitation, early transfer, and exploratory procedures emerge as life-saving interventions.

Mobility of patients experiencing bleeding and tamponade can exacerbate issues of instability (12).

#### **Conclusion:**

In conclusion, our case highlights the rare but potentially life-threatening complication of right ventricular injury following pericardiocentesis. The presentation of such injuries underscores the importance of meticulous procedural planning, careful patient selection, and immediate recognition of complications during and after pericardiocentesis. Early diagnosis through imaging modalities like echocardiography, coupled with prompt surgical intervention when indicated, plays a crucial role in optimizing patient outcomes. This case underscores the necessity for ongoing vigilance and adherence to best practices in pericardiocentesis procedures to minimize the risk of RV injury and its associated morbidity and mortality.

## REFERENCES :

- 1- Affronti A, Ruel M. Emergency Surgery for Iatrogenic Injuries attributable to Percutaneous Coronary Interventions: When Planning and Time Matter. *J Am Heart Assoc.* 2019;8(1):e011525. doi:10.1161/JAHA.118.011525
- 2- Verevkin A, von Aspern K, Leontyev S, Lehmann S, Borger MA, Davierwala PM. Early and Long-Term Outcomes in Patients Undergoing Cardiac Surgery Following Iatrogenic Injuries During Percutaneous Coronary Intervention. *J Am Heart Assoc.* 2019;8(1):e010940. doi:10.1161/JAHA.118.010940
- 3- Chandraratna PAN, Mohar DS, Sidarous PF. Role of Echocardiography in the Treatment of Cardiac Tamponade. *Echocardiography.* 2014;31(7):899-910. doi:10.1111/echo.12605
- 4- Gumrukcuoglu HA, Odabasi D, Akdag S, Ekim H. Management of Cardiac Tamponade: A Comperative Study between Echo-Guided Pericardiocentesis and Surgery—A Report of 100 Patients. *Cardiol Res Pract.* 2011;2011:1-7. doi:10.4061/2011/197838
- 5- Mattox KL, Estrera AL, Wall MJ Jr. Traumatic Heart Disease. In: Braunwald E, Zipes DP, Libby P, Bonow RO, editors. *Braunwald's heart disease.* 7th ed. Philadelphia: Elsevier Saunders; 2005. p. 1781-8.
- 6- Adler Y, Charron P, Imazio M, et al. 2015 ESC Guidelines for the diagnosis and management of pericardial diseases. *Eur Heart J.* 2015;36(42):2921-2964. doi:10.1093/eurheartj/ehv318
- 7- Hsu LF, Scavée C, Jaïs P, Hocini M, Haïssaguerre M. Transcardiac pericardiocentesis: an emergency life-saving technique for cardiac tamponade. *J Cardiovasc Electrophysiol.* 2003; 14:1001-1003.
- 8- Tsang TS, Freeman WK, Barnes ME, Reeder GS, Packer DL, Seward JB. Rescue echocardiographically guided pericardiocentesis for cardiac perforation complicating

catheter-based procedures. The Mayo Clinic experience. J Am Coll Cardiol. 1998; 32:1345-1350.

- 9- Fejka M, Dixon SR, Safian RD, O'Neill WW, Grines CL, Finta B, et al. Diagnosis, Management, and Clinical Outcome of Cardiac Tamponade Complicating Percutaneous Coronary Intervention. Am J Cardiol. 2002; 90(11): 1183-6.
- 10- Levine MJ, Bairn DS. Endomyocardial biopsy. In: Grossman W, editor. Cardiac Catheterization, Angiography and Intervention. Philadelphia: Lea&Febiger; 1991. p. 383-95.
- 11- Velmahos GC, Degiannis E, Souter I, Saadia R. Penetrating trauma to the heart: a relatively innocent injury. Surgery. 1994;115(6): 694-7.
- 12- Özatik MA, Göl K, Budak B, Küçüker Ş, Sarıtaş A, Mavitaş B ve ark. AçıkKalpAmeliyatlarıSonrasıKanamaveyaTamponadNedeniyleYoğunBakımdaYapılanReek splorasyonlar. Anadolu KardiyolDerg. 2004; 4(1): 19-22.

UNDER PEER REVIEW