

## **Abstract**

Lutembacher's syndrome (LS) is a very rare condition and is characterized by a congenital ostium secundum type atrial septal defect (OS-ASD) and an acquired mitral stenosis (MS) which is commonly rheumatic in origin, most common in females. Here we report a case of a 35-year-old male with Lutembacher's syndrome who underwent balloon mitral valvuloplasty (BMV) and device closure of the atrial septal defect (ASD). Previously the treatment preferred for patients with LS was surgical but in today's era, transcatheter intervention should be preferred in suitable patients. Because of the large ASD, BMV necessitated technical modification of taking the Accura balloon over the wire (OTW) into the left ventricle (LV), and also larger ASD device had to be used to prevent device embolization.

**Keywords:** Lutembacher's syndrome, atrial septal defect, mitral stenosis, BMV, Balloon manipulation, percutaneous intervention

## **Introduction**

Lutembacher syndrome (LS) was first described in a letter by anatomist Johann Friedrich Meckel in 1750. However, the first comprehensive account of these two defects was reported by a French physician Rene Lutembacher in 1916. The true incidence of Lutembacher's syndrome is not clearly known<sup>1</sup>. Lutembacher's syndrome (LS) is a very rare condition and is characterized by a congenital ostium secundum type atrial septal defect (OS-ASD) and an acquired mitral stenosis (MS) which is commonly rheumatic in origin<sup>2</sup>. The incidence of ASD in patients with mitral stenosis is 0.6-0.7%. Both the lesions in LS can be congenital or acquired. Congenital MS is a very rare entity accounting for only 0.6% of congenital heart disease. Assuming a relatively uniform incidence of ASD worldwide, the incidence of co-existing rheumatic MS depends on the geographic prevalence of RHD for this reason, it is reported more often in Southeast Asia. The syndrome can present at any age but is usually more common in young adults. There is a predilection for females because ASD and rheumatic MS are both more prevalent in females<sup>3</sup>, but in our case patient is a young male.

Although open heart surgery is still considered the treatment of choice to fix both conditions at the same time, it is associated with surgical complications, long hospital stay, sternotomy, skin scar, psychosocial effects and higher surgical risk if reoperation for mitral valve restenosis is necessary later<sup>4</sup>.

Here we report a case of a young male patient with Lutembacher's syndrome managed successfully with percutaneous transcatheter intervention in the same setting.

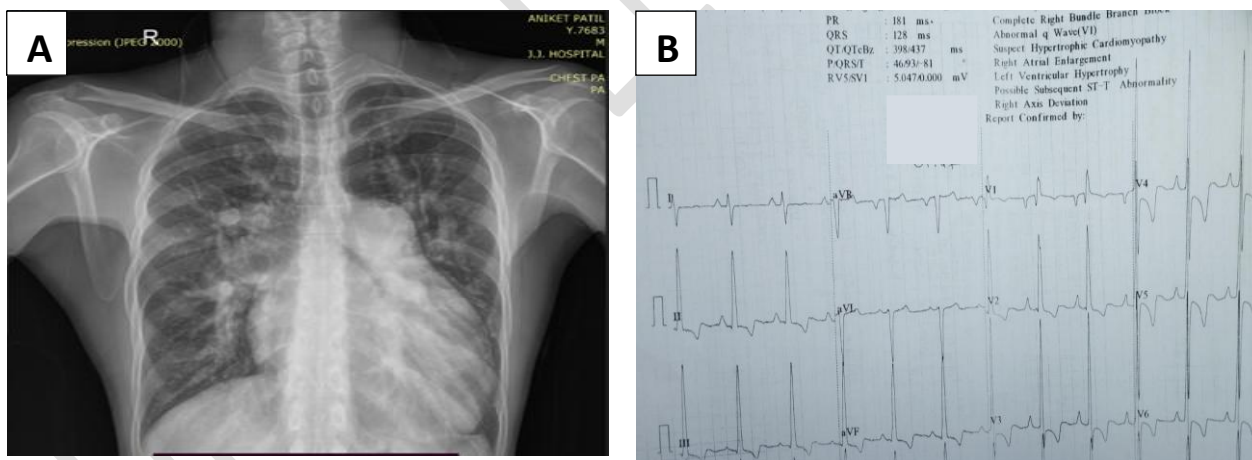
## Case report

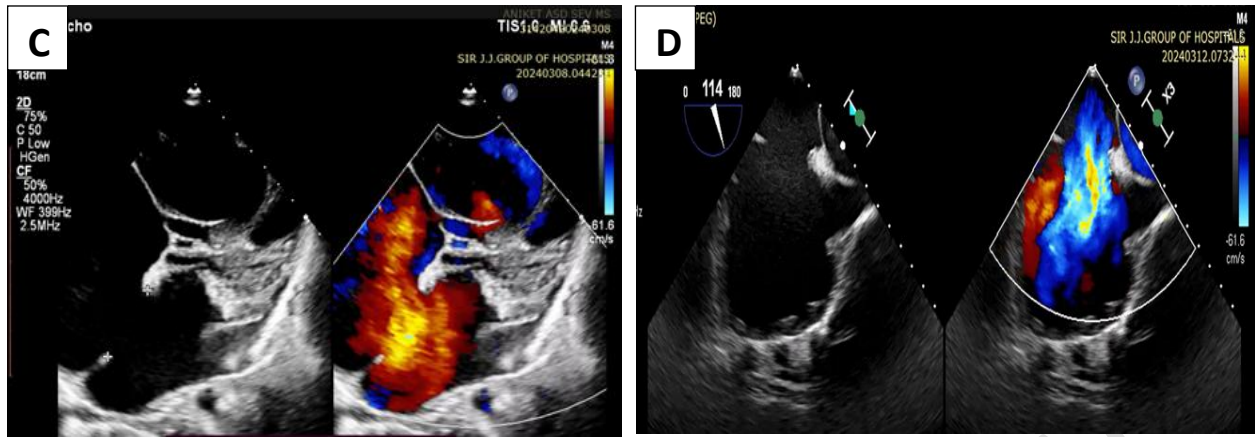
A 35-year-old male, presented with a history of dyspnoea on exertion in New York Heart Association (NYHA) class II since last 4 months. Physical examination revealed a loud first heart sound, wide and fixed split second heart sound, low pitch grade  $\frac{3}{4}$  mid-diastolic rumbling murmur at the apex, and lower left sternal border with grade 4/6 ejection systolic murmur in the left second parasternal region. Electrocardiogram (ECG) showed right axis deviation, incomplete right bundle branch block (RBBB) with Right atrial enlargement with RVH with strain pattern (Figure 1B). Chest X-ray findings showed increased pulmonary vascular markings with a prominent right pulmonary artery and straightening of the left heart border (Figure 1A).

Transthoracic echocardiography (TTE) showed a 35 mm OS-ASD with severe rheumatic MS (Figure 1C). The mitral valve area (MVA) was 1.3 cm<sup>2</sup> by planimetry with a peak by mean trans mitral gradient (TMG) of 18/9 mm of Hg with mild Mitral regurgitation. Color flow Doppler revealed a left-to-right shunt across the OS-ASD. There was severe tricuspid regurgitation (TR) with a pulmonary artery systolic pressure (PASP) of 121 mm Hg (Figures 1C, 2A & B).

Trans oesophageal echocardiography (TEE) was done which showed 36 mm OS-ASD with a left to right shunt, with adequate SVC, IVC, and aortic rim for device placement (Figure 1D). Severe MS with pliable Mitral valve with mild eccentric MR and no calcification noted, with Wilkins score of 6.

The ASD and MS were amenable to percutaneous treatment, hence PTMV and ASD device closure was planned and performed in a single setting.





**Figure 1.** (A) Chest X-ray PA view shows enlarged heart and prominent pulmonary arteries with congestion and straightening of left heart border; (B) ECG shows normal sinus rhythm with right axis deviation, incomplete RBBB, and right atrial enlargement with RVH and strain pattern.; (C) TTE showing OS ASD with the left to right shunt; (D) TEE image in bicaval view showing large OS ASD with good IVC rim.

## Technique

The procedure was undertaken after well-informed written consent from the patient.

The patient was loaded with 325 mg of aspirin 1 day prior to the procedure. After antibiotic prophylaxis, under mild sedation and local anesthesia, left femoral arterial and right femoral venous access was obtained, and 5,000 units of heparin were administered.

A pigtail catheter inserted through the left femoral artery and positioned in the ascending aorta. A 0.032" wire was inserted in the right femoral vein to inferior vena cava (IVC) to the right atrium (RA) to the left atrium (LA), and over 0.032 wire, Mullins trans septal introducer sheath placed in LA and pressures noted (mean gradient 24 mm of Hg), which was replaced by Zolbi wire and kept in LA.

Accura double lumen balloon dilatation catheter of size 26 mm crossed with some difficulty across the mitral valve into the left ventricle as there was no support for guiding the balloon due to large ASD, multiple premature ventricular contractions (PVCs) noted on the monitor, distal end of the balloon inflated first. The balloon slightly pulled back to place the waist of the balloon across the mitral valve opening followed by full inflation of the balloon to the predetermined size with successful dilation of the mitral valve with a significant reduction of mean TMG to 9/5 mm of Hg and area by planimetry of 2.2 cm<sup>2</sup> on TTE and no pericardial effusion or increase in MR noted (Figure 2C, D & 3A). Post BMV significant reduction in LA pressure was noted (mean gradient 4mm of Hg).

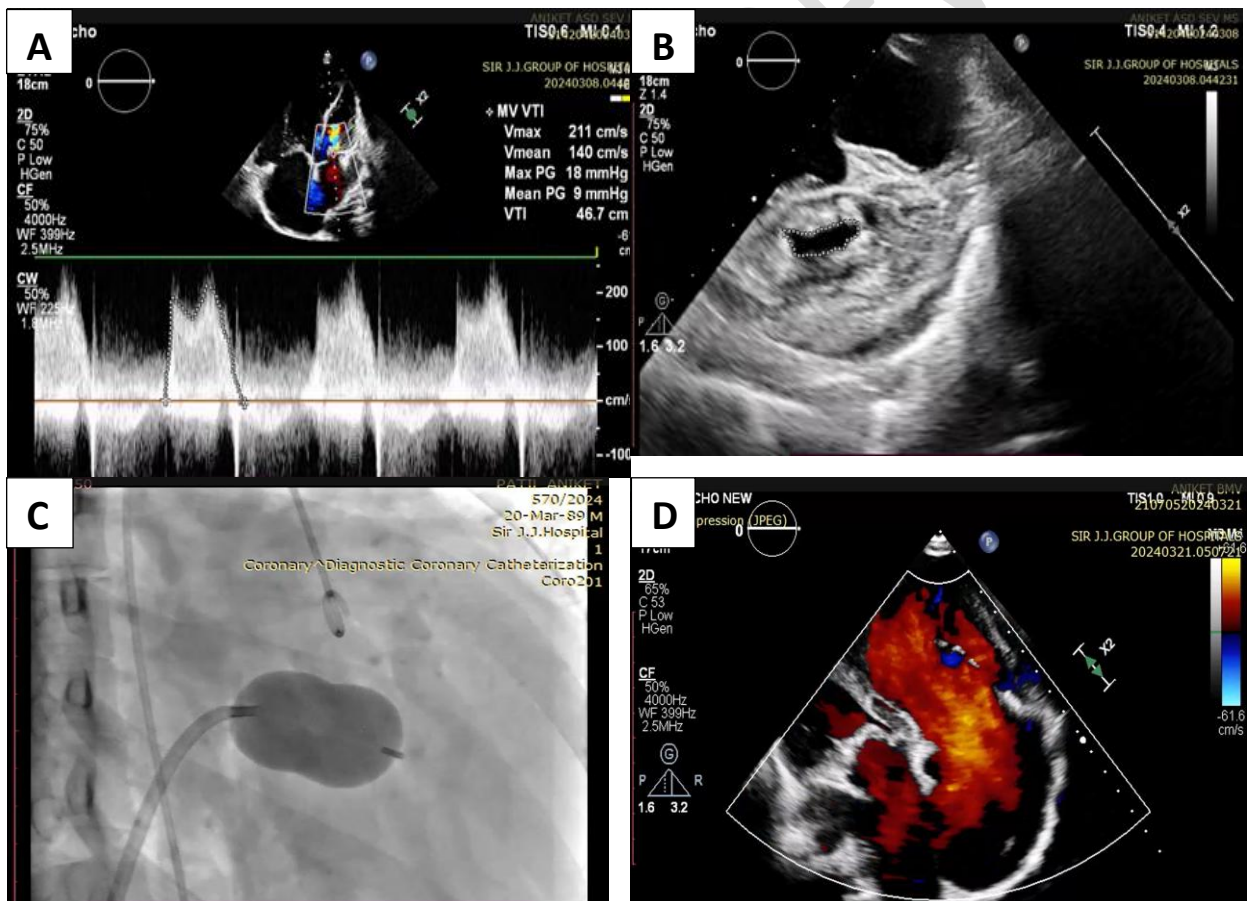
After successfully performing BMV, the ASD device closure was undertaken, and a multipurpose angiographic catheter (MPA2) passed into the right femoral vein to IVC to RA to the right ventricle (RV) to pulmonary artery pressures noted.

MPA2 catheter then passed from RA to LA and replaced with Amplatz super-stiff guidewire. 7F venous sheath replaced with 14 F Lifetech sheath. A Lifetech ASD device closure of size 44mm loaded in delivery cable and through the delivery system ASD device crossed through ASD, position confirmed under TTE and fluoroscopy followed by the release of the device in

place(Figure 3B,C). On TTE, the device was seen in situ with no residual shunt across the defect noted with no arrhythmia on ECG (Figure 3D).

## Discussion

The combination of congenital atrial septal defect and acquired mitral stenosis was described by Lutembacher in 1916<sup>5</sup>. This syndrome has a higher prevalence in women, likely due to the increased occurrence of ostium secundum ASD and rheumatic mitral stenosis in women. In patients with mitral stenosis who had undergone percutaneous balloon mitral valvuloplasty through the trans-septal approach, the later procedure created an ASD during the procedure, iatrogenic Lutembacher's syndrome. The incidence of atrial left to right shunt following percutaneous balloon mitral valvuloplasty has been reported to be 11% to 12%<sup>6</sup>. In most of these patients, the magnitude of the left to right shunt was small and the defect usually diminished or closed over time. In rare instances, the iatrogenic ASD might be hemodynamically significant enough to warrant intervention.



**Figure 2.** (A) Continuous wave doppler tracing on TTE showing the mean gradient across the mitral valve at initial evaluation; (B) planimetry-based MVA calculation in the stenosed valve with fused commissures (MVA 1.3 cm<sup>2</sup>); (C) Fluoroscopy image showing balloon dilatation (Accura balloon 26mm) of mitral valve; (D) Post BMV TTE shows a wide-open mitral valve with unobstructed transmitral flow during diastole.

The effect of ASD on MS causes the delayed appearance of high pulmonary venous pressure, and hence symptoms like dyspnoea, hemoptysis, and early increase of pulmonary arteriolar resistance. While the MS maintains the pressure gradients across the atria promoting left-to-right shunting till the late stages. The one hemodynamic complication of MS which is aggravated by atrial septal defect is low systemic output which improves after the appearance of pulmonary artery hypertension (PAH) which decreases the left to right shunting<sup>7</sup>.

Traditionally, this condition was corrected by surgical treatment<sup>8</sup>. With the introduction of transcatheter closure of ASD and percutaneous balloon mitral valvuloplasty, Lutembacher's syndrome can then be treated percutaneously<sup>9,10</sup>.

However, the interventional procedure is, not simply a combination of two simple procedures, that is, BMV and ASD device closure, as the coexisting anomalies change the cardiac anatomy in a way that makes catheter manipulation complex<sup>11</sup>. Due to large ASD, there is a lack of support for the PTMC balloon crossing the mitral valve can be a challenging task, and various techniques are then required e.g. OTW technique, balloon flotation, catheter sliding technique, etc. The use of percutaneous treatment of Lutembacher's syndrome was first described by Ruiz and colleagues in 1992<sup>12</sup>. Ruiz and colleagues used Lock's clamshell occluder and double-balloon mitral and aortic valvotomies performed as a palliative rescue procedure in a patient with Lutembacher's syndrome and severe pulmonary hypertension to improve risk prior to surgical therapy.

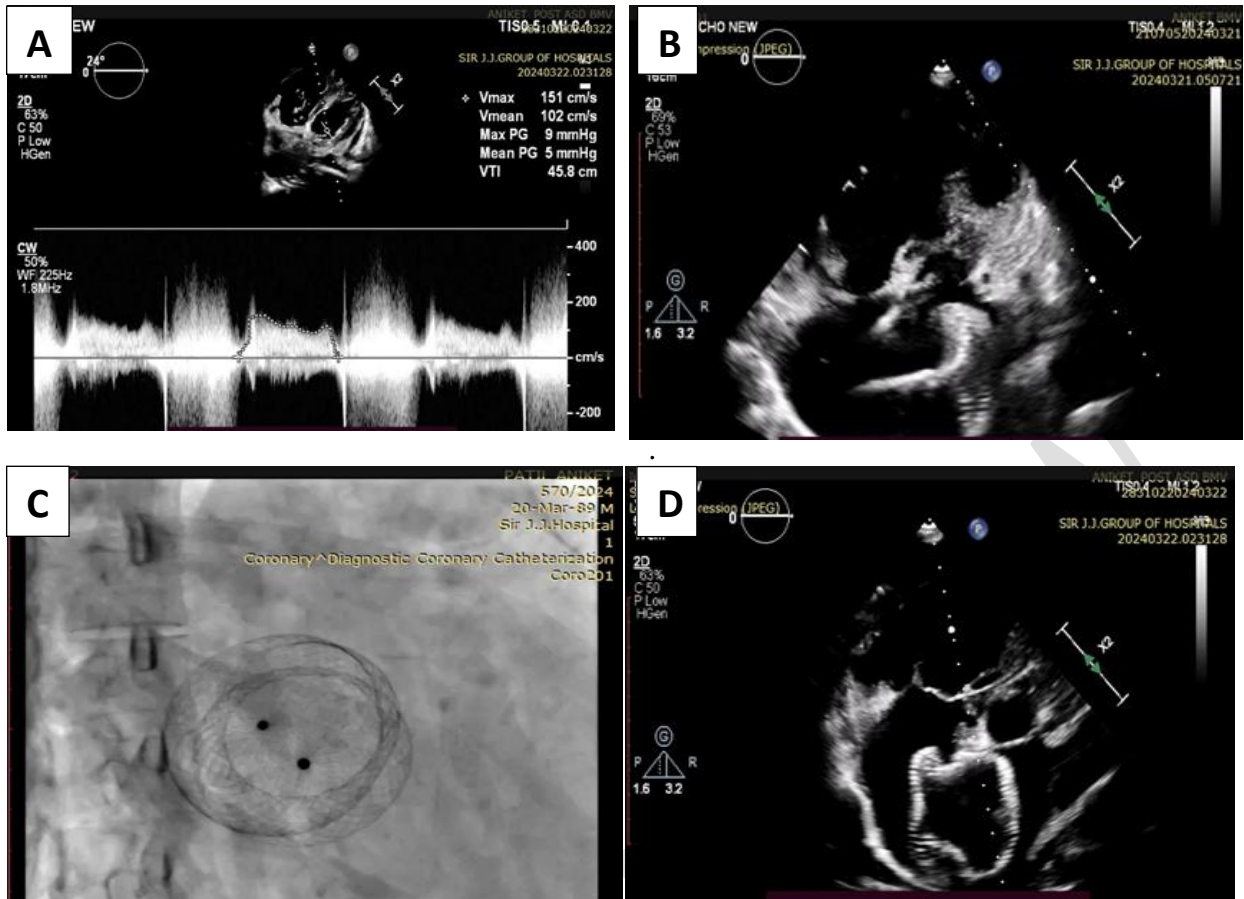
In 1999, Joseph and colleagues<sup>13</sup> described the procedure of percutaneous treatment of Lutembacher syndrome with a 16mm Amplatzer septal occluder and a 25-mm-diameter cylindrical single balloon. The likelihood of mitral restenosis occurring still exists; the presence of the ASD occluder may make it undesirable to use the transseptal approach in repeated mitral valvuloplasty. The retrograde nontransseptal approach may be an option in these patients<sup>14</sup>.

### **Follow up**

At 3 months of follow-up, the patient was asymptomatic (NYHA I) and was able to do all routine activities without discomfort. TTE showed a mean gradient of 5 mm of Hg across the mitral valve with ASD device in situ with no residual shunt across it.

### **Conclusion**

Percutaneous treatment of Lutembacher syndrome is feasible in suitable patients, the procedure can be safely and effectively carried out and should be considered as an alternative to surgical therapy.



**Figure 3.** (A) Continuous wave Doppler tracing post-BMV showing significant reduction in TMG; (B) TTE image showing the placement of ASD device ring on the LA side with a delivery cable attached; (C) Fluoroscopy image showing large ASD device (44 mm) post-deployment across ASD; (D) TTE showing ASD device in position across ASD.

### Learning Objectives

In patients with Lutembacher syndrome, the BMV procedure can be complex with difficulties in stabilizing the balloon across the stenosed mitral valve. A careful assessment of device size with the help of either TEE or conventional balloon sizing and choosing a larger device is recommended to prevent device embolization.

## Abbreviations:

LS-Lutembacher's syndrome  
BMV- Balloon Mitral Valvuloplasty  
RHD- Rheumatic Heart Disease  
OS-ASD-Ostium Secundum Atrial Septal Defect  
NYHA- New York Heart Association  
OS- Opening Snap  
TTE-TransThoracic Echocardiography  
TEE-TransEsophageal Echocardiography  
ECG- Electrocardiogram  
MVA-Mitral Valve Area  
MPA- MultiPurposeAngiographic catheter  
IVC-Inferior Vena Cava  
SVC- Superior Vena Cava  
F-French unit  
AP-anteroposterior  
PA- Posteroanterior  
LAO- Left Anterior Oblique  
LA- Left Atrium  
LV- Left Ventricle  
MS- Mitral Stenosis  
IAS-Inter Atrial septum  
OTW- Over the wire  
RBBB-Right bundle branch block  
TMG-Trans mitral gradient

## References

1. Mahajan K, Oliver TI. Lutembacher Syndrome. 2023 Mar 6. In: StatPearls [Internet]. Treasure Island (FL): StatPearls Publishing; 2024 Jan.
2. Perloff JK. Atrial septal defect: simple and complex. In: Perloff JK, ed. *The Clinical Recognition of Congenital Heart Disease*. 4th ed. W.B. Saunders; 1994:293–380.
3. Sandhya S. Kulkarni, Amit K. Sakaria, Sanket K. Mahajan, Kuldeep B. Shah. Lutembacher's syndrome. *Journal of Cardiovascular Disease Research*. Volume 3, Issue 2, 2012, Pages 179-181.
4. Phan, Quang Tan, Hieu Lan Nguyen, Tai Duc Le, WangSoo Lee, HoYoun Won, SeungYong Shin, Saima Sharmin, Truong Quang Nguyen, & SangWook Kim. "Combined Percutaneous Procedure in Patient with Lutembacher Syndrome: A Case Report and Real-World Experience Review." *Cardiology Research* [Online], 9.6 (2018): 385-391.
5. Lutembacher R. De la stenose mitrale avec communication interauriculaire. *Arch Mal Coeur* 1916;9:237.
6. Cheng TO. Percutaneous balloon valvuloplasty. New York: Igakushion; 1992:269.
7. Nadkarni P, Viegas Parab M, Naik G. Percutaneous Transcatheter Therapy in a Case of Lutembacher's Syndrome. *Indian Journal of Clinical Cardiology*. 2024;0(0).

8. John S, Munshi SC, Bhati BS, et al. Coexistent mitral valve disease with left-to-right shunt at the atrial level: results of surgical treatment in 15 cases. *J Thorac Cardiovas Surg* 1970;60:174-187.
9. King TD, Mills NL. Nonoperative closure of atrial septal defects. *Surgery* 1974;75: 383-388.
10. Inoue K, Owaki T, Nakamura T, et al. Clinical application of transvenous mitral commissurotomy by a new balloon catheter. *J Thorac Cardiovasc Surg* 1984; 87: 394-402.
11. Vadivelu R, Chakraborty S, Bagga S. Transcatheter therapy for Lutembacher's syndrome: The road less traveled. *Ann Pediatr Card* 2014;7:37-40.
12. Ruiz CE, Gamra H, Mahrer P, et al. Percutaneous closure of a secundum atrial septal defect and double balloon valvotomies of a severe mitral and aortic valve stenosis in a patient with Lutembacher's syndrome and severe pulmonary hypertension. *Cathet Cardiovasc Diagn* 1992; 25 : 309-312.
13. Joseph G, Abhaichand Rajpal K, Kumar KP. Definitive percutaneous treatment of Lutembacher's syndrome. *Cathet Cardiovasc Interv* 1999;48:199-204.
14. Stefanidis C, Stratos C, Pitsavos C, et al. Retrograde non transseptal balloon mitral valvuloplasty : immediate results and long-term follow-up. *Circulation* 1992 ; 85 : 1760-1767.