

A challenging case of percutaneous mitral balloon valvuloplasty in a patient with situs inversus dextrocardia

Abstract

Situs inversus with dextrocardia is a rare congenital disorder. There is a rare coincidence of rheumatic severe mitral stenosis in a patient with situs inversus and dextrocardia. Most of these patients undergo surgery due to technical difficulty, here we report a case of a 41-year-old male managed successfully with PMBV.

Keywords:

Dextrocardia; Rheumatic mitral stenosis; Inoue technique; Percutaneous mitral balloon valvuloplasty; Situs inversus totalis.

Introduction

Situs inversus totalis refers to the heart being a mirror image situated on the right side with all visceral organs to be mirrored with incidence of approximately 1 in 12,000 people¹. Distorted cardiac anatomy makes fluoroscopy guided transcatheter procedures difficult which become technically more challenging in the cases with percutaneous mitral balloon valvuloplasty (PMBV), where the cardiac malpositions substantially increase the complications beginning from interatrial septal puncture to left ventricular entry [11-13]. There are very few reports on successful percutaneous mitral balloon valvuloplasty (PMBV) in an abnormal cardiac anatomy using the standard Inoue technique²⁻⁷. Here we describe a case of a 41-year-old male with situs inversus totalis, where PMBV was successfully performed with slight modifications of the standard Inoue technique.

Case Report

A 41-year-old male patient presented with progressive exertional dyspnoea NYHA class II of 6 months duration which has recently progressed to NYHA class III. Blood pressure was 110/70 mm Hg in the right arm in supine position. Pulse rate was 76/min, irregular, low volume, with no special character with all peripheral pulses palpable. Jugular venous pressure was elevated with absent a wave.

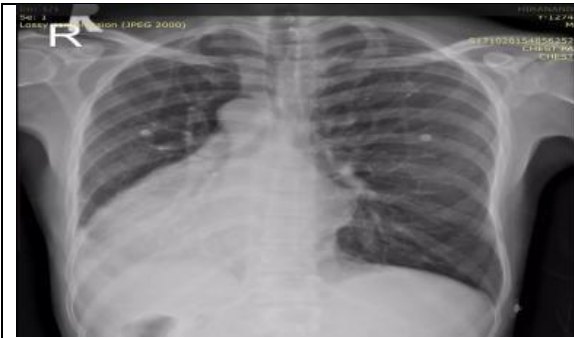

Figure 1. Chest X-ray PA view showing dextrocardia with cardiomegaly with straightening of right heart border with gastric air bubble on right side.

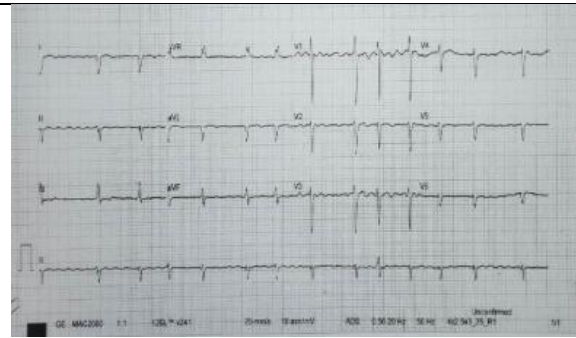


Figure 2. ECG showing Atrial flutter with variable block with right axis deviation with positive R wave in lead aVR .

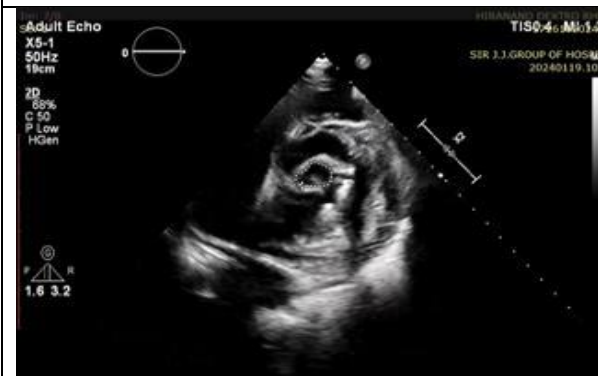

Figure 3. 2D TTE image showing mitral valve area by planimetry of 0.9 cm^2

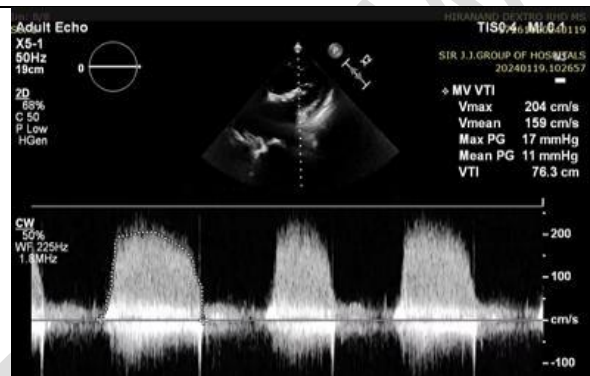


Figure 4. 2D TTE image showing peak by mean trans-mitral gradient of 17/11 mm of Hg.

Apex beat was located in right fifth intercostal space, tapping in character. There was grade II right parasternal heave. P_2 was palpable. S_1 was varying intensity. S_2 was loud; loud P_2 component with narrow split. Opening snap (OS) was present with narrow A_2 -OS gap. There was long grade IV mid diastolic rumbling murmur without presystolic accentuation. Pan systolic murmur grade III/VI of tricuspid regurgitation was present in right parasternal area. The electrocardiograph (ECG) showed atrial flutter with variable block, upright R wave in aVR, reduction in the R wave voltage across the chest leads with evidence of right ventricular hypertrophy (Figure 2). Chest X-ray PA view showed dextrocardia with situs inversus (Figure 1). 2D Transthoracic echocardiography (TTE) showed severe mitral stenosis with mitral valve area (MVA) of 0.9 cm^2 by planimetry (Figure 3,4) and mild mitral and aortic regurgitation with moderate functional tricuspid regurgitation. The gradient across mitral valve was peak 17 and mean 11 mm Hg, with Wilkin's score of 7/16. Transesophageal echo (TEE) ruled out any left atrial or appendage clot

Procedure

After well-informed consent, under local anaesthesia with mild sedation, right femoral artery, vein and left femoral venous access was obtained with a 7 French (7F) arterial and venous sheath. A 6F pigtail catheter was inserted retrograde into the aorta and placed in to the aortic root (Figure 5). A 6F Multipurpose Angiographic catheter (MPA) was inserted via right femoral venous sheath, placed in right pulmonary artery and pressure noted. A 0.035" J-tip guide wire was then passed up the left femoral vein into the inferior vena cava (IVC) and up into the left-sided superior vena cava (SVC) via the left-sided right atrium (Figure 6). 7F left femoral venous

sheath removed and 8F Mullins sheath was inserted on the guide wire, into the left SVC. A curved Brockenbrough septal puncture needle was introduced into the sheath stopping just before the tip and was oriented to 9 o'clock position in the SVC. Septal descent of septal puncture needle was performed in the AP view with the needle rotated from 12 o'clock to 9 o'clock position. The right border of the spine was used as a landmark for trans-septal puncture with a site midway between pigtail catheter and spine (Figure 7). Septal puncture was done in anteroposterior (AP) view and also confirmed in left lateral projection which was contrary to a conventional left anterior oblique (LAO) 40° view. Trans oesophageal echocardiography (TEE) was in place to guide the septal puncture in mid oesophageal 90° bi-caval view. A check shoot was taken from Mullin's sheath to confirm its position inside left atrium (LA) (Figure 9).

A "loopy" LA wire was then passed through the sheath inside LA (Figure 10). The septum was dilated with 14 F septal dilator (Figure11) and heparin 70 IU/kg IV was given. Subsequently, the Accura balloon of size 26 was introduced over the loopy LA wire inside the LA (Figure12). The LA wire was then withdrawn and the balloon was flushed and simultaneous LA and left ventricle (LV) pressures were recorded. Now, a shaper guide wire was used to guide the balloon towards mitral valve by slight counter clock rotation till a bobbing motion at the balloon tip was noted (Figure13). Shaper guide wire was pulled and balloon was pushed to facilitate its entry into the LV (Figure14). Mitral valve was negotiated and multiple sequential balloon inflation given in LAO 27° projection (Figure 15,16,17). Post-procedural LA pressure reduced from 24 to 9 mm of Hg, 2D TTE was suggestive of MVA was 1.9 cm², peak/mean trans-mitral gradient of 14/5 mm of Hg with split lateral commissure and mild MR and no pericardial effusions (Figure18,19). Patient was then shifted to monitoring ward.

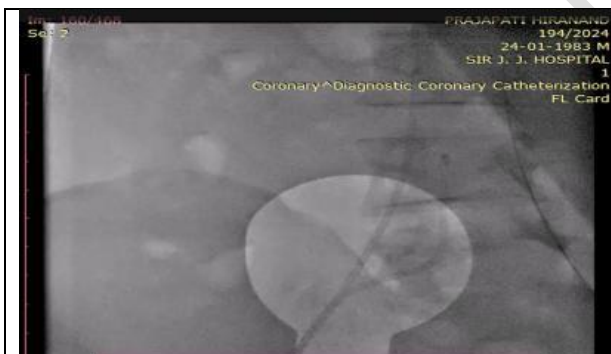


Figure 5. Fluoroscopy image (AP view) showing Right femoral arterial and venous cannulation with pigtail and MPA and left femoral vein cannulation with 0.035" J-tip guide wire for Mullin's sheath insertion and septal puncture .

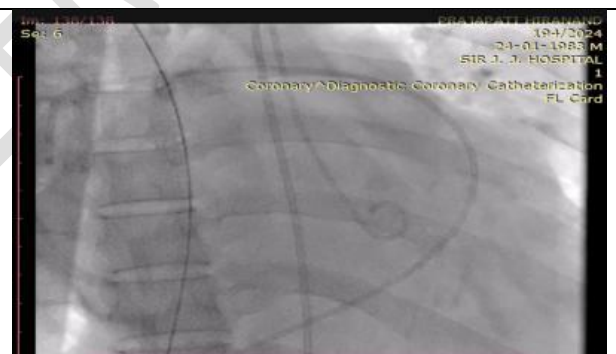

Figure 6. Fluoroscopy mirror image (AP view) showing pigtail positioned in ascending aorta , MPA placed in right pulmonary artery and 0.035" J-tip guide wire for Mullin's sheath insertion placed in left sided superior vena cava.

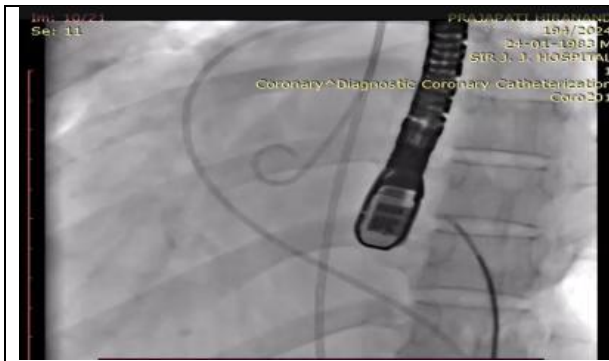

Figure 7. Fluoroscopy image (AP view) showing 8F Mullin's sheath with Brockenbrough septal puncture needle oriented to 9 o'clock position.

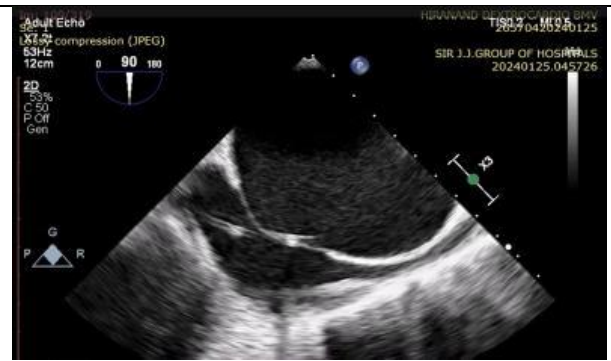

Figure 8. TEE image (mid oesophageal 90° bicaval view) showing Mullin's sheath with Brockenbrough septal puncture needle pointed at IAS.

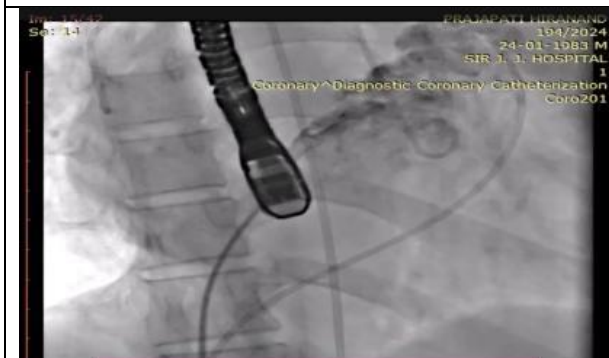

Figure 9. Fluoroscopy mirror image (AP view) showing shoot is being taken from Mullin's sheath to confirm LA

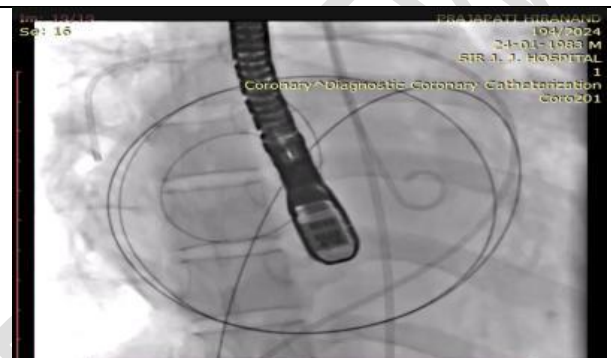

Figure 10. Fluoroscopy image (AP view) showing looped wire kept in LA.

But, despite all the precautions, 5 hours after the procedure patient had an episode of syncope due to Brady-arrhythmia and hypotension, bedside echo was suggestive of tamponade (Figure 18). Emergency peri-cardiocentesis was done 120 ml of haemorrhagic fluid drained, patient continuously monitored, but there was no refilling, patient stabilised. Patient was discharged after 3 days.

Discussion

Mirror-image dextrocardia has been estimated to occur with a prevalence of 1:10,000 patients. There are only a few reported cases of PMBV in patients with dextrocardia and situs inversus². Whether, this reflects the tendency to avoid transseptal puncture and PMBV in these technically difficult cases, thus referring them to cardiac surgeons for mitral valve replacement is open to speculation. In general, anatomical variations of the heart are considered relative contraindications for transseptal catheterization, as it is thought to have a higher risk of cardiac perforation. Over time various modifications of the standard Inoue technique have evolved and are being used by different operators to suit the needs of these patients with uncharacteristic cardiac anatomy. The problem has been addressed in pregnancy with successful PMBV in anatomically challenging hearts³. As in this case, transseptal catheterization is performed from the left groin to reduce the puncture needle angulations at the confluence of the iliac veins to the left-sided inferior vena cava⁴. The catheter placed in the non-coronary aortic sinus marks the antero-superior limit of the IAS. Septal descent is done by rotating the external indicator of the needle at the 7-9 O'clock position²⁻⁵.

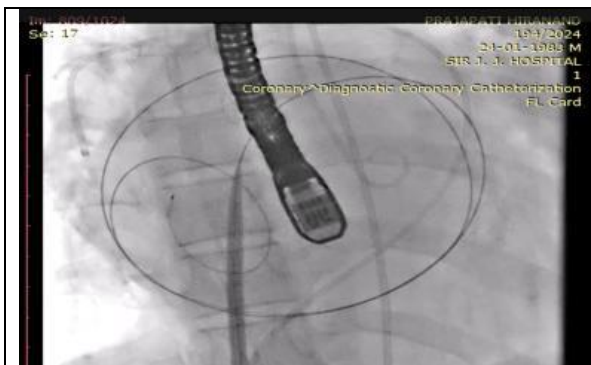

Figure 11. Fluoroscopy image (AP view) showing 14F dilator across the septum

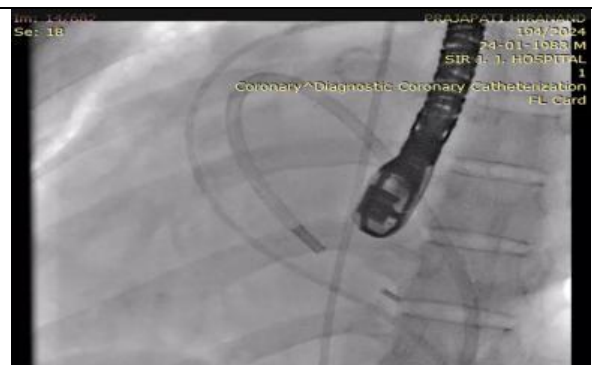

Figure 12. Fluoroscopy image (AP view) showing Accura balloon inside LA.

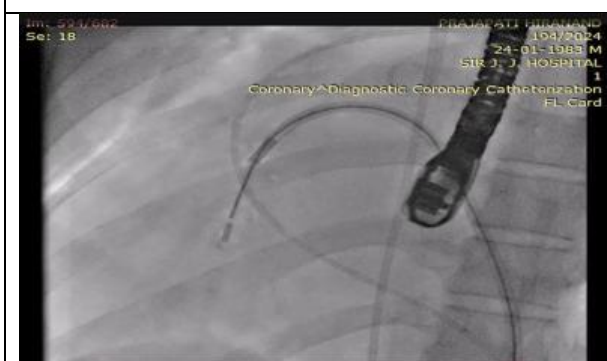

Figure 13. Fluoroscopy image (AP view), a shaper guide wire was inserted.

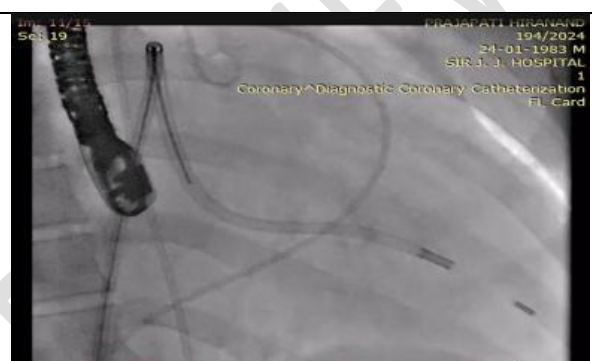

Figure 14. Fluoroscopy mirror image (LAO 13 view) showing Accura balloon in LV cavity.

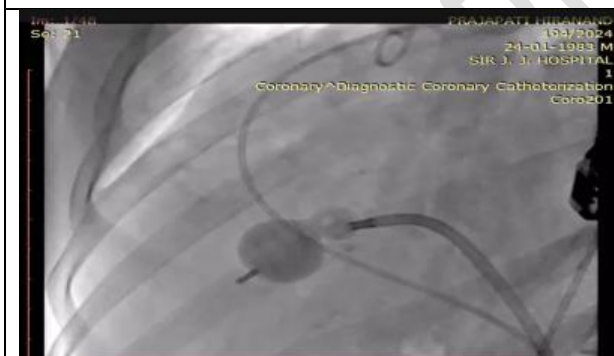

Figure 15. Fluoroscopy image (LAO 27) showing balloon inflation of distal end.

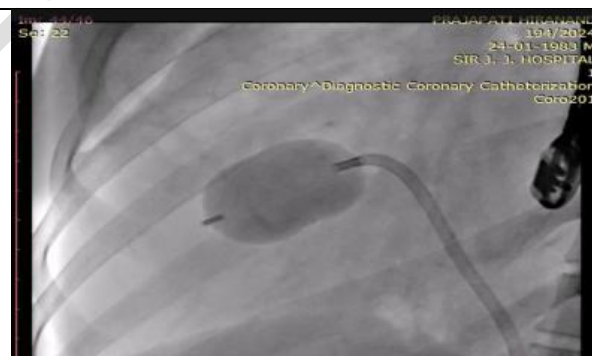

Figure 16. Fluoroscopy image (LAO 27) Showing complete balloon inflation across the mitral valve.

The radiographic images acquired in the inverted position can be used as fluoroscopic guidance for the septal puncture, as previously described by Nallet et al² and facilitates balloon entry into the LA, and its depth can be confirmed by contrast staining into the left atrium, pressure measurement and can be of additional use in the presence of the septal aneurysm^{2,4,8}. This also aids in confirming the limits of the interatrial septum. Levophase pulmonary angiography has been used for IAS delineation in a patient with isolated dextrocardia and normal atrial situs⁶. Transesophageal and intracardiac echo are important adjunctive pathfinders for interventional cases as complex as this^{2,7}. The trans jugular approach is thought to overcome many of the technical problems encountered with the trans femoral route in cases with anatomical alterations⁸.

Despite the challenging anatomy, PMBV has been demonstrated to be a safe and feasible option for MS in patients with unusual cardiac anatomy^{9,10}.

But, close monitoring of such patients need to be done post procedure for at least 12 hours and the operator must be prepared for any such unwanted complications (as in our case tamponade) that may occur despite the precautions taken during the procedure.

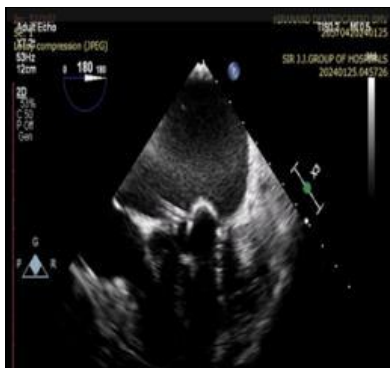

Figure 17. TEE (mid oesophageal 180° view) image showing inflated balloon across mitral valve.

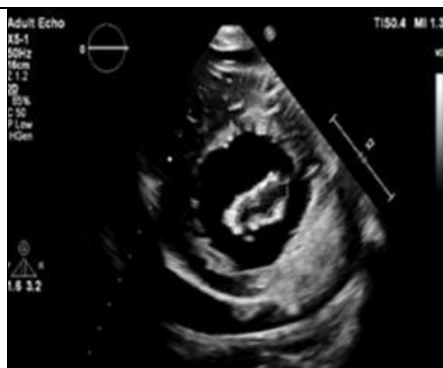


Figure 18. 2D TTE image showing mitral valve area by planimetry of 1.9 cm² with pericardial effusion.

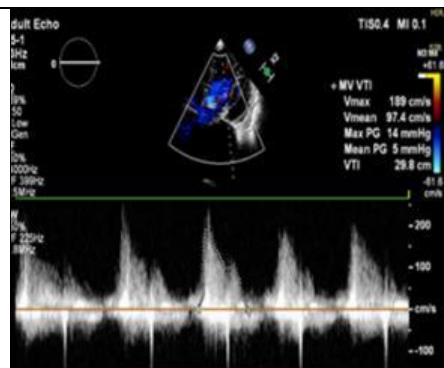


Figure 19. 2D TTE image showing significant reduction in peak by mean trans-mitral gradient to 14/5 mm of Hg.

Follow up

At 3 months of follow-up, the patient was asymptomatic (NYHA I) and was able to do all routine activities. TTE showed mild MS with a mean gradient of 5 mm of Hg with no evidence of pericardial effusion or LA clot.

Conclusion

In summary, PMBV is possible in patients with dextrocardia by modifying the Inoue technique and following specific protocols for groin and septal puncture.

Learning Objectives

List 1 : Here are some technical modifications to keep in mind when performing PMBV in patients with dextrocardia

Steps	Conventional PMBV	PMBV in dextrocardia
Trans-septal catheterization	Right groin	Left groin
Descent of needle assembly	4 - 6 o'clock position	7 -9 o'clock position

Septal puncture	AP view LAO view	Pseudo AP view RAO view
Crossing of mitral valve and balloon dilatation	RAO view	LAO view

Abbreviations:

PMBV- Percutaneous Mitral Balloon Valvuloplasty

NYHA- New York Heart Association

OS- Opening Snap

TTE- TransThoracic Echocardiography

TEE- TransEsophageal Echocardiography

ECG- Electrocardiogram

MVA-Mitral Valve Area

MPA- MultiPurpose Angiographic catheter

IVC-Inferior Vena Cava

SVC- Superior Vena Cava

F-French unit

AP-anteroposterior

PA- Posteroanterior

LAO- Left Anterior Oblique

LA- Left Atrium

LV- Left Ventricle

MS- Mitral Stenosis

IAS-Inter Atrial septum

RHD- Rheumatic Heart Disease

References

1. Sinha, S., Thakur, R., Jha, M., Sayal, K., Sachan, M., Krishna, V., Kumar, A., Mishra, V., Varma, C. Percutaneous Mitral Valvotomy in a Case of Situs Inversus Totalis and Juvenile Rheumatic Critical Mitral Stenosis: Case Report. *Journal of Clinical Medicine Research, North America*, 8, feb. 2016.
2. Nallet O, Lung B, Cormier B, Porte JM, Garbarz E, Michel PL, et al. Specifics of technique in percutaneous mitral commissurotomy in a case of dextrocardia and situs inversus with mitral stenosis. *Cathet Cardiovasc Diagn* 1996; 39:85-8.
3. Said SA, Veerbeek A, van der Wieken LR. Dextrocardia, situs inversus and severe mitral stenosis in a pregnant woman: successful closed commissurotomy. *Eur Heart J* 1991; 12:825-8.
4. Namboodiri N, Harikrishnan SP, Ajitkumar V, Tharakan JA. Percutaneous mitral commissurotomy in a case of mirror-image dextrocardia and rheumatic mitral stenosis. *J Invasive Cardiol* 2008; 20:E33-5.
5. Chow WH, Fan K, Chow TC. Balloon mitral commissurotomy in a patient with situs inversus and dextrocardia. *J Heart Valve Dis* 1996; 5:307-8.
6. Verma PK, Bali HK, Suresh PV, Varma JS. Balloon mitral valvotomy using Inoue technique in a patient of isolated dextrocardia with rheumatic mitral stenosis. *Indian Heart J* 1999;51:315-7.
7. Shalghanov TN, Paprika D, Borbás S, Temesvári A, Szili-Török T. Preventing complicated transseptal puncture with intracardiac echocardiography: case report. *Cardiovasc Ultrasound* 2005; 1:3-5.
8. Joseph G, George OK, Mandalay A, Sathe S. Transjugular approach to balloon mitral valvuloplasty helps overcome impediments caused by anatomical alterations. *Catheter Cardiovasc Interv* 2002; 57: 353-62.
9. Patel TM, Dani SI, Thakore SB, Chaq MC, Shah SC, Shah UG, et al. Balloon mitral and aortic valvuloplasty in mirror-image dextrocardia. *J Invasive Cardiol* 1996; 8:164-8.
10. Raju R, Singh S, Kumar P, Rao S, Kapoor S, Raju BS. Percutaneous balloon valvuloplasty in mirror-image dextrocardia and rheumatic mitral stenosis. *Cathet Cardiovasc Diagn* 1993; 30:138-40.
11. Munde, K. S., Jalkote, S. K., & Niari, J. (2023). Killing Two Birds in One Stone- Percutaneous Treatment of a Large ASD and Pulmonary Stenosis in the Same Setting in an Adult Patient-a Case Report. *Cardiology and Angiology: An International Journal*, 12(4), 358–362. <https://doi.org/10.9734/ca/2023/v12i4379>
12. Ahmed Elsaka, O. M. R. M., & Elsaka, O. (2021). Percutaneous Mitral Balloon Valvuloplasty: Technique and Results. *Asian Journal of Medicine and Health*, 19(10), 124–132. <https://doi.org/10.9734/ajmah/2021/v19i1030388>
13. Soulatges C, Momeni M, Zarrouk N, Moniotte S, Carbonez K, Barrea C, Rubay J, Poncelet A, Sluysmans T. Long-term results of balloon valvuloplasty as primary treatment for congenital aortic valve stenosis: a 20-year review. *Pediatric cardiology*. 2015 Aug;36:1145-52.