

## Pseudocyesis Explored: A Detailed Review of Associated Psychiatric Disorders.

Abstract :

**Background:** Pseudocyesis (or pseudocyesis vera) also known as “phantom pregnancy” was previously described according to the Diagnostic and Statistical Manual of Mental Disorders (DSM-5) as a false belief of being pregnant that is associated with objective signs and reported symptoms of pregnancy. The exact etiology and management of this rare disorder are not known but certain factors have been associated with this including the presence of certain psychiatric conditions.

**Objective:** This study aims to provide a better understanding of the factors associated with pseudocyesis including psychiatric disorders and available treatment modalities.

**Materials and Methods:** A comprehensive review of literature on pseudocyesis in humans and its association with various psychiatric conditions. Available articles published from 1970 to January 2021 were included. Relevant articles from Google Scholar, PubMed, ScienceDirect, and Web of Science were reviewed.

**Results:** According to our review, it has been found that various social and cultural factors such as strong cultural views on the need for childbearing as prerequisite for womanhood have led to the manifestation of this condition. The etiology of pseudocyesis is associated with various psychological and endocrine disturbances sometimes mediated by psychosomatic disorders.

**Conclusion:** Pseudocyesis could be associated with psychiatric conditions such as major depression, schizophrenia, bipolar disorder, hypomania, and post-traumatic stress disorder. The treatment options may vary according to the presence of co-morbidities in different patients. Adopting a multidisciplinary approach encompassing gynecologists, psychologists and psychiatrists, is important in providing holistic care for this group of patients.

**Keywords:** Pseudocyesis, false pregnancy, psychiatric disorders, schizophrenia, phantom pregnancy.

### Introduction

Pseudocyesis (or pseudocyesis vera) also known as “phantom pregnancy” was previously described according to the Diagnostic and Statistical Manual of Mental Disorders (DSM-5) as a false belief of being pregnant that is associated with objective signs and reported symptoms of pregnancy, which may include abdominal enlargement, reduced menstrual

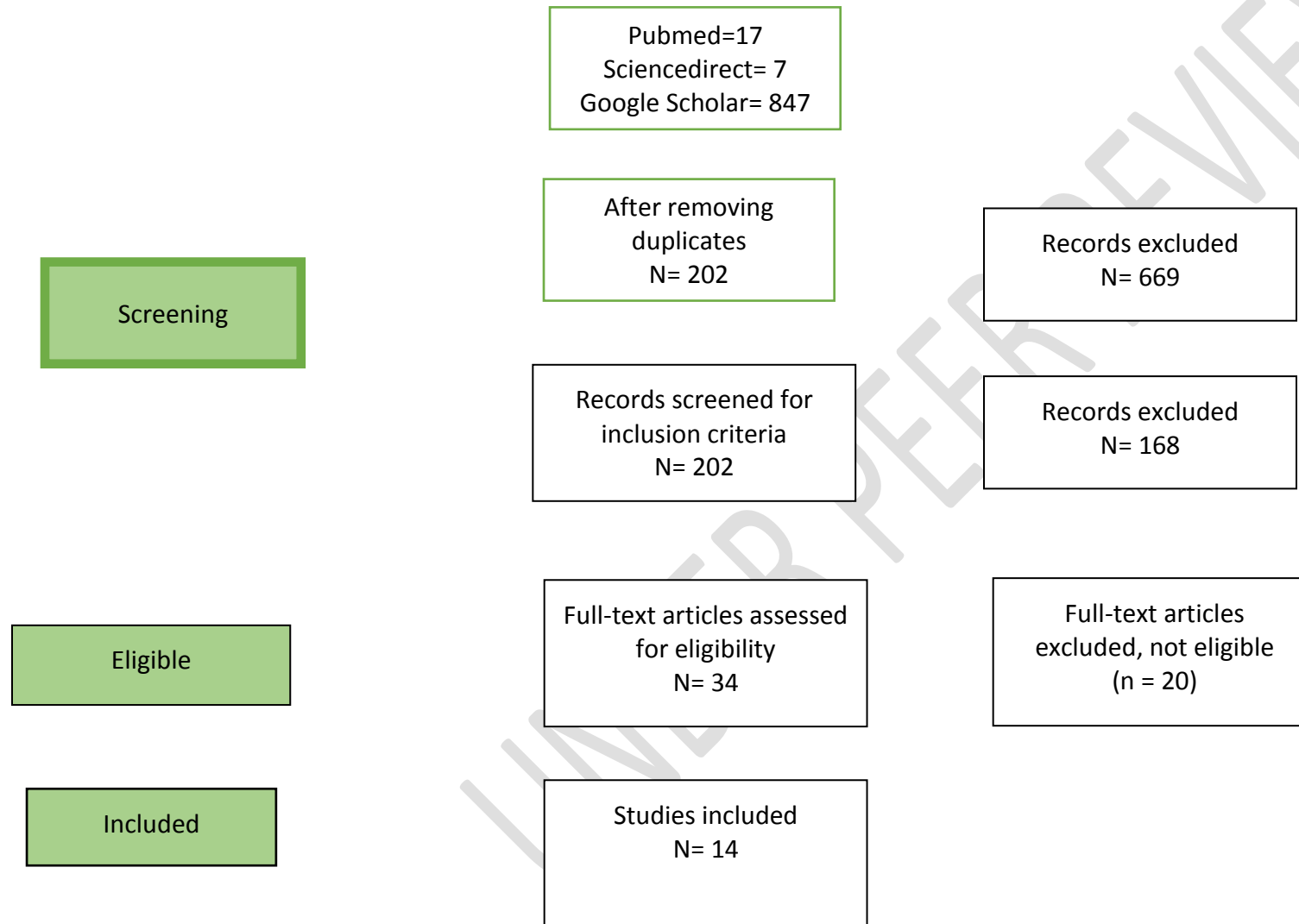
flow, amenorrhea, subjective sensation of fetal movement, nausea, breast engorgement and secretions, and labor pains at the expected date of delivery. It is derived from the Greek words: pseudēs= false, and kyçsis= pregnancy [1,2]. Pseudocyesis is a rare disorder that has been reported in all races, countries, and among various social statuses [2]. Reliable, specific information about pseudocyesis prevalence has not been compiled, though almost six hundred case reports have been documented globally [3,4]. Cases of pseudocyesis have been reported from the days of Hippocrates, back in 300 BC. It was reported that the Queen of England was a historical example who twice falsely believed that she was pregnant [5,6].

Published articles describe pseudocyesis as a multifactorial disorder where neuroendocrine disorders, social, psychodynamic, and cultural issues, as well as psychiatric factors contribute to its evolution [3]. However, no definitive etiology has been found. Numerous cases have reported the presence of psychiatric conditions such as major depressive disorder, psychotic disorders, bipolar disorder, anxiety disorders, and personality disorders among patients presenting with pseudocyesis [3,6,7,10]. Depression has also been strongly reported to play a major role in the development of pseudocyesis [11]. Koic et al. suggested that pseudocyesis can also be the first manifestation of psychosis [12]. Pseudocyesis has captured the attention of both the clinical and research communities for decades. However, only a few cases of pseudocyesis have been reported worldwide, with none having explored the association with psychiatric conditions.

### **Methodology**

This review article was done on the available literature reporting any psychiatric disorders and psychological factors in patients with pseudocyesis, the epidemiology, etiology, and methods of treatment in humans only. Relevant articles from PubMed, ScienceDirect, and Google Scholar were reviewed. Bibliographies of the selected articles were explored to identify additional relevant articles. Available case reports, case series, letters to the editor, and original articles published from 1970 to January 2021, reporting on human subjects, were included. The searches were identified using the keywords: Pseudocyesis, Psychiatric conditions, and false pregnancy. All review articles and studies on non-human species were excluded.

Flow chart 1: Prisma Flowchart



## Result

In this review, we found 14 eligible articles in the form of case reports, letters to editors, case series, and original research that discussed pseudocyesis in relation to psychiatric conditions. The summary of the findings from the case reports, letters to the editor, and case series are presented in table 1. The two original studies in table 2 included one retrospective study of 20 patients in Brazil and one prospective study of 25 patients in Nigeria. The retrospective study by Caixeta et al. reported neuropsychiatric conditions found among pseudocyesis patients which included affective disorders (45%) and psychotic disorders (45%) [13]. The nature of the association was however not provided.

Table No. 1: Case reports, case series, and letters to the editor with various psychiatric disorders associated with Pseudocyesis.

S/N	Authors (Year)	Type of Study	Associated Psychiatric and Psychological Conditions	Nature of Association	Other information	Interventions
1.	Amit B. Nagdive et.al 2021 [14]	Case report	Intermittent auditory hallucination.	Auditory hallucination and delusion (Folie-à-deux) co-occurring with signs of pregnancy.	<ul style="list-style-type: none"><li>-History of multiple spontaneous abortions.</li><li>- Pressure from family to have a baby.</li><li>-The patient and her spouse had a deep desire to have a baby.</li><li>-Husband also claimed he could hear faint sounds that he believed were coming from the baby.</li></ul>	<ul style="list-style-type: none"><li>-The patient was managed with quetiapine, which was titrated to 600 mg over 3 weeks, plus psychotherapy.</li><li>-The patient's husband was treated with olanzapine which was titrated to 15 mg plus psychotherapy.</li></ul>

2.	Espiridion, Eduardo D et.al 2020 [7]	Case report	Post-traumatic stress disorder and bipolar disorder.	History of bipolar disorder and post-traumatic stress disorder. Co-occurring features of mania with psychosis and pseudocyesis.	<ul style="list-style-type: none"> <li>- One month prior to admission, the patient discontinued her psychiatric medications, which included risperidone, oxcarbazepine, and topiramate, because she worried that they might harm her baby.</li> <li>- Three months history of amenorrhea prior to presentation.</li> <li>- Obesity (body mass index: 35.45)</li> <li>- Hormone levels, including prolactin (PRL), FSH, and LH were within normal limits.</li> </ul>	The patient was given olanzapine for her agitation and was subsequently stabilized with haloperidol and lorazepam. She was restarted on her home medications, including risperidone, oxcarbazepine, and topiramate for her bipolar disorder and propranolol for her migraine.
3.	Shweta Mittal et.al 2017 [15]	Letter to editor	<ul style="list-style-type: none"> <li>- Depression</li> <li>- Prior suicide attempt.</li> </ul>	Prior history of depression and suicide attempt. Co-occurring depressive episode.	<ul style="list-style-type: none"> <li>Tearful and confused at presentation with mixed emotions as she did not wish to be pregnant.</li> <li>- 6 months history of amenorrhea</li> <li>- No information was provided for hormone levels.</li> </ul>	Sertraline was started and the home treatment team provided daily visits and gently challenged her thought process.

4.	Sandeep Grover et.al 2013 [8]	Case report	<ul style="list-style-type: none"> <li>- Psychotic disorder</li> <li>- Moderate depressive episode</li> </ul>	Co-occurring features of pseudocyesis and initiation of antipsychotics for the treatment of her psychotic disorder.	<p>- Initial symptoms of Acute and Transient (Brief) Psychotic Disorder 2 months after the death of her son (treated with risperidone, switched to olanzapine, and then to trifluoperazine and ECT). Moderate depressive episode after stopping ECT (treated with sertraline).</p> <p>Trifluoperazine was switched to quetiapine due to amenorrhea and galactorrhea on examination. Also laboratory findings were significant for increased serum prolactin levels (150 ng/ml). Significant increase in weight and waist circumference after initiating quetiapine.</p>	Symptoms resolved after she was started on clozapine and the dose was gradually titrated to 200 mg/day, with which she achieved full remission with no further increase in body weight and waist circumference over the period of 12 weeks of therapy. Remission was also accompanied with normalization of serum prolactin levels.
----	-------------------------------	-------------	---	---	---	---

5.	Tarun Yadav et.al 2012 [16]	Case report	Delusion of persecution	Co-occurring delusion of persecution after the death of her son.	<ul style="list-style-type: none"> <li>-Unknown psychiatric illness in maternal grandfather.</li> <li>-Death of her son</li> <li>-Obesity</li> <li>-Head contrast-enhanced CT revealed bilateral frontoparietal atrophy.</li> <li>-Serum prolactin, TSH and FSH levels were above the normal limits. Triiodothyronine (T3) and thyroxine (T4) were low normal.</li> </ul>	Remission was achieved after initiating thyroxine.
6.	HabekDubravko et.al 2010 [10]	Case reports	<p>Case 1- Mild mental retardation</p> <p>Case 2- Paranoid schizophrenia</p>	<p>Case 1- Prior history of mild mental retardation.</p> <p>Case 2- Prior history of paranoid schizophrenia treated with antipsychotic.</p>	<p>Case 1- Post menopause for 8 years.</p> <ul style="list-style-type: none"> <li>-Transabdominal ultrasound study revealing a dilated, overfilled urinary bladder, before and after urination.</li> <li>-Hyperprolactinemia (prolactin:782.09 <math>\mu</math>mol), the levels of estradiol, progesterone, FSH, LH, and TSH were within normal postmenopausal range, and <math>\beta</math>-HCG was negative.</li> <li>-MRI of the pituitary gland was not performed because the patient feared this mode of investigation.</li> </ul> <p>Case 2-6 months history of amenorrhea and no prior pregnancy.</p> <ul style="list-style-type: none"> <li>-Normal hormone test results except for elevated levels of LH.</li> </ul>	<p>Case 1- Managed with antipsychotic therapy.</p> <p>Case 2- Psychiatric hospitalization for treatment (not specified).</p>

					Negative $\beta$ -HCG.	
7.	<u>Jeannine Del Pizzo et.al 2010</u> [6]	Case report	-Suicidal ideation -Bipolar disorder	History of bipolar disorder and suicidal ideation with multiple psychiatric admissions.	History of multiple foster homes, physical and sexual abuses. Pregnancy symptoms including amenorrhea, abdominal discomfort, and enlargement. PRL was slightly elevated.	Lansoprazole was given for gastritis, and progestin challenge was done to induce withdrawal bleeding.
8.	NarayanaManjunatha et.al 2009 [9]	Case report	Paranoid schizophrenia	History of schizophrenia treated with antipsychotics. Co-occurring negative symptoms of schizophrenia.	Increased waist circumference, elevated triglyceride (TG), and low high-density lipoprotein (HDL) levels. Diagnosis of antipsychotic-induced metabolic syndrome.	Treatment with amisulpride led to remission.

9.	Waldman,A.J et.al 1992 [17]	Letter to the editor	Schizophrenia	7-year history of schizophrenia, non-compliant with medications.	History of unstable relationship with a cohabiting partner and distress over being the only female of child-bearing age in her family who did not have children.	Delusion of pregnancy resolved after thiothixene treatment.
----	--------------------------------	----------------------------	---------------	---	--	--

10.	Signer, S. F., Weinstein 1992 [18]	Case series (6 cases)	<ol style="list-style-type: none"> <li>1. Major depression with psychosis,</li> <li>2. Bipolar disorder</li> <li>3. Erotomanic delusions, stroke, and confabulation at presentation.</li> <li>4. Anorexia, bipolar disorder, schizophrenia, and cocaine abuse.</li> <li>5. Psychosis and bipolar disorder.</li> <li>6. Bipolar disorder</li> </ol>	<ol style="list-style-type: none"> <li>1. Depressed mood and hallucinations at presentation. Developed depression 6 weeks later.</li> <li>2. History of bipolar disorder, grandiose delusion and confabulation at presentation.</li> <li>3. Erotomanic delusions, stroke, and confabulation at presentation.</li> <li>4. Previous history: Anorexia, bipolar disorder, schizophrenia, stroke, and cocaine abuse.</li> <li>5. Previous history: psychosis and bipolar disorder.</li> <li>6. Previous history: Bipolar disorder.</li> </ol>	<ol style="list-style-type: none"> <li>1. Childhood physical and sexual abuse. Got pregnant after a rape at the age of 17 years. Elevated PRL. Binge drinking, and substance abuse.</li> <li>2. Father was an alcoholic. CT showed infarction of right basal ganglia.</li> <li>3. None stated.</li> <li>4. Viral infection at 6-month-old that caused paralysis of the palate.</li> <li>5. Flattened affect, slow developmental milestones (learning and speech). CT showed prominent cerebral atrophy.</li> <li>6. Low FSH/LH and elevated PRL.</li> </ol>	<ol style="list-style-type: none"> <li>1. Treated with fluphenazine decanoate.</li> <li>2. Treated with lithium, fluphenazine, and amitriptyline.</li> <li>3. Mood cycles were treated with lithium and thioridazine was used to manage the delusion.</li> <li>4. Treated with lithium, carbamazepine, and thiothixene</li> <li>5. Delusions resolved with the use of neuroleptics which were eventually discontinued due to extrapyramidal side effects.</li> <li>6. Treated with lithium, haloperidol, and clonazepam.</li> </ol>
-----	--	-----------------------------	--	---	---	---



1	Ouj (2009) [26]	Prospective cohort	4 years	3 hospitals in the Brazilian Central Region	25	Mean age: 33.6 years. Range: 23-44 years. 72.7% had no formal education.	Incidence of pseudocyesis: 0.3%. 36.4% had a previous miscarriage, another 36.4% had no child. Reports on psychiatric illnesses or associations were not presented.
2	Caixeta et al. (2013) [13]	Retrospective study	10 years	Rural Southeastern Nigeria	20	Mean age: 33 years. Range: 20-44 years. 44% had no children, and 83% were of reproductive age. Two of the cases were males.	Affective disorders and psychotic disorders were each seen among 45% of the patients. Epilepsy (5%) and Huntington disorder (5%) were other neuropsychiatric disorders found in the study.

Among the 18 cases in the case reports/case series, 12 (66.7%) were diagnosed with schizophrenia or presented with symptoms of schizophrenia. Five of the cases were diagnosed with bipolar disorder, four with major depressive disorder and two of the cases had anorexia nervosa. Folie-a-deux and post-traumatic stress disorder (PTSD) were each seen in one case. In ten cases, the associated psychiatric conditions were co-occurring with pseudocyesis at the time of diagnosis while in fifteen cases, the associated psychiatric conditions were reported as past occurrences. In six cases, the associated psychiatric illnesses were presented as both histories and co-occurring at the time of presentation. In one case, the patient developed a psychiatric condition (major depressive disorder) 6 weeks after presentation with pseudocyesis. In another case, the patient was reported noncompliant with psychiatric medication (antipsychotics).

In seven cases (38.9%), the patients were found to have hormonal imbalance affecting prolactin, follicle stimulating hormone (FSH), and thyroid stimulating hormone (TSH). In three cases, the patients had a deep desire to have a baby, and in one case, the woman was constantly pressured by her family members to have a child. Five studies reported a history of amenorrhea prior to presentation of pseudocyesis. Three cases reported a history of sexual abuse and a history of miscarriage while two studies reported loss of a child prior to the development of pseudocyesis. Nine cases (50%) included in our analysis, disclosed remission of pseudocyesis symptoms after starting antipsychotics for their

underlying orcoexisting psychiatric conditions or as a treatment for the features of pseudocyesis. In the case of a woman with a history of depression, features of pseudocyesis resolved after initiating sertraline for treatment of the depression. One of the cases reported remission after treatment with a proton pump inhibitor and progestin challenge for gastritis and amenorrhea respectively.

Table 3: Frequency of Psychiatric Disorders in the reviewed cases.

S/N	Associated Psychiatric Conditions	Frequency N (%)
1	Positive symptoms of Schizophrenia	12 (66.7)
2	Bipolar disorder	5 (27.8)
3	Major Depressive Disorder	4 (22.2)
4	Anorexia nervosa	2 (11.1)
5	Folie-a-deux, PTSD, Mental Retardation	1 (5.6) *

\*Each of these conditions were found in only one case.

Table 4: Treatment options reported in the reviewed literature.

Treatment Options and Management forPseudocyesis
--

- Diagnostic tests such as pregnancy tests and sonographic examinations can be conducted and shown to the patient to convince them about their current non-pregnancy state.
- Psychological support and psychotherapy including grounding techniques, psychodynamic and supportive psychotherapy, can be provided in a multi-disciplinary approach encompassing psychiatrists, gynecologists and other specialists.
- Counseling the patient and referring to the clinical psychologists.
- Management of existing infertility.
- Creating awareness and educating the populace, including young girls.

## Discussion

In this paper, we aimed to review pseudocyesis in terms of epidemiology, etiology, associated psychiatric conditions, and treatment. It is imperative that pseudocyesis be distinguished from “delusion of pregnancy” (belief of being pregnant with the absence of physical symptoms), “factitious disorder” (belief of being pregnant but acknowledging that she is not pregnant), and “erroneous pseudocyesis” (misinterpretation of signs suggestive of pregnancy [1,7]). Pseudocyesis is a complex and multifactorial disorder most prevalent among women, aged 20 to 39 years [4]. However, rare cases in premenarchal and postmenopausal women have also been reported in literature [4,7,10]. Previous studies also suggest that cases of pseudocyesis are more prevalent in developing countries or underdeveloped countries as compared to developed nations [8,21]. The etiology of pseudocyesis remains obscure [11]. Available literature indicates that a psychological deep desire for pregnancy and neuroendocrine disturbances play an important role in the development of pseudocyesis [1]. However, it is worth mentioning that even when pseudocyesis has a psychological basis, every patient has a different disease course. Although many speculations on the etiology of this disorder have been made, the most accepted theory relates to the interaction between psychological factors and reproductive dysregulation that are caused by neuroendocrine/endocrine disorders [3].

Previous literature review done by Tarín et al. linked pseudocyesis to neuroendocrine and/or endocrine disorders such as higher sympathetic nervous system activity, dysfunction of central nervous system catecholaminergic pathways for hormone secretion regulation, and lower steroid feedback inhibition of GnRH resulting in symptoms typically found among patients with pseudocyesis [1]. Neuroendocrinological disturbances in the hypothalamic-pituitary-ovarian axis such as deficiency of dopamine, elevated prolactin, adrenocorticotrophic hormone, and cortisol levels are also biological factors that have been suggested to be responsible for the occurrence of pseudocyesis [1,9,22]. The case report by Tarín et al. in which remission of pseudocyesis symptoms occurred after the initiation of hormone therapy with thyroxine in a woman with elevated TSH level, is an example that demonstrates the possible association of endocrinopathies with the development of pseudocyesis. Some studies also considered pseudocyesis as possibly due to an antipsychotic-associated hyperprolactinemia and metabolic syndrome [8,9].

Psychological factors such as intense desire for pregnancy [1], psychological stress-induced hyperprolactinemia [23,24], grief reaction following tubal ligation, or hysterectomy were also found to be contributing factors to pseudocyesis. Social factors such as lower socioeconomic status, limited access to healthcare [4], lack of family support [6,25], low educational status [26] and cultural factors such as the pressure of having a child can also affect the mental health of the patient, and possibly lead to the development of pseudocyesis [27].

In this review, the key findings are that schizophrenia and mood disorders (bipolar disorder and depression) are the most common psychiatric illnesses found in cases of pseudocyesis. This is a typical example of interaction between the mind and the body [15]. Various studies dating back to the early 1970s provided initial evidence on the association of pseudocyesis with psychosis [19,28]. These studies suggested that the development of pseudocyesis may be due to the dysfunction in dopamine activity associated with schizophrenia. The studies also indicated the underreporting of pseudocyesis cases when they co-occurred with schizophrenia which may be due to the consideration of the disease as part of the delusions in the patients [3]. However, as seen in the result of this review, various psychiatric disorders are associated with pseudocyesis, suggesting a wide variation in the pattern of association between the different psychiatric conditions and pseudocyesis. For instance, some patients were reported to have histories of underlying psychiatric disorders prior to presentation with pseudocyesis, while others developed pseudocyesis simultaneously with various psychiatric disorders- particularly psychotic and mood disorders. Some reported pseudocyesis after discontinuation of antipsychotics while others reported it after initiation of antipsychotics [7,10]. The multidirectional nature of these findings suggest that a direct link between a particular psychiatric disorder, or psychiatric medication cannot be made without further evidence. Furthermore, it is important to note that some studies such as that by Sandeep et. al reported remission of pseudocyesis with normalization of serum prolactin level.

Social factors and traumatic experiences such as cultural pressure for pregnancy in the reproductive age group, discordant family dynamics, loss of a child, history of repetitive miscarriages, and sexual abuse have been reported in most of the cases reviewed in this study [26]. Sometimes, adverse factors such as abusive partners, infertility, and recent miscarriage led to distress and depression which have been commonly observed among patients with pseudocyesis [3,4,7,18]. These case reports indicate that social factors such as lower socio-economic class may be related to the manifestation of pseudocyesis. It is evident from extant literature that individuals with pseudocyesis sometimes have a strong desire to have a child or are under pressure of having a child, while some of the patients had histories of child loss or miscarriages [14]. However, contrary to the positive association of pseudocyesis with the desire to have a child as reported by Nagdive et. al [14], Shweta et al described the case of a patient with a prior history of depression, who presented with mixed emotions and feelings of not longing for a child [15].

Given the foregoing, it can be inferred that the management of pseudocyesis will be most effective with a combination of psychosocial and pharmacological interventions as suggested in table 4. The treatment of pseudocyesis depends on the underlying associated conditions. In most case reports examined in this review, a multidimensional approach including psychotherapy; pharmacotherapy like antidepressants and antipsychotics; hormonal therapy such as replacement therapy, has been suggested as a promising therapeutic option. An example can be seen from the case of the female patient who had resolution of her pseudocyesis after she was treated with lansoprazole and progestin [15]. In many other studies, psychological disorders have been closely associated with pseudocyesis. In such cases, various forms of psychotherapy such as the cognitive, behavioral, and psychoanalytic variants have been suggested as important and beneficial treatments along with consideration of pharmacotherapy for associated co-morbidities in the patients [3,7]. These findings suggest that treatments adopting a multidisciplinary model provide successful outcomes [15]. Summarily, the treatment for pseudocyesis requires a multifaceted approach where the overall aim is to help the patients recognize the condition and to counsel them regarding it.

### **Limitations:**

Despite the strength of this study, the nature of the study as a comprehensive review of available literature on pseudocyesis presents some inherent limitations. Firstly, it was difficult establishing the exact nature of the association between pseudocyesis, and other psychiatric conditions based on existing data. In addition, there was not enough empirical

evidence from available studies to conclusively affirm a direct correlation between antipsychotics and the development of pseudocyesis. Therefore, further prospective studies with larger patient samples are required to better evaluate these relationships. Another limitation is the fact that the bulk of the literature included in this study were case reports/case series, the assertions made by these studies are not conclusive as case reports have their limitations such as selection bias, lack of control, difficulties in comparing cases and generalization of findings [29].

### **Conclusion:**

Pseudocyesis is an intriguing condition. Despite the availability of literature on the disorder for decades, the search for its precise correlation with other conditions- whether psychiatric, endocrinologic and otherwise- continues. Schizophrenia and mood disorders such as depression and bipolar disorder are the most common psychiatric conditions in patients with pseudocyesis. Psychosocial and cultural factors such as the importance of bearing a child, the loss of a child, and previous traumatic experiences also play a role in this condition. Though common worldwide, it is more prevalent in developing countries. Treatment demands a multidisciplinary approach including a team comprising gynecologists, psychologists, psychiatrists, and other professionals depending on the presentation.

### **References**

1. Tarín JJ, Hermenegildo C, García-Pérez MA, Cano A: Endocrinology and physiology of pseudocyesis. *Reprod Biol Endocrinol* 2013, 11:39. 10.1186/1477-7827-11-39.
2. American Psychiatry Association: DSM-5. Accessed: December 28, 2012, <https://www.psychiatry.org/psychiatrists/practice/dsm>.
3. Azizi M, Elyasi F: Biopsychosocial view to pseudocyesis: A narrative review. *Int J Reprod Biomed* 2017, 15:535–42.
4. Avni-Barron O: UpToDate. Accessed: September 14, 2021, <https://www.uptodate.com/contents/pseudocyesis>.
5. Sultana K, Nazneen R, Ara I: Pseudocyesis: A case report on false pregnancy. *J Dhaka Med Coll* 2013, 21:235–7. 10.3329/jdmc.v21i2.15365.
6. Del Pizzo J, Posey-Bahar L, Jimenez R: Pseudocyesis in a teenager with bipolar disorder. *Clin Pediatr (Phila)* 2011, 50:169–71. 10.1177/0009922809350675.
7. Espiridion ED, Fleckenstein C, Boyle P, Oladunjoye AO: A rare case of pseudocyesis in a patient with bipolar disorder. *Cureus* 2020, 12:e10352. 10.7759/cureus.10352.
8. Grover S, Sharma A, Ghormode D, Rajpal N: Pseudocyesis: A complication of antipsychotic-induced increased prolactin levels and weight gain. *J Pharmacol Pharmacother* 2013, 4:214. 10.4103/0976-500X.114610.
9. Manjunatha N, Saddichha S: Delusion of pregnancy associated with antipsychotic induced metabolic syndrome. *World J Biol Psychiatry* 2009, 10:669–70. 10.1080/15622970802505800.
10. Dubravko H: Pseudocyesis in peri- and postmenopausal women. *Open Medicine* 2010, 5:372–4. 10.2478/s11536-009-0084-8.
11. Makhil M: Psychodynamic and Socio-Cultural Perspective of Pseudocyesis in a Non-Fertile Indian Woman: A Case Report | Semantic Scholar(2013). (2013). Accessed: September 16, 2021, <https://www.semanticscholar.org/paper/Psychodynamic-and-Socio-Cultural-Perspective-of-in-Makhil-Majumder/7a6abe213e4264de532d174d6c63dd11ba791ae4>.
12. Elvira K: PSEUDOCYESIS AND COUVADE SYNDROME(2002). (2002). Accessed: September 16, 2021, [https://hrcak-srce-hr.translate.google.com/19614?\\_x\\_tr\\_sl=hr&\\_x\\_tr\\_tl=en&\\_x\\_tr\\_hl=en&\\_x\\_tr\\_pto=ajax,sc,elem](https://hrcak-srce-hr.translate.google.com/19614?_x_tr_sl=hr&_x_tr_tl=en&_x_tr_hl=en&_x_tr_pto=ajax,sc,elem).

13. Caixeta L, Brasil R, Vargas C, *et al.*: 1347 – Pseudocyesis study in brazil. *Eur Psychiatry* 2013, 28:1. 10.1016/S0924-9338(13)76395-8.
14. Nagdive AB, Bhainsora RS, Fernandes R, Behere PB, Sethi S: Pseudocyesis Leading to Folie-à-Deux. *J Neurosci Rural Pract* 2021, 12:419–23. 10.1055/s-0041-1726615.
15. Mittal S, Lucking AN, Cunnane JG: Pseudocyesis: birth of a phantom. *Prim Care Companion CNS Disord* 2017, 19. 10.4088/PCC.17102102.
16. Yadav T, Balhara YPS, Kataria DK: Pseudocyesis versus delusion of pregnancy: differential diagnoses to be kept in mind. *Indian J Psychol Med* 2012, 34:82–4. 10.4103/0253-7176.96167.
17. Waldman AJ, Marchese MJ, Greer RA: Pseudocyesis in a schizophrenic woman of child-bearing age. *Psychosomatics* 1992, 33:360–1. 10.1016/S0033-3182(92)71983-5.
18. Signer SF, Weinstein RP, Munoz RA, Bayardo JF, Katz MR, Saben LR: Pseudocyesis in organic mood disorders. Six cases. *Psychosomatics* 1992, 33:316–23. 10.1016/S0033-3182(92)71971-9.
19. Taylor J, Kreeger A: Recurrent pseudocyesis and hypomania. *Br J Psychiatry* 1987, 151:120–2. 10.1192/bjp.151.1.120.
20. Reichenbacher T, Yates A: Pseudocyesis as the presenting symptom in an adolescent patient with an incipient thought disorder(1987). (1987). Accessed: September 16, 2021, <https://ur.booksc.eu/book/13097324/711618>.
21. Ibekwe PC, Achor JU: Psychosocial and cultural aspects of pseudocyesis. *Indian J Psychiatry* 2008, 50:112–6. 10.4103/0019-5545.42398.
22. Starkman MN, Marshall JC, La Ferla J, Kelch RP: Pseudocyesis: psychologic and neuroendocrine interrelationships. *Psychosom Med* 1985, 47:46–57. 10.1097/00006842-198501000-00005.
23. Thippaiah SM, George V, Birur B, Pandurangi A: A case of concomitant pseudocyesis and couvade syndrome variant. *Psychopharmacol Bull* 2018, 48:29–32.
24. Seeman MV: Pseudocyesis, delusional pregnancy, and psychosis: The birth of a delusion. *World J Clin Cases* 2014, 2:338–44. 10.12998/wjcc.v2.i8.328.
25. Miller WH, Maricle R: Pseudocyesis: a model for cultural, psychological, and biological interplay. *Journal of Psychosomatic Obstetrics & Gynecology* 1988, 8:183–90. 10.3109/01674828809016786.
26. Ouj U: Pseudocyesis in a rural southeast Nigerian community. *J ObstetGynaecol Res* 2009, 35:660–5. 10.1111/j.1447-0756.2008.00997.x.
27. Kamal A, Rahman W, Laila L, Hakim N: Case reports on pseudocyesis. *J Armed Forces Med Coll* 2013, 8:56–8. 10.3329/jafmc.v8i1.13542.
28. Brown E, Barglow P: Pseudocyesis. A paradigm for psychophysiological interactions. *Arch Gen Psychiatry* 1971, 24:221–9. 10.1001/archpsyc.1971.01750090027004.
29. Nissen T, Wynn R: The clinical case report: a review of its merits and limitations. *BMC Res Notes* 2014, 7:264. 10.1186/1756-0500-7-264.