

# Navigating the Burden of Glioblastoma- Diagnosis to Treatment: Current Status and Future Perspectives

---

## Abstract:

Glioblastoma (GBM) commonly presents with symptoms including headaches, seizures, nausea, vomiting, and cognitive decline. The specific symptoms experienced may differ based on the tumor's location and size inside the brain. The precise etiology of GBM remains uncertain, while certain risk factors like as radiation exposure, genetic susceptibility, and advanced age have been found. The results of functional imaging provide proof that a tumor has a widespread impact on the brain during its progression. To be more specific, a wide variety of neurological illnesses, such as GBM/HGG, have the ability to change the resting-state functional connectivity (rsFC), which is a measure that describes the functional organization in the brain. Glioblastoma multiforme (GBM) has a tendency to swiftly invade the neighboring brain tissue, posing challenges for full surgical extraction.

Keywords: surgical extraction, Glioblastoma, genetic susceptibility, transportation of drugs

## 1. INTRODUCTION:

Glioblastoma (GBM) is a highly malignant and lethal kind of brain cancer, known for its fast proliferation and invasive behavior[1]. Gliomas are a type of tumor that develops in the glial cells, which are the supporting tissue of the brain. Despite the progress made in medical research, the outlook for GBM remains unfavorable, with a median survival period of approximately 12 to 15 months, even when aggressive therapy is pursued. Glioblastoma (GBM) commonly presents with symptoms including headaches, seizures, nausea, vomiting, and cognitive decline. The specific symptoms experienced may differ based on the tumor's location and size inside the brain[2]. The precise etiology of GBM remains uncertain, while certain risk factors like as radiation exposure, genetic susceptibility, and advanced age have been found[3]. The diagnosis of GBM typically entails a combination of imaging modalities, such as magnetic resonance

imaging (MRI) and computed tomography (CT) scans, in addition to a biopsy for definitive confirmation of the existence of cancerous cells[4]. After being diagnosed, the usual treatment options for GBM involve surgically removing as much of the tumor as possible, followed by further therapies such radiation therapy and chemotherapy to specifically target any remaining cancer cells[5]. Despite the use of aggressive treatment strategies, glioblastoma multiforme (GBM) is well-known for its propensity to relapse and exhibit resistance to traditional therapy. This is partially attributed to its extremely invasive character, which presents difficulties in achieving total eradication of all malignant cells. Moreover, the blood-brain barrier presents a substantial impediment to the transportation of drugs, hence restricting the efficacy of chemotherapeutic medicines[6]. Ongoing research is focused on developing more precise and individualized therapeutic approaches for GBM, such as immunotherapy, targeted molecular treatments, and innovative drug delivery techniques[7]. Current clinical trials are being conducted to investigate novel strategies in order to enhance outcomes for patients afflicted by this debilitating illness. Nevertheless, the intricate biology and diversity of GBM still pose significant obstacles in the quest for efficacious therapies. There have been previous research that have revealed links between changes in brain morphology and cognitive and motor impairment in healthy ageing, sex, hemisphere, and illnesses. It is important[8] to note that patients diagnosed with GBM or HGG frequently have neurologic and cognitive abnormalities prior to beginning any treatment program. According to conventional wisdom, these deficiencies can be explained by tumor tissue invasion and localized mass effects[9]. The cognitive function of patients with high-grade gliomas (HGG) was shown to be significantly more impaired than that of individuals with low-grade gliomas (LGG), even after taking into consideration the extent of the tumour.89,8 On the basis of these data, it was determined that broad changes in brain morphometry existed beyond the area of the tumor[10]. The fact that similar motor deficiencies were observed in paediatric patients who were diagnosed with malignant glioma coincided with thinner bilateral motor cortices is a fascinating piece of evidence that suggests a connection between motor impairment and more distal morphological changes in glioma. Whether or not there are extensive structural changes in the presence of a focally damaging GBM is something that is currently unknown[11]. The results of functional imaging provide proof that a tumor has a widespread impact on the brain during its progression. To be more specific, a wide variety of neurological illnesses, such

as GBM/HGG, have the ability to change the resting-state functional connectivity (rsFC), which is a measure that describes the functional organization in the brain. Recent rsFC findings in GBM/HGG reveal that there are frequent abnormalities in the functional architecture. These distortions extend beyond the focally malignant tissue and are of a bi-hemispheric origin[12, 13].

### 1.1. Grading Of Glioblastoma:

The WHO (World Health Organization) classification is currently the accepted global standard for the naming and diagnosis of gliomas. The classification of gliomas is based on histological criteria and categorizes them into grades I to IV according to their level of aggressiveness. Grade I gliomas are characterized by modest proliferative capacity and can be cured with surgical procedures. In contrast, grade II to IV gliomas are very malignant and invasive. Glioblastoma multiforme is classified as Grade IV by the World Health Organization (WHO) due to its very aggressive, invasive, and undifferentiated nature[14].

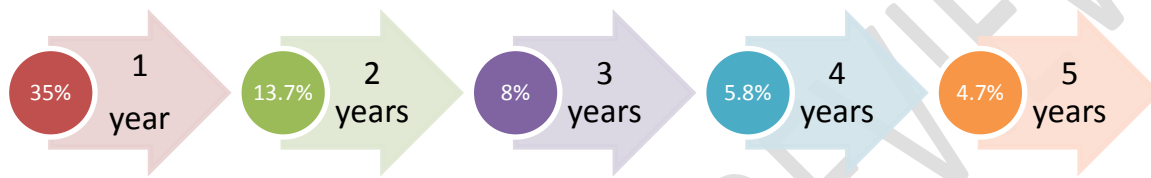
**Table 1 Grading og glioblastoma**

Grade	Name	Description
I	Pilocytic Astrocytoma	Slow-growing tumor. Well-defined borders. Cells look normal under the microscope. More common in children.
II	Diffuse Astrocytoma	Slow-growing tumor. Borders may be less defined. Cells look slightly abnormal under the microscope. May progress to higher grades over time.
III	Anaplastic Astrocytoma	Faster-growing tumor. Borders are less defined. Cells look significantly abnormal under the microscope. More aggressive than Grade II tumors.
IV	Glioblastoma (GBM)	Highly aggressive tumor. Fast-growing with diffuse invasion into surrounding brain tissue. Cells highly abnormal under the microscope. Most severe form.

### 1.2.EpidemiologyAnd Etiology Of Glioblastoma:

GBM, a rare tumor with a global incidence of less than 10 per 100,000 persons, poses a significant public health concern because to its poor prognosis. Patients diagnosed with GBM have a survival rate of only 14-15 months. It represents half of all gliomas across all age categories. The occurrence of this condition is possible at any age, however, it is most commonly observed between the ages of 55 and 60. Malignant gliomas account for 2.5% of cancer-related deaths and rank as the third leading cause of cancer-related mortality among those aged 15 to 34[15]. The incidence of GBM is greater in men compared to women. The prevalence of gliomas is higher in the western world compared to less developed countries, potentially due to

underreporting of glioma cases, restricted healthcare access, and variations in diagnostic methodologies. Several studies have indicated that individuals of African descent had a lower susceptibility to GBM, while other ethnic groups such as Asians, Latinos, and Whites have a higher incidence of this condition[16].



**Figure 1 Glioblastoma Relative Survival Rates**

Glioblastoma (GBM) is a highly malignant brain tumor that arises from glial cells, which are supporting cells in the brain. The precise cause of GBM is not completely understood, but various variables have been implicated in its development [17]. Mutations in specific genes have been linked to the formation of GBM. One of the most widely recognized genetic changes is the mutation of the epidermal growth factor receptor (EGFR) gene, which is present in a substantial number of instances of glioblastoma (GBM). GBM has also been associated with other genetic changes, including mutations in the PTEN, TP53, and IDH genes[18]. Environmental factors can potentially elevate the likelihood of getting GBM. These factors encompass ionizing radiation (such as radiation therapy for various medical diseases), certain compounds, and electromagnetic fields. Nevertheless, the impact of environmental factors on the development of GBM is not as comprehensively recognized as that of genetic factors. Glioblastoma (GBM) is more prevalent in the elderly population, particularly in persons aged 60 and above, who have the highest occurrence rate[19, 20]. Nevertheless, it can manifest at any age, especially in toddlers. GBM has a somewhat higher prevalence in males

compared to females, however the exact reasons for this disparity remain unclear[19]. Immune system dysfunction can potentially contribute to the development of GBM. Several studies have indicated that the presence of persistent inflammation or inhibition of the immune system may play a role in the development and advancement of GBM tumors. Certain researchers have examined the possible influence of viral infections on the formation of GBM. For instance, the presence of specific strains of human cytomegalovirus (HCMV) has been observed in GBM tumors. However, the importance of this discovery is still being studied[21]. In general, GBM is probably a complex disease that involves both hereditary and environmental components. Additional investigation is required to have a comprehensive understanding of the intricate causes of this malignant brain tumor.

## **2. Importance of Early Diagnosis and Intervention of Glioblastoma (GBM):**

Prompt identification and timely treatment of glioblastoma (GBM) are crucial owing to the highly malignant characteristics of this kind of brain cancer. Prompt identification enables timely commencement of therapy, which has the potential to enhance outcomes. Glioblastoma multiforme (GBM) is widely known for its aggressive growth and ability to resist treatment, making early detection crucial for effective intervention. Timely diagnosis offers a greater array of therapy possibilities. GBM treatment often entails a multimodal approach that combines surgical intervention, radiation therapy, and chemotherapy. Timely identification could potentially allow for the utilization of less invasive interventions or involvement in research studies assessing innovative treatments[22, 23]. Glioblastoma multiforme (GBM) has a tendency to swiftly invade the neighboring brain tissue, posing challenges for full surgical extraction. Nevertheless, identifying the tumor at an early stage enables the possibility of surgically extracting a greater amount of it, so decreasing the overall size of the tumor and maybe impeding its advancement. GBM can result in substantial neurological impairments, depending on the tumor's location and size. Timely intervention might mitigate brain function deterioration by minimizing harm to crucial brain regions and decreasing the likelihood of consequences like seizures and cognitive impairment. Prompt diagnosis and intervention can enhance the overall quality of life for those with GBM. Through the more efficient management of symptoms and the postponement of illness advancement, patients may attain enhanced

physical, emotional, and cognitive well-being[24]. Timely diagnosis enables healthcare providers to swiftly undertake measures to offer supportive care. This encompasses the management of symptoms such as pain, exhaustion, and psychological distress, while also offering support and resources to patients and their families in order to effectively deal with the difficulties associated with living with GBM. Despite intensive treatment, GBM frequently reoccurs. Regular monitoring enables the early discovery of recurrence, which in turn allows for prompt alterations to treatment options. This proactive approach has the potential to enhance outcomes and improve the quality of life for patients dealing with recurrent disease[25].

### 3. **Pathophysiology and Molecular Mechanisms of Glioblastoma (GBM):**

Glioblastoma (GBM) is the most aggressive and common type of primary malignant brain tumor in adults. Understanding its pathophysiology and molecular mechanisms is crucial for developing effective treatment strategies. GBM is characterized by numerous genetic alterations, including mutations, amplifications, deletions, and chromosomal abnormalities[26]. The two most frequently altered pathways in GBM are the **RTK/RAS/PI3K** pathway and the **p53** tumor suppressor pathway. Receptor tyrosine kinase (RTK) activation is common in GBM, leading to downstream signaling through the RAS/PI3K pathway, which promotes cell growth, survival, and migration. Genetic alterations affecting this pathway include amplification of the **EGFR** gene and mutations in **PTEN** and **PIK3CA**. The tumor suppressor protein p53 plays a crucial role in regulating cell cycle progression, DNA repair, and apoptosis. Mutations in the **TP53** gene are frequent in GBM, leading to loss of p53 function and dysregulation of cell cycle control. A subset of GBMs (~10-20%) harbor mutations in the **IDH1** or **IDH2** genes. These mutations are associated with a distinct molecular and clinical phenotype, often occurring in younger patients and associated with better prognosis compared to IDH wild-type GBMs. Amplification of the **EGFR** gene and expression of the EGFR $\nu$ III mutant form are common in GBM. EGFR $\nu$ III is a constitutively active variant that promotes cell proliferation and invasion[27]. The tumor microenvironment of GBM plays a critical role in tumor progression and therapeutic resistance. Factors such as hypoxia, angiogenesis, immune cell infiltration, and extracellular matrix remodeling contribute to tumor growth and invasion. Epigenetic dysregulation, including changes in DNA methylation, histone modifications, and non-coding RNA expression, is a hallmark of GBM. These alterations contribute to the activation of oncogenes and silencing of tumor suppressor genes. GBM tumors have developed various mechanisms to evade immune

surveillance, including expression of immune checkpoint molecules (e.g., PD-L1), secretion of immunosuppressive factors, and recruitment of regulatory T cells and myeloid-derived suppressor cells[28].

## 4. Methodology

EfficientNet architecture on the provided dataset, optimizing the model's weights through backpropagation, and employing an Adam optimizer. The training loop incorporated patience-based early stopping to prevent overfitting and improve generalization. The EfficientNet architecture, known for its efficiency and scalability, was employed. The training process included a dynamic learning rate strategy and binary cross-entropy loss. In this project, a state-of-the-art Convolutional Neural Network (CNN) was developed for the detection of Glioblastoma, a highly aggressive form of brain cancer. Leveraging multimodal imaging biomarkers, including FLAIR, T1w, and T1wCE, the model was trained on a comprehensive dataset from the Brain Tumor Radiogenomic challenge. The dataset, obtained in DICOM format, was meticulously processed to extract relevant features from each modality. Utilizing efficient data loading techniques and animation visualization, a robust understanding of the imaging data was established. Randomly sampled images were showcased, providing a glimpse into the diversity of the dataset. To train the CNN model, a patient-stratified split was performed into training and validation sets. The EfficientNet architecture, known for its efficiency and scalability, was employed. The training process included a dynamic learning rate strategy and binary cross-entropy loss.

The model's performance was evaluated using metrics such as loss and accuracy during both training and validation epochs. A patient stratified split ensured the model's ability to generalize across different cases. The training process involved fine-tuning the EfficientNet architecture on the provided dataset, optimizing the model's weights through backpropagation, and employing an Adam optimizer. The training loop incorporated patience-based early stopping to prevent overfitting and improve generalization.

Upon completion of training, the best-performing model was saved, and an ensemble of models was created to enhance predictive robustness. This ensemble was applied to a test set, generating predictions for the BraTS21ID samples. The final results were compiled into a submission file, detailing the predicted MGMT values for each patient.

The project not only exemplifies the application of advanced deep learning techniques for medical image analysis but also underscores the significance of multimodal biomarkers in improving diagnostic capabilities for Glioblastoma.

Glioblastoma is the most dominant and aggressive brain tumor taking over 200,000 lives annual and comprising of 60% of all brain tumor cases. These tumors are incredibly invasive fully growing in around 300 days and ultimately leading to neuronal death in 6 months or less.

Survival time for patients with glioblastoma ranges from approximately 14-15 months post diagnosis with treatment and 3-4 months without. The low survival time is due to a lack of active detection (late diagnosis) as lesions are often incidental findings or identified when patients are presented with a seizure. However, by then it is too late with patients already being in stage 4 of glioblastoma with the tumors spreading even faster and fatality being unpreventable.

This is primarily due to the lack of robust prognostic and predictive biomarkers. Thus, there is a critical need for novel non-invasive biomarkers to enhance early detection, facilitate accurate grading and subtyping, and enable tracking/preliminary selection of therapeutic response.

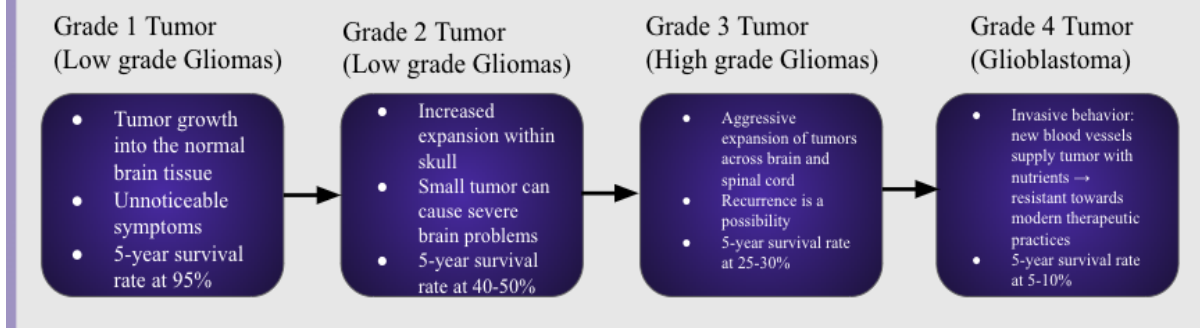


Figure2. Tumor growth process

With the knowledge of such a connection, such voxel-based morphometry (VBM) data can be harnessed by a pre-trained **3D Convolutional Neural Network**, EfficientNet-b0, to validate such breakthrough gray matter biomarkers; successful use of VBM data—segmenting traditional imaging techniques into grey matter, white matter, and cerebrospinal fluid—in the early detection of GBM validates the existence of previously highlighted novel gray-matter-related biomarkers drawn from data-mining.

In this case, novel biomarkers focused on gray-matter composition may be introduced with an application in the diagnosis of GBM, offering significant **prognostic value** and impacting the potential treatment of patients with the disorder.

UNDER PEER REVIEW

Block diagram of pretrained architecture:

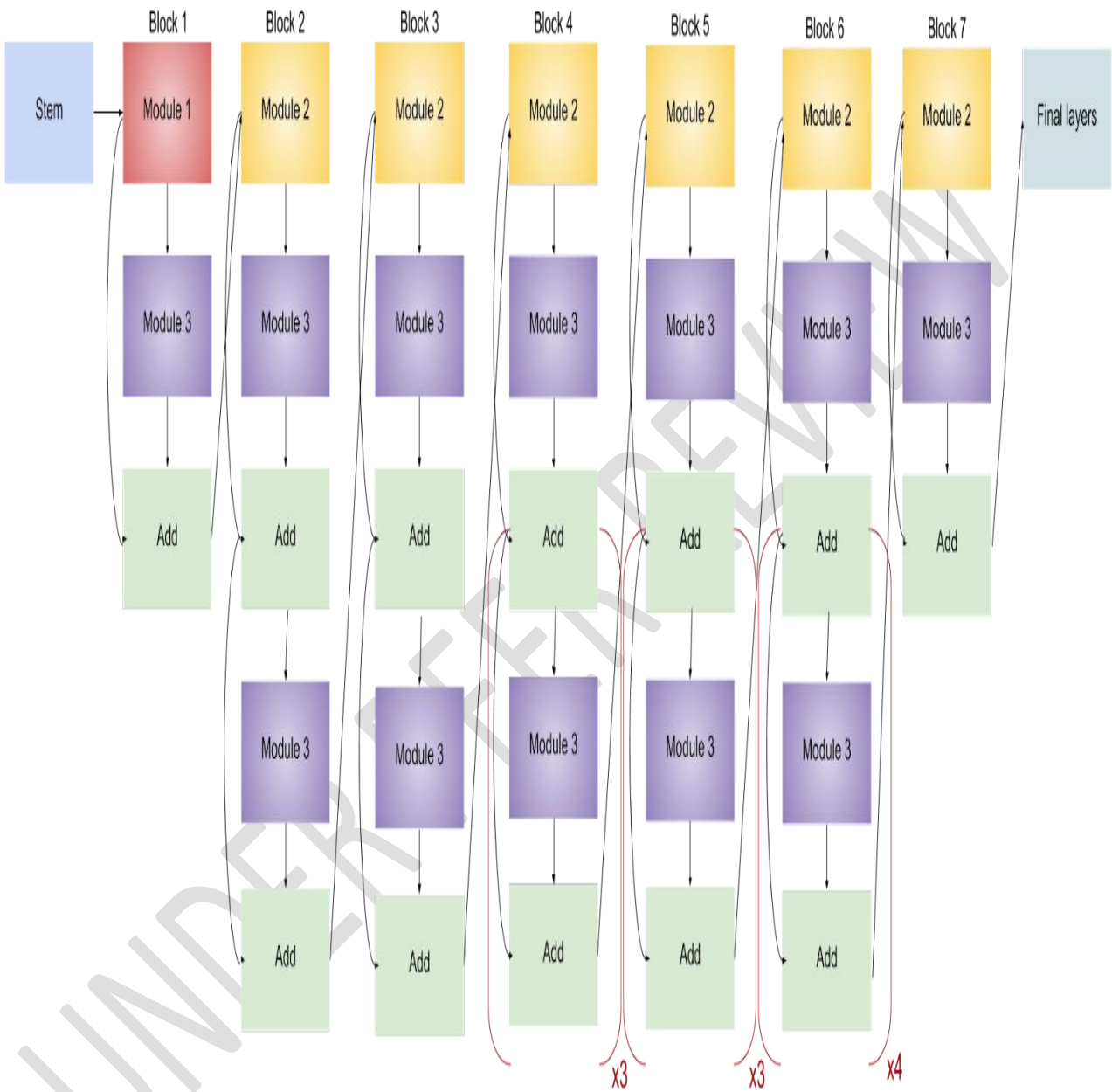


Figure3. Block diagram architecture

- AUC performance metric used to measure model efficacy

- The binary nature of classification in the study entails the use of AUC over other performance metrics
- Threshold-independent metric, assessing the model's performance across all possible classification thresholds; allows for an overall measure of the model's discrimination ability.

The architecture we used emphasized simplicity over accuracy. However, by replacing the EfficientNet b-0 architecture to a more advanced architecture in which one can increase the number of parameters, we can improve the accuracy greatly. Moreover, the proposed use of deep learning suffers from a **lack of abundant data** and doesn't account for nuisance factors such as age and gender cohorts. When applied to a greater data sample with specific sorting, it is possible to achieve a higher accuracy in conjunction with more advanced architecture types. Furthermore, by applying the same method of tracking changes in cortical thickness and hippocampal volume, one may utilize the discovered biomarkers to target and monitor low grade glioma. If presented with data representing low grade gliomas (grades I-II), we can use leverage the aforementioned biomarkers attack all stages of gliomas, effectively diagnosing the condition before a grade IV glioma ever forms. This would prove effective in detecting tumors early allowing for better therapeutic practices and presents limitless **prognostic value**. Early discovery of presence of tumors in the brain can provide professions with more time to customize a safe and efficient way of assist their patients.

The Biomarkers discovered will completely revolutionize therapeutic approaches to all stages of glioblastoma:

- Grade I: Grade I gliomas fall under low grade gliomas which are surgically curable. Our research increases the efficiency of surgical removals exponentially. Through the measurement of CT and hippocampal volume, medical professionals can better pinpoint the presence of tumors enhancing the precision and completeness of surgical removal.
- Grade II: Like grade I gliomas, grade II falls under low grade gliomas which utilizes practices such as radiographic therapy. Our research presents a breakthrough by showing changes in the brain which indicate tumors. Monitoring the tumors at an earlier time gives professionals the ability to precisely remove them before they build resistance and rapidly spread.

- Grade III: Grade III gliomas falls within high grade gliomas. A safe gross total resection, concomitant chemoradiation, and radiographic follow-up for recurrence are an acceptable treatments. Our findings will increase the efficiency of the total resection by presenting professionals the ability to accurately assess tumor locations within the brain and surgically remove it. During this stage of gliomas are rapidly spreading and completely removal is extremely difficult making our findings vital.

- Grade IV (glioblastoma): A safe gross total resection, concomitant chemoradiation, and radiographic follow-up for recurrence are an acceptable treatment. Much like Grade III tumors, a total resection is needed. Our model which analyzes changes in Cortical Thickness and Hippocampal volume gives medical professionals the upper hand over the tumor helping them gather information on patients to determine the best approach towards the frequency and maintenance chemotherapy.

Hypothesis: if a 3D Convolutional Neural Network leveraging such VBM data proves to be an effective method of early detection for glioblastoma, then there exists the possible identification of a novel gray matter biomarker for the disorder, greatly impacting the diagnosis and future treatment of GBM

## 5. Results and Discussions

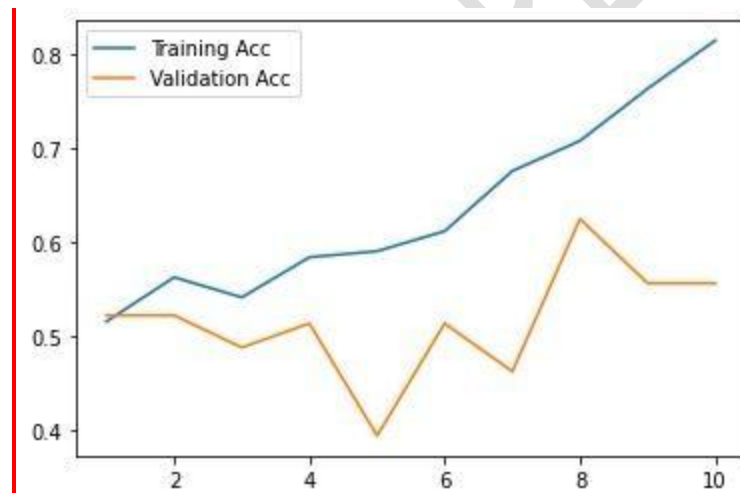


Figure4. Therapeutic approaches to all stages of glioblastoma

The efficientNet-b0 is a pretrained model. The main advantage of using this model is the principled scaling used to widen, deepen and increase resolution of the model layers as needed

The voxel based morphology approach is the novelty model as it is rarely studied. By using this approach, we confirmed the clinical relevance of gray matter biomarkers suggested by the following study [29]:

Scientists may use the same method as them to calculate the certain gray matter thresholds to indicate a trend to substantiate looking into this process in the first place. Voxel-based morphometry (VBM) is a fully automated image analysis technique allowing identification of regional differences in gray matter (GM) and white matter (WM) between groups of subjects without a prior region of interest. It is largely popular because of the fact that it is relatively easy to use and has provided biologically plausible results. The current solution uses the variations of response by the gray matter to the MRI scans. The novelty in my research points toward a change in its composition making that the biomarker per-say but we could shorten it as the gray matter evolution is a biomarker relevant to glioblastoma prediction.

The fact that the algorithm is working and using a MRI scan which mainly revolve around detecting grey matter is a proof of the grey matter being a biomarker.

## **6. Future Perspectives:**

Because of the constant progress that has been made in medical research and technology, the future of glioblastoma therapy promises to be filled with positive prospects. Researchers are investigating a variety of immunotherapy treatments in order to activate the immune system of the body to recognize and destroy glioblastoma cells[30]. Checkpoint inhibitors of the immune system, chimeric antigen receptor (CAR) T-cell therapy, and cancer vaccines are all included in this category. There is a possibility that immunotherapy could provide patients with glioblastoma with new treatment options. Immunotherapy has demonstrated promising outcomes in treating other types of cancer. For the purpose of developing targeted therapies, researchers are continually locating particular molecular targets and genetic abnormalities that are responsible for the progression of glioblastoma[31]. In order to restrict the growth of tumors while protecting normal cells, targeted therapies try to interrupt the abnormal pathways that are responsible for their development. It is possible that targeted therapy will become more successful and personalized as our understanding of the molecular foundations of glioblastoma continues to grow. Advances in genome sequencing technologies have made it possible to do a full examination of a patient's tumor DNA, which is a key component of

precision medicine. This information can assist in identifying specific genetic abnormalities that are responsible for the growth of tumors and can guide decisions for treatment. The goal of precision medicine is to adjust treatments to the unique genetic composition of each patient's tumor, which could result in treatment regimens that are both more successful and more tailored to the individual than those currently available. In the field of nanomedicine, nanotechnology presents novel approaches to the delivery of drugs and the delivery of tailored therapies. It is possible to create nanoparticles in such a way that they preferentially deliver therapeutic medicines to glioblastoma cells while minimizing injury to healthy tissue. In addition, nanoparticles have the ability to pass through the blood-brain barrier, which is a barrier that is frequently encountered when treating brain tumors[32]. The application of nanomedicine has the potential to improve the effectiveness of currently available treatments and to overcome some of the limitations that are associated with conventional medicines. Technologies for editing genes, like as CRISPR-Cas9, have the ability to directly target and alter the genetic abnormalities that are responsible for the growth of glioblastoma. The goal of gene therapy approaches is to either repair genes that have been mutated or introduce therapeutic genes in order to limit the progression of tumors[33]. Gene therapy shows promise as a potential future treatment option for glioblastoma, despite the fact that it is still in the early phases of evaluation and research. In light of the multifaceted nature of glioblastoma, researchers are looking into combination therapy that target many elements of tumor growth and survival. Combining more conventional treatments, such as surgery, chemotherapy, and radiation therapy, with more contemporary methods, such as immunotherapy, targeted therapy, and gene therapy, is an example of this. The use of combination medicines has the potential to have synergistic benefits and improve treatment outcomes for people suffering from glioblastoma. The translation of promising preclinical results into viable medicines for patients is still a considerable issue, despite the fact that these breakthroughs give promise for improved outcomes in the treatment of glioblastoma[34]. For the purpose of determining whether or not new treatment methods are both safe and effective, clinical trials are an indispensable component. They are also necessary for the introduction of novel therapies into clinical practice. At the same time, it is necessary for researchers, physicians, and industry partners to work together across multiple disciplines in order to accelerate development in the field of glioblastoma treatment.

## Conclusions:

During the diagnostic process, patients who have been diagnosed with GBM/HGG have various locations in the hemisphere that is contralateral to the tumor that show cortical thinning. On top of that, the hemispheric CT and a subset of these morphological abnormalities (i.e., cortical thinning in lobes and parcels) were found to be highly predictive of survival in patients. It is possible that scientists will use the same procedure as them in order to determine the specific grey matter thresholds that will signal a trend in order to justify the investigation of this process in the first place. Voxel-based morphometry, often known as VBM, is a technique for analysing images that is totally automated and allows for the discovery of regional changes in grey matter (GM) and white matter (WM) between groups of participants that do not have a prior region of interest. The fact that it is relatively simple to use and has produced results that are realistic from a biological standpoint is a major contributor to its widespread popularity. The approach that is now being utilized makes use of the differing responses that the grey matter has to the MRI scans. It is possible that we may abbreviate it because the grey matter evolution is a biomarker that is significant to glioblastoma prediction. The interesting thing about my research is that it indicates a change in its composition, which would make that the biomarker per-say.

## References

---

1. Tsien, C., et al., *ACTR-32. NRG oncology RTOG 1205: randomized phase II trial of concurrent bevacizumab and re-irradiation vs. bevacizumab alone as treatment for recurrent glioblastoma*. *Neuro Oncol*, 2019. **21**.
2. Venkataramani, V., et al., *Glutamatergic synaptic input to glioma cells drives brain tumour progression*. *Nature*, 2019. **573**.
3. Vijapura, C., et al., *Genetic syndromes associated with central nervous system tumors*. *Radiographics*, 2017. **37**.
4. Weller, M., *Where does O6 -methylguanine DNA methyltransferase promoter methylation assessment place temozolomide in the future standards of care for glioblastoma?* *Cancer*, 2018. **124**.
5. Weller, M., et al., *EANO guidelines on the diagnosis and treatment of diffuse gliomas of adulthood*. *Nat Rev Clin Oncol*, 2021. **18**.
6. Weller, M., et al., *Prolonged survival with valproic acid use in the EORTC/NCIC temozolomide trial for glioblastoma*. *Neurology*, 2011. **77**.
7. Weller, M. and E. Rhun, *How did lomustine become standard of care in recurrent glioblastoma?* *Cancer Treat Rev*, 2020. **87**.

8. Applebaum, A.J., et al., *Prognostic awareness and communication preferences among caregivers of patients with malignant glioma*. *Psychooncology*, 2018. **27**.
9. Armstrong, T.S., et al., *Sleep-wake disturbance in patients with brain tumors*. *Neuro Oncol*, 2017. **19**.
10. Armstrong, T.S., et al., *The symptom burden of primary brain tumors: evidence for a core set of tumor- and treatment-related symptoms*. *Neuro Oncol*, 2016. **18**.
11. Beevers, Z., et al., *Pharmacological treatment of depression in people with a primary brain tumour*. *Cochrane Database Syst Rev*, 2020. **7**.
12. Bergo, E., et al., *Neurocognitive functions and health-related quality of life in glioblastoma patients: a concise review of the literature*. *Eur J Cancer Care (Engl)*, 2019. **28**.
13. Brikell, I., et al., *Medication treatment for attention-deficit/hyperactivity disorder and the risk of acute seizures in individuals with epilepsy*. *Epilepsia*, 2019. **60**.
14. Chaichana, K.L., et al., *Factors involved in maintaining prolonged functional independence following supratentorial glioblastoma resection. Clinical article*. *J Neurosurg*, 2011. **114**.
15. Amirian ES, Ostrom QT, Armstrong GN, et al. *Aspirin, non-steroidal anti-inflammatory drugs (NSAIDs), and glioma risk: original data from the glioma international case-control study and a meta-analysis*. *Cancer Epidemiol Biomarkers Prev*. 2019 Mar;28(3):555–62.
16. Chaudhry, N.S., et al., *Predictors of long-term survival in patients with glioblastoma multiforme: advancements from the last quarter century*. *Cancer Invest*, 2013. **31**.
17. *IARC Working Group on the evaluation of carcinogenic risks to humans. Non-ionizing radiation, part 1: static and extremely low-frequency (ELF) electric and magnetic fields*. Lyon, France; IARC. 2002.
18. *Brain tumour risk in relation to mobile telephone use: results of the INTERPHONE international case-control study*. *Int J Epidemiol*, 2010. **39**.
19. Amirian, E.S., G.N. Armstrong, and R. Zhou, *The glioma international case-control study: a report from the genetic epidemiology of Glioma International Consortium*. *Am J Epidemiol*, 2016. **183**.
20. Alles, B., C. Pouchieu, and A. Gruber, *Dietary and alcohol intake and central nervous system tumors in adults: results of the CERENAT multicenter case-control study*. *Neuroepidemiology*, 2016. **47**.
21. Andersson, U., S. Degerman, and A.M. Dahlin, *The association between longer relative leukocyte telomere length and risk of glioma is independent of the potentially confounding factors allergy, BMI, and smoking*. *Cancer Causes Control*, 2019. **30**.
22. Anssar, T.M., M.F. Leitzmann, and R.A. Linker, *Autoimmune diseases and immunosuppressive therapy in relation to the risk of glioma*. *Cancer Med*, 2020. **9**.
23. Bouffet, E., V. Larouche, and B.B. Campbell, *Immune checkpoint inhibition for hypermutant glioblastoma multiforme resulting from germline biallelic mismatch repair deficiency*. *J Clin Oncol*, 2016. **34**.
24. Carlberg, M., et al., *Case-control study on occupational exposure to extremely low-frequency electromagnetic fields and glioma risk*. *Am J Ind Med*, 2017. **60**.
25. Chen, H., G. Chen, and G. Li, *Two novel genetic variants in the STK38L and RAB27A genes are associated with glioma susceptibility*. *Int J Cancer*, 2019. **145**.
26. Chen, H., B. Sun, and Y. Zhao, *Fine mapping of a region of chromosome 11q23.3 reveals independent locus associated with risk of glioma*. *PLoS One*, 2012. **7**.
27. Codd, V., C.P. Nelson, and E. Albrecht, *Identification of seven loci affecting mean telomere length and their association with disease*. *Nat Genet*, 2013. **45**.
28. Cote, D.J., et al., *A prospective study of tea and coffee intake and risk of glioma*. *Int J Cancer*, 2020. **146**.

29. Lamichhane, B., et al., *Structural gray matter alterations in glioblastoma and high-grade glioma—A potential biomarker of survival*. *Neuro-Oncology Advances*, 2023. **5**(1).
30. Disney-Hogg, L., A.J. Cornish, and A. Sud, *Impact of atopy on risk of glioma: a Mendelian randomisation study*. *BMC Med*, 2018. **16**.
31. Dubrow, R., et al., *Coffee, tea, soda, and caffeine intake in relation to risk of adult glioma in the NIH-AARP Diet and Health Study*. *Cancer Causes Control*, 2012. **23**.
32. Kuan, A.S., J. Green, and C.M. Kitahara, *Diet and risk of glioma: combined analysis of three large prospective studies in the UK and USA*. *Neuro-Oncology*, 2019. **21**.
33. Labreche, K., B. Kinnersley, and G. Berzero, *Diffuse gliomas classified by 1p/19q co-deletion, TERT promoter and IDH mutation status are associated with specific genetic risk loci*. *Acta Neuropathol*, 2018. **135**.
34. Leece, R., et al., *Global incidence of malignant brain and other central nervous system tumors by histology, 2003–2007*. *Neuro-Oncology*, 2017. **19**.