

### **PERSISTENT MULLERIAN DUCT SYNDROME WITH UNDESCENDED TESTIS AND TESTICULAR SEMINOMA - A RARE CASE WITH REVIEW OF LITERATURE**

#### **ABSTRACT**

Persistent Mullerian Duct Syndrome (PMDS) is a rare type of male pseudohermaphroditism<sup>1</sup>. It is brought on by an insufficiency of anti-mullerian hormone (AMH) or a malfunction of its receptor (type II). Approximately 150 adult cases<sup>2</sup> of PMDS have been documented overall, with the majority from the Middle East, USA and Europe. 44 publications (49 individuals)<sup>3</sup> with 3 testicular tumors linked to PMDS were found using the Medline/Pubmed search; the majority (59%)<sup>3</sup> of the patients presented with a big abdominal mass. In our case, the abdomen mass that was identified as seminoma testis in a 22-year-old male patient with PMDS. Our goal in presenting this case is to highlight how uncommon it is for PMDS patients to have a testicular tumor, and how the presence of an undescended testis raises the risk of testicular tumor development in PMDS patients. The clinicians should be aware of rare entity while dealing with the cryptorchidism with inguinal hernia and necessary management should be done to offer proper treatment.

**Keywords:** PMDS, anti-mullerian hormone, testicular tumor, pseudohermaphroditism

#### **INTRODUCTION**

PMDS is brought on by either a type II receptor deficiency or a lack of anti-Mullerian hormone (AMH) secretion or action. It is defined by the existence of a uterus, fallopian tubes, upper vagina, and external genitalia of the male kind in an individual. The karyotype is of XY type. Its remarkable syndromic relationship with testicular cancer, which frequently develops

on cryptorchid testis, was initially reported by NILSON in 1939<sup>4</sup>. Testosterone is secreted by fetal Leydig cells and fetal Sertoli cells secrete anti-Mullerian hormone. Male external genitalia develop due to the effect of testosterone. Fetal mullerian duct structures regress due to the effect of anti-Mullerian hormone<sup>7</sup>. Anti-Mullerian hormone production occur during 7<sup>th</sup> week of gestation by Sertoli cells.<sup>1</sup> Mullerian duct structures(Uterus, cervix, fallopian tubes and upper two thirds of vagina) undergo regression during fetal life in a normal male. So PMDS affects sex development in which mullerian duct structures are found in a normal phenotypic and genotypic male with male external genitalia. Due to association of PMDS with cryptorchidism and malignancy, the main aim of treatment is to prevent or detect testicular malignancy and protect patients fertility. Testicular cancer in a case of PMDS usually occurs in adults due to neglected cryptorchidism or undescended testis.

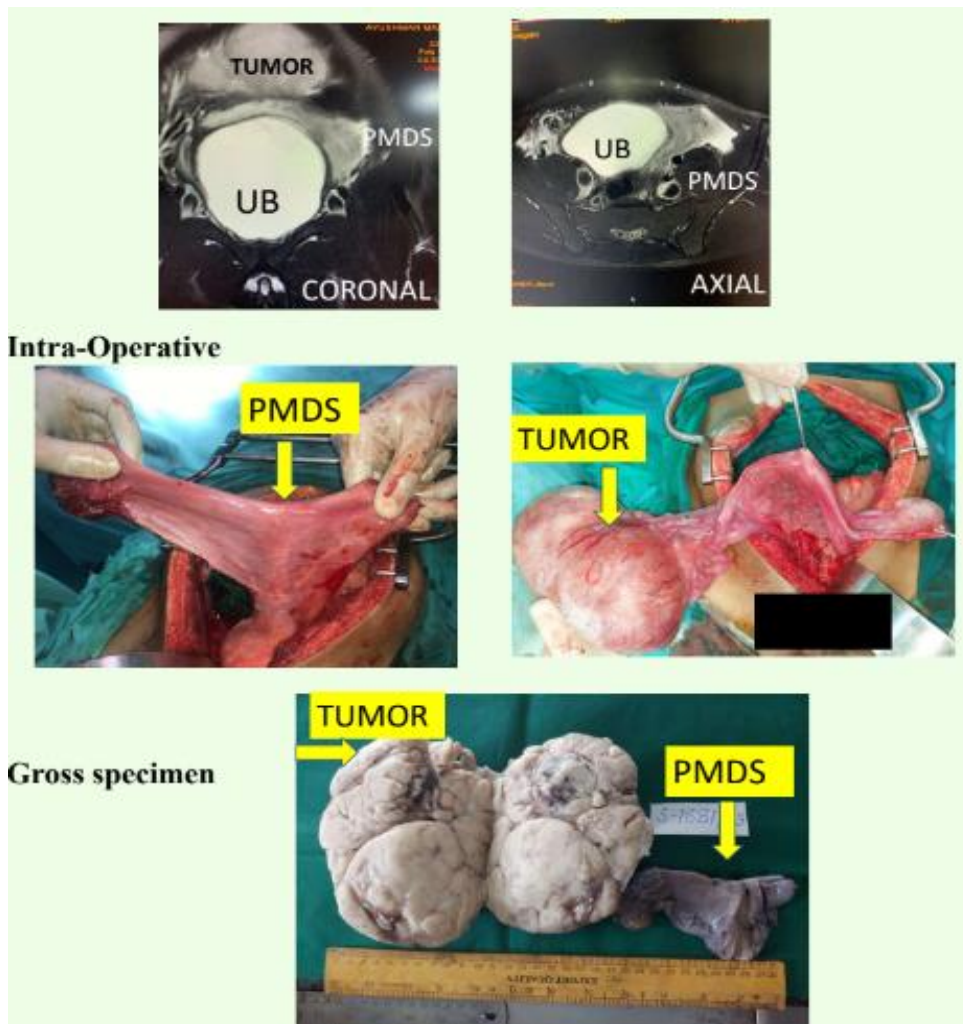
### **CASE PRESENTATION**

A 22 year male patient presented with history of right sided abdominal pain since 4 years and fullness of lower abdomen since 2 months. On examination, there was an abdominal mass of size 12x6cm, firm to hard in consistency, extending from umbilical region to hypogastrium. Associated with bilateral irreducible inguinal hernia, empty right hemiscrotum and well developed penis. CECT abdomen and pelvis with thorax was suggestive of large lobulated mass lesion of size 16x12x8.7cm in right iliac, lumbar and lower mid abdomen region. No retroperitoneal or paraaortic lymph nodes. Right testis not seen in right scrotal sac and bilateral inguinal hernia with peritoneal fat on right side and left horn of persistent mullerian duct on left side as its content. Beta HCG(112.1mIU/ml) and LDH(1530U/L) was elevated. AFP(5.59ng/ml) was normal. OT finding -1)mass in right lumbar region with rudimentary uterus, 2)mass has supply of gonadal vessels, 3)uterus with right fallopian tube going into deep inguinal ring, 4)left side testis delivered into abdomen looks normal but small in size, 5)left fallopian tube/round ligament going into deep inguinal ring, 6)left testis preserved and orchidopexy done, 7)abdominal mass was sent for frozen section and found out to be of testicular origin. Excision of abdominal mass with remnant of mullerian

duct(uterus, B/L fallopian tubes and upper part of vagina) was done. Final histopathology report with IHC(tumor cells are immunopositive for CD117 and SALL4 while negative for CD30 and AFP)confirmed malignant GCT(seminoma) of right testis with LVI, stage pT2 and persistent mullerian duct structures. Patient received 2 cycles of adjuvant chemotherapy(carboplatin) as per multidisciplinary tumour board decision.Follow up ultrasound abdomen, beta HCG, LDH and AFP after 6 months of treatment were normal.

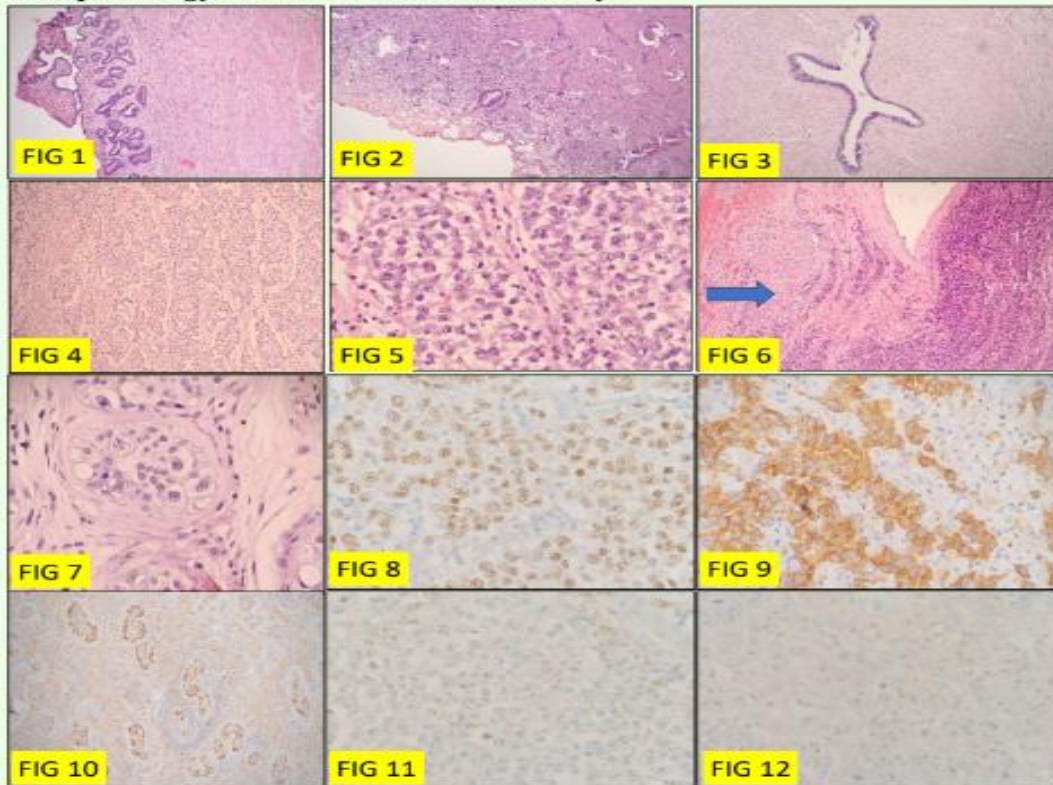
**Fig 1:- Showing imaging, intraoperative findings & gross specimen**

UNDER PEER REVIEW



**Fig 2 :-Histopathology and IHC of the specimen**

### Histopathology and Immunohistochemistry:



**Fig 1:-** Endomyometrium displaying primitive glands, ill formed stroma underlying myometrium (H&E, 200X).

**Fig:2:-** Cervix shows few primitive glands over collagenized stroma. No overlying lining epithelium identified (H&E, 200X)

**Fig:3:-** Fallopian tube structure show primitive pseudostratified columnar epithelial lining. (H&E, 200X)

**Fig:4,5,6:-** Neoplastic cells arranged in sheets, thin fibrovascular septae with lymphocytic infiltration., granuloma (Arrow)

**Fig 7:-**Germ cell neoplasia in situ .**Fig 8:-** SALL4 (diffuse nuclear) positive (Diaminobenzidine,400X)

**Fig- 9,10:-** Tumor cells are immunopositive for CD 117[( cytoplasmic and nuclear), (Diaminobenzidine,400X)] Highlights GCNIS component (Diaminobenzidine,200X)

**Fig 11,12:-** Tumor cells are negative for CD30 and AFP (Diaminobenzidine,400X)

### DISCUSSION

The uncommon condition known as Persistent Mullerian Duct Syndrome (PMDS) is an internal male pseudo-hermaphrodite state. The genotype and phenotype is of the normal

male. It is characterized by persistence of the Mullerian duct structures (uterus, cervix, fallopian tubes, and upper part of the vagina). This condition is brought on by lack of Mullerian inhibiting factor (MIF) being produced by immature Sertoli cells in the testes that have just developed. It might be identified in childhood or later in life. During the seventh week of pregnancy, the Leydig cells and Sertoli cells of the developing testes in a male fetus begin to produce testosterone and MIF, respectively. Mullerian duct structures survive when there is a flaw in this typical pathway. Since it obstructs the normal testicular descent, these residual Mullerian structures cause cryptorchidism. External genitalia and wolffian duct structures develop into a typical male since the production of testosterone and reaction of target organs to testosterone are unaffected. In accordance with the anatomical structure, PMDS is classified into male and female forms. Males account for over 80% of cases, making them the most prevalent form. These come in three varieties. Testes in a position similar to the ovaries are found in type I (60–70%)<sup>4</sup>, while type II (20–30%), has one testis in the hernial sac or scrotum along with mullerian structures<sup>4</sup>, also known as hernia uteri inguinal. Type III (10%) has both testes, fallopian tubes, and the uterus (transverse testicular ectopia) all located in the same hernial sac<sup>4</sup>. Type II refers to our patient. PMDS is extremely rare and is rarely detected prior to surgery. Most often, there is vague abdominal and pelvic pain with a non-specific clinical presentation. It has also been reported that the condition was accidentally discovered while exploring infertility<sup>8</sup>. Patients may experience loss of appetite, loss of weight, pain abdomen, or symptoms connected to the tumor growth<sup>5</sup> when they have a cryptorchid testes tumor, as was the situation with our patient. Surgical treatment with removal of tumour and Mullerian derivatives yields the greatest results. In patients with PMDS, the risk of cancer in an ectopic testis is comparable to that of a cryptorchid testis in a normal male<sup>6</sup>. Chemotherapy lowers the likelihood of recurrence, however the disease's prognosis is dependent on the tumor's characteristics.

**Table 1 :LITERATURE REVIEW OF PMDS WITH TESTICULAR TUMOR**

<b>CASES</b>	<b>TYPE OF MALIGNANCY</b>	<b>CONCLUSION</b>	<b>REFERENCES</b>
<p>Searches for case reports and reviews using the PubMed database (<a href="http://www.ncbi.nlm.nih.gov/pubmed">www.ncbi.nlm.nih.gov/pubmed</a>) yielded 45 publications in foreign languages and 5 papers in Chinese when the search term persistent Müllerian duct syndrome was used. There are approximately 150 adult instances of PMDS recorded worldwide, with the majority from Middle East, USA and Europe. Eleven young patients at the Fudan University Children's Hospital in Shanghai, China, were identified as having PMDS during laparoscopic surgery.</p>	<p>In patients with PMDS, 30 instances of malignant transformation have been found. Most malignant tumors are found in ectopic testes, with the Müllerian remnants being the site of only few of them. It is known of just one patient who got endocervical adenocarcinoma and another with clear cell adenocarcinoma. Tumors involving ectopic testis can be seminomatous or non-seminomatous germ</p>	<p>Maintaining the patient's fertility and preventing or early identifying the malignancy in mullerian duct derivatives and undescended or ectopic testis are the main goals of treatment.</p>	<p>1</p>

	cell tumors, with seminomas being the most prevalent type.		
A Medline/PubMed search turned up 44 publications (49 patients) with testicular tumors linked to PMDS; most of the patients (59%) had a noticeable abdominal mass when they first appeared.	Most frequent are seminomas (approximately 75%).	Adults with advanced stage disease who have neglected or received insufficient treatment for their cryptorchidism are typically the ones that come with testicular cancer in PMDS.	3
Thirty-seven of the 39 instances of PMDS-associated cancers that have been documented in the literature have been linked to various testicular tumors. Actually, testicular neoplasms are the most often reported malignancies in PMDS.	The most frequent cancer to manifest is a seminomatous germ cell tumor. Additionally documented were germ cell tumors of non-seminomatous type and an	The primary objectives of PMDS treatment are fertility preservation, the treatment of undescended testes and persistent	7

	<p>instance of combined teratoma and choriocarcinoma. There have only been 20 cases of PMDS associated with testicular cancer recorded thus far. Malignant transformation of the abdominal testes occurs in healthy males with undescended testes at a rate of 5% to 18% overall. Compared to testicular cancer, Mullerian malignancies are far less common. The Mullerian derivative malignant transformation rate of PMDS ranges</p>	<p>Mullerian duct structures , and the avoidance of residual cancer in mullerian duct structures. Patients with PMDS are treated surgically.</p>	
--	--	--	--

	<p>from 3.1% to 8.4%, according to a case series by Farikullah et al.</p>		
<p>Patients with PMDS have an increased risk of testicular cancer, similar to those who have isolated undescended testicles. Twenty cases of PMDS with testicular cancer have been documented thus far.</p>	<p>Seminoma is the most prevalent type of testicular cancer, with embryonal carcinoma, teratocarcinoma, and choriocarcinoma following in order of frequency.</p>	<p>Managing undescended testicles and Mullerian duct derivatives, preventing Mullerian remains from becoming malignant, and preserving fertility are the major objectives of treatment for patients with PMDS.</p>	8
<p>Due to its rarity, PMDS is typically not well reported; nonetheless, because of its epidemiological association with GCT and potential for infertility, it is crucial to be aware of this</p>	<p>The incidence of GCT in adults with PMDS has been estimated to reach up to 33%, which is higher than the risk</p>	<p>As discussed in this study, radiological or intraoperative evidence are frequently used</p>	10

<p>disorder.</p>	<p>of isolated cryptorchidism. The most common histotype is seminoma, however other histotypes that have been reported include, mixed germ cell tumor, embryonal cell carcinoma, choriocarcinoma, yolk sac tumor and gonadoblastoma.</p>	<p>to suspect PMDS diagnosis because of its rarity. In conclusion, if a patient has bilateral cryptorchidism, PMDS should always be considered and genetic counseling should be contacted right away. This is crucial to lower the chance of infertility and GCT.</p>	
------------------	--	---	--

**CONCLUSION**

A rare entity is PMDS with a germ cell tumor. It is challenging to diagnose preoperatively and, consequently, to anticipate intraoperatively due to its rarity. When treating cryptorchidism and cancer in it, surgeons and pathologists should be aware of this circumstance. An intra-abdominal testis has a higher chance of getting cancer and other symptoms. In such a case, the mullerian remains ought to be removed as well when undertaking surgery for a germ cell tumor.

UNDER PEER REVIEW

**REFERENCES:**

1. Persistent Müllerian duct syndrome: A case report and review Xiaoya Ren , Di Wu , Chunxiu Gong.
2. Nerune SM, Hippargi SP, Mestri NB, Mehrotra NM. Persistent mullerian duct syndrome with ovarian endometriosis - a rare case report. *J Chin Diagn Res*. 2016;10(2):ED14–5.
3. Testicular malignancy in persistent Mullerian duct syndrome: Experience from an apex cancer center with review of literature-April 2023-Malar Raj Philips , Arun Ramdas Menon , Gaurav RKumar , Kanuj Malik , Sruti Chandrasekaran , Thendral Ramaswamy , Kathiresan Narayanaswamy , Anand Raja.
4. J.Y. Picard, R.L. Cate, C. Racine, N. Josso. The persistent müllerian duct syndrome: an update based upon a personal experience of 157 cases.
5. Cancer on cryptorchid testis revealing a Persistent Müllerian Duct Syndrome: A rare case Author links open overlay panelAhmed Samet, Mohamed Amine Mseddi, Rami Bahloul, Nouri Rebai, Ali Bahloul, Mourad Hadj Slimène.
6. R. Aboutorabi, B. Feiz zadeh, R. RajabianGynecomastia secondary to choriocarcinoma in a man with persistant mullerian ductInt J Endocrinol Metab, 3 (2005), pp. 140-142.
7. Mahsa Ahadi, Hussein Soleimantabar, Babak Javanmard, Sara ZahedifardA Rare Case of Persistent Mullerian Duct Syndrome and Review of Literature.
8. Abdullah B. Alanazi,\* Afrahdhowayan, Mousa M. Almuhanha, and Abdullah M. Alghamdi : Persistent Mullerian duct syndrome (PMDS): Case report and review of literature.
9. Hsi-Chin W. Persistent Müllerian duct syndrome with seminoma. *Am J Roentgenol*. 2000;174(1) (AJR).
10. Persistent Müllerian Duct Syndrome and Germ Cell Tumor: A Case Report and a Review of the Literatureby D Alaimo, G Galli, F Sirchia, S Bursi, M Lucchesi, A Gallotti, R Naspro, P Pedrazzoli, G Rosti, S Marino, S Secondino